

Original Article

Pressure- and Velocity-Based Physiological Assessment of Stenotic Lesions at Hyperemia in Superficial Femoral Artery Disease: Importance of Hyperemic Stenosis Resistance

Kuniyasu Ikeoka, MD, PhD, Tetsuya Watanabe, MD, PhD, Yukinori Shinoda, MD, Tomoko Minamisaka, MD, Hidetada Fukuoka, MD, Hirooki Inui, MD, Keisuke Ueno, MD, Soki Inoue, MD, Kentaro Mine, MD, and Shiro Hoshida, MD, PhD

Background: In superficial femoral artery (SFA) stenosis, stenosis resistance may increase, but the relationship between stenosis resistance and stenotic severity remains to be seen. This study aimed to investigate the physiological response, through a hyperemic condition, and the pathophysiological significance of Doppler flow and stenosis resistance in SFA.

Methods: Twenty-four limbs with focal stenosis of the SFA were analyzed. We assessed the fractional flow reserve (FFR), hyperemic stenosis resistance (h-SR), and vascular flow reserve (VFR) of the SFA with a pressure/Doppler flow sensor-tipped combination guidewire before and after endovascular therapy (EVT).

Results: FFR, h-SR, and VFR changed significantly after EVT. h-SR was more strongly correlated with % area stenosis, measured by intravascular ultrasound than FFR (FFR: $r=-0.716$, h-SR: $r=0.741$, $p<0.0001$, respectively). However, VFR was not associated with % area stenosis. A receiver operating characteristic curve showed cut-offs h-SR >0.36 mmHg·sec/cm, and FFR <0.88 predicted $>75\%$ area stenosis with area under curves of 0.883 and 0.828, respectively.

Conclusion: h-SR can indicate stenotic severity in an SFA focal lesion more prominently than FFR and may be a new physiological index to determine indication for EVT. VFR was

not feasible for assessment in SFA focal stenosis.

Keywords: fractional flow reserve, hyperemic stenosis resistance, % area stenosis, superficial femoral artery, vascular flow reserve

Introduction


In coronary arteries, several physiological parameters have been introduced to diagnose functional coronary lesion severity and indicate therapy.^{1–3} The fractional flow reserve (FFR), a pressure-derived metric, was more closely correlated with coronary stenotic severity. Moreover, the velocity-derived, coronary flow reserve indicates coronary microvascular disease.^{3,4} However, in case of the lower-limb circulation, it is unclear whether the same regulatory mechanisms play a role. Several studies reported translational pressure measurement, with pressure sensor wires, to calculate FFR in peripheral arterial diseases.^{5–7} In pathophysiological conditions, such as stenosis of the superficial femoral artery (SFA), stenosis resistance may increase, but the relationship between stenosis resistance and stenotic severity remains to be seen. We aimed to elucidate SFA stenosis resistance's pathophysiological significance at maximal hyperemia. We simultaneously assessed a pressure- and velocity-based index of hyperemic stenosis resistance (h-SR) using a dual-sensor (pressure and Doppler velocity)-equipped guidewire before and after endovascular therapy (EVT).⁸

Methods

The study population consisted of 24 subjects (16 men, 8 women) who underwent EVT for isolated mid or distal SFA focal lesions between May 2016 and December 2017. We excluded subjects with SFA ostial lesions, popliteal arterial lesions, chronic total occlusive lesions, and diffuse

Department of Cardiovascular Medicine, Yao Municipal Hospital, Yao, Osaka, Japan

Received: March 12, 2019; Accepted: April 18, 2019
Corresponding author: Shiro Hoshida, MD, PhD. Department of Cardiovascular Medicine, Yao Municipal Hospital, 1-3-1 Ryuge-cho, Yao, Osaka 581-0069, Japan
Tel: +81-72-922-0881, Fax: +81-72-924-4820
E-mail: shiro.hoshida@hosp-yao.osaka.jp

 ©2019 The Editorial Committee of Annals of Vascular Diseases. This article is distributed under the terms of the Creative Commons Attribution License, which permits use, distribution, and reproduction in any medium, provided the credit of the original work, a link to the license, and indication of any change are properly given, and the original work is not used for commercial purposes. Remixed or transformed contributions must be distributed under the same license as the original.

lesions over 15 cm long, applicable to TASC C or D. Moreover, we excluded limbs associated with aorto-iliac inflow lesions, critical limb ischemia, low left ventricular ejection fraction (<40%) on echocardiogram, atrial fibrillation, and chronic renal disease maintained on hemodialysis. Patients who were papaverine intolerant were also excluded. The study protocol followed the principles outlined in the Declaration of Helsinki, and the Yao Municipal Hospital's institutional review board approved the study. Written informed consent was obtained from all subjects.

After local anesthesia induction, a 6-Fr guiding sheath (Destination, Terumo, Tokyo, Japan) was advanced to a point of the common femoral artery through a contralateral femoral approach. An intra-arterial bolus of 5,000 IU heparin was injected. A 0.014-in pressure/Doppler sensor-tipped guidewire (ComboWire XT; Philips Volcano, San Diego, CA, USA) was calibrated outside the body and equalized to the common femoral artery pressure. The sensor-tipped guidewire was then advanced into the SFA. The intra-arterial pressure curve and Doppler wave were obtained distal to the stenotic lesions. The mean distal pressure (MDP) and average peak velocity (APV) at baseline were obtained from the pressure/Doppler analyzer (ComboMap; Philips Volcano, San Diego, CA, USA). Then 20 mg of intra-arterial papaverine was administered to the lower limb, via a guiding catheter, to induce hyperemia. All administrations were at least 3 min after the previous one after returning to baseline hemodynamic conditions. Saline was flushed after each administration. The FFR was obtained as the MDP/mean proximal pressure (MPP) at hyperemia. The vascular flow reserve (VFR) was obtained as hyperemic APV/baseline APV. h-SR was obtained as (hyperemic MPP–hyperemic MDP)/hyperemic APV. An intravascular ultrasound (IVUS) examination was performed to record vessel characteristic data. A commercially available IVUS catheter (Eagle Eye Gold; Philips Volcano, San Diego, CA, USA) was used to examine the minimum lumen area, the external elastic membrane (EEM) area, and % area stenosis. The IVUS catheter was manually pulled back. The indication for revascularization was symptomatic disease (Rutherford category 2–3), with $\geq 70\%$ diameter stenosis on angiography, according to the Japanese Circulation Society's guidelines for patients with

peripheral artery disease. The lesion was dilated, using a balloon catheter, with a diameter equal to the reference vessel diameter. After balloon dilatation for at least 1 min, stenting was done if there was flow-limiting dissection, a pressure gradient ≥ 5 mmHg, or $\geq 30\%$ residual stenosis. Patients received nitinol self-expandable stents (Lifestent; Bard, Murray Hill, NJ, USA) with a diameter 1 mm larger than the reference vessel diameter. The FFR, VFR and h-SR were repeatedly calculated after balloon dilatation and/or stenting. Only two subjects could not be analyzed after stenting because of sensor-tipped guidewire damage.

Continuous variables are reported as mean \pm standard deviation, and categorical variables as frequencies. An unpaired or paired t-test was performed, as appropriate, to compare continuous variables between groups, and the Chi-square test was used to compare proportions between groups. Linear regression showed the relationship between the groups. A p value of <0.05 was considered statistically significant. The receiver operating characteristic

Table 1 Baseline clinical characteristics

Age, y	73.7 \pm 6.7
Men, n (%)	16 (67)
Body mass index	25.2 \pm 3.6
Arteriosclerosis risk factors, n (%)	
Hypertension	23 (96)
Dyslipidemia	15 (63)
Diabetes mellitus	15 (63)
Chronic kidney disease	1 (4)
Current smoking	12 (50)
Coronary artery disease, n (%)	20 (83)
Cerebral artery disease, n (%)	13 (54)
Rutherford category (2/3)	3/21
TASC II classification (A/B)	12/12
Lesion length, cm	9.2 \pm 5.2
Below the knee run off (0/1/2/3)	0/8/8/8
Ankle-brachial index	0.83 \pm 0.13
Intravascular ultrasound data	
EEM area, mm ²	27.6 \pm 5.8
Minimum lumen area, mm ²	5.8 \pm 2.6
% area stenosis	79.0 \pm 8.4

Values are mean \pm standard deviation or numbers (%).

EEM: external elastic membrane

Table 2 Hemodynamic characteristics of the superficial femoral artery stenoses

	b-APV (cm/sec)	h-APV (cm/sec)	VFR	h-MDP (mmHg)	h-MPP (mmHg)	FFR	h- Δ P (mmHg)	h-SR (mmHg·sec/cm)
pre EVT	20.9 \pm 7.1	35.8 \pm 12.4	1.73 \pm 0.31	71.8 \pm 14.5	89.5 \pm 18.6	0.81 \pm 0.12	17.2 \pm 13.3	0.56 \pm 0.44
post EVT	22.6 \pm 7.8*	42.8 \pm 12.2**	1.91 \pm 0.41*	81.4 \pm 13.4**	84.8 \pm 15.1	0.97 \pm 0.056**	3.67 \pm 5.13**	0.088 \pm 0.12**

Values are mean \pm standard deviation. "b" indicates baseline; "h" indicates during hyperemia.

APV: average peak velocity; VFR: vascular flow reserve; MDP: mean distal pressure; MPP: mean proximal pressure; FFR: fractional flow reserve; Δ P: mean pressure gradient (MPP–MDP); SR: stenosis resistance index; EVT: endovascular therapy

*p<0.05 compared with pre EVT. **p<0.01 compared with pre EVT.

curve assessed the cut-off indicating $>75\%$ area stenosis. The best cut-off point for balancing the sensitivity and specificity of the test was the point on the curve closest to the upper left-hand corner (0, 1) point. All statistical analyses were performed with EZR (Saitama Medical Center, Jichi Medical University, Saitama, Japan), a graphical user interface for R (The R Foundation for Statistical Computing, Vienna, Austria).

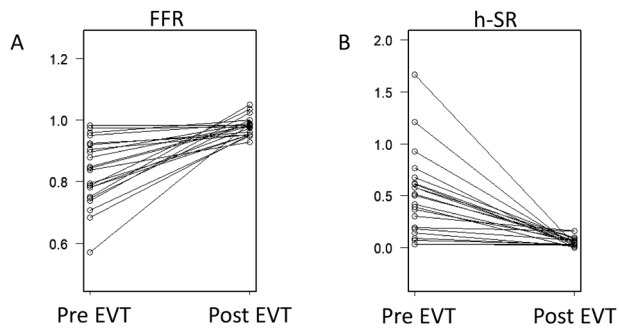


Fig. 1 Changes in fractional flow reserve (FFR, **A**) and hyperemic stenosis resistance (h-SR, **B**) values following endovascular therapy (n=22).

Results

Table 1 provides the study subjects' baseline clinical characteristics. The isolated, focal stenotic lesions in the SFA were analyzed in this study. The lesions were within TASC II classification A or B, and the mean lesion length was 9.2cm. We excluded critical limb ischemia patients who may have had microvascular disease. All lesions were analyzed by IVUS. Revascularization was obtained in all lesions, but eight limbs required stenting after balloon angioplasty.

EVT-induced hemodynamic changes were evaluated with a pressure/Doppler flow sensor-tipped combination guidewire (Table 2). In only two cases, physiological values could not be evaluated after stenting because of wire malfunction. The FFR in the target lesion vessels was 0.81 ± 0.12 before EVT and improved significantly after EVT (Fig. 1A). h-SR was 0.56 ± 0.44 mmHg·sec/cm before EVT and reduced to near zero level after EVT (Fig. 1B). The % area stenosis before EVT was significantly correlated with FFR and h-SR; compared to the % area stenosis and FFR ($r = -0.716$, Fig. 2A), the % area stenosis

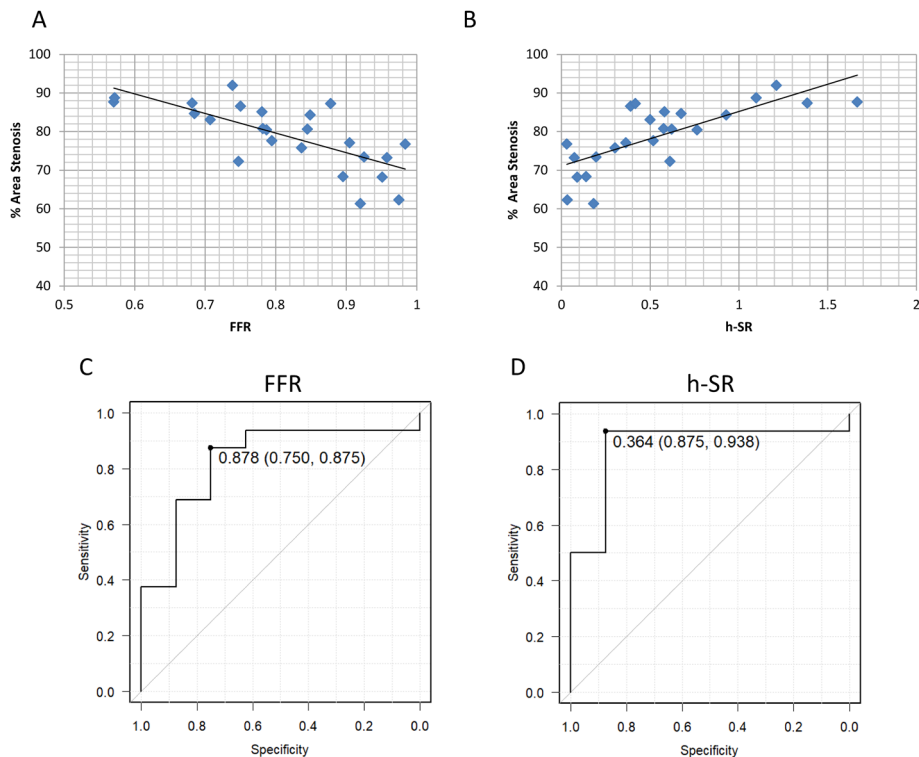


Fig. 2 The relationship of fractional flow reserve (FFR) and hyperemic stenosis resistance (h-SR), with % area stenosis, measured by intravascular ultrasound before endovascular therapy (EVT). A significant correlation of FFR and h-SR was observed with % area stenosis before EVT (FFR: $r = -0.716$, h-SR: $r = 0.741$, $p < 0.0001$, respectively) (**A**, **B**). A receiver operating characteristic curve showed cut-offs FFR < 0.88 and h-SR > 0.36 mmHg·sec/cm predicted over 75% area stenosis with area under curves of 0.883 and 0.828, respectively (**C**, **D**).

and h-SR were highly correlated ($r=0.741$, Fig. 2B). The numbers of run-off vessels were not associated with physiological parameters (data not shown).

A receiver operating characteristic analysis for evaluating over 75% area stenosis in the SFA lesions revealed an FFR less than 0.88 was the cut-off (Fig. 2C). In contrast, h-SR more than 0.36 was the cut-off (Fig. 2D). The area under curve was 0.883 in case of h-SR, larger than that of FFR at 0.828. The h-SR threshold, 0.36, had high enough sensitivity and specificity for significant SFA stenotic lesions (sensitivity: 0.938, specificity: 0.875, Fig. 2D). No significant differences were observed in h-SR and FFR before EVT between the patients with Rutherford categories 2 and 3.

On the other hand, VFR was not significantly correlated with the % area stenosis ($r=0.120$, $p=0.58$). A receiver operating characteristic analysis for evaluating over 75% area stenosis demonstrated that VFR was inferior to FFR and h-SR as a predictor ($p=0.025$ and $p=0.014$, respectively). VFR had little relationship with stenotic severity in the SFA.

Discussion

This study demonstrated pressure- and velocity-based physiological data in lower-limb intervention. There were extreme changes in h-SR and FFR after EVT in the focal stenotic SFA lesions. Lesion severity, measured by IVUS, was strongly associated with h-SR and FFR, but not VFR, before EVT. $h-SR > 0.36$ and $FFR < 0.88$ were cut-off values to predict over 75% area stenosis. These physiological parameters indicated structural stenosis in the SFA lesions.

Physiological flow reserve studies are very rare in lower-limb arteries compared to coronary arteries. Although the indications for therapy are not based on stenotic severity, such as % area stenosis measured by IVUS in the lower-limb field, we observed the close correlation between the stenotic severity and physiological data such as h-SR and FFR. To our knowledge, this is the first study to identify intra-arterial physiological stenosis severity analysis by pressure- and velocity-combined simultaneous assessment in the SFA lesions. A pressure/velocity, sensor-tipped guidewire can provide a physiological stenosis resistance parameter, h-SR.⁹⁾ Stenosis resistance, derived from mean intra-arterial pressure and velocity distal to the stenotic lesions, was shown to be highly reproducible in coronary circulation. The h-SR index in coronary circulation was a more powerful predictor of reversible perfusion defects than coronary flow reserve and FFR.¹⁰⁾ Several IVUS studies suggested that FFR correlated with coronary arterial stenosis severity.^{11,12)} Although we demonstrated h-SR and FFR both indicated focal stenosis severity at hyperemia before EVT in SFA lesions, h-SR was more strongly cor-

related with % area stenosis than FFR.

In coronary circulation, coronary flow reserve before the procedure indicated stenosis severity and microvascular disorder.^{3,4)} In our claudication subjects, with relatively minor microvascular disorders, VFR did not predict lesion severity before EVT. Absolute blood flow difference may be a responsible mechanism. The coronary flow reserve is around 4.0 in normal candidates; on the other hand, VFR was only around 2.0.^{8,13)} In terms of pressure study, $FFR \leq 0.92$ after EVT predicted in-stent restenosis in the SFA.⁷⁾ VFR, measured by a thermodilution method after EVT, predicted limb prognosis in critical limb ischemia patients.¹⁴⁾ It is not clear whether pressure- and velocity-based parameters predict limb prognosis, such as lesion restenosis or amputation free survival. A prospective study with a larger sample size is needed to evaluate the parameters before and after EVT as a predictor.

Study limitations

Our study has some limitations. This study has a small sample size. Too many male subjects have a potential for bias. We included only focal short stenosis lesions. The physiological study for long, diffuse SFA lesions is not clear. Velocity-based flow analysis may change in patients with microvascular disorders. Some patients showed that FFR was high (near 1.0) and h-SR was low (near 0) even before EVT, which may be related to the inclusion criteria (symptomatic disease [Rutherford category 2–3] with $\geq 70\%$ diameter stenosis on angiography) adopted in this study. We analyzed clinical data during EVT procedures and did not collect clinical follow-up data.

Conclusion

h-SR can indicate stenotic severity in an SFA focal lesion and may be a new physiological index to determine indication for endovascular treatment. FFR was a less prominent determinant for lesion severity, although VFR was not a predictor.

Disclosure Statement

All authors have no conflict of interest

Author Contributions

Study conception: KI

Data collection: YS, TM, HF

Analysis: TW, KM

Investigation: HI, KU, SI

Writing: KI, SH

Critical review and revision: all authors

Final approval of the article: all authors

Accountability for all aspects of the work: all authors

References

- 1) Pijls NHJ, de Bruyne B, Peels K, et al. Measurement of fractional flow reserve to assess the functional severity of coronary-artery stenoses. *N Engl J Med* 1996; **334**: 1703-8.
- 2) Voskuil M, van Liebergen RAM, Albertal M, et al. Coronary hemodynamics of stent implantation after suboptimal and optimal balloon angioplasty. *J Am Coll Cardiol* 2002; **39**: 1513-7.
- 3) Gould KL, Kirkeeide RL, Buchi M. Coronary flow reserve as a physiologic measure of stenosis severity. *J Am Coll Cardiol* 1990; **15**: 459-74.
- 4) Meuwissen M, Chamuleau SAJ, Siebes M, et al. Role of variability in microvascular resistance on fractional flow reserve and coronary blood flow velocity reserve in intermediate coronary lesions. *Circulation* 2001; **103**: 184-7.
- 5) Hioki H, Miyashita Y, Miura T, et al. Diagnostic value of peripheral fractional flow reserve in isolated iliac artery stenosis: a comparison with the post-exercise ankle-brachial index. *J Endovasc Ther* 2014; **21**: 625-32.
- 6) Kobayashi N, Hirano K, Nakano M, et al. Measuring procedure and maximal hyperemia in the assessment of fractional flow reserve for superficial femoral artery disease. *J Atheroscler Thromb* 2016; **23**: 56-66.
- 7) Kobayashi N, Hirano K, Yamawaki M, et al. Ability of fractional flow reserve to predict restenosis after superficial femoral artery stenting. *J Endovasc Ther* 2016; **23**: 896-902.
- 8) Ikeoka K, Hoshida S, Watanabe T, et al. Pathophysiological significance of velocity-based microvascular resistance at maximal hyperemia in peripheral artery disease. *J Atheroscler Thromb* 2018; **25**: 1128-36.
- 9) Siebes M, Verhoeff BJ, Meuwissen M, et al. Single-wire pressure and flow velocity measurement to quantify coronary stenosis hemodynamics and effects of percutaneous interventions. *Circulation* 2004; **109**: 756-62.
- 10) Meuwissen M, Siebes M, Chamuleau SAJ, et al. Hyperemic stenosis resistance index for evaluation of functional coronary lesion severity. *Circulation* 2002; **106**: 441-6.
- 11) Takagi A, Tsurumi Y, Ishii Y, et al. Clinical potential of intravascular ultrasound for physiological assessment of coronary stenosis: relationship between quantitative ultrasound tomography and pressure-derived fractional flow reserve. *Circulation* 1999; **100**: 250-5.
- 12) Briguori C, Anzuini A, Airoidi F, et al. Intravascular ultrasound criteria for the assessment of the functional significance of intermediate coronary artery stenoses and comparison with fractional flow reserve. *Am J Cardiol* 2001; **87**: 136-41.
- 13) Gould KL, Lipscomb K, Hamilton GW. Physiologic basis for assessing critical coronary stenosis. Instantaneous flow response and regional distribution during coronary hyperemia as measures of coronary flow reserve. *Am J Cardiol* 1974; **33**: 87-94.
- 14) Fukunaga M, Fujii K, Kawasaki D, et al. Vascular flow reserve immediately after infrapopliteal intervention as a predictor of wound healing in patients with foot tissue loss. *Circ Cardiovasc Interv* 2015; **8**: e002412.