

CASE REPORT

Nagoya J. Med. Sci. 82, 783–790, 2020
doi:10.18999/nagjms.82.4.783

An experience in prenatal diagnosis via QF-PCR of a female child with a 9.9 Mb pure deletion at 18p11.32–11.22

Thanh Nha Uyen Le^{1,2}, Viet Nhan Nguyen^{1,2}, Thi Duyen Anh Doan^{1,2}, Huu Nhat Binh Doan², Phan Tuong Quynh Le^{1,2}, Tuan Linh Le^{1,2} and Thi Minh Thi Ha^{1,2}

¹Department of Medical Genetics, Hue University of Medicine and Pharmacy, Hue University, Hue, Vietnam
²Center of Prenatal and Neonatal Screening-Diagnosis, Hospital of Hue University of Medicine and Pharmacy, Hue University, Hue, Vietnam

ABSTRACT

Quantitative Fluorescent – Polymerase Chain Reaction (QF-PCR) is a rapid prenatal diagnosis test for 21, 18, 13 and sex chromosomal aneuploidy detection. However, it could not detect partial trisomy or partial monosomy of those chromosomes. Here, we report a 19-month-old Vietnamese female with a 9.9 Mb pure deletion of chromosome 18 at 18p11.32–11.22 confirmed by next generation sequencing. The patient was short statured with facial dysmorphic features as well as motor skill and speech delays. First trimester screening showed high risk of trisomy 21 with only increased nuchal translucency (NT 3.9 mm) by ultrasound as an indication. Prenatal diagnosis by QF-PCR from amniotic DNA revealed normal disomy. Noticeably, two short tandem repeat (STR) markers D18S391 and D18S976 located on 18p exhibited uninformative patterns (one peak). Thus, our case suggested that the combination of both D18S391 and D18S976 markers with uninformative patterns in QF-PCR for prenatal diagnosis and increased NT in the first trimester ultrasound may be a significant indication of 18p monosomy.

Keywords: 18p monosomy, QF-PCR, increased nuchal translucency, D18S391, D18S976

Abbreviations:

AF: amniotic fluid

NGS: next generation sequencing

NT: nuchal translucency

QF-PCR: Quantitative Fluorescent – Polymerase Chain Reaction

STR: short tandem repeat

This is an Open Access article distributed under the Creative Commons Attribution-NonCommercial-NoDerivatives 4.0 International License. To view the details of this license, please visit (<http://creativecommons.org/licenses/by-nc-nd/4.0/>).

INTRODUCTION

18p deletion (18p-) syndrome, also known as monosomy 18p or de Grouchy syndrome, is a rare chromosomal aberration caused by partial or complete deletion of the short arm of chromosome 18. The incidence of this disorder is estimated to affect approximately 1 in 50000 live

Received: October 30, 2019; accepted: March 19, 2020

Corresponding Author: Thi Minh Thi Ha, MD, PhD

Department of Medical Genetics, Hue University of Medicine and Pharmacy, Hue University, 6 Ngo Quyen street, Hue, 49000, Vietnam

Tel: +84-914046350, E-mail address: htmthi@huemed-univ.edu.vn, htmthi@hueuni.edu.vn

births, with a female to male ratio of 3:2. It was first described in 1963 and since then, more than 150 cases have been documented globally.¹⁻³

The phenotypic manifestations of 18p- syndrome vary greatly from among patients depending on the deletion size and breakpoints involved.^{4,5} The most common features include mental retardation with variable severity, short stature, craniofacial dysmorphism as well as speech and cognitive delays. Other clinical symptoms less frequently consist of behavioral disorders, cardiac malformations, dystonia, growth hormone deficiency and autoimmune diseases.^{1,6,7} Concerning mental retardation, Sebold et al² reported that the average full scale IQ was 69 with a range from 51 to 99. Most of the affected cases are fertile and normal in puberty.^{1,8}

A majority of 18p- cases are supposed to originate from *de novo* deletions, whereas the remainder is suspected to come from unbalanced chromosomal abnormalities involving chromosome 18 or imbalanced familial transmission of structural rearrangements.^{1,6,8,9} Notably, a great number of 18p- cases were diagnosed at elder children or adults while the prenatal detection rate of those cases has been limited due to the nonspecific indications by ultrasound, except for the severe malformations pertaining to the holoprosencephaly spectrum which has an incidence rate of approximately 10%.^{7,8,10-12} Here, we report a Vietnamese girl with a 9.9 Mb pure deletion at 18p11.32–11.22, who only presented the increased nuchal translucency (3.9 mm) in the first trimester screening and whose prenatal diagnosis by QF-PCR (Quantitative Fluorescence – Polymerase Chain Reaction) did not detect 21, 18, 13 and sex chromosomal aneuploidy.

CASE REPORT

The proband is a 19-month-old daughter of a non-consanguineous couple. She was born full-term by Caesarean section without complications from her mother's second gravida. The first trimester screening revealed high risk of trisomy 21, with a nuchal translucency (NT) of 3.9 mm. However, the prenatal diagnosis by QF-PCR from amniotic cells excluded trisomy 21, 18, 13 and sex chromosomal aneuploidy. Her birthweight was 3000g. She was referred to our department because of short stature, motor skill and speech delays. In her mother's first gravida, increased NT (4.2 mm) was also detected in the fetus and the pregnancy ended in a stillbirth.

Clinical examination showed that her height (70 cm), weight (8500 g) and head circumference (45 cm) were below the 3rd percentile, between the 15th and 3rd percentile, at the 15th percentile, respectively. Her face features were as follows: rectangular in shape with hypertelorism, a low and flat nose and large, protruding ears. Her mouth was large with a prominent philtrum and a Cupid's bow shaped upper lip (carp-shaped mouth) (Fig. 1A-1B). Her neck was short. She did not experience crawling and was able to sit at around 8 months of age. She could neither stand, walk nor speak, and she presented a mild muscular hypotonia in both lower limbs. She knew to express her emotions, demands and interests using body language. No other malformations were identified.

Blood tests revealed the normal range of thyroid stimulating hormone, cortisol, free thyroxine, and growth hormone. A cardiac ultrasound indicated no abnormalities.

The karyotype of the patient determined a partial short arm deletion of chromosome 18 (Fig. 2A), while her parents have normal karyotypes. Further analysis by NGS confirmed a 9.9 Mb pure deletion at 18p11.32–18p11.22 (chr18: 618,247–10,597,239) (Fig. 2B). Tracing back to the prenatal diagnosis by QF-PCR, we noticed that the two STR markers D18S391 and D18S976 located on 18p were both uninformative. D18S391 presented a peak height/area which was almost the same as that of the next informative heterozygous STR marker whereas

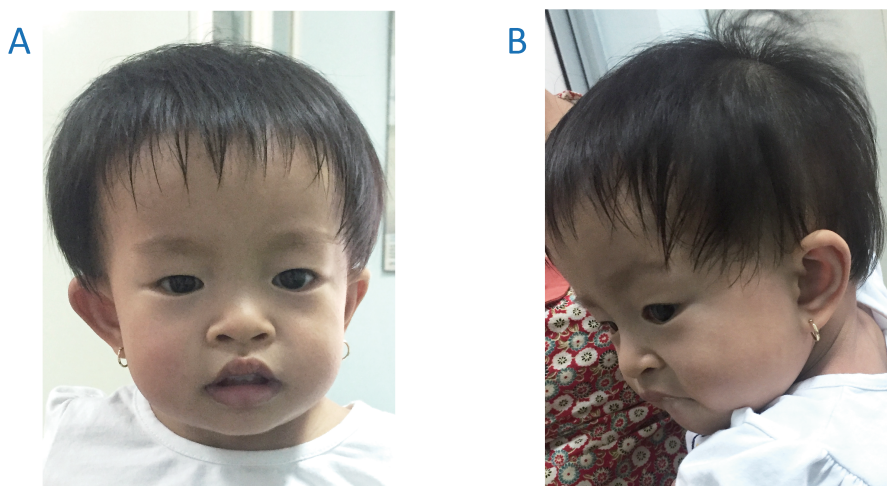

Fig. 1 Facial dysmorphic features of the patient

Fig. 1A-B: The patient presented with rectangular face, hypertelorism, low and flat nose. The mouth was large with a prominent philtrum and a cupid's bow shaped upper lip (carp-shaped mouth), large, protruding ears and short neck.

D18S976 peak height/area appeared to be half of the previous homozygous STR marker on the electropherograms (Fig. 3).

DISCUSSION

The karyotype of the patient indicated a partial short arm deletion of chromosome 18 (Fig. 2A), while her parents have normal karyotypes. This girl's manifestations were in accordance with the very frequent phenotype of most of the previously reported 18p- cases such as speech delay and short stature; and frequent features including a rectangular face, flat nasal bridge, carp-shaped mouth, large and protruding ears, and a short neck.^{1,8} She had mild mental retardation with motor skill and speech delay which is also frequently observed in 18p- syndrome,^{5,8} however she knew to express her emotions, demands and interests using body language. According to Wester et al,¹³ the critical region responsible for mental retardation was between 18p11.1 and 18p 11.21. This might explain the mild intellectual disability in our case as the loss material was from 18p11.22. Moreover, Sebold et al² reported that the average IQ score of subjects with 18p- syndromes was 69 and ranged from 51 to 99. Thus, the cognitive impairment typically falls into the mild to borderline range.

The breakpoint was at 18p11.32–18p11.22 and resulted in a 9.9 Mb pure deletion as determined by NGS (Fig. 2B). According to Schaub et al,¹⁴ approximately half of cases have breakpoints located in the pericentromeric region and the remainders are scattered along the entirety of the short arm. Interestingly, there have been no reports of large interstitial deletion of 18p, although some microdeletions were reported by Myers et al.¹⁵ Our presented case was noticeable with a 9.9 Mb interstitial deletion at 18p11.32–18p11.22. Although the lost genetic material was rather large consisting of many important dosage-sensitive genes,⁹ the manifestations of our case were less severe than would be expected. Our patient has no features of holoprosencephaly spectrum, seizure, autoimmune disease, behavioral disorder or growth hormone deficiency which were




Fig. 2 Results of genetic diagnosis of 18p deletion

Experience from a case with monosomy 18p

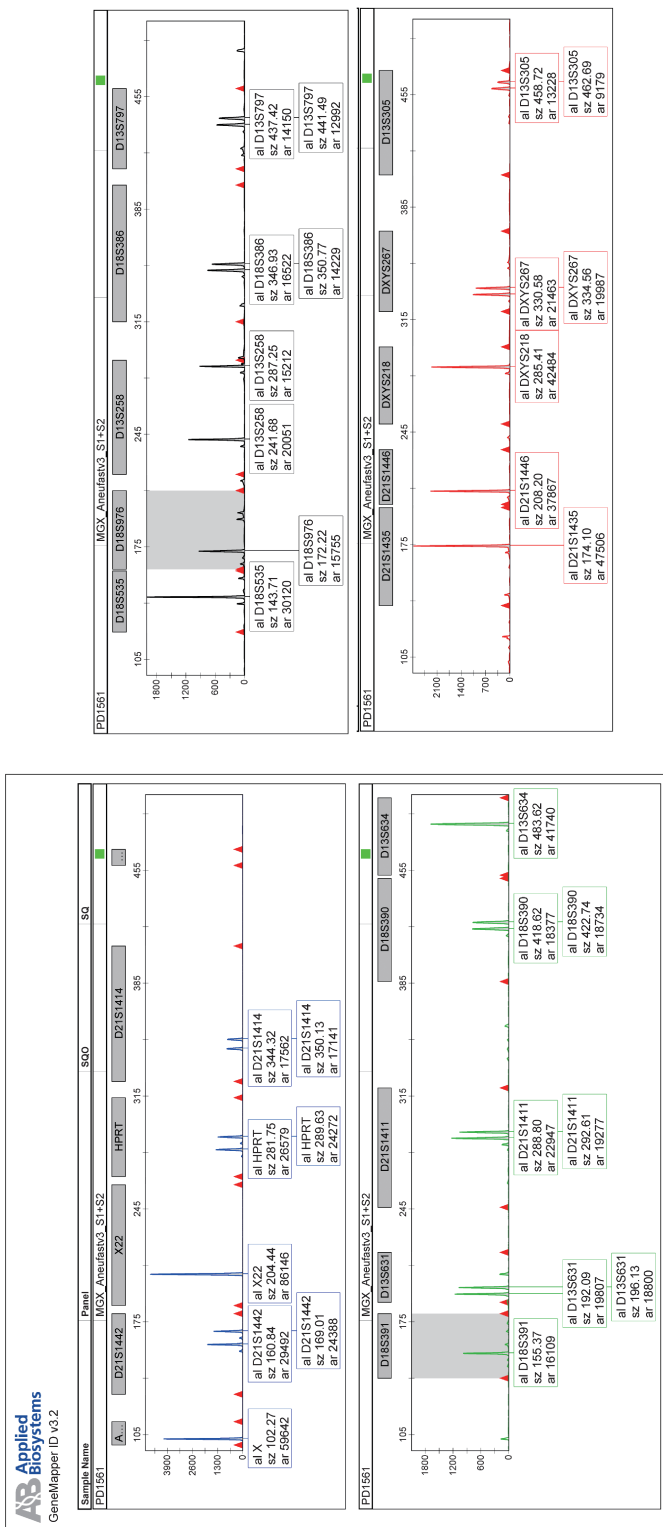


Fig. 3 Results of QF-PCR analysis of standard reaction (S1 and S2 set) from amniotic DNA. The two markers D18S391 and D18S976 located on 18p revealed uninformative patterns (highlighted by grey area). The three other markers located on 18q include D18S390, D18S386 (heterozygote peaks with 1:1 ratio) and D18S535 (uninformative peaks).

reported as rare features in 18p- syndromes. A similar case reported by Sun et al¹⁶ had a 15.3 Mb deletion of 18p but also had a less severe phenotype compared to other reported cases with smaller size of deletion.^{16,17} This indicates the variability of this syndrome. Brenk et al⁴ proposed a phenotypic map for 18p monosomy syndrome based on the manifestations of their patients and other reported cases. However, those critical regions were rather large and have not been refined since their initial identification. In addition, the exact causative dosage-sensitive gene has yet to be determined.⁹

There were a number of factors which might contribute to the variability of this syndrome including age-related symptoms, inhomogeneous clinical classification, incomplete penetrance of the trait, undetected mosaicism, and the uncovering of a recessive trait by the deletion.^{4,5} In a report by Hasi-Zogaj et al,⁹ the average age of onset seizure was 11 years old. A critical region for holoprosencephaly, HPE4, has been defined to be the most distal segment of 18p. However, the hemizygosity of HPE4 does not always confer the phenotype of holoprosencephaly as it presents in approximately 10–15% of 18p- patients with variable spectrum, from the severe malformations such as cyplopia, cebocephaly, premaxillary agenesis to the mild forms such as agenesis of corpus callosum, hypopituitarism, and minor facial feature with/without brain malformation.¹ This suggests the involvement of other multiple genetic and environmental factors. Our patient was diagnosed at 19-month-old, much younger than the majority of previously reported 18p monosomic cases. As there were some symptoms that were age-related development, the long-term follow up with our case is necessary.

The QF-PCR analysis of the fetal DNA extracted from AF showed disomy patterns for chromosome 13, 18 and 21. Five investigated STR markers of chromosome 18 were D18S391, D18S976, D18S535, D18S386, and D18S390, in which only D18S391 and D18S976 markers located on the short arm of chromosome 18 (18p11.2 and 18p11.31, respectively). Remarkably, both D18S391 and D18S976 markers illustrated uninformative peaks while the two markers D18S386, and D18S390 exhibited clear heterozygous patterns within the normal range (Fig. 3). Thus, normal disomy for chromosome 18 was reported. Among the eight STR markers linked to chromosome 18 including five for standard reactions (S1 and S2 set) and three for back-up reaction (M18) provided in Aneufast QF-PCR Rapid detection 21, 18, 13, X and Y Aneuploidies kit, only two markers D18S391 and D18S976 represented the short arm chromosome 18. Moreover, the peak height/peak area of D18S391 was almost equivalent to the peak height/peak area of the neighbor marker D13S631 (heterozygous peaks) which might suggest equal DNA dosages at these loci. A similar pattern was seen for D18S976 as compared with the neighbor marker D13S258 (heterozygous peaks) while its height/area was almost half of D18S535 (homozygous). Unfortunately, these monosomic indications were missed as uninformative peaks in prenatal diagnosis for the patient.

This is the first case we have detected among more than 3300 cases of prenatal diagnosis by QF-PCR in our laboratory since 2011. QF-PCR is a rapid aneuploidy test for prenatal diagnosis. It is not designed for the diagnosis of structural chromosome abnormalities and monosomy, but monosomy X. Therefore, QF-PCR may overlook structural chromosomal abnormalities. Among 163 samples blindly tested by QF-PCR for aneuploidy of chromosome 13, 18, 21 and conventional karyotyping, Moftah et al¹⁸ detected two cases with monosomy 18p by conventional karyotyping, and both cases were considered normal by QF-PCR analysis. Nevertheless, from our case, it is important to analyze the peak height/peak area of one or more QF-PCR STR markers with trisomic biallelic or homozygous patterns which might be useful indications for either partial trisomy or partial monosomy. By doing this, we could not only minimize the number of misdiagnosed cases but also detect affected subjects early during the prenatal period. Inkster et al¹⁹ confirmed a triplication within chromosome Xq26.2 by chromosome microarray

analysis, after detection of a trisomic biallelic pattern of DX1187 marker by QF-PCR. Badenas et al²⁰ detected a case with monosomy 18p by QF-PCR and karyotyping, however the author did not show markers with monosomic pattern in the report.

It is essential to highlight in our case that the ultrasound examination showed only the increased NT (3.9 mm) at the first trimester screening. The case with 18p monosomy in Badenas's²⁰ report also had an increased NT. Yakut et al¹¹ highlighted an association between increased NT and monosomy 18p. As mentioned above, the monosomy 18p phenotype was atypical and the majority of patients with this syndrome were often diagnosed as children or adults. Therefore, prenatal screening by ultrasound might not detect any abnormal signs, except for solely increased NT. Although prenatal diagnose by QF-PCR could detect some cases based on the observed patterns of both the peak number and the peak height/ area, QF-PCR could suggest rather than diagnose either partial trisomy or partial monosomy due to other possible factors which may affect QF-PCR results such as PCR efficiency, SNP at primer binding site. Therefore, further analysis by NGS or microarray to confirm the diagnosis is necessary for those doubted cases.

In conclusion, we report herein a patient with a 9.9 Mb pure deletion at 18p11.32–11.22. Our case suggested that the combination of both D18S391 and D18S976 markers with uninformative patterns in a QF-PCR assay for prenatal diagnosis and increased NT in the first trimester ultrasound may be an indication of monosomy 18p.

PATIENT CONSENT

Written informed consent was obtained from the patient's parents for the publication of this case report.

ACKNOWLEDGMENTS

We thank Gentis JSC, Vietnam, for assisting us in performing NGS analysis.

CONFLICT OF INTEREST

The authors have no conflicts of interest to declare.

REFERENCES

1. Turleau C. Monosomy 18p. *Orphanet J Rare Dis.* 2008;3(1):4.
2. Sebold C, Soileau B, Heard P, et al. Whole arm deletions of 18p: medical and developmental effects. *Am J Med Genet A.* 2015;167A(2):313–323.
3. Xu L-j, Wu L-x, Yuan Q, Lv Z-g, Jiang X-y. A case of 18p deletion syndrome after blepharoplasty. *Int Med Case Rep J.* 2017;10:15–18.
4. Brenk CH, Prott E-C, Trost D, et al. Towards mapping phenotypical traits in 18p- syndrome by array-based comparative genomic hybridisation and fluorescent in situ hybridisation. *Eur J Hum Genet.* 2007;15(1):35–44.
5. Goyal M, Jain M, Singhal S, Nandimath K. 18p deletion syndrome: Case report with clinical consideration and management. *Contemp Clin Dent.* 2017;8(4):632–636.
6. Kasasbeh FA, Shawabkeh MM, Hawamdeh AA. Deletion of 18p syndrome. *Lab Med.* 2011;42(7):436–438.
7. Tekeli H, Kendirli MT, Şenol MG, et al. A case with 18p deletion and dystonia and review of the literature. *Neurol Asia.* 2015;20(3):287–290.
8. Maranda B, Lemieux N, Lemyre E. Familial deletion 18p syndrome: case report. *BMC Med Genet.*

- 2006;7(1):60.
9. Hasi-Zogaj M, Sebold C, Heard P, et al. A review of 18p deletions. *Am J Med Genet C Semin Med Genet.* 2015;169(3):251–264.
 10. Lurie I, Lazjuk G. Partial monosomies 18. *Humangenetik.* 1972;15(3):203–222.
 11. Yakut S, Simsek M, Pestereli H, Baumer A, Luleci G, Schinzel A. Del (18p) syndrome with increased nuchal translucency revealed in prenatal diagnosis. *Genet Couns.* 2011;22(3):317–319.
 12. Yi Z, Yingjun X, Yongzhen C, Liangying Z, Meijiao S, Baojiang C. Prenatal diagnosis of pure partial monosomy 18p associated with holoprosencephaly and congenital heart defects. *Gene.* 2014;533(2):565–569.
 13. Wester U, Bondeson ML, Edeby C, Annerén G. Clinical and molecular characterization of individuals with 18p deletion: a genotype–phenotype correlation. *Am J Med Genet A.* 2006;140(11):1164–1171.
 14. Schaub RL, Reveles XT, Baillargeon J, Leach RJ, Cody JD. Molecular characterization of 18p deletions: evidence for a breakpoint cluster. *Genet Med.* 2002;4(1):15–19.
 15. Myers KA, Warman Chardon J, Huang L, Boycott KM. Deletion of AFG3L2 associated with spinocerebellar ataxia type 28 in the context of multiple genomic anomalies. *Am J Med Genet A.* 2014;164A(12):3209–3212.
 16. Sun H, Wan N, Wang X, Chang L, Cheng D. Genotype-phenotype analysis, neuropsychological assessment, and growth hormone response in a patient with 18p deletion syndrome. *Cytogenet Genome Res.* 2018;154(2):71–78.
 17. Verrotti A, Palka C, Prezioso G, et al. Deletion 18p11. 32p11. 31 in a child with global developmental delay and atypical, drug-resistant absence seizures. *Cytogenet Genome Res.* 2015;146(2):115–119.
 18. Moftah R, Marzouk S, El-Kaffash D, et al. QF-PCR as a molecular-based method for autosomal aneuploidies detection. *ARSci.* 2013;1(3):21–28.
 19. Inkster A, Thomas MA, Gamache NS, et al. A Challenging Prenatal QF-PCR Rapid Aneuploidy Test Result Caused by a Maternally Inherited Triplication within Chromosome Xq26. 2. *Cytogenet Genome Res.* 2018;156(1):5–8.
 20. Badenas C, Rodríguez-Revenga L, Morales C, et al. Assessment of QF-PCR as the first approach in prenatal diagnosis. *J Mol Diagn.* 2010;12(6):828–834.