

Original Article

Superficial cortical landmarks for localization of the hippocampus: Application for temporal lobectomy and amygdalohippocampectomy

R. Shane Tubbs^{1,2,3}, Marios Loukas², Nicholas M. Barbaro⁴, Aaron A. Cohen-Gadol⁴

¹Pediatric Neurosurgery, Children's Hospital of Alabama, Birmingham, Alabama, ⁴Goodman Campbell Brain and Spine, Department of Neurological Surgery, Indiana University School of Medicine, Indianapolis, Indiana, USA, ²Department of Anatomic Sciences, St. George's University School of Medicine, St. George's, Grenada, ³Centre of Anatomy and Human Identification, University of Dundee, Scotland, UK

E-mail: R. Shane Tubbs - Shane.Tubbs@childrensal.org; Marios Loukas - mloukas@sgu.edu; Nicholas M. Barbaro - nbarbaro@goodmancampbell.com;*Aaron Cohen-Gadol - acohenmd@gmail.com

*Corresponding author

Received: 08 October 14 Accepted: 18 November 14 Published: 03 February 15

This article may be cited as:Tubbs RS, Loukas M, Barbaro NM, Cohen-Gadol AA. Superficial cortical landmarks for localization of the hippocampus: Application for temporal lobectomy and amygdalohippocampectomy. *Surg Neurol Int* 2015;6:16.Available FREE in open access from: <http://www.surgicalneurologyint.com/text.asp?2015/6/1/16/150663>

Copyright: © 2015 Tubbs RS. This is an open-access article distributed under the terms of the Creative Commons Attribution License, which permits unrestricted use, distribution, and reproduction in any medium, provided the original author and source are credited.

Abstract

Background: Accessing the hippocampus for amygdalohippocampectomy and procedures such as depth electrode placement requires accurate knowledge regarding the location of the hippocampus.

Methods: The authors removed 10 human cadaveric brains (20 sides) from their crania, noted relationships between the lateral temporal neocortex and underlying hippocampus, and measured the distance between the hippocampus and superficial landmarks.

Results: Mean distances were as follows: 3.8 cm from the tip of the temporal lobe to the head of the hippocampus; 6.5 cm from the tip of the temporal lobe to the junction of the fornix and hippocampus; and 3.5 cm between the tail and head of the hippocampus. The head of the hippocampus ranged from 0 to 5 mm inferior to the inferior temporal sulcus. The tail of the hippocampus ranged from 2.2 to 7 mm superior to the inferior temporal sulcus. In two specimens, the tail was deep to the superior temporal sulcus. Generally the length of the hippocampus was along the inferior temporal sulcus and inferior aspect of the middle temporal gyrus. The hippocampus tended to be more superiorly located and shorter in females and left sides, but this was not statistically significant.

Conclusions: Additional landmarks for localizing the underlying hippocampus may be helpful in temporal lobe surgery. Our study showed relatively constant anatomic landmarks between the hippocampus and overlying temporal cortex that may help localize the hippocampus during amygdalohippocampectomy and depth electrode implantation, verify the accuracy of image-guided methods, and used as adjunct methodologies when these latter technologies are unavailable.

Key Words: Anatomy, epilepsy surgery, hippocampectomy, landmarks, neurosurgery, temporal lobe

**Access this article
online****Website:**www.surgicalneurologyint.com**DOI:**

10.4103/2152-7806.150663

Quick Response Code:

INTRODUCTION

Even with advancements in pharmacologic treatment of epilepsy, there is still a group of patients whose seizures have a higher tendency to be refractory to medical therapy. Medial temporal lobe epilepsy often is caused by medial temporal lobe sclerosis or lesional epileptogenic foci within the amygdala and hippocampal formation. The hippocampus and surrounding formation are made up of the cornu ammonis (hippocampus proper), subiculum, dentate gyrus, supracallosal gyrus, alveus, fimbria, and fornix.^[4] Traditionally attributed to the formation and storage of memory, manipulation of the dominant hippocampal formation may result in cognitive and memory dysfunction after surgery.^[5-7]

Anterior temporal lobectomy with amygdalohippocamectomy has proven efficacious for cessation of intractable seizures of medial temporal lobe origin. Aggressive resection of these medial temporal lobe structures has been associated with improved surgical outcomes.^[10] In this study, we attempted to study more precise superficial anatomic landmarks to guide the surgeon to the deeper lying hippocampus [Figure 1]. Such landmarks can be used to refine or verify the accuracy of intraoperative image-guidance and especially when such navigation is not used or is unavailable.

MATERIALS AND METHODS

Ten formalin-fixed cadaveric brains (20 sides) were removed from the crania. The specimens were derived from six male and four female cadavers, aged 35–75 years (mean 65 years) at death. Brains were next hemisected in the midline and the fornix identified and followed toward the left and right hippocampus. Once the hippocampus was isolated from a mesial approach, 6-cm long straight needles were placed into its head, tail,

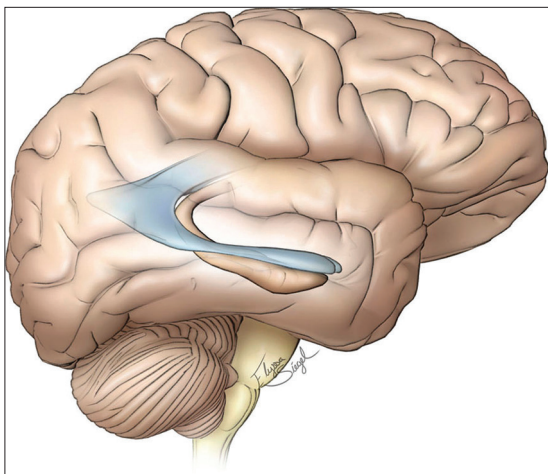


Figure 1: The relationship of right hippocampus and temporal horn to the superficial structures. © *The Neurosurgical Atlas*, by Aaron A. Cohen-Gadol, MD, MSc, used with permission

and the midpoint between these structures, and passed laterally perpendicular to the cortical surface and until they reached the cortical surface. The specimens were turned over and the pin exit sites marked externally with smaller pins [Figures 2 and 3]. The pia and arachnoid mater had been previously removed to better visualize the cortical surface. Measurements between the outer temporal lobe cortical landmarks (sulci and gyri) and the underlying hippocampus (both its head and tail) were then made with digital calipers (Mitutoyo, Japan). Axial sections through the overlying cortex were made with the hippocampus intact to verify the overlying relationships [Figure 4]. Statistical analysis between sides and gender were made using Statistica 12 (Tulsa, OK) with statistical significance set at $P < 0.05$.

RESULTS

We did not note any gross intracranial pathology or evidence of previous surgery in any specimen. The distance from the tip of the temporal lobe to the “head” of the hippocampus ranged from 3.5 to 4.3 cm (mean 3.8 cm) [Figures 2,3,5, and 6]. The distance from the tip of the temporal lobe to the junction of the fornix with the hippocampus ranged from 6 to 6.7 cm (mean 6.5 cm) [Figures 2,3,5, and 6]. The distance between the tail and head of the hippocampus ranged from 3 to 4.1 cm (mean 3.5 cm) [Figures 5 and 6]. The head of the hippocampus ranged from 0 to 5 mm inferior to the inferior temporal sulcus. The tail of the hippocampus ranged from 2.2 to 7 mm superior to the inferior temporal sulcus.

In two right-sided specimens, the tail was deep to the superior temporal sulcus [Figure 6]. In general, the length of the hippocampus was along the inferior temporal sulcus and inferior aspect of the middle temporal gyrus. From anterior to posterior, the hippocampus always sloped upward. No statistical difference for these measurements was noted between left and right sides.

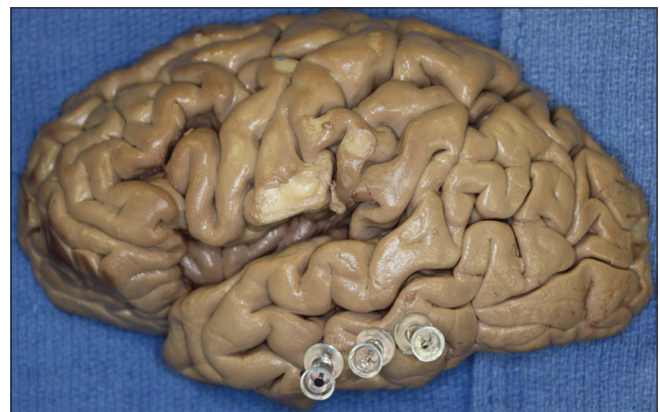


Figure 2: Left hemisphere with pins noting the anterior, middle, and posterior parts of the hippocampus

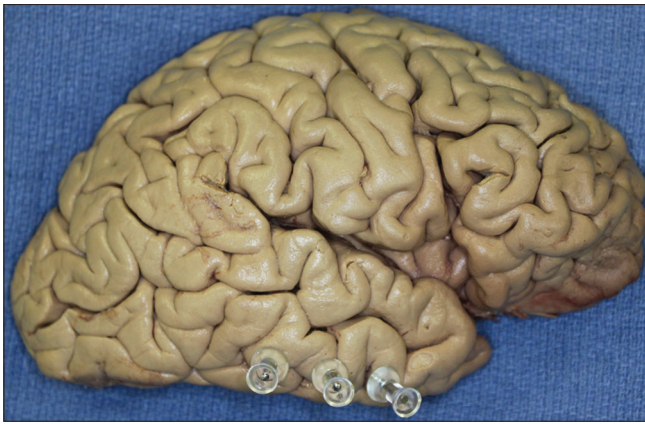

Figure 3: Right hemisphere with pins noting the anterior, middle, and posterior parts of the hippocampus

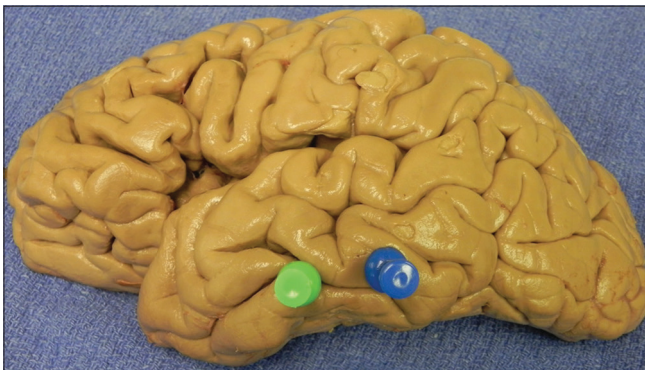


Figure 5: Left hemisphere with pins marking the head and tail of the hippocampus. Here, the head (anterior pin) is seen at the level of the inferior temporal sulcus and the tail (posterior pin) is seen at the level of the lower part of the middle temporal gyrus

Although the hippocampus tended to be more superiorly located in female specimens and on left sides, this did not reach statistical significance. Also, the length of the hippocampus tended to be shorter in females, but this too failed to reach statistical significance.

DISCUSSION

Localization of the hippocampus in relation to superficial structures is important for exposure of the hippocampus during anteromedial temporal lobectomy and amygdalohippocampectomy procedures while minimizing the extent of neocortical resection, especially on the dominant hemisphere. Furthermore, intraoperative depth electrodes placed within the hippocampus can provide useful information regarding the relative epileptogenicity of this medial structure versus the temporal neocortex. Therefore, it is important to localize the hippocampus as accurately as possible using all the available data, including image guidance and surface landmarks. In our study, we found that the inferior temporal sulcus and middle temporal gyrus were relatively constant landmarks to the underlying hippocampus. Additionally, and within

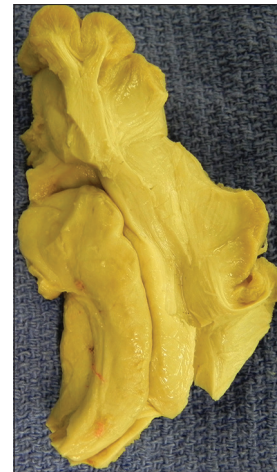


Figure 4: Axial section through the right temporal lobe for verification of outer cortical landmarks to internally positioned hippocampus

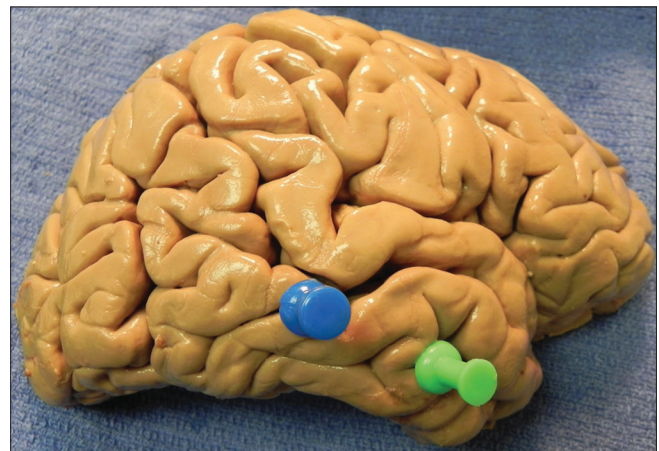


Figure 6: Right hemisphere with pins marking the head and tail of the hippocampus. In this specimen, the head (anterior pin) of the hippocampus is deep to the inferior temporal sulcus. However, the tail (posterior pin) is located in the superior temporal sulcus

a centimeter more or less, the length of the hippocampus was similar in length between sides and genders.

Surgical anatomy

The hippocampus sits in the medial part of the temporal lobe and on the floor of the temporal horn of the lateral ventricle. The amygdala is situated anterior and superior to the head of hippocampus. The uncus, which is part of the entorhinal cortex, wraps around the inferior border of the hippocampus and appears as a continuous homogeneous ovoid mass with the amygdala on magnetic resonance imaging (MRI).^[2,5] The hippocampal head, or pes hippocampus, emerges from the temporal horn of the lateral ventricle and can be recognized from the body by its 'digitationes hippocampi.' The head is usually 1.5–2 cm wide^[9] and tapers into the hippocampal body, becoming roughly 1 cm in width on average.^[1] The body of the hippocampus is further subdivided into intraventricular

and extraventricular parts. The intraventricular part is the floor of the temporal horn. Its convex shape is smooth compared to the head with its digitations. The medial and lateral borders of the intraventricular part are the fimbria and narrow collateral eminence, respectively.

Applications for selective amygdalohippocampectomy and depth electrode placement

The data presented about the localization of the “head” of the hippocampus 3–4 cm from the anterior temporal tip may have important implications regarding the extent of temporal neocortical resection necessary to perform an amygdalohippocampectomy. If a localized lesion is present along this anterior region, further neocortical resection will not be necessary. However, if an extensive hippocampectomy for medial temporal lobe sclerosis is contemplated, disconnection of the occipitotemporal fasciculus along the lateral aspect of the hippocampus will allow lateral mobilization the temporal cortex (instead of its resection), to provide enough exposure to allow for a posterior hippocampectomy [Figure 7]. Furthermore, based on these data, resection of the superior temporal gyrus is not necessary for exposure of the ventricle. Finally, a corticotomy within the middle temporal gyrus, along the mid portion of the temporal lobe, will expose the ventricle [Figure 7]. It should be noted that the measurements taken in these specimens were not from individuals with known temporal lobe pathology or epilepsy syndromes. In mesial temporal sclerosis, the most common pathologic finding in temporal lobe epilepsy, the hippocampus is slightly smaller in diameter than in normal patients. This change may not

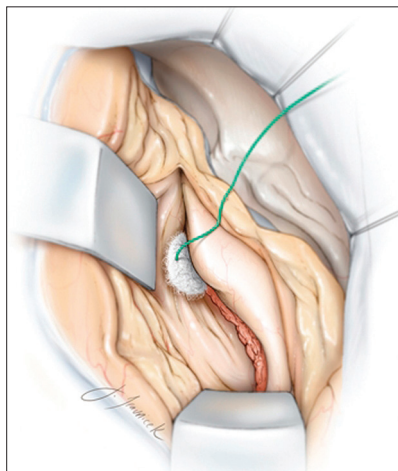


Figure 7: Disconnection of the occipitotemporal fasciculus along the lateral aspect of the hippocampus will allow lateral mobilization the temporal cortex (instead of its resection), to provide enough exposure to allow for a posterior hippocampectomy. A corticotomy within the middle temporal gyrus, along the mid portion of the temporal lobe, will expose the ventricle. © The Neurosurgical Atlas, by Aaron A. Cohen-Gadol, MD, MSc, used with permission

significantly affect the anteroposterior measurements presented here.

In a study by Davies *et al.*,^[3] electrodes were placed into the hippocampus within the middle temporal gyrus at a depth of 3.5 cm. Therefore, the surgeon may use the freehand technique to insert depth electrodes at a distance of 3–4 cm from the temporal tip, through and perpendicular to the inferior temporal gyrus, to reach the anterior hippocampus. A second electrode may be placed 6–7 cm posteriorly to evaluate the electrical activity in the posterior hippocampus. Placement of the electrodes through the middle temporal gyrus as previously advised^[8] may insert the electrodes within the ventricle and avoid accurate recording from the medial structures.

CONCLUSIONS

We performed the above cadaveric study to better identify the relationships between the outer temporal cortex and the deeper lying hippocampus. Such landmarks may be useful to neurosurgeons in localizing the hippocampus in conjunction with or to verify imaged-guided technologies or when these devices are not used or are unavailable.

ACKNOWLEDGMENTS

The authors received no funding for this study and have no conflicts of interest in regard to this study and manuscript.

REFERENCES

1. Ayberk G, Yagli OE, Comert A, Esmer AF, Canturk N, Tekdemir I, *et al.* Anatomic relationship between the anterior sylvian point and the pars triangularis. *Clin Anat* 2012;25:429-36.
2. Bronen RA, Cheung G. Relationship of hippocampus and amygdala to coronal MRI landmarks. *Magn Reson Imaging* 1991;9:449-57.
3. Davies KG, Phillips BL, Hermann BP. MRI confirmation of accuracy of freehand placement of mesial temporal lobe depth electrodes in the investigation of intractable epilepsy. *Br J Neurosurg* 1996;10:175-8.
4. Duvernoy HM. *The Human Hippocampus*. Berlin, Heidelberg, New York: Springer-Verlag; 2005.
5. Naidich TP, Daniels DL, Haughton VM, Williams A, Pojunas K, Palacios E. Hippocampal formation and related structures of the limbic lobe: Anatomic-MR correlation. Part I. Surface features and coronal sections. *Radiology* 1987;162:747-54.
6. Siadat MR, Soltanian-Zadeh H, Elisevich KV. Knowledge-based localization of hippocampus in human brain MRI. *Comput Biol Med* 2007;37:1342-60.
7. Sindou M, Guenet M. Surgical anatomy of the temporal lobe for epilepsy surgery. *Adv Tech Stand Neurosurg* 2003;28:315-43.
8. Van Gompel JJ, Meyer FB, Marsh WR, Lee KH, Worrell GA. Stereotactic electroencephalography with temporal grid and mesial temporal depth electrode coverage: Does technique of depth electrode placement affect outcome? *J Neurosurg* 2010;113:32-8.
9. Wen HT, Rhoton AL Jr, de Oliverira E, Cardoso AC, Tedeschi H, Baccanelli M, *et al.* Microsurgical anatomy of the temporal lobe: Part I: Mesial temporal lobe anatomy and its vascular relationships as applied to amygdalohippocampectomy. *Neurosurgery* 1999;45:549-92.
10. Wyler AR, Hermann BP, Somes G. Extent of medial temporal resection on outcome from anterior temporal lobectomy: A randomized prospective study. *Neurosurgery* 1995;37:982-90.