

CASE REPORT

Follicular dendritic cell sarcoma treated with a variety of chemotherapy

Masaaki Sasaki¹ | Hiroaki Izumi³ | Takaaki Yokoyama¹ | Motohiro Kojima² | Ako Hosono¹

¹Division of Breast and Medical Oncology, National Cancer Center Hospital East, Chiba, Japan

²Division of Pathology, National Cancer Center Hospital East, Chiba, Japan

³Division of Psychosomatic medicine, Kinki University Hospital, Osaka, Japan

Correspondence

Masaaki Sasaki, Breast and Medical Oncology, National Cancer Center Hospital East, 6-5-1, Kashiwanoha, Kashiwa-shi, Chiba, Japan.
Email: massasak@east.ncc.go.jp

Abstract

Follicular dendritic cell sarcoma (FDSC) is a very rare malignant tumor derived from follicular dendritic cells. Radical resection is the standard therapy for patients with local disease, but an optimal chemotherapy regimen has not been determined for unresectable disease. We report our experience of an FDSC patient with multiorgan involvement. In the present case, disease was only located in the pancreas initially and radical resection was performed. Multiple metastasis developed after the treatment and several factors that indicated a poor prognosis were observed. The present case had a very poor prognostic disease but survived for a long time with a good performance status because of the multiple chemotherapy regimens, which follow therapeutic strategies for malignant lymphoma and soft tissue sarcoma. As far as we know, this is the first study reporting the indication of bendamustine for FDSC patients.

KEYWORDS

bendamustine, chemotherapy, follicular dendritic cell sarcoma

1 | INTRODUCTION

Dendritic cells are immune cells involved in antigen presentation and endocytosis and are classified as T-cell-associated dendritic cells and B-cell-associated dendritic cells. Follicular dendritic cells are B-cell-associated dendritic cells present in lymph follicles. Follicular dendritic cells are mesenchymal in origin, and although they play a role in the maintenance of the lymph follicle environment and the activation of B cells in lymph follicles, they have no antigen presenting or endocytosis functions unlike other dendritic cells.

Follicular dendritic cell sarcoma (FDSC) is a very rare malignant tumor derived from follicular dendritic cells. It is not always easy to make the distinction because of histological similarities with non-Hodgkin lymphoma, sarcoma, melanoma, undifferentiated carcinomas, and other dendritic and histiocytic cell disease. The diagnosis is based on morphology and immunohistochemical assay. Morphology is characterized by spindle to ovoid cells forming fascicles, whorls, diffuse sheets, or nodules. Lymphoplasmacytic infiltration is frequently present in tumor tissue. Tumor cells typically express markers of follicular dendritic cell differentiation, including CD21, CD23, and CD35. Clusterin, fascin, and podoplanin are additional markers that are uniformly

positive.¹⁻⁴ Radical resection is the standard therapy for patients with local disease, and adjuvant radiotherapy did not have a significant influence on survival outcomes.^{1,5} Chemotherapy is indicated for patients with unresectable disease or multiorgan involvement.^{1,6} An optimal chemotherapy regimen has not been determined for this rare disease and cytotoxic agents for malignant lymphoma or soft tissue sarcoma are commonly used to treat FDSC patients.^{4,7,8} Therefore, the accumulation of case reports is important to clarify the pathophysiology of FDSC and establish an optimal treatment strategy. We report our experience of an FDSC patient with multiorgan involvement whose disease was controlled by multiple chemotherapy regimens and who maintained a good performance status over a long period.

2 | CASE REPORT

2.1 | Clinical course

A 42-year-old Japanese woman initially complained of chest discomfort. The patient was initially diagnosed with a solid pseudopapillary neoplasm (SPN) localized to the pancreas and received distal pancreatectomy,

This is an open access article under the terms of the Creative Commons Attribution-NonCommercial-NoDerivs License, which permits use and distribution in any medium, provided the original work is properly cited, the use is non-commercial and no modifications or adaptations are made.

© 2016 The Authors. Hematological Oncology published by John Wiley & Sons Ltd.

splenectomy, and fundectomy. Five months later, an abdominal computerized tomography scan identified multiple liver metastasis, lymph node metastasis, and peritoneum dissemination. The metastatic tumor showed rapid growth and she was admitted to our hospital.

Although the final pathology report was not settled at the time of first-line chemotherapy, we implemented chemotherapy for SPN with SG regimen (S-1, 80 mg/body, on days 1–14 and Gemcitabine, 1000 mg/m², on days 1 and 8 of the 21-day cycle) based on the pathology evaluation from the pathologist who diagnosed first owing to rapid tumor growth, but disease progression was evidently observed after 1 cycle. Combination therapy was selected as first-line chemotherapy because of its high response rate in patients with pancreas cancer.⁹ At the same time, an accurate pathologic diagnosis was made from tumor specimens and she was diagnosed with FDGS. Histological analysis of the patient tumor biopsy demonstrated a tumor mass with a diffuse growth of spindle cells, multinucleated cells, intranuclear inclusions, and Hodgkinoid plasma cells (Figure 1).

Immunohistochemical analysis revealed that the tumor cells were positive for CD21, CD23, CD68 (weak), vimentin, clusterin, and fascin and were negative for CD1a, HMB-45, desmin, smooth muscle actin, and S100.

After 6 cycles of doxorubicin (DXR) (60 mg/m², on day 1 of the 21-day cycle), a standard cytotoxic agent of soft tissue sarcoma,^{10,11} a good partial response was observed, and careful observation without chemotherapy was continued for 3 months (Figure 2). Ifosfamide (IFM) administered at 1.8 mg/m² on days 1–3 of the 21-day cycle was selected as a third-line chemotherapeutic agent because it is a standard cytotoxic agent for the treatment of soft tissue sarcoma,^{11,12} and CHOP (cyclophosphamide, vincristine, doxorubicin, prednisolone), which is a standard regimen for malignant lymphoma,^{13,14} was selected as a fourth-line chemotherapy treatment. However, despite this treatment, disease rapidly progressed. ESHAP (etoposide, methylprednisolone, cisplatin, cytarabine), which is a standard salvage regimen for malignant lymphoma,¹⁵ was selected as a fifth-line chemotherapy treatment. Shrinkage of the abdominal mass was observed after 1 cycle of ESHAP. Because of the high-grade adverse effects (nausea, vomiting, and fatigue) associated with ESHAP, the patient required an 80% reduction in chemotherapy doses from the third cycle of ESHAP onward. At the end of 4 cycles of ESHAP, renal dysfunction due to cisplatin was observed and ESHAP was not continued. We selected a weekly dose of paclitaxel (PTX) (80 mg/m²) as a sixth-line chemotherapy treatment because PTX is metabolized by the liver and taxane is effective for soft tissue sarcoma therapy. Weekly

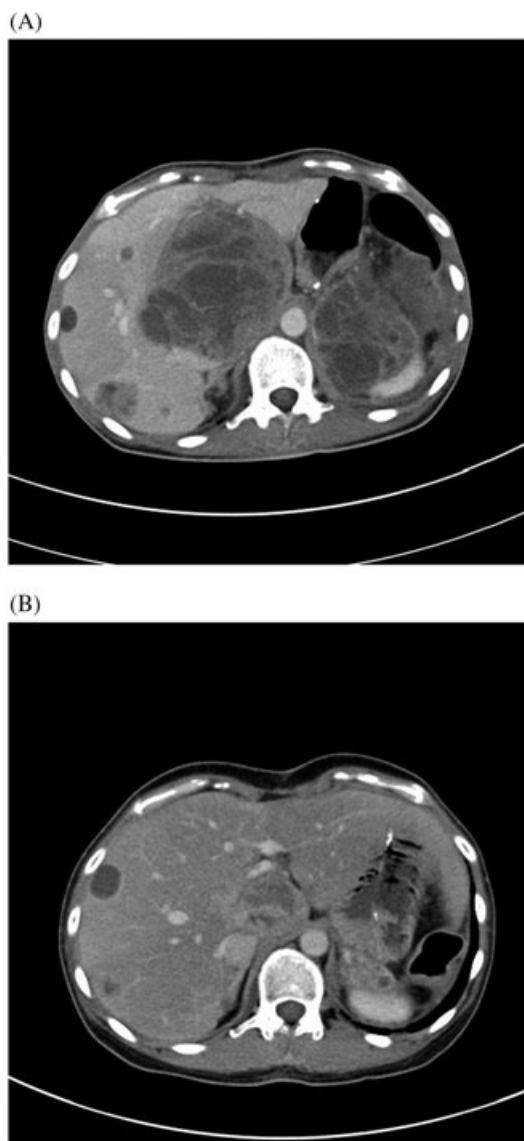


FIGURE 2 CT images of abdomen. A, Before DXR. B, After DXR

administered PTX controlled the disease progression, and the patient maintained a good performance status for 4 months. At the next onset of disease progression, we selected bendamustine (120 mg/m², on days 1 and 2 of the 21-day cycle), which is effective for the treatment of malignant lymphomas,¹⁶ as a seventh-line therapy. After administration of bendamustine, the laboratory data were improved rapidly. However, a second course could not be initiated at day 22 because

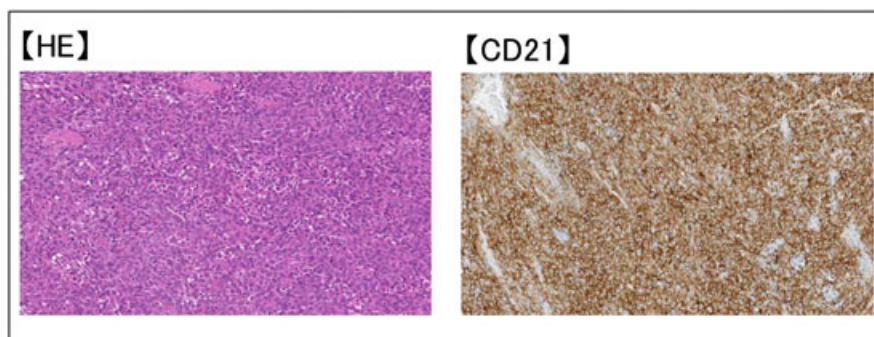


FIGURE 1 Hematoxylin and eosin staining and immunochemical features of the tumor

of the development of adverse effects caused by bendamustine such as diarrhea and loss of appetite. Although we attempted to recover the beneficial performance status of the treatment using intravenously administered saline to counter the dehydration caused by excessive diarrhea, disease progression continued, and we decided that a continuation of the chemotherapy was impossible.

2.2 | Laboratory data

CT scans were performed before progression, and we finally decided treatment change. However, in this case, changes in alkaline phosphatase (ALP) and C-reactive protein (CRP) looked associated with CT image, and we also used ALP and CRP as a possible surrogate marker to infer effectiveness of treatment. The relationship between disease control and laboratory data is shown in Figure 3. During effective chemotherapy treatment with DXR, ESHAP, or PTX, CRP and ALP values were decreased or were maintained at the same level, and during disease progression, these values were increased significantly. After the first administration of bendamustine, CRP and ALP levels were significantly and rapidly decreased. However, adverse events related to bendamustine were prolonged, and we could not start a second cycle of chemotherapy on day 22 of the first cycle. On day 35 of the first cycle, ALP, lactate dehydrogenase, and CRP were significantly increased and disease progression was observed.

3 | DISCUSSION

In a pooled analysis of FDCC patients by Saygin et al,¹ 68% of FDCC patients had extranodal disease, and a common extranodal site, including the liver, lung, tonsil, spleen, or soft tissue, was involved. FDCC of the pancreas as reported in the present case is very rare. In this analysis, they reported that early disease accounted for 85% of all FDCC cases. Because radical resection is indicated for most of FDCC patients, there have been few reports of advanced disease, which is indicated for chemotherapy. In another case report, CHOP, which is the standard

chemotherapy for malignant lymphoma and salvage therapy for refractory cases after the treatment of malignant lymphomas and soft tissue sarcomas, was indicated for unresectable patients.⁶ Other studies reported that chemotherapy for malignant lymphoma or soft tissue sarcoma was commonly selected, but optimal palliative chemotherapy regimens are controversial and data on the use of palliative chemotherapy are limited for refractory FDCCS.

To our knowledge, the control of disease in an FDCC patient using many different chemotherapy regimens to maintain a good performance status has not been reported previously. Saygin et al reported prognostic variables of FDCC patients from a pooled univariate analysis of all published data and indicated that age (young age ≤ 40 years), absence of lymphoplasmacytic infiltration, large tumor size (>6 cm), and mitotic counts ($\geq 5/10$ high-power field) were significant indicators of a poor prognosis. In multivariate analysis, lymphoplasmacytic infiltration and tumor size were associated with a poor prognosis. Furthermore, the median survival for local disease was 168 months, and the 2-year survival rate was 82.8% for local disease. However, the 2-year survival rate was 42.8% for metastatic disease.¹ In the present case, disease was only located in the pancreas initially, and radical resection was performed, but disease-free survival was only 6 months. In the current case study, multiple metastasis developed after the treatment, and several factors that indicated a poor prognosis were observed that were in accordance with a previous study by Saygin et al. The current case study had a very poor prognostic disease but survived for a long time with a good performance status because of the multiple chemotherapy treatments administered.

The characteristics of the clinical course of the present case were as follows: (i) although it was a very aggressive tumor and performance status was low before DXR, the tumor shrunk rapidly and the patient's performance status recovered immediately after the indication of DXR; (ii) the response to DXR was very good, and the reason for changing to another regimen was not due to progressive disease; nevertheless, IFM and CHOP (containing DXR) was not effective in treating the disease; (iii) although the use of the third- and the fourth-line chemotherapy, normally used to treat soft tissue sarcoma

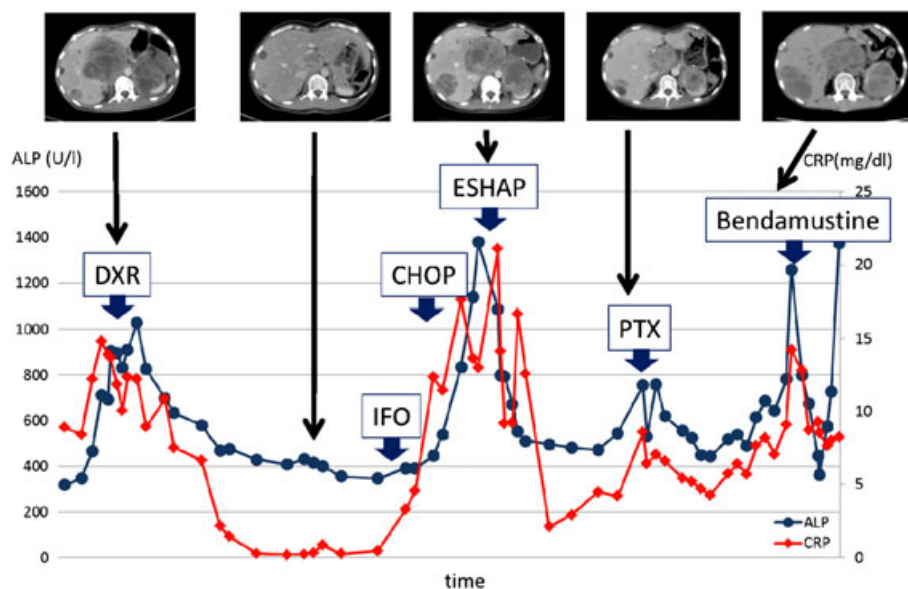


FIGURE 3 Relationship between changes in laboratory data (CRP and ALP) and tumor responses to chemotherapy

and malignant lymphoma, was not effective, the fifth-line chemotherapy (ESHAP) and sixth-line PTX were effective and performance status recovered.

As far as we know, this is the first study reporting the indication of bendamustine for FDCS patients. Bendamustine is very effective for low-grade B-cell lymphoma and is a current standard chemotherapy for low-grade B-cell lymphoma.¹⁶ In addition, clinical trials evaluating the use of bendamustine in diffuse large B-cell lymphoma, an intermediate grade lymphoma, are under way. The result of a phase II clinical trial to evaluate the effectiveness of bendamustine in previously treated diffuse large B-cell lymphoma reported that the overall response rate was 62.7%, the complete response rate was 37.3%, and the progression-free survival was 6.7 months.¹⁷ Bendamustine is expected to become a key drug for the treatment of intermediate grade lymphoma. The result of a phase II clinical trial to evaluate the effectiveness of bendamustine in previously treated soft tissue sarcoma reported that the partial response rate was 3%, the stable disease rate was 31%, and the 3-month progression-free survival rate was 35.3% and 6-month progression-free survival rate was 23.5%.¹⁸ Bendamustine was selected for the seventh-line chemotherapy treatment because it has antitumor effects and low cross-resistance with other alkylators, thus making it suitable for the treatment of alkylator-refractory patients. After the administration of bendamustine, ALP and CRP levels were decreased dramatically. This clinical course was observed when DXR or ESHAP was administered and changes in ALP and CRP levels were associated with disease control. Although it was impossible to continue bendamustine treatment because of bendamustine-induced adverse effects and subsequent reduced physical strength of the patient, a rapid decrease of ALP and CRP was observed regardless of the many other chemotherapy regimens administered previously. As for present case, bendamustine could not continue after 1 cycle, and we did not demonstrate good outcome with bendamustine. However, there may be room for examination in the adequacy of bendamustine as treatment option for FDCS.

ACKNOWLEDGEMENT

There is no source of support.

CONFLICT OF INTEREST

There is no conflict of interest.

ETHICS STATEMENT

This is a retrospective case report of FDCS. Any identifying information of patient has not been revealed. Additional examinations were not performed for this study.

REFERENCES

- Saygin C, Uzunaslan D, Ozguroglu M, et al. Dendritic cell sarcoma: a pooled analysis including 462 cases with presentation of our case series. *Crit Rev Oncol Hematol*. 2013;88(2):253–271.
- Dalia S, Shao H, Sagatys E, et al. Dendritic cell and histiocytic neoplasms: biology, diagnosis, and treatment. *Cancer Control*. 2014;21(4):290–300.

- Dalia S, Jaglal M, Chervenick P, et al. Clinicopathologic characteristics and outcomes of histiocytic and dendritic cell neoplasms: the moffitt cancer center experience over the last twenty five years. *Cancers*. 2014;6(4):2275–2295.
- Caces DB, Daniel S, Paredes-Tejada JM, et al. Spontaneous regression of follicular dendritic cell sarcoma. *J Clin Oncol*. 2012;30(3):e24–e26.
- Perkins SM, Shinohara ET. Interdigitating and follicular dendritic cell sarcomas: a SEER analysis. *Am J Clin Oncol*. 2013;36(4):395–398.
- Soriano AO, Thompson MA, Admirand JH, et al. Follicular dendritic cell sarcoma: a report of 14 cases and a review of the literature. *Am J Hematol*. 2007;82(8):725–728.
- Shinagare AB, Ramaiya NH, Jagannathan JP, et al. Primary follicular dendritic cell sarcoma of liver treated with cyclophosphamide, doxorubicin, vincristine, and prednisone regimen and surgery. *J Clin Oncol*. 2011;29(35):e849–e851.
- Choi BS, Baek JH, Shin YM, et al. Follicular dendritic cell sarcoma: a case report and review of the literature. *Cancer Res Treat*. 2010;42(2):121–124.
- Ueno H, Ioka T, Ikeda M, et al. Randomized phase III study of gemcitabine plus S-1, S-1 alone, or gemcitabine alone in patients with locally advanced and metastatic pancreatic cancer in Japan and Taiwan: GEST study. *J Clin Oncol*. 2013;31(13):1640–1648.
- Santoro A, Tursz T, Mouridsen H, et al. Doxorubicin versus CYVADIC versus doxorubicin plus ifosfamide in first-line treatment of advanced soft tissue sarcomas: a randomized study of the European Organization for Research and Treatment of Cancer Soft Tissue and Bone Sarcoma Group. *J Clin Oncol*. 1995;13(7):1537–1545.
- Judson I, Verweij J, Gelderblom H, et al. Doxorubicin alone versus intensified doxorubicin plus ifosfamide for first-line treatment of advanced or metastatic soft-tissue sarcoma: a randomised controlled phase 3 trial. *Lancet Oncol*. 2014;15(4):415–423.
- van Oosterom AT, Mouridsen HT, Nielsen OS, et al. Results of randomised studies of the EORTC Soft Tissue and Bone Sarcoma Group (STBSG) with two different ifosfamide regimens in first- and second-line chemotherapy in advanced soft tissue sarcoma patients. *European J Cancer*. 2002;38(18):2397–2406.
- Fisher RI, Gaynor ER, Dahlborg S, et al. Comparison of a standard regimen (CHOP) with three intensive chemotherapy regimens for advanced non-Hodgkin's lymphoma. *N Engl J Med*. 1993;328(14):1002–1006.
- Coiffier B, Lepage E, Briere J, et al. CHOP chemotherapy plus rituximab compared with CHOP alone in elderly patients with diffuse large-B-cell lymphoma. *N Engl J Med*. 2002;346(4):235–242.
- Velasquez WS, McLaughlin P, Tucker S, et al. ESHAP—an effective chemotherapy regimen in refractory and relapsing lymphoma: a 4-year follow-up study. *J Clin Oncol*. 1994;12(6):1169–1176.
- Rummel MJ, Niederle N, Maschmeyer G, et al. Bendamustine plus rituximab versus CHOP plus rituximab as first-line treatment for patients with indolent and mantle-cell lymphomas: an open-label, multicentre, randomised, phase 3 non-inferiority trial. *Lancet*. 2013;381(9873):1203–1210.
- Vacirca JL, Acs PI, Tabbara IA, et al. Bendamustine combined with rituximab for patients with relapsed or refractory diffuse large B cell lymphoma. *Ann Hematol*. 2014;93(3):403–409.
- Hartmann JT, Mayer F, Schleicher J, et al. Bendamustine hydrochloride in patients with refractory soft tissue sarcoma: a noncomparative multicenter phase 2 study of the German sarcoma group (AIO-001). *Cancer*. 2007;110(4):861–866.

How to cite this article: Sasaki M, Izumi H, Yokoyama T, Kojima M, Hosono A. Follicular dendritic cell sarcoma treated with a variety of chemotherapy. *Hematological Oncology*. 2017;35:905–908. <https://doi.org/10.1002/hon.2364>