

Fatal butane toxicity and delayed onset of refractory ventricular fibrillation

Khalid N. Almulhim, MD.

ABSTRACT

تم جلب رجل يبلغ من العمر 30 عاما إلى قسم الطوارئ من قبل الخدمات الطبية الطارئة. وقد وجد أنه فاقد الوعي ولكنه يتنفس بشكل طبيعي، وكان لديه تشنج لأكثر من 30 دقيقة. لم يكن لديه تاريخ السابق لأي من الأمراض الجهازية، العملية مسبقا، استخدام أدوية وأي حساسية معروفة. ووفقا للشهود، كان وحده في المقهى، وإلى جانبه كانت هنالك عبوة إعادة تعبئة تحتوي على 250 مل من غاز البوتان النقي المنقى، وانهار فجأة واصابته نوبة تشنج. وبعد ست ساعات، وضع الرجفان البطيني، ولم يستجب إلى ضخ الأميودارون، و 4 مرات لتقويم نبض القلب والرجفان. وقد توفي بعد 45 دقيقة من الإنعاش.

A 30-year-old male was presented to the Emergency Department (ED) by the Emergency Medical Services (EMS). He was found unconscious but breathing normally, and had a seizure for more than 30 minutes. He was no previous history of systemic disease, previous operation, medication and any known allergy. According to the witnesses, he was alone in the coffee shop, and besides him was a lighter refill canister containing 250 ml extra purified butane gas, and he suddenly collapsed and had seizure. Six hours later, he developed ventricular fibrillation and he was not responding to amiodarone infusion, and 4 times defibrillation and cardioversion. He died after 45 minutes of resuscitation.

*Saudi Med J 2017; Vol. 38 (12): 1250-1254
doi: 10.15537/smj.2017.12.20811*

From the College of Medicine, King Faisal University, Al-Ahsa, Kingdom of Saudi Arabia.

Received 10th July 2017. Accepted 18th July 2017.

*Address correspondence and reprint request to: Dr. Khalid N. Almulhim, College of Medicine, King Faisal University, Al-Ahsa, Kingdom of Saudi Arabia. E-mail: khalid.almulhim@hotmail.com
ORCID ID: orcid.org/0000-0001-8564-8620*

Toxicity of any substance is the degree at which it creates harmful effect on human being or any organism. Usually toxicity will be of 2 types, acute toxicity and chronic toxicity, where the former inflicts harmful effects immediately at a single exposure, or a short-term exposure to the toxin, but the later become detrimental with an extended period of time with intermittent or long term exposure of the toxin by the patient. Butane is a colorless, highly inflammable organic compound, which is in a gaseous state at normal atmospheric pressure and at room temperature. Butane is usually used in fuel gas, as a component of petroleum and for many different industrial purposes. It is also used as a fuel for the common cigarette lighters and is available in canisters for refill. Butane in lighters will be with small quantities of isobutane and propane, which is commercially available in the market. Different types of butane abuse or accidental inhalations are reported to the emergency units of hospitals, which is becoming a serious public health issue. Sen et al¹ discussed the misuse of the volatile agent, the cause of intoxication, and the management of such a case in the intensive care units. Acute exposure guideline levels (AEGL) for selected airborne chemicals² expressed in parts per million, defines 3 AEGLs with varying degree of severity and toxic effects. Of the 3 AEGLs, the third AEGL could lead to life-threatening health issues or even death. The AEGL explains the cases specifying that butane might cause arrhythmias in humans exposed at high concentrations, and no adequate human or animal data are available to evaluate its end point in a quantitative way. The guideline also pointed out similar case reports, which indicate that single exposure to high concentrations of butane might cause severe brain damage in fetus, but no adequate data are available for a quantitative evaluation in humans. However, there is an old study conducted in human volunteers indicates that

Disclosure. Authors have no conflict of interests, and the work was not supported or funded by any drug company.

a patient who is exposed to butane illustrates cutaneous lesions, which may be secondary to absorption of the toxic product, probably induced by inhalation rather than by percutaneous penetration.³ Because of its easy access, often it is used in higher dose for inhalant abuse. Even though the toxicity of butane is low, the period and frequency of exposure to the substance is also a deciding factor. Sasao et al⁴ reported 3 forensic autopsy cases of sudden death that occurred while sniffing n-butane and isobutane from portable gas cartridges and they concluded in their study that the presence or absence of n-butane metabolites might reflect the way of butane inhalation, such as the frequency and duration. Hence, how many times and how long the case is exposed to butane is an important predicting factor, which makes the situation serious enough for a fatal incident. This case report is discussing the case, describing the symptoms, signs, diagnosis, and treatment of an unusual case of a 30-year-old male with delayed onset of refractory ventricular fibrillation.

Case Report. A 30-year-old male was presented to the Emergency Department (ED) by the Emergency Medical Services (EMS) and he was unconscious when he was brought to the ED and he has been on seizure for more than 30 minutes. He was unconscious and was breathing normally when the EMS arrived at him. It was reported that the patient was without any history of systemic disease, previous surgeries, medication and any known allergy. According to the witnesses, the patient was alone in a coffee shop and besides him was a lighter refill canister containing 250 ml extra purified butane gas, and reported that he suddenly collapsed and

had seizure. Started infusion of fluids, but tachycardia persists despite the infusion of 2 liters of fluids. He was then intubated for securing the airway and introduced mechanical ventilation with volume-control (FiO₂: 0.50, Tidal volume: 550 ml, frequency: 12 beats/min, positive end-expiratory pressure: 5 cm H₂O) and the central line was inserted. He was also sedated with midazolam and fentanyl infusion.

Clinical findings. Upon presentation, the following were the observations made by the ED physicians: heart rate: 170 beats per minute, body temperature: 37.8°, oxygen saturation: 90% on room air temperature, electrocardiogram: sinus tachycardia (Figure 1), and Table 1 illustrates the timeline of the case, starting from the time of spotting to admission until the final outcome with diagnosis of condition and different stages of interventions.

Diagnostic assessment. Laboratory investigation indicates acute renal failure, high levels of creatinine kinase (1700 U/L), indication of tissue damage, especially myocardium and muscle tissue. Computed tomography of the brain shows mild brain edema.

Follow-up and outcome. Tachycardia persisted even after 3 hours later, followed by dropping of blood pressure to 70/50 mm Hg. Hence, the physician started infusing inotropes, but 6 hours later he developed ventricular fibrillation. He did not respond to amiodarone infusion, followed by 4 times of defibrillation and cardioversion. Finally, he died after 45 minutes of resuscitation.

Discussion. We presented with a case of delayed onset of refractory ventricular fibrillation (VF) following butane inhalation. Butane refill canisters are popular

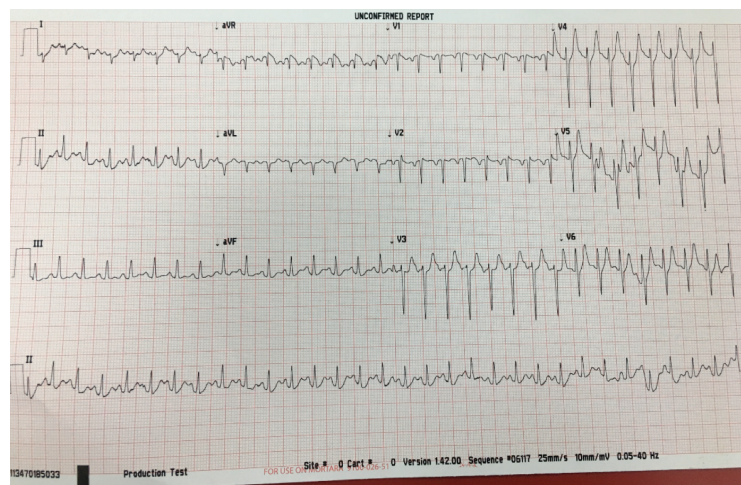


Figure 1 - Electro cardiogram of patient demonstrating sinus tachycardia.

among the people, especially among the youth due to the easy availability, which contains hydrocarbons.⁵ Based on the available literature, the refill canister contains 54% n-butane, 26% propane, and 20% isobutane. Ago et al⁶ reported that n-butane in the can of anti-perspiration aerosol deodorant induced fatal cardiac arrhythmia, which leads to the death of patient. Sugie et al,⁷ with autopsy findings and gas analysis reveals that the cause of death in their case was ventricular fibrillation, induced by hard muscle exercise in few minutes after gas inhalation. But in our case, VF sets in after a long gap, which was in contradiction to the other reported literatures. However, few studies indicated delayed fatalities with multiple organ failures.⁸ Williams et al⁹ reported a successful resuscitation case followed

by a volatile substance abuse and according to them this was the first documented evidence of VF associated with butane gas, which illustrates the tragedy of butane abuse even in fit young people. Sen et al¹⁰ also reported butane intoxication, where the patient had a syncope and persistent VF during the course of resuscitation. Myocardial infarction (MI) in children is a very rare condition, but as reported by Godlewski et al¹¹ butane inhalation to the toxic level can even lead to sudden cardiac arrest due to VF even in children. Another study conducted by Gunn et al¹² also illustrated that butane sniffing cause ventricular fibrillation. But, in our case, we were not sure how long and how much the patient was exposed to butane at the time he was found unconscious.

Table 1 - Timeline of a 30-year-old male presented with delayed onset of refractive ventricular fibrillation following butane inhalation.

Dates	Summaries from initial and follow-up visits	Diagnostic testing	Interventions
13 th March 2017 (23:35 p.m.)	A 30-year-old unconscious male was presented to the ED by the EMS, who has been on seizure for more than 30 minutes. No history of systemic disease, previous surgeries, medication and any known allergy. He was alone in the coffee shop and besides him was a lighter refill canister containing 250 ml extra purified butane gas. He suddenly collapsed and had seizure.		
13 th March 2017 (23:50 p.m.)		RR: 16 breaths/ minute Random blood sugar: 130 mg/dl GCS: 3/15 Chest examination: decrease air entry bilaterally CVS: normal Abdomen: normal Skin examination: first degree burn on the face around the mouth, no needle marks ECG: sinus tachycardia CXR: normal	
14 th March 2017 Laboratory test (2:30 a.m.)		Acute renal failure, high levels of creatinine kinase of 1700 U/L. CT of the brain: mild brain edema	
14 th March 2017 Follow-up test (4:15 a.m.)		Tachycardia persisted, followed by dropping of blood pressure to 70/50 mm Hg. The patient developed ventricular fibrillation	Infusion of intropes
14 th March 2017 Final outcome (7:45 a.m.)			No response to amiodarone infusion, followed by 4 times of defibrillation and cardioversion. The patient died after 45 minutes of resuscitation

RR - respiratory rate, GCS - Glasgow Coma Scale, CVS - cardio vascular system examination, ECG - electrocardiogram, CXR - chest x-ray

Inhalation of butane, the extremely volatile hydrocarbon when enters the lung replaces oxygen, which leads to hypoxia and the patient slowly become unconscious. Butane, the highly lipophilic gas reaches the brain and lungs, while propane affects the central nervous system, which once enters the circulation gets concentrated in these organs. Moreover, butane acts as a catecholamine, leading to a fatal condition of tachyarrhythmias, which was clear from the ECG findings. The hydrocarbon, butane usually causes inflammation of the walls of alveoli,¹³ but the x-ray findings was without any signs of lung inflammation or pneumonitis. The toxicological property of butane seriously affects the brain, resulting in subsequent development of severe brain damage.¹⁴ However, there was no serious damage in the brain, which was clarified from the CT findings, indicating only mild brain edema. But, the high level of creatinine kinase was an indicator of muscle tissue damage.¹⁵

Furthermore, cardiac involvement of butane toxicity is common and is reported in the available literature that it may be due to coronary artery spasms. El-Menyar et al¹⁶ assumes in their study that cardiac complications after butane inhalations may partly be secondary to intense coronary artery spasm on the basis of clinical and laboratory findings. The cardiac involvement also leads to frequent ventricular fibrillations, which makes resuscitation difficult. Edwards et al¹⁷ suggest that antiarrhythmic agents should be used early during resuscitation to prevent recurrent arrhythmias. However, infusion of infusing intropes did not work out in this case and developed ventricular fibrillation, resulting in the death of patient. The available literature also illustrates that a massive intoxication of butane leads to serious damages, which includes VF resulting in sudden death. This is demonstrated by Zivković et al,¹⁸ where they concluded that propane-butane mixture leads to the depletion of oxygen in the air, consequently causing hypoxia and anoxia, which leads to unconsciousness and eventual death. They also mentioned that the causes of death include cardiac arrhythmias, reflex cardiac vagal inhibition, and/or central nervous system depression. Another study by Bowen et al¹⁹ stated that deaths associated with the abuse of butane and toluene, where all substances appeared to be capable of killing directly by their toxic effects, probably through cardiac and/or respiratory mechanisms. However, a case report made by Wien Klin Wochenschr et al⁸ explained the case

of a 14 year old boy who inhaled butane gas from an aerosol-can used for refilling gas lighter. In this case the boy died 2 days later due to multiple organ failure involving the central nervous system, cardiovascular system, pulmonary system, and liver. Nevertheless, there are not much study indicating a delayed onset of refractory VF and its association with butane toxicity the relation.

In conclusion, delayed onset of VF may be because of a low level of toxicity from butane inhalation. Hence, management of such cases will be difficult to handle unless and until the right information is received by the physician. We recommend the emergency management system to collect as much as information, right from the source immediately after transferring the patient to the intensive care units.

References

1. Sen A, Erdivanli B. Cardiac arrest following butane inhalation. *Anesth Essays Res* 2015; 9: 273-275.
2. Acute Exposure Guideline Levels for Selected Airborne Chemicals: Volume 12. Committee on Acute Exposure Guideline Levels; Committee on Toxicology; Board on Environmental Studies and Toxicology; Division on Earth and Life Studies; National Research Council. Washington (DC): National Academies Press (US); 2012. p. 27.
3. Jeanmougin M, Bonvalet D, Civatte J, Ramelet AA, Vilmer C. Non-drug toxicoderma by a respiratory or probable percutaneous route (fluorocarbons, butane, phenyl-azo-beta-naphthol. *Ann Dermatol Venereol* 1984; 111: 437-444.
4. Sasao A, Yonemitsu K, Ohtsu Y, Mishima S, Nishitani Y. Quantitative determination of n-butane metabolites in three cases of butane sniffing death. *Forensic Sci Int* 2015; 254: 180-184.
5. Mowry JB, Spyker DA, Cantilena LR Jr, Bailey JE, Ford M. 2012 Annual Report of the American Association of Poison Control Centers' National Poison Data System (NPDS): 30th Annual Report. *Clin Toxicol (Phila)* 2013; 51: 949-1229.
6. Ago M, Ago K, Ogata M. A fatal case of n-butane poisoning after inhaling anti-perspiration aerosol deodorant. *Leg Med (Tokyo)* 2002; 4: 113-118.
7. Sugie H, Sasaki C, Hashimoto C, Takeshita H, Nagai T, Nakamura S, Furukawa M, Nishikawa T, Kurihara K. Three cases of sudden death due to butane or propane gas inhalation: analysis of tissues for gas components. *Forensic Sci Int* 2004; 143: 211-214.
8. Rieder-Scharinger J, Peer R, Rabl W, Hasibeder W, Schobersberger W. Multiple organ failure following inhalation of butane gas: a case report. *Wien Klin Wochenschr* 2000; 112: 1049-1052.
9. Williams DR, Cole SJ. Ventricular fibrillation following butane gas inhalation. *Resuscitation* 1998; 37: 43-45.
10. Sen A, Erdivanli B. Cardiac arrest following butane inhalation. *Anesth Essays Res* 2015; 9: 273-275.

11. Godlewski K, Werner B, Sterliński M, Pytkowski M, Szwed H, Domagała M, et al. Myocardial infarction after butane inhalation in a 14-year-old boy. *Kardiol Pol* 2006; 64: 305-308.
12. Gunn J, Wilson J, Mackintosh AF. Butane sniffing causing ventricular fibrillation. *Lancet* 1989; 1 (8638): 617.
13. Shrivastava MS, Palkar AV, Karnik ND. Hydrocarbon pneumonitis masquerading as acute lung injury. *BMJ Case Rep* 2011; 2011: pii: bcr0320114017. doi: 10.1136/bcr.03.2011.4017.
14. Döring G, Baumeister FA, Peters J, von der Beek J. Butane abuse associated Encephalopathy. *Klin Padiatr* 2002; 214: 295-298.
15. Carr F, Prasad B. An unusual case of renal tubular acidosis. *BMJ Case Rep* 2011; 2011: pii: bcr1220103616. doi: 10.1136/bcr.12.2010.3616.
16. El-Menyar AA, El-Tawil M, Al Suwaidi J. A teenager with angiographically normal epicardial coronary arteries and acute myocardial infarction after butane inhalation. *Eur J Emerg Med* 2005; 12: 137-141.
17. Edwards KE, Wenstone R. Successful resuscitation from recurrent ventricular fibrillation secondary to butane inhalation. *Br J Anaesth* 2000; 84: 803-805.
18. Zivković V, Juković F, Nikolić S. [Suicidal asphyxiation by propane-butane mixture inside a plastic bag: case report]. *Srp Arh Celok Lek* 2010; 138: 376-378.
19. Bowen SE, Daniel J, Balster RL. Deaths associated with inhalant abuse in Virginia from 1987 to 1996. *Drug Alcohol Depend* 1999; 53: 239-245.

Case Reports

Case reports will only be considered for unusual topics that add something new to the literature. All Case Reports should include at least one figure. Written informed consent for publication must accompany any photograph in which the subject can be identified. Figures should be submitted with a 300 dpi resolution when submitting electronically. The abstract should be unstructured, and the introductory section should always include the objective and reason why the author is presenting this particular case. References should be up to date, preferably not exceeding 15.