

Treatment of Combined Spinal Deformity in Patient with Ollier Disease and Abnormal Vertebrae

S. O. Ryabykh¹ A. V. Gubin¹ O. G. Prudnikova¹ A. E. Kobzyev¹

¹Russian Ilizarov Scientific Center, "Restorative Traumatology and Orthopaedics," Kurgan, Russian Federation

Global Spine J 2013;3:109–114.

Address for correspondence Sergei Olegovich Ryabykh, Cand. Sci. (Med.), Head of Laboratory for Axial Skeletal Pathology and Neurosurgery with the Russian Ilizarov Scientific Center, "Restorative Traumatology and Orthopaedics," Ministry of Health and Social Development of the Russian Federation, 6, ul. M. Ulianovoy, Kurgan 640014, Russia (e-mail: rso_@mail.ru).

Abstract

We report staged treatment of severe combined spinal deformity in an 11-year-old patient with Ollier disease and abnormal cervical vertebra. Combined scoliosis with systemic pathology and abnormal vertebrae is a rare condition and features atypical deformity location and rapid progression rate and frequently involves the rib cage and pelvis, disturbing the function of chest organs and skeleton. Progressive deformity resulted in cachexia and acute respiratory failure. A halo-pelvic distraction device assembled of Ilizarov components was employed for a staged surgical treatment performed for lifesaving indications. After vital functions stabilized, the scoliosis curve of the cervical spine was corrected and fixed with a hybrid system of transpedicular supporting points, connecting rods, and connectors that provided staged distraction during growth. The treatment showed good functional and cosmetic result.

Keywords

- ▶ Ollier disease
- ▶ enchondromatosis
- ▶ atypical scoliosis
- ▶ halo-pelvic traction

Combined scoliosis with systemic pathology and abnormal vertebrae is a rare condition and features atypical deformity location and rapid progression rate and frequently involves the rib cage and pelvis, disturbing the function of the chest organs and skeleton. Ollier disease (also known as "enchondromatosis" and "Maffucci syndrome") is characterized by lesions in the growth plates of bones and is mostly associated with deformity of the limbs and the skull and muscular dystrophy, with a high risk of malignant transformation (up to 40%) in enchondromas.^{1–3} We found no evidence of spinal deformity with Ollier disease using bibliographical databases of Medline, PubMed, and periodicals of CIS countries. Therefore, we report our experience of observation and treatment of a patient with combined severe spinal deformity⁴ caused by enchondromatosis and abnormal vertebral formation. Our objective was to assess the possibility and efficacy of surgical correction and stabilization in children with combined spinal

deformity coupled with systemic pathology and vertebrae abnormality.

Material and Methods

A boy, 11 years old, was first seen for spinal deformity by a spinal surgeon in July 2011. The child's medical history indicated that he had outpatient appointments with an orthopedic surgeon for limb deformities. The diagnosis of Ollier disease was verified genetically in 2001. The boy was advised to wear orthopedic shoes. The spinal deformity was noted to progress during the previous 2 years. Orthopedic status showed disproportionate stature; evident cachexia with a weight of 18 kg; decompensated, rigid, extended right-side cervicothoracic scoliosis with torso deviated to the right and head to the left up to 90 degrees of Cobb's angle; gibbus on the right; hypertrophic muscles of the neck

received
February 27, 2012
accepted after revision
August 15, 2012
published online
November 28, 2012

© 2013 Georg Thieme Verlag KG
Stuttgart · New York

DOI <http://dx.doi.org/10.1055/s-0032-1329891>.
ISSN 2192-5682.

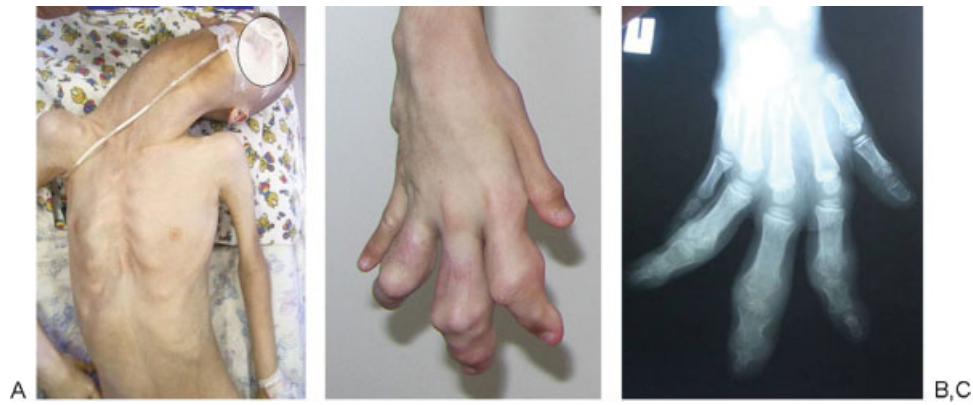

Figure 1 Photo of the patient at the intensive care unit of the regional children’s hospital.

more severe on the right; clinodactyly and hypertrophied phalanges of the fingers; and grade I funnel chest deformity (►Figs. 1A–C). Minimal exercise (walk up to 20 m) caused growing respiratory insufficiency. Neurological assessment showed clear consciousness.

Mental status was adequate for his age. Coordination tests were performed with intention; tendon reflexes of upper and lower limbs were brisk and symmetrical, and muscle strength of the upper limbs was graded as 5 and lower limbs as 3 according to American Spinal Injury Association Standard

Neurological Classification of Spinal Cord Injury. No sensory impairment or pelvic organ dysfunction was detected. The patient developed quick fatigue with episodes of hypoxia (falling asleep).

A radiological picture is presented in ►Fig. 2. Additional assessments were recommended at the Ilizarov Centre and possible surgical correction was considered. However, admission to the hospital was delayed due to viral respiratory infection. Emergency admission to the regional children’s hospital was required on August 1, 2011, for a severe

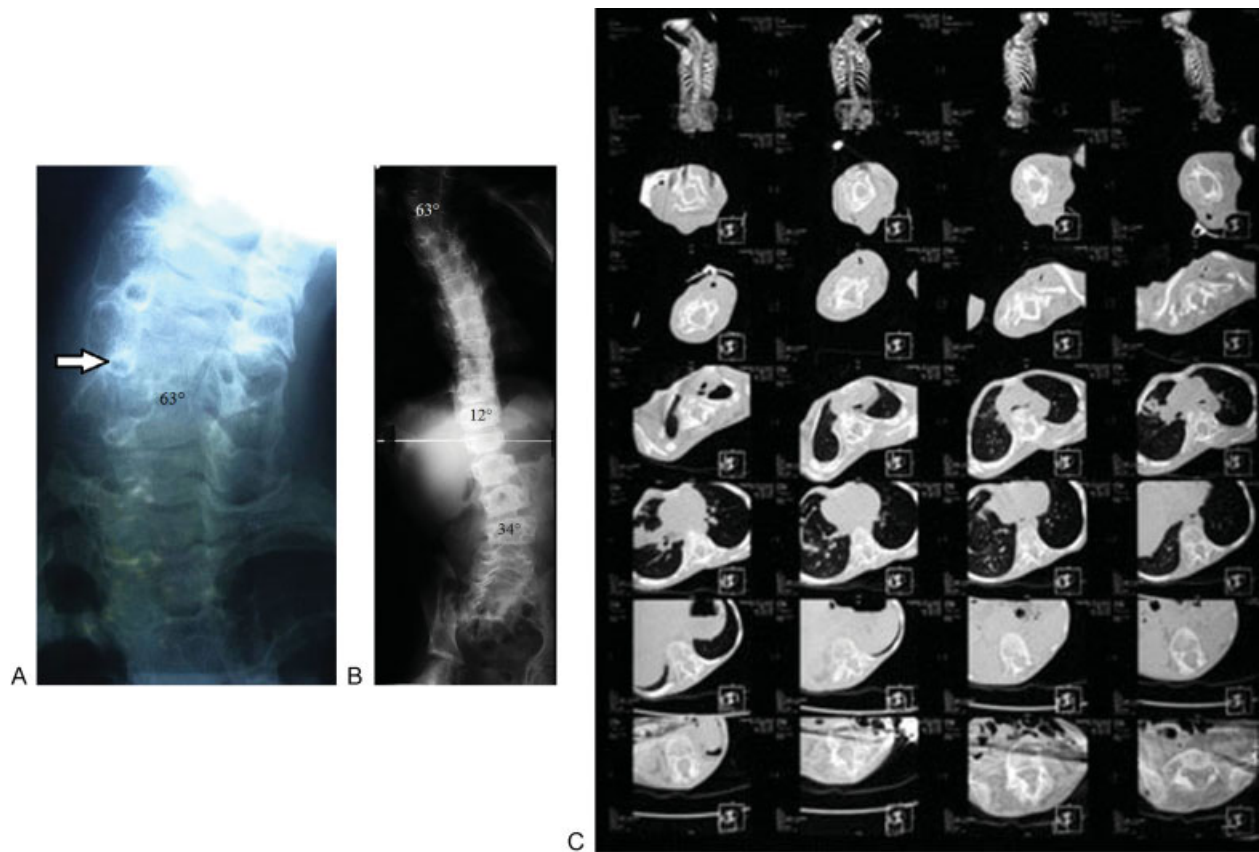


Figure 2 Imaging findings: (A, B) radiographs of the spinal column: C4 lateral nonsegmented hemivertebra on the right (marked with arrow), scoliotic curve, and decrease in the volume of thoracic cage. (C) Computed tomography shows evident cervical spine rotation and signs of pneumofibrosis.

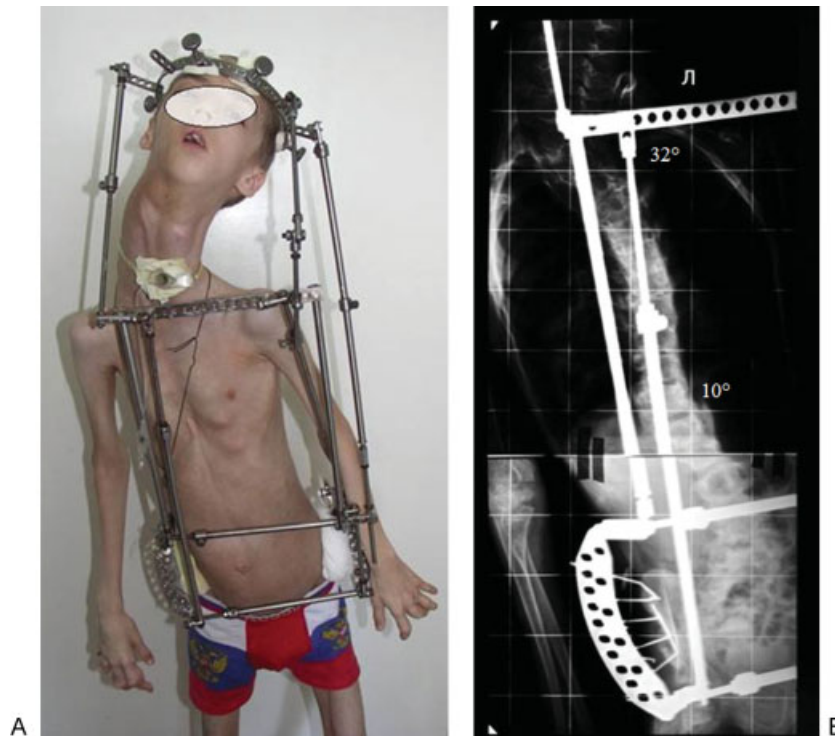


Figure 3 Photo (A) and radiograph (B) of the patient following deformity correction with halo-pelvic system assembled of the Ilizarov components.

condition with complaints of spitting up blood, coughing, and frequent episodes of sleep apnea lasting to 1 minute. Mechanical lung ventilation and antibacterial and syndrome-based therapy were performed at the intensive care unit. The reduced mechanical ventilation parameters led to higher levels of hypercapnia.

An external fixation device was applied for halo-pelvic traction by a team of spinal surgeons of the Kurgan Ilizarov Center on August 5, 2011. The frame was set up in the distraction mode of 6 cm to correct spinal deformity and to create favorable conditions for lung excursion (→**Fig. 3**). Saturation was shown to normalize in dynamics. However, tracheostomy was performed due to progressive respiratory failure on August 1, 2011. The patient's condition stabilized, and in 2 days he was transferred to autonomous breathing with tracheostomy and at 7 days he was transported to a somatic department (on August 25, 2011).

The patient was referred from the regional children's hospital to the neurosurgery department of the "Russian Ilizarov Scientific Centre Restorative Traumatology and

Orthopaedics" on September 29, 2011. The diagnosis on admission indicated Ollier disease with multiple deformities of axial skeleton, severe combined scoliosis with underlying systemic pathology and disturbed cervical spine formation, progressive muscular dystrophy, pneumofibrosis of the right lung, myocardiodystrophy, grade 3 cachexia, tracheostomy, and frame application for halo-pelvic traction.

On admission to the center, the patient was able to stand independently for 10 minutes and walk with support for 6 minutes without respiratory distress or imbalance, but he needed help with his meals and getting up. His torso balance improved in the coronal plane with persistent decompensation, but sagittal balance was compensated (→**Fig. 3A**). Deformity correction with instrumentation was achieved up to 32 degrees (−31 degrees) at the level of major cervicothoracic curve and up to 10 degrees (−2 degrees) at the level of accompanying lumbar arch (→**Fig. 3B**). Spirometry showed a 43% decrease in lung capacity.

Operative intervention performed on September 29, 2011, included correction and multisupport instrumentation fixation of C2–T9 segments with combined connector-type system (Summit-Expedium; DePuy International Ltd., Leeds, UK), posterior local spondylodesis, and dismantling of the halo-pelvic traction system (→**Fig. 4**).

The procedure involved incision at the level of C2–C10 spinous processes after cleaning the operation field. The vertebrae were exposed and hemostasis provided. Evident torsion to the apex of the arch was observed in the superior portion of the thoracic spine. Pairwise interlaminar screws were placed in C2; lateral mass screws (Summit) introduced in C4, C5, C6; and transpedicular and intracorporeal screws



Figure 4 Intraoperative multisupport instrumentation fixation of C2–C9 segments with connector-type system. Posterior local spondylodesis with chronOS strips (Synthes, Oberdorf, Switzerland).

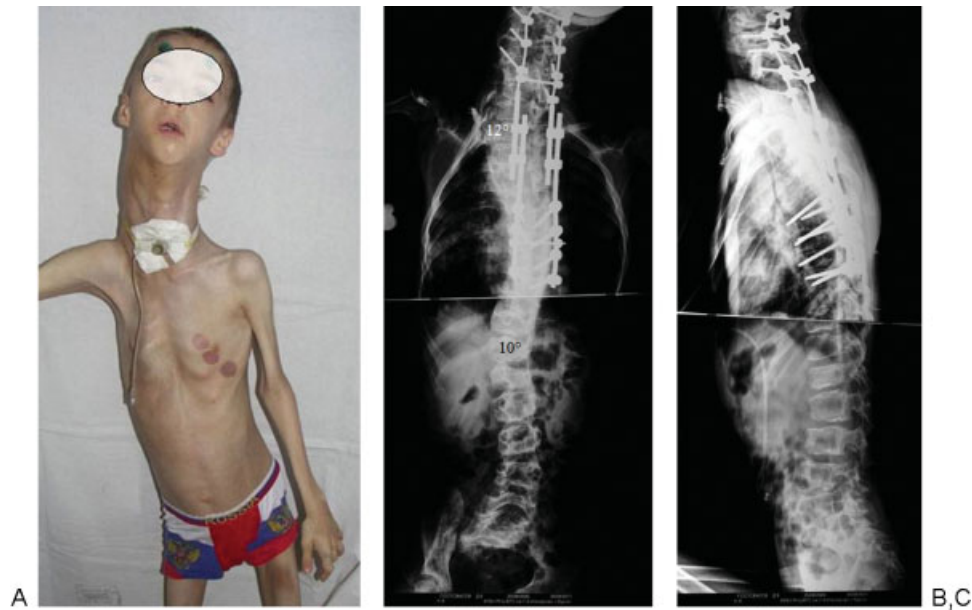

Figure 5 Photo (A) and radiographs (B, C) of the patient prior to discharge. Major arch of the deformity corrected to 12 degrees.

inserted in T6, T7, T8, T9 (on the left) and T6, T7, T9 (on the right). Reliable screw placement was secured by image intensifier. Connecting rods 3.5/5.5 were laid over the fixation points and connected at C6–T6 level bilaterally with four parallel connectors. Acute correction with tensioned rods was produced with distraction provided on the left and compression on the right under protection of methylprednisolone injection. Visual scoliosis correction was 80%. The construct was reinforced by two transverse bars mounted to the cervical spine and one connection plate to the thoracic spine. Frame stability was checked and hemostasis provided. The wound was stitched layer by layer. The system of intratissue anesthesia was incorporated in the wound. The skin was intradermally stitched and dressings applied. The halo-pelvic traction device was dismantled and aseptic dressings placed. Loss of blood volume was 200 mL (5% of the total body volume).

Satisfactory functional and cosmetic effect was obtained (►Fig. 5). Functional result assessed at 1 month after the surgery showed increased vital capacity of 56% according to spirometry findings and improved respiratory function with pulmonary stress test. The patient could walk with support for 30 minutes without respiratory imbalance, and he could eat food and stand up by himself, with torso balance in the coronal and sagittal planes being compensated (►Fig. 5A). The patient's weight was 21 kg (+3 kg). Checkup radiographs showed adequate screw position; spinal deformity correction was achieved at the level of major cervicothoracic curve to 12 degrees (–51 degrees) and at the level of accompanying lumbar arch to 10 degrees (–2 degrees; ►Fig. 5B). Therefore, the spinal correction was 81% and 17%, respectively. Neurological assessment demonstrated improved lower-extremity muscular strength (graded 4). The child was discharged on November 4, 2011, and tracheostomy was removed on November 23, 2011.

Discussion

The objective of the demonstration was to emphasize medical considerations on system abnormalities of patients with severe progressive spinal deformity, so called “high-risk deformities” that entail a severely reduced quality of life due to static and dynamic imbalance and progressive life-threatening functional disorders.^{5,6} Traditionally, such cases are considered incurable. It can be expected that the improved quality of peri- and postnatal care with persistent rate of worsening maternal health would inevitably lead to an increase in this patient cohort.

The clinical example presented here demonstrates the modern possibilities of surgical treatment, which dramatically improved a child's condition and his quality of life. Functional scoliosis-related life-threatening disorders were absolute indications to surgery. A strategy of surgical treatment involved application of an external stabilizing system in the position of moderate spinal correction and additional correction and stabilization with a posterior internal multisupport construct after improvement of his general condition. Tactical application included a halo-pelvic device assembled of Ilizarov components and a hybrid system with transpedicular supporting points, connecting rods, and connectors that provided staged distraction during growth.^{7–9}

Legal consideration of surgical treatment with detailed substantiation of a lifesaving procedure is required. The management team must include spine surgeons, pediatricians, pulmonologists, and neurologists.

Disclosures

S. O. Ryabykh, None
 A. V. Gubin, None
 O. G. Prudnikova, None
 A. E. Kobzyev, None

References

- 1 D'Angelo L, Massimi L, Narducci A, Di Rocco C. Ollier disease. *Childs Nerv Syst* 2009;25:647–653
- 2 Silve C, Jüppner H. Ollier disease. *Orphanet J Rare Dis* 2006;1:37
- 3 Schwarz W, Harges J, Schulte M. Multiple Enchondromatose: Morbus Ollier. *Unfallchirurg* 2002;105:1139–1142
- 4 James JL. Idiopathic Scoliosis: the prognosis, diagnosis, and operative indications related to curve patterns and the age of onset. *J Bone Joint Surg Br* 1954;36B:36–49
- 5 Campbell RM Jr, Smith MD. Thoracic insufficiency syndrome and exotic scoliosis. *J Bone Joint Surg Am* 2007;89(Suppl 1):108–122
- 6 Goldberg CJ, Gillic I, Connaughton O, et al. Respiratory function and cosmesis at maturity in infantile-onset scoliosis. *Spine* 2003;28:2397–2406
- 7 Ryabykh SO, Gubin AV, Prudnikova OG, Kobzyev AE. Primenenie dinamicheskikh sistem pri deformatsiyakh pozvonochnika u aktivno rastuschikh detei (Application of dynamic systems for spinal deformities in actively growing children) (In Russian). Paper presented at: Chaklinskije Chleniya Orthopaedic and Trauma Meeting with International Participation; October 26–27, 2011; Ekaterinburg, Russia
- 8 Lenke LG, Kim YJ, Rinella AS. Treatment of spinal deformity utilizing thoracic pedicle screws. *Semin Spine Surg* 2002;14:66–87
- 9 Lehman RA Jr, Lenke LG, Keeler KA, et al. Operative treatment of adolescent idiopathic scoliosis with posterior pedicle screw-only constructs: minimum three-year follow-up of one hundred fourteen cases. *Spine* 2008;33:1598–1604