

Pelvic osteotomies in hip dysplasia: why, when and how?

K Venkatadass¹, V Durga Prasad¹, Nasser Mohammed Mansor Al Ahmadi² and S Rajasekaran¹

¹Department of Orthopaedics & Spine Surgery, Ganga Hospital, Coimbatore, India

²Alwaly Hospital, Aden, Yemen

Correspondence should be addressed to N M M Al Ahmadi
Email
drnmmab@gmail.com

- Acetabular dysplasia is a significant problem in the spectrum of developmental dysplasia of hip. In a younger child, positioning the femoral head into the acetabulum helps in reciprocal remodeling of the acetabulum and correction of dysplasia. In an older child, the remodeling potential is limited and often the acetabular dysplasia needs surgical intervention in the form of a pelvic osteotomy.
- Thus, pelvic osteotomy forms an integral part of surgical management of hip dysplasia. The ultimate goal of these osteotomies is to preclude or postpone the development of osteoarthritis and add more years of life to the native hip.
- Pelvic osteotomies play a pivotal role in normalizing hip morphology. The choice of pelvic osteotomy depends on the age of a child, the type of dysplasia and the status of the tri-radiate cartilage.
- Several types of re-directional and reshaping pelvic osteotomies have been described in the literature to improve the stability and restore the anatomy and biomechanics of the dysplastic hip.
- This article attempts to review the current indications for various pelvic osteotomies with a brief description of their techniques along with the outcomes and complications published thus far. Besides, the guidelines to choose the right pelvic osteotomy are also provided.

Keywords

- ▶ developmental dysplasia hip
- ▶ acetabular dysplasia
- ▶ pelvic
- ▶ acetabular
- ▶ osteotomy
- ▶ subluxation
- ▶ dislocation
- ▶ Salter
- ▶ Pemberton
- ▶ Dega
- ▶ San Diego

EFORT Open Reviews
(2022) 7, 153–163

Introduction

Surgical correction of idiopathic developmental dysplasia of the hip (DDH) is one of the most challenging problems in pediatric orthopedic surgery. The treatment goal is to achieve a stable, congruent and concentric hip joint as early as possible, which in turn will preclude or postpone the development of degenerative osteoarthritis (OA) of the hip (1, 2). Despite extensive long-term studies, controversy still exists in all realms of surgical treatment of DDH (3, 4). As far as the acetabular side procedures are concerned, ambiguity still exists regarding the remodeling capacity of acetabulum, ideal age for pelvic osteotomy (PO), type of PO, safety and long-term radiological and clinical outcomes of each type of osteotomy.

The choice of treatment for DDH is age-dependent (5). Even after successful reduction of the hip joint, the remodeling capacity of the acetabulum decreases with age, leading to residual dysplasia, late subluxation or

dislocation. It is believed that in DDH, if the treatment is not started before weight-bearing, the prognosis is poor for the satisfactory development of hip joint by any of the conservative methods (6). Pemberton stated that 'in the treatment of DDH in a child 1 year and older, surgical correction by direct attack on the acetabulum is a more conservative and dependable method of treatment than so-called conservative methods' (7).

The upper age limit of acetabular remodeling is 4 years, and beyond this, the correction of acetabular dysplasia will need surgical intervention in the form of PO. Spence *et al.* compared 38 patients who underwent open reduction (OR) and femoral osteotomy (FO) with 33 patients who underwent OR and PO in children aged 15 months to 4 years. Patients with PO had quicker and better improvement in the radiographic acetabular index and thus concluded that PO was more effective in improving acetabular dysplasia than FO (8).

Although PO is a powerful tool for improving radiographic parameters in DDH, it may not be necessary for all patients (5). In the age group between 18 months and 4 years, the need for a PO is decided based on the degree of acetabular dysplasia in serial radiographs over 6 months to 1 year. Persistent acetabular dysplasia with the subluxation is an absolute indication for a PO. This article presents a review of various reconstructive POs, indications for each, a brief technical description and their outcomes and complications. We also present simple guidelines to choose the right type of PO for a given patient.

Why is a pelvic osteotomy needed in DDH?

Until infancy, concentric reduction of the femoral head into the acetabulum through closed or open method is generally sufficient to get reciprocal remodeling to achieve a stable and congruent hip. Past infancy, most surgeons agree that treatment with a PO, with or without a FO, is indicated to ensure adequate femoral head coverage (9). Although the minimum age at which a PO should be performed is still controversial, it is generally accepted that DDH in a child above walking age will most likely need a PO (10).

Pemberton stated that the 'structural defect in the anterior acetabulum is a constant finding in DDH, and surgical correction of dysplasia should include correction of this defect' (6). An ideal PO should address the anatomical deficiency of the acetabulum to improve the femoral head coverage. However, the dictum of constant anterolateral acetabular deficiency in DDH is now debatable. Analysis of acetabular morphology using 3D CT demonstrates that the acetabular deficiency in DDH can occasionally be directly lateral or posterior superior (11, 12). This reveals that acetabular dysplasia is more complex than it is generally believed to be. More than localized defect or hypoplasia, acetabular dysplasia is a combination of mal-direction, marginal erosion, hypoplasia (localized or global), abnormal shape and decreased acetabular surface area (13). This emphasizes the fact that one single type of PO would not suffice to address the entire spectrum of acetabular deficiency. It cannot be overemphasized that the primary goal of any PO is only to improve the femoral head coverage and stability and not to obtain a reduction of the joint. Essentially, the hip must be well reduced before any reconstructive PO is undertaken.

When should a pelvic osteotomy be done in DDH?

There is a well-established correlation between age at reduction and residual dysplasia. Lindstrom *et al.*

have shown that the acetabular index (AI) at follow-up is directly related to the age at an initial reduction (14). Salter and Dubos have stated that acetabular remodeling cannot be ensured after the age of 18 months (15). Others have suggested that remodeling may occur up to 8 years. Remodeling of the acetabulum is considered to be most predictable in children younger than 4 years. The risk of producing a dysplastic acetabulum will be doubled if the hip is not reduced by this age (16).

In general, for children up to 12–18 months, though OR is needed to get a concentric reduction, PO is rarely required considering remodeling potential. Between 18 months and 4 years, the need for a PO at the time of OR is controversial (17, 18, 19). One school of thought is to delay the acetabular procedure, assess the adequacy of the remodeling and decide based on serial follow-up radiographs. However, Salter and Pemberton strongly believed in adding the acetabular procedure at the time of primary treatment to maximize the likelihood of normal acetabular development. DelBello *et al.* compared the results of OR alone, OR followed by delayed PO and OR plus immediate PO in a group of older children with DDH. Only the immediate osteotomy group achieved acetabular indices comparable to those in normal control subjects. Based on these findings, the authors recommended routine PO at the time of OR for all patients over the age of 18 months (20). In children 4 years or older, the PO is performed routinely because of the unpredictable remodeling potential. In children older than 8 years, the need for intervention is based on the symptoms, severity of the dysplasia and laterality. An acetabular side procedure will always be needed if the patient is planned for surgical intervention.

Overview of pelvic osteotomies

The pelvic osteotomies can be broadly grouped into three types: (1) re-directional osteotomies (Salter's triple, periacetabular osteotomy and spherical osteotomy), (2) reshaping osteotomies (Pemberton, Dega and San Diego) and (3) salvage procedures (Chiari and shelf – not detailed in this review). If the hip joint can be concentrically reduced by either closed or open reduction, reconstructive POs are indicated. If a concentric reduction is not possible by any described methods, salvage procedures are opted.

Radiological assessment

Complete radiographic evaluation of the hip is essential before any hip osteotomy. It includes a standardized pelvis anteroposterior (AP) view, frog-leg lateral view, false-profile view and functional radiographs (abduction internal rotation, flexion abduction and adduction

views) to determine the severity of acetabular dysplasia and deformity of the proximal femur. AP view should be assessed for a break in Shenton’s line, the appearance of acetabular sourcil, teardrop morphology, AI, center-edge angle of Wiberg (CEA), extrusion index and congruency of the hip joint. A widened teardrop with loss of the concavity of its lateral aspect characterizes hip subluxation or dislocation. Standard radiographic acetabular indices in different age groups are shown in Fig. 1 (21, 22). The standard pelvic radiographs do not differentiate anterior, superior or posterior deficiency. As acetabular dysplasia is more than a simple malrotation or anterolateral deficiency, a 3D CT greatly helps determine an individual hip's exact morphology and plan for an osteotomy specifically to correct the defect (21). Though not routinely done, in young children, analysis with 3D MRI gives a true morphology of a cartilaginous acetabulum.

Standard anterior surgical approach

All POs described for DDH can be performed through a single standard anterior approach. We prefer an anterior bikini incision, which is more cosmetic and versatile. Proximally, the iliac apophysis is elevated to expose the inner and outer iliac table and distally, the Smith–Peterson interval is utilized. To protect the lateral femoral cutaneous nerve, the fascia over tensor fascia lata (TFL) is incised rather than the traditional approach between Sartorius and TFL. The rectus femoris can either be released (if an

OR is needed) or retracted laterally (rectus sparing approach prevents hip flexion weakness). The inner iliac table is elevated subperiosteally up to the sciatic notch. In the outer table, the abductors are tunneled (rather than complete elevation) in line with the desired osteotomy up to the sciatic notch (abductor-sparing approach).

For all acetabuloplasty procedures, care should be taken to protect the sciatic nerve and the superior gluteal neurovascular bundle in the greater sciatic notch by placing the blunt retractors subperiosteally in the notch (23). Pemberton, Dega, San Diego and Salter osteotomies need a bone graft (iliac autograft, graft from femur osteotomy or allograft) to hold the correction. Salter’s osteotomy, triple PO and periacetabular osteotomies are unstable and need internal fixation.

Re-directional osteotomies

These are complete innominate osteotomies, which can reorient the acetabulum to improve anterolateral coverage without change in size or shape of the acetabulum.

Salter innominate osteotomy (SIO)

In 1961, Salter first described a complete innominate osteotomy for stabilizing the reduced hip by redirection of the entire acetabulum. The pubic symphysis serves as a rotating hinge, and the acetabulum is redirected to cover the anterolateral deficiency (24).



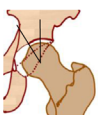
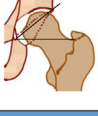
	Radiological Index	Normal hip		Dysplastic hip	
		Boys	Girls	Boys	Girls
	Before skeletal maturity				
	Acetabular index at 3-months	22°±4°	25°±3.5°	≥27°	≥29°
	Acetabular index at 24-months	19°±3.6°	18°±3.5°	≥24°	≥23°
	After skeletal maturity				
	Tonnis angle (acetabular roof angle)	3-13°		>14°	
	Lateral center-edge angle	22-33°		<22°	
	Medial center-edge angle	35-44°		>45°	
	Acetabular arc	61-65°		<60°	
	Sharp’s angle	38-42°		>43°	
	Extrusion Index	17-27%		>27%	

Figure 1
Radiographic indices for normal and dysplastic hips.

The primary indication for an SIO is an anterolateral acetabular deficiency in an otherwise concentrically reduced hip. A shallow acetabulum is a relative contraindication. SIO is indicated between 18 months and 8 years of age, beyond which the correction could be suboptimal due to rigidity of symphysis. However, the best results are shown in <4 years of age. The most common error that leads to a poor outcome is failure to achieve a concentric reduction of the hip joint before innominate osteotomy.

The SIO is a transverse iliac osteotomy from just above the anterior inferior iliac spine (AIIS), extending to the sciatic notch (Fig. 2A). The distal acetabular fragment is manipulated by a pointed clamp to hinge on the pubic symphysis and provided anterior and/or lateral translation. A triangular wedge of bone is cut from the iliac crest and placed into the osteotomy site and fixed with two- or three-threaded K-wires (Fig. 2B).

Salter *et al.* reported 93.6% excellent to good results in patients operated from 18 months to 4 years of age with no failures in a review of 15-year follow-up on 140 patients. In the 4–10-year age group, only 56.7% achieved excellent to good results, and the failure rate was 6.6% (15). The reported complications include avascular necrosis (AVN) (5.7%), loss of correction (2.8%), re-dislocation (5.6%), sciatic nerve palsy and acetabular retroversion. Overcorrection can lead to retroversion of the acetabulum and posterior insufficiency. Posterior subluxation of the

femoral head, especially when combined with femur osteotomy, was reported in a series by Dora *et al.* (25). The SIO is not recommended in older children, albeit few reports of its successful application in the older age group as well (26, 27).

Thomas *et al.* reported the survivorship of SIO at 45 years as 54% and said that bilateral dysplasias were associated with poor outcomes (28). Bohm *et al.* reported overall survivorship of 90% following SIO at an average of 30 years of follow-up (29). Kobayashi *et al.* reviewed long-term radiographic results of SIO and found that the osteotomy does not consistently result in acetabular retroversion into adulthood (30).

Triple pelvic osteotomy (TPO)

TPO is a complete reorientation osteotomy described to overcome the drawbacks of the SIO. A prerequisite of the operation is a congruous joint or a joint that would become congruous by the osteotomy. The primary indications are in older children and adolescents with open TRC, where other POs are inadequate or counterproductive and also where the acetabulum requires a change in the version. Sufficient hip abduction (20–30) should be present to allow lateral rotation of the acetabulum. The drawbacks of TPO are it violating the posterior column and creating pelvic discontinuity. It is an unstable osteotomy requiring rigid fixation and immobilization. It leads to pelvic asymmetry and affects the birth canal negating the possibility of a normal vaginal delivery.

The TPO technique continues to evolve since its original description by Le Coeur in 1965 (31). The main limitation of this original technique is that the sacrospinous ligament remains attached to the mobile fragment and can lead to retroversion of the acetabular fragment. Steel modified Le Coeur’s TPO to divide the ischium through an incision in the gluteal region (32). Many modifications of the TPO are described with changes at the level of the ischial cut and the type of the iliac cut (33, 34, 35, 36) (Fig. 2C and D).

In Tonnis TPO, ischial cut is made in a prone position just below the acetabulum exiting proximal to the ischial spine. The proposed advantages are less compromise in pelvic stability, greater mobility of the acetabular fragment for lateral rotation and medial displacement, avoiding the possibility of retroversion (33). The Bernese TPO is done through a single anterior incision, and the cuts are similar to Tonnis TPO. It is important to stay extra-periosteal to avoid injury to the tri-radiate cartilage. A modification of Bernese TPO is described in which the ischial cut is done through a medial incision (36, 37). Lipton’s modified TPO and interlocking type TPO are modifications of the iliac cut to increase the stability and contact of the osteotomy (34, 35, 38) (Fig. 2D).

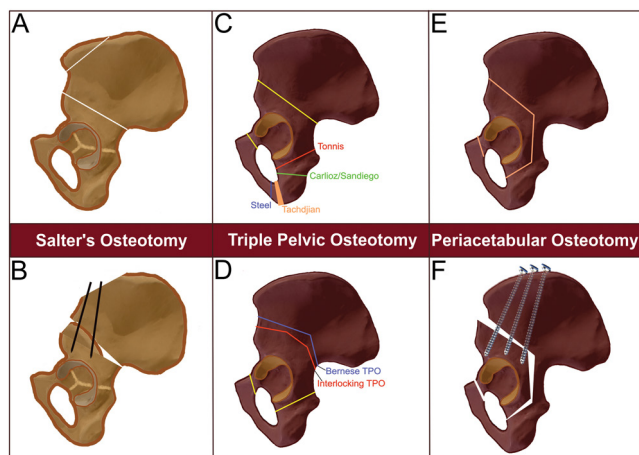


Figure 2 Re-directional osteotomies. (A) Salter’s innominate osteotomy as viewed from the lateral aspect of the ilium. (B) Iliac graft placed anteriorly to keep the osteotomy site open and stabilized with K-wires. (C) Triple pelvic osteotomy – modification of ischial cuts in Steel’s (blue line), Tachdjian’s (orange wedge), Carlioz/San Diego (green line) and Tonnis TPO (red line). (D) Triple pelvic osteotomy – modification of iliac cuts in Bernese TPO (blue line) and interlocking TPO (red line). (E) Bernese PAO – osteotomy lines as viewed from the lateral aspect of the ilium. (F) Bernese PAO – osteotomy following correction and screw fixation.

Bernese periacetabular osteotomy

Ganz *et al.* in 1988 described a complete reorientation osteotomy with bone cuts made close to the acetabulum that can allow for the maximum correction of version, lateral and anterior coverage (39). The primary indication is to improve the congruency and coverage of hip with acetabular dysplasia in patients with closed TRC.

The Bernese peri-acetabular osteotomy (PAO) technique has been described in detail and has not changed significantly over time (39). Most surgeons use a single anterior approach that spares the abductor muscles, performing the osteotomies from the inner aspect of the pelvis. These include an incomplete osteotomy of the ischium, a complete osteotomy of the pubis and a biplanar osteotomy of the ilium. The continuity of the posterior column of the acetabulum is maintained (Fig. 2E and F). The intact posterior column makes this osteotomy very stable, and postoperative immobilization is not required. Additional advantages include preserving the blood supply to the acetabular fragment and preserving the shape of the pelvis, which permit normal vaginal delivery. The major disadvantage is the technical difficulty and steep learning curve.

Siebenrock *et al.* reported the long-term results in 71 of the 75 hips initially reported by Ganz. At a mean follow-up of 11.3 years, the hip joint was preserved in 82% of the patients, with good to excellent results in 73%. The remaining patients required salvage procedures at an average of 6.1 years. The factors associated with

an unfavorable outcome were older age at the time of surgery, moderate to severe pre-operative arthritis, an associated labral lesion, less anterior coverage correction and suboptimal postoperative radiological indices (40).

Reshaping osteotomies

Reshaping osteotomies are incomplete innominate osteotomies in which the acetabular roof is bent down to increase the coverage at the desired place of deficiency. These are rightly called ‘acetabuloplasties’ and are inherently stable, which doesn’t require fixation (Fig. 3).

Pemberton pericapsular osteotomy (PPO) (anterolateral acetabuloplasty)

Paul A Pemberton described a pericapsular osteotomy for DDH in 1965, one of the most popular acetabuloplasties (6). It is recommended in a child >1 year of age or who has started walking. As this technique depends on the plasticity of TRC, it can be done up to 12–14 years, after which the triradiate will become too rigid (6). The hinging occurs at TRC till 4 years of age and in older children, along with hinging at TRC, rotation also occurs at the symphysis and sacroiliac joint.

In this, a bicortical iliac osteotomy is done, which starts just above the AIIS and goes into the posterior column of acetabulum halfway between the sciatic notch and posterior acetabular rim and stops short of the ilio-ischial ramus of the TRC. The osteotomy is curvilinear, parallel to and approximately 1 cm above the joint capsule (Fig. 4).

Pemberton reported good results in 94.3% cases, and the AVN rate was 10.4%, most of which were Kalamchi type-II with typical findings of coxa valga (6). Wu *et al.* studied the effect of an isolated PPO on rates of AVN in patients who underwent only an OR with no FO. In 49 patients who were followed for >10 years, 51% had some AVN and 37% had clinically relevant AVN. They have reported that more distal positioning of the femoral head after the PO is an independent risk factor for AVN (41). Careful surgical release of soft-tissue contractures, avoiding negative AI, femoral shortening and avoidance of cast immobilization with the hip in an extreme position are believed to reduce the incidence of AVN effectively.

Ali Aydin, in 2012, reported results of OR and PPO in 91 hips with a mean age of 34 months. In their series, type-1 AVN was seen in 9.9%, type-2 in 7.7% and type-3 in 1.1% and one had type-4 AVN. They observed that complication rate increased in patients with Tonnis type-4 hip dislocation, in patients over 3 years and in cases where a second surgery was necessary (42). Wada *et al.* reported excellent and good results with PPO in 82.3% of

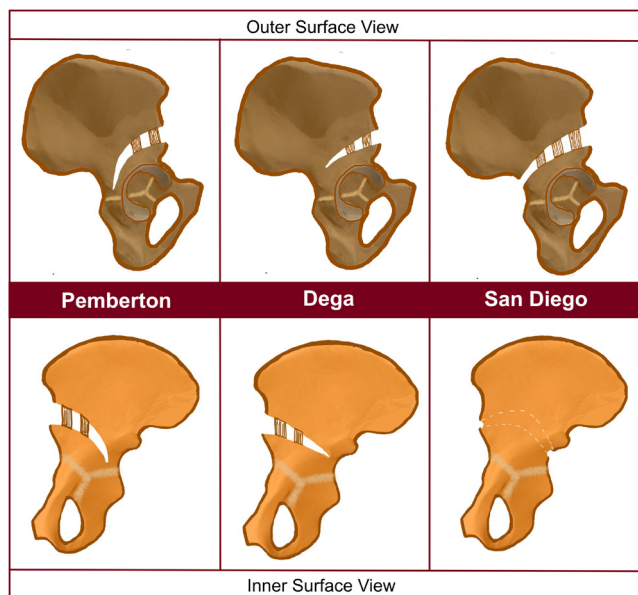


Figure 3
Reshaping osteotomies (right – Pemberton, middle – Dega, left – San Diego). Osteotomies as viewed from the outer surface (upper row) and inner surface (lower row) of the ilium.

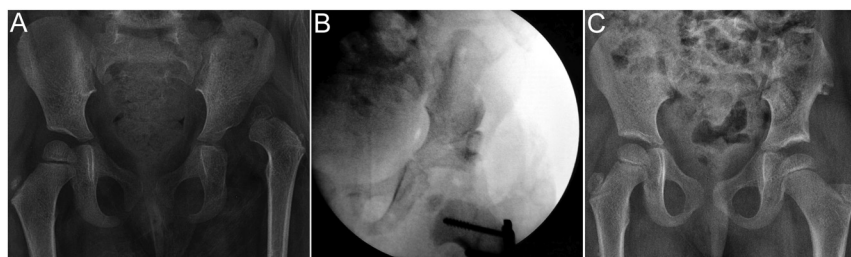


Figure 4

Case example of Pemberton osteotomy in a 3-year and 8-month-old female child with left side DDH. (A) AP pelvic radiograph showing left hip dislocation with an AI of 37.3°. (B) Intraoperative image intensifier view of the Pemberton acetabuloplasty of the left hip. (C) At 34 months following OR, Pemberton osteotomy and femur shortening osteotomy of left hip, AP pelvic radiograph showing good femoral head coverage and an AI and CEA of 15° and 20°, respectively.

17 hips, all over 7 years of age (43). Wang *et al.* compared radiographic results of SIO and PPO at >10-year follow-up and found that patients with PPO had improved anterior acetabular coverage. The functional outcomes were good and equivalent with both osteotomies (44).

Dega osteotomy (lateral acetabuloplasty)

Wiktor Dega briefly described a transiliac osteotomy in 1964 in German literature, followed by a detailed description of his technique in 1974 in Polish (45, 46). In his initial report, Dega described the supra-acetabular semicircular osteotomy as a true lateral bending acetabuloplasty in which the inner table of the ilium was completely intact. However, in the later publication in 1974, he modified the technique in which the inner table of the ilium was cut in the anterior two-thirds. The first detailed description of the technique in English literature was published in 2001 by Grudzaik *et al.* (47).

The osteotomy begins anteriorly on the interspinous ridge between the ASIS and AIIS. The orientation of the osteotomy is curvilinear when viewed from the lateral cortex, starting just above the AIIS, curving gently cephalad and posteriorly (curves at the midpoint of the acetabulum) to end approximately 1–1.5 cm in front of the sciatic notch. The osteotomy is bicortical anteriorly, and a variable amount of posteromedial cortex of the inner table of the pelvis in front of the sciatic notch is left intact. A lamina spreader is used to open the osteotomy in a desirable direction. Bone graft is shaped according to the gap at the osteotomy site, and a larger graft is placed anteriorly than posteriorly to get more anterior coverage (Figs 3 and 5). Theoretically, it is possible to change the graft size and placement, the extent of inner iliac cortical cut and the size of acetabular fragment based on whether the patient has an anterior or lateral deficiency, thus making it a versatile osteotomy that can both reorient and reshape the acetabulum.

Czubak *et al.* in 2018 reported the outcomes of OR, femur osteotomy and Dega osteotomy in 52 hips with a mean age of 3.9 years (1.2–12.8). The AI was corrected

to normal in all hips. AVN was seen in 5.8% of hips and coxa magna in one hip (48). Karlen *et al.* in 2009 reported results of Dega osteotomy in 26 hips, with an overall complication rate of 19% and AVN in 7.6% hips. The incidence of reoperation rate in their series was 3.8% (49). Ming-Hua *et al.* in 2016 reported the outcomes of modified high-level Dega osteotomy in 162 patients, between 1.5 and 6 years of age. They reported a favorable and good outcome in >90% of hips where the mean AI changed from 38.0° to 20.8° and the mean CE angle increased from –10.7° to 29.4° after the intervention (50).

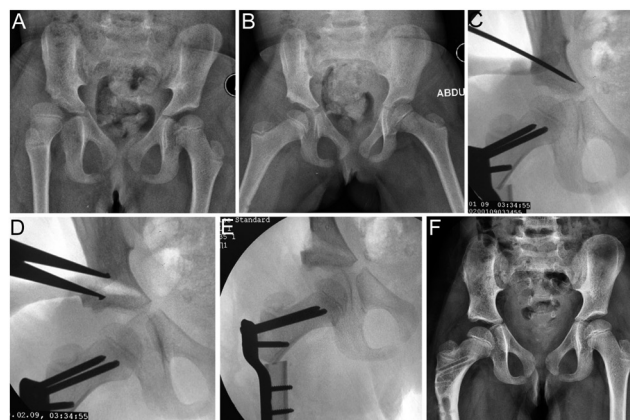


Figure 5

Case example of Dega osteotomy. (A) AP pelvic radiographs of 2-year and 8-month-old female child who presented with subluxation and residual dysplasia after open reduction of the right hip 2 years ago. (B) Abduction and internal rotation view showing good containment of right hip. (C) After femoral varus derotation osteotomy showing the osteotome making the cut for Dega's osteotomy. (D) Intraoperative image intensifier view after opening the osteotomy with a lamina spreader showing good correction of the dysplasia. (E) Intraoperative image intensifier view after placement of the graft showing a well-reduced hip joint with good coverage. (F) Pelvis with both hips AP view done at 14 months following right side Dega osteotomy and proximal femur osteotomy showing well-reduced hip joint with normal AI.

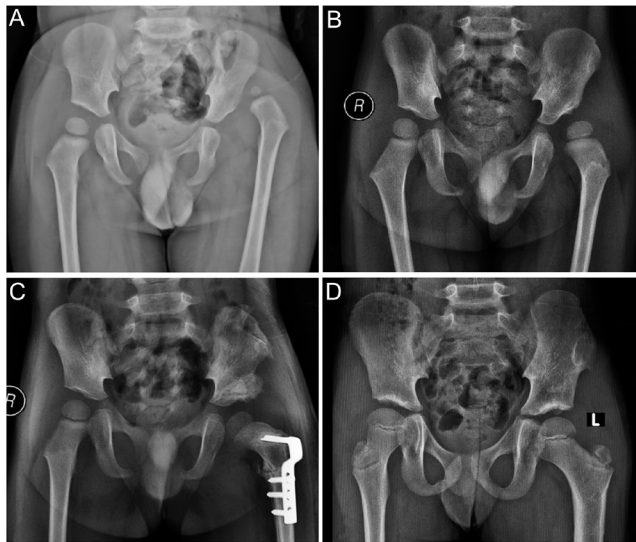


Figure 6
Case example demonstrating San Diego osteotomy. (A) AP pelvic radiograph of a 1-year-old boy presenting with left hip dislocation. (B) One-year follow-up radiograph after open reduction showing residual acetabular dysplasia with AI of 38.9° and CEA of 0°. (C) Radiograph at 3 months following San Diego osteotomy and proximal femur varus derotation osteotomy of the left hip showing restoration of Shenton’s arc and AI. (D) Pelvis radiograph at 5-year follow-up showing a concentric reduction of the left hip with an AI of 13.7° and CEA of 30°.

Modified San Diego acetabuloplasty

Mubarak *et al.* modified Dega’s osteotomy to improve the lateral and posterior coverage of the acetabulum (51). This modified Dega osteotomy, known as San Diego acetabuloplasty, was designed initially for hip dysplasia secondary to neuromuscular disease, where the deficiency is predominantly posterosuperior or

direct lateral compared to the anterolateral deficiency seen in DDH (11). Later, it was expanded to treat idiopathic DDH with anterior and anterolateral deficiency (52).

The main difference between the Dega acetabuloplasty and the San Diego acetabuloplasty is that in the latter the inner cortex of the ilium is completely intact except anteriorly and posteriorly, where it is bicortical at the AIIS and sciatic notch respectively. The acetabulum is hinged on the anterior and posterior limbs of the TRC, and bone grafts are utilized to wedge the osteotomy open (Figs 3 and 6). The unicortical osteotomy allows the surgeon to alter the shape of the acetabulum specifically to address the deficiency simply by changing the size and placement of the bone grafts. Three unequal-sized triangular bone wedges are used, and when the largest graft is placed anteriorly, it increases the anterolateral coverage (52). Placing the largest graft posteriorly increases the posterior coverage.

Badrinath *et al.* in 2019 compared the results of PPO with modified San Diego in DDH and showed comparable clinical and radiographic outcomes. The proposed advantage is that the acetabular reshaping can be customized to address a specific acetabular deficiency (52).

Which pelvic osteotomy to choose for a patient?

The choice of PO depends on the morphological abnormality in the acetabulum and the magnitude of correction needed to normalize it. We can broadly categorize acetabular dysplasia’s into two different types as follows:

- 1) Primary dysplasia – acetabular deficiency in an untreated DDH

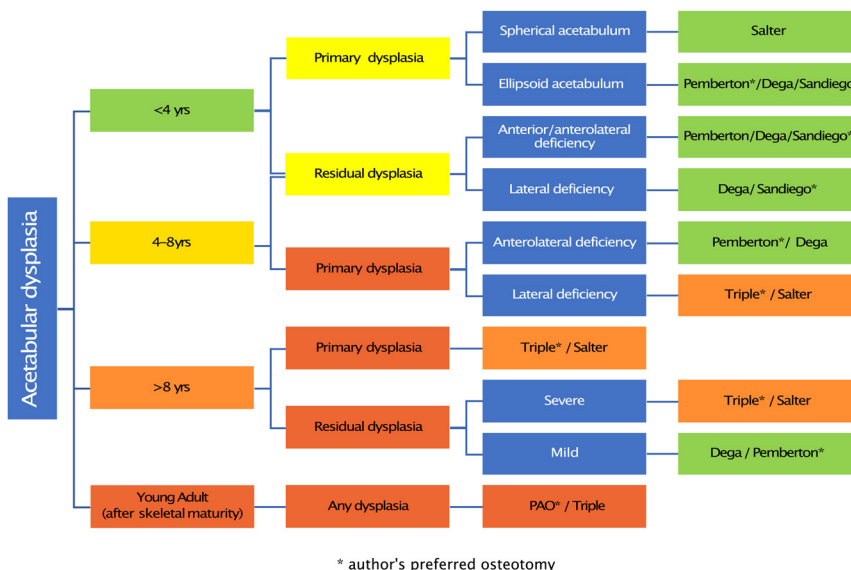


Figure 7
Authors’ algorithm to choose a pelvic osteotomy based on patient’s age, type of dysplasia, the shape of the acetabulum and the status of the triradiate cartilage.

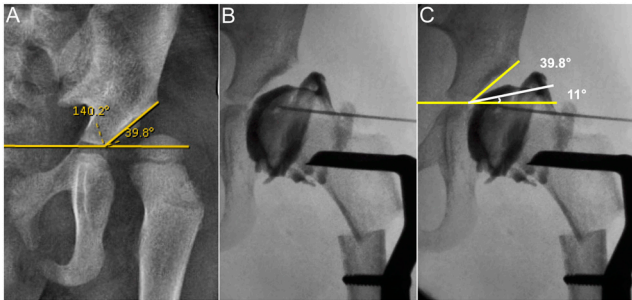


Figure 8

(A) Preoperative radiograph of an 18-month-old girl with subluxation and dysplasia of the left hip with an AI of 39.8° indicating the need for a pelvic osteotomy. (B) Intraoperative image intensifier view of the arthrogram after femoral varus derotation osteotomy showing the cartilaginous acetabular roof. (C) The cartilaginous AI measuring 11° in the same view.

2) Residual dysplasia – the dysplasia in a treated DDH (both closed and open reduction)

In general, the amount of correction needed is less in residual dysplasia compared to primary dysplasia. The other factor which influences the magnitude of correction required is the age at which the patient presents. We can divide this into four different age groups: (1) <4 years, (2) 4–8 years, (3) >8 years (up to TRC closure) and (4) young adults (after skeletal maturity). As the age advances, reshaping acetabuloplasties hinging through the cartilage becomes challenging and getting a massive correction may not be possible. The authors' preferred approach to choose a PO is shown in the algorithm (Fig. 7).

Acetabular dysplasia in <4 years

In children less than 4 years with primary dysplasia, the type of PO is decided based on the acetabular shape and location of deficiency. In this age group, the AI measured

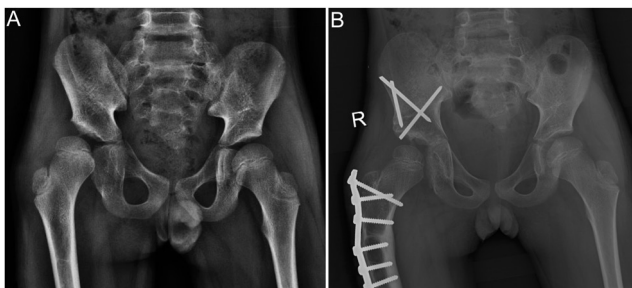


Figure 9

(A) An 8-year-old boy with right side residual acetabular dysplasia with an AI of 30.4° (OR and FO done at 20 months of age) with lateral uncoverage. (B) AP pelvic radiograph 14 months following TPO and proximal femur varus osteotomy showing good femoral head coverage with an AI of 21.1°.

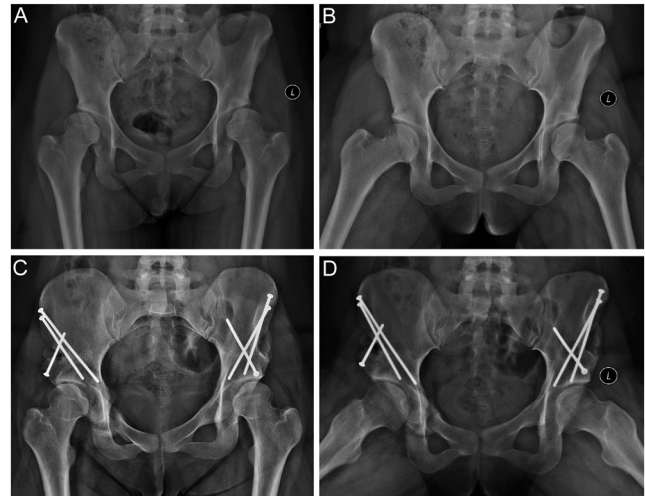


Figure 10

An 18-year-old female with bilateral acetabular dysplasia treated with PAO. (A) AP pelvic radiograph with discontinuity in Shenton's line on both hips, with an acetabular roof angle of 18.2° on the right side and 19.9° on the left side. (B) The abduction internal rotation view showed a congruent reduction of bilateral hips. (C and D) At 14 months following bilateral PAO, AP and frog-leg lateral pelvic radiographs showing bilateral congruent hip joints with a roof angle of 5.8° and 7.1° on the right and left side, respectively.

on the X-ray may not be accurate as part of the acetabular cartilage is unossified. The authors prefer to measure the cartilaginous AI with intra-operative arthrogram (Fig. 8). The shape of the normal acetabulum is hemispherical, and the anterior wall is about half of the posterior wall. In untreated dysplasia, weight-bearing and walking gradually lead to a change in the shape of the acetabulum from hemispherical to ellipsoidal. If the acetabulum is spherical and there is an anterior or anterolateral deficiency, an SIO is indicated. A Pemberton or Dega type of acetabuloplasty in this scenario can lead to inferior subluxation of the head. If the acetabulum is shallow and ellipsoidal, any kind of reshaping acetabuloplasty (Pemberton, Dega, San Diego) may be performed.

In those children with residual dysplasia in this group (typically seen during follow-up visits after closed/open reduction), the acetabulum is invariably shallow and ellipsoidal, and a reshaping acetabuloplasty is indicated.

Acetabular dysplasia in 4–8 years

Residual dysplasia in this age group is often mild as the hip is enclosed and can be tackled with reshaping acetabuloplasty procedures.

Primary dysplasia in this age group could be challenging as often the degree of dysplasia is severe.

The classical San Diego type of acetabuloplasty may not be adequate as it is unicortical, limiting the amount of correction one could achieve. Similarly, the classical Dega type osteotomy is also limited by the intact posterior part of the ilium.

The PPO, which is bicortical and extends up to the TRC, could provide enough correction for severe dysplasia, especially when the deficiency is anterolateral. However, the amount of lateral coverage that one could achieve is limited with PPO. Thus, in cases with severe lateral uncoverage, a re-directional osteotomy like TPO is the preferred choice by the authors (Fig. 9). There are a few reports of the use of SIO in this age group as well.

Acetabular dysplasia >8 years

Mild residual dysplasias in this age group are amenable for correction with Pemberton or Dega type osteotomy. The severe residual dysplasias and all primary dysplasias will need a re-directional osteotomy, and TPO is the preferred choice. Theoretically, an SIO can be done in this age group and the authors do not have any personal experience with this.

Acetabular dysplasia in young adults (after skeletal maturity)

Irrespective of the type of dysplasia, in this age group, the preferred PO is the Bernese PAO which is a powerful tool to correct even severe dysplasias (Fig. 10). However, the PAO is technically challenging, requires specialized osteotomes and instruments, and hence a TPO is a worthy alternative in this age group which equally gives good correction.

Conclusion

PO is an essential part of the surgical management of hip dysplasia, and the literature is loaded with various types with modifications. A thorough understanding of the principles of pelvic osteotomies is essential to choose the right intervention for the right patient. The guidelines provided based on the type of dysplasia, the age of the patient and the status of the tri-radiate cartilage help in choosing the right type of PO. With the advent of the 3D technology in the field of orthopedics, in future, 3D planning and printing may be of immense use in planning and executing these complex osteotomies.

ICMJE Conflict of Interest Statement

The authors declare that there is no have conflict of interest that could be perceived as prejudicing the impartiality of this study.

Funding Statement

This work did not receive any specific grant from any funding agency in the public, commercial, or not-for-profit sector.

References

- Gillingham BL, Sanchez AA & Wenger DR.** Pelvic osteotomies for the treatment of hip dysplasia in children and young adults. *Journal of the American Academy of Orthopaedic Surgeons* 1999 **7** 325–337. (<https://doi.org/10.5435/00124635-199909000-00005>)
- Hadley NA, Brown TD & Weinstein SL.** The effects of contact pressure elevations and aseptic necrosis on the long-term outcome of congenital hip dislocation. *Journal of Orthopaedic Research* 1990 **8** 504–513. (<https://doi.org/10.1002/jor.1100080406>)
- Guille JT, Pizzutillo PD & MacEwen GD.** Developmental dysplasia of the hip from birth to six months. *Journal of the American Academy of Orthopaedic Surgeons* 2000 **8** 232–242. (<https://doi.org/10.5435/00124635-200007000-00004>)
- Vitale MG & Skaggs DL.** Developmental dysplasia of the hip from six months to four years of age. *Journal of the American Academy of Orthopaedic Surgeons* 2001 **9** 401–411. (<https://doi.org/10.5435/00124635-200111000-00005>)
- Murphy RF & Kim YJ.** Surgical management of pediatric developmental dysplasia of the hip. *Journal of the American Academy of Orthopaedic Surgeons* 2016 **24** 615–624. (<https://doi.org/10.5435/JAAOS-D-15-00154>)
- Pemberton PA.** Pericapsular osteotomy of the ilium for treatment of congenital subluxation and dislocation of the hip. *Journal of Bone and Joint Surgery: American Volume* 1965 **47** 65–86. (<https://doi.org/10.2106/00004623-196547010-00004>)
- Pemberton PA.** Pericapsular osteotomy of the ilium for the treatment of congenitally dislocated hips. *Clinical Orthopaedics and Related Research* 1974 **98** 41–54. (<https://doi.org/10.1097/00003086-197401000-00007>)
- Spence G, Hocking R, Wedge JH & Roposch A.** Effect of innominate and femoral Varus derotation osteotomy on acetabular development in developmental dysplasia of the hip. *Journal of Bone and Joint Surgery: American Volume* 2009 **91** 2622–2636. (<https://doi.org/10.2106/JBJS.H.01392>)
- Huang SC & Wang JH.** A comparative study of nonoperative versus operative treatment of developmental dysplasia of the hip in patients of walking age. *Journal of Pediatric Orthopedics* 1997 **17** 181–188. (<https://doi.org/10.1097/00004694-199703000-00009>)
- Chen C, Wang T-M & Kuo KN.** Pelvic osteotomies for developmental dysplasia of the hip. In *Developmental Diseases of the Hip – Diagnosis and Management*. Ed **D Spasovski**. InTech, 2017. (<https://doi.org/10.5772/67516>)
- Kim HT & Wenger DR.** Location of acetabular deficiency and associated hip dislocation in neuromuscular hip dysplasia: three-dimensional computed tomographic analysis. *Journal of Pediatric Orthopedics* 1997 **17** 143–151. (<https://doi.org/10.1097/00004694-199703000-00002>)
- Kim SS, Frick SL & Wenger DR.** Anteversion of the acetabulum in developmental dysplasia of the hip: analysis with computed tomography. *Journal of Pediatric Orthopedics* 1999 **19** 438–442. (<https://doi.org/10.1097/00004694-199907000-00004>)
- Wedge JH.** Editorial: Hip joint acetabular dysplasia. *Journal of Pediatric Orthopedics* 1997 **17** 142.
- Lindstrom JR, Ponseti IV & Wenger DR.** Acetabular development after reduction in congenital dislocation of the hip. *Journal of Bone and Joint Surgery: American Volume* 1979 **61** 112–118. (<https://doi.org/10.2106/00004623-197961010-00020>)

- 15. Salter RB & Dubos JP.** The first fifteen year's personal experience with innominate osteotomy in the treatment of congenital dislocation and subluxation of the hip. *Clinical Orthopaedics and Related Research* 1974 **98** 72–103. (<https://doi.org/10.1097/00003086-197401000-00009>)
- 16. Harris NH.** Acetabular growth potential in congenital dislocation of the hip and some factors upon which it may depend. *Clinical Orthopaedics and Related Research* 1976 **119** 99–106. (<https://doi.org/10.1097/00003086-197609000-00016>)
- 17. Farsetti P, Caterini R, Potenza V & Ippolito E.** Developmental dislocation of the hip successfully treated by preoperative traction and medial open reduction: a 22-year mean followup. *Clinical Orthopaedics and Related Research* 2015 **473** 2658–2669. (<https://doi.org/10.1007/s11999-015-4264-3>)
- 18. Powell EN, Gerratana FJ & Gage JR.** Open reduction for congenital hip dislocation: the risk of avascular necrosis with three different approaches. *Journal of Pediatric Orthopedics* 1986 **6** 127–132. (<https://doi.org/10.1097/01241398-198603000-00001>)
- 19. Kothari A, Grammatopoulos G, Hopewell S & Theologis T.** How does bony surgery affect results of anterior open reduction in walking-age children with developmental hip dysplasia? *Clinical Orthopaedics and Related Research* 2016 **474** 1199–1208. (<https://doi.org/10.1007/s11999-015-4598-x>)
- 20. DelBello D, Nattrass G, Moseley C & Watts HG.** Acetabular development after open reduction in developmental dysplasia of the hip: the role of concurrent innominate osteotomy. *Orthopaedic Trans* 1995 **19** 298.
- 21. Scoles PV, Boyd A & Jones PK.** Roentgenographic parameters of the normal infant hip. *Journal of Pediatric Orthopedics* 1987 **7** 656–663. (<https://doi.org/10.1097/01241398-198707060-00005>)
- 22. Wiberg G.** Studies on dysplastic acetabula and congenital subluxation of the hip joint: with special reference to the complication of osteoarthritis. *Acta Chirurgica Scandinavica, Supplement* 1939 **83** 58.
- 23. Selberg CM, Chidsey B, Skelton A & Mayer S.** Pelvic osteotomies in the child and young adult hip: indications and surgical technique. *Journal of the American Academy of Orthopaedic Surgeons* 2020 **28** e230–e237. (<https://doi.org/10.5435/JAAOS-D-19-00223>)
- 24. Salter RB.** Innominate osteotomy in the treatment of congenital dislocation and subluxation of the hip. *Journal of Bone and Joint Surgery: British Volume* 1961 **43-B** 518–539.
- 25. Dora C, Mascard E, Mladenov K & Seringe R.** Retroversion of the acetabular dome after Salter and triple pelvic osteotomy for congenital dislocation of the hip. *Journal of Pediatric Orthopedics: Part B* 2002 **11** 34–40. (<https://doi.org/10.1097/00009957-200201000-00006>)
- 26. Böhm P & Weber G.** Salter's innominate osteotomy for hip dysplasia in adolescents and young adults: results in 58 patients (69 osteotomies) at 4–12 years. *Acta Orthopaedica Scandinavica* 2003 **74** 277–286. (<https://doi.org/10.1080/00016470310014193>)
- 27. Schmidutz F, Roesner J, Niethammer TR, Paulus AC, Heimkes B & Weber P.** Can Salter osteotomy correct late diagnosed hip dysplasia: a retrospective evaluation of 49 hips after 6.7 years? *Orthopaedics and Traumatology, Surgery and Research* 2018 **104** 637–643. (<https://doi.org/10.1016/j.otsr.2018.05.004>)
- 28. Thomas SR, Wedge JH & Salter RB.** Outcome at forty-five years after open reduction and innominate osteotomy for late-presenting developmental dislocation of the hip. *Journal of Bone and Joint Surgery: American Volume* 2007 **89** 2341–2350. (<https://doi.org/10.2106/JBJS.F.00857>)
- 29. Böhm P & Brzuske A.** Salter innominate osteotomy for the treatment of developmental dysplasia of the hip in children: results of seventy-three consecutive osteotomies after twenty-six to thirty-five years of follow-up. *Journal of Bone and Joint Surgery: American Volume* 2002 **84** 178–186. (<https://doi.org/10.2106/00004623-200202000-00003>)
- 30. Kobayashi D, Satsuma S, Kinugasa M, Kuroda R & Kurosaka M.** Does Salter innominate osteotomy predispose the patient to acetabular retroversion in adulthood? *Clinical Orthopaedics and Related Research* 2015 **473** 1755–1762. (<https://doi.org/10.1007/s11999-014-4053-4>)
- 31. Le Cœur P.** Correction des défauts d'orientation de l'articulation coxofémorale par ostéotomie de l'isthme iliaque. *Revue de Chirurgie Orthopedique* 1965 **51** 211.
- 32. Steel HH.** Triple osteotomy of the innominate bone. *Journal of Bone and Joint Surgery: American Volume* 1973 **55** 343–350. (<https://doi.org/10.2106/00004623-197355020-00010>)
- 33. Tönnis D, Behrens K & Tscharan F.** A modified technique of the triple pelvic osteotomy: early results. *Journal of Pediatric Orthopedics* 1981 **1** 241–249. (<https://doi.org/10.1097/01241398-198111000-00001>)
- 34. Lipton GE & Bowen JR.** A new modified technique of triple osteotomy of the innominate bone for acetabular dysplasia. *Clinical Orthopaedics and Related Research* 2005 **434** 78–85. (<https://doi.org/10.1097/01241398-200207000-00010>)
- 35. Kumar D, Bache CE & O'Hara JN.** Interlocking triple pelvic osteotomy in severe Legg-Calvé-Perthes disease. *Journal of Pediatric Orthopedics* 2002 **22** 464–470. (<https://doi.org/10.1097/01241398-200207000-00010>)
- 36. Sankar WN.** Modified Bernese triple innominate osteotomy. In *Hip Arthroscopy and Hip Joint Preservation Surgery*, pp. 1–15. Eds S Nho, M Leunig, C Larson, A Bedi & B Kelly. New York, NY: Springer.
- 37. Rebello G, Zilkens C, Dudda M, Matheney T & Kim YJ.** Triple pelvic osteotomy in complex hip dysplasia seen in neuromuscular and teratologic conditions. *Journal of Pediatric Orthopedics* 2009 **29** 527–534. (<https://doi.org/10.1097/BPO.0b013e3181b2b3be>)
- 38. Mei-Dan O, Jewell D, Garabekyan T, Brockwell J, Young DA, McBryde CW & O'Hara JN.** The Birmingham Interlocking Pelvic Osteotomy for acetabular dysplasia: 13- to 21-year survival outcomes. *Bone and Joint Journal* 2017 **99-B** 724–731. (<https://doi.org/10.1302/0301-620X.99B6.BJJ-2016-0198.R3>)
- 39. Ganz R, Klaue K, Vinh TS & Mast JW.** A new periacetabular osteotomy for the treatment of hip dysplasias. Technique and preliminary results. *Clinical Orthopaedics and Related Research* 1988 **232** 26–36. (<https://doi.org/10.1097/00003086-198807000-00006>)
- 40. Siebenrock KA, Schöll E, Lottenbach M & Ganz R.** Bernese periacetabular osteotomy. *Clinical Orthopaedics and Related Research* 1999 **363** 9–20. (<https://doi.org/10.1097/00003086-199906000-00003>)
- 41. Wu KW, Wang TM, Huang SC, Kuo KN & Chen CW.** Analysis of osteonecrosis following Pemberton acetabuloplasty in developmental dysplasia of the hip: long-term results. *Journal of Bone and Joint Surgery: American Volume* 2010 **92** 2083–2094. (<https://doi.org/10.2106/JBJS.I.01320>)
- 42. Aydin A, Kalali F, Yildiz V, Ezirmik N, Aydin P & Dostbil A.** The results of Pemberton's pericapsular osteotomy in patients with developmental hip dysplasia. *Acta Orthopaedica et Traumatologica Turcica* 2012 **46** 35–41. (<https://doi.org/10.3944/aott.2012.2613>)
- 43. Wada A, Fujii T, Takamura K, Yanagida H, Taketa M & Nakamura T.** Pemberton osteotomy for developmental dysplasia of the hip in older children. *Journal of Pediatric Orthopedics* 2003 **23** 508–513.
- 44. Wang CW, Wu KW, Wang TM, Huang SC & Kuo KN.** Comparison of acetabular anterior coverage after Salter osteotomy and Pemberton acetabuloplasty: a long-term followup. *Clinical Orthopaedics and Related Research* 2014 **472** 1001–1009. (<https://doi.org/10.1007/s11999-013-3319-6>)

- 45. Dega W.** Schwierigkeiten in der chirurgischen Reposition der veralteten kongenitalen Subluxation des Hüftgelenkes bei Kindern. *Beiträge zur Orthopädie und Traumatologie* 1964 **11** 642–647.
- 46. Dega W.** Transiliac osteotomy in the treatment of congenital hip dysplasia. *Chirurgia Narzadow Ruchu i Ortopedia Polska* 1974 **39** 601–613.
- 47. Grudziak JS & Ward WT.** Dega osteotomy for the treatment of congenital dysplasia of the hip. *Journal of Bone and Joint Surgery: American Volume* 2001 **83** 845–854. (<https://doi.org/10.2106/00004623-200106000-00005>)
- 48. Czubak J, Kowalik K, Kawalec A & Kwiatkowska M.** Dega pelvic osteotomy: indications, results and complications. *Journal of Children's Orthopaedics* 2018 **12** 342–348. (<https://doi.org/10.1302/1863-2548.12.180091>)
- 49. Karlen JW, Skaggs DL, Ramachandran M & Kay RM.** The Dega osteotomy: a versatile osteotomy in the treatment of developmental and neuromuscular hip pathology. *Journal of Pediatric Orthopedics* 2009 **29** 676–682. (<https://doi.org/10.1097/BPO.0b013e3181b7691a>)
- 50. Ming-Hua D, Rui-Jiang X & Wen-Chao L.** The high osteotomy cut of Dega procedure for developmental dysplasia of the hip in children under 6 years of age. *Der Orthopäde* 2016 **45** 1050–1057. (<https://doi.org/10.1007/s00132-016-3283-4>)
- 51. Mubarak SJ, Valencia FG & Wenger DR.** One-stage correction of the spastic dislocated hip. Use of pericapsular acetabuloplasty to improve coverage. *Journal of Bone and Joint Surgery: American Volume* 1992 **74** 1347–1357. (<https://doi.org/10.2106/00004623-199274090-00008>)
- 52. Badrinath R, Bomar JD, Wenger DR, Mubarak SJ & Upasani VV.** Comparing the Pemberton osteotomy and modified San Diego acetabuloplasty in developmental dysplasia of the hip. *Journal of Children's Orthopaedics* 2019 **13** 172–179. (<https://doi.org/10.1302/1863-2548.13.190004>)