



Review of the UBC Porcine Model of Traumatic Spinal Cord Injury

Kyoung-Tae Kim, M.D., Ph.D.,¹⁻³ Femke Streijger, Ph.D.,³ Neda Manouchehri,³ Kitty So,³ Katelyn Shortt,³ Elena B. Okon, Ph.D.,³ Seth Tigchelaar, MS,³ Peter Cripton, Ph.D.,³ Brian K. Kwon, M.D., Ph.D., FRCSC^{3,4}

Department of Neurosurgery,¹ Kyungpook National University Hospital, Daegu, Korea

Department of Neurosurgery,² School of Medicine, Kyungpook National University, Daegu, Korea

International Collaboration on Repair Discoveries (ICORD),³ University of British Columbia, Vancouver, Canada

Vancouver Spine Surgery Institute,⁴ Department of Orthopaedics, University of British Columbia, Vancouver, Canada

Traumatic spinal cord injury (SCI) research has recently focused on the use of rat and mouse models for *in vivo* SCI experiments. Such small rodent SCI models are invaluable for the field, and much has been discovered about the biologic and physiologic aspects of SCI from these models. It has been difficult, however, to reproduce the efficacy of treatments found to produce neurologic benefits in rodent SCI models when these treatments are tested in human clinical trials. A large animal model may have advantages for translational research where anatomical, physiological, or genetic similarities to humans may be more relevant for pre-clinically evaluating novel therapies. Here, we review the work carried out at the University of British Columbia (UBC) on a large animal model of SCI that utilizes Yucatan miniature pigs. The UBC porcine model of SCI may be a useful intermediary in the pre-clinical testing of novel pharmacological treatments, cell-based therapies, and the “bedside back to bench” translation of human clinical observations, which require preclinical testing in an applicable animal model.

Key Words : Spinal cord injuries · Porcine model · Translational medical research · Preclinical testing.

INTRODUCTION

Traumatic spinal cord injury (SCI) resulting in motor weakness, sensory loss, and autonomic dysfunction, has no efficacious clinical treatments. In past years, researchers have sought to find efficacious therapies for the treatment of traumatic SCI^{1,6-8,10,11,14}, many of which have been found to be effective in *in vivo* rodent models of SCI. Unfortunately, while many experimental treatments have shown great promise in

rodent models, the few of them that have actually successfully been translated into clinical trials for human SCI, have failed to demonstrate convincing efficacy²⁴. While rodent models of SCI have many benefits, including well-controlled injuries (contusion impactors, clip compression, dorsal hemisection), and widely utilized outcome measures (Basso, Beattie, Bresnahan locomotor scale, cylinder rearing test, horizontal ladder test, catwalk), the anatomical differences in cord size, and subarachnoid space compared with humans are notable (Fig. 1).

• Received : October 19, 2017 • Revised : December 20, 2017 • Accepted : February 28, 2018

• Address for reprints : **Brian K. Kwon, M.D., Ph.D., FRCSC**

Department of Orthopaedics, International Collaboration on Repair Discoveries (ICORD), University of British Columbia, 6th Floor, Blusson Spinal Cord Center, 818 West 10th Avenue, Vancouver V5Z 1M9, Canada

Tel : +1-604-875-5857, Fax : +1-604-875-8223, E-mail : brian.kwon@ubc.ca

This is an Open Access article distributed under the terms of the Creative Commons Attribution Non-Commercial License (<http://creativecommons.org/licenses/by-nc/4.0>) which permits unrestricted non-commercial use, distribution, and reproduction in any medium, provided the original work is properly cited.

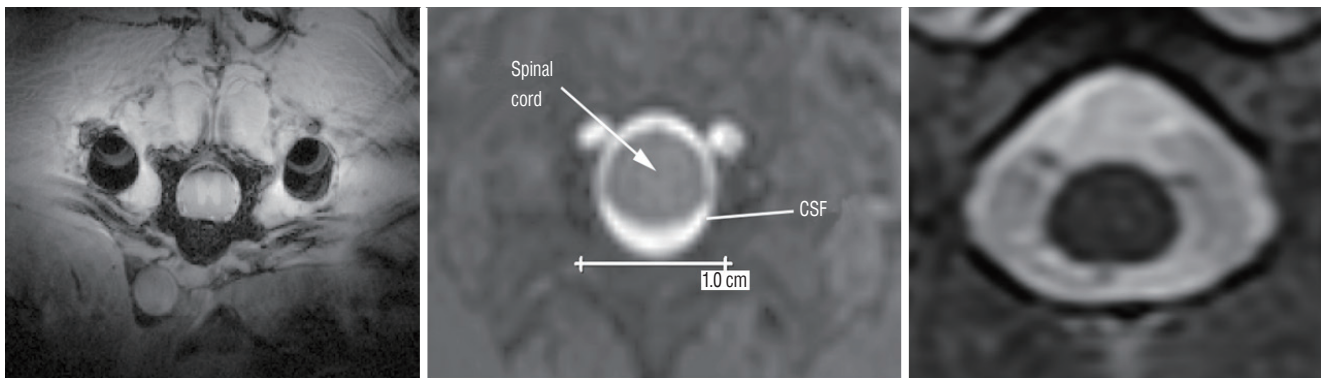


Fig. 1. Axial image from magnetic resonance imaging. Left to right, Sprague-Dawley rat, Yucatan miniature pig, and human at T10. The width of the porcine spinal cord is close to a human spinal cord and a prominent layer of cerebrospinal fluid (CSF) surrounds the porcine and human spinal cord. The transverse diameter of the rat, pig, and human spinal cord on these sections are 3.2, 7.0, and 8.3 mm, respectively. Scale bar=10 mm.

These differences may contribute to the lack of success of clinical trials for SCI therapies, which otherwise show promise in small animal, rodent studies.

Here, we review the large animal model of SCI using Yucatan miniature pigs by Lee et al.¹⁵⁾ Although there are challenges with regards to experimental cost and animal housing of larger species, the pig model has a number of advantages as a pre-clinical model of traumatic SCI. The anatomical, physiological, and genetic similarities between pigs²⁷⁾ and humans have made pigs useful as models in a variety of research settings including stroke^{3,9,17)}, traumatic brain injury^{2,25,28)}, and SCI^{18,21-23,26)}. We suggest that the porcine model of thoracic SCI is a useful intermediary model for preclinical SCI studies. In the present review, we describe our porcine model of SCI and present examples of how this model can be used for studying the pathophysiology of traumatic SCI as well as validating results from promising rodent studies.

SURGICAL PROCEDURES

The description of the development of our pig model was published by Lee et al.¹⁵⁾ with details of the surgical procedures.

Anesthesia and preparation for surgery

Our model utilizes female Yucatan miniature pigs typically weighing between 20–25 kg at the time of surgery. Animals are pre-medicated with telazol 4–6 mg/kg intramuscular (IM) injection in conjunction with xylazine 1 mg/kg IM and atropine (0.02–0.04 mg/kg) IM. Animals are induced with ei-

ther isoflurane (2–3% in O₂) or propofol 2 mg/kg, depending on the study's anesthetic requirements, and endotracheally intubated. Pigs are given an intravenous (IV) dose of antibiotics (cefazolin, 15 mg/kg), and an IM injection of analgesics (ketoprofen, 3 mg/kg) before surgery. Bupivacaine (1 mg/kg) is injected into the skin and subcutaneous tissue of the incision line as a local anesthetic. A urinary catheter (10 Fr, Jorgensen Laboratories Inc., Loveland, CO, USA) is manually inserted before surgery and is maintained after surgery until the spontaneous urination is restored. Mechanical ventilation is maintained at 10–12 breaths/min and the tidal volume at 12–15 mL/kg (Veterinary Anesthesia Ventilator model 2002, Hallowell EMC, Pittsfield, MA, USA). Standard monitoring is performed for heart rate, respiratory rate, blood pressure, end-tidal carbon dioxide, inspired and expired isoflurane levels, and oxygen saturation (pulse oximeter 8600V, Nonin Medical Inc., Markham, ON, USA and Cardell MAX-12HD Veterinary Monitor, Paragon Medical Supply, Inc., Coral Springs, FL, USA). Hydration is maintained with 1.25% dextrose solution and the temperature is measured by a rectal probe and maintained at 37.0–38.0°C with a heating pad (T/Pump, Gaymar Industries, Inc., Orchard Park, NY, USA).

Laminectomy and mounting of platform

Our most commonly performed injury is at the level of Thoracic 10 (T10) level, but the injury level can be altered depending on the research design. The vertebral levels are easily identified with anatomical landmarks such as the apex of the kyphotic thoracic spine. With the pig in the prone position on the surgical table (Fig. 2), a dorsal midline incision is made between T7 and T14, the length of which is determined by the

nature of the experiment. The spinous processes, laminae, and transverse processes of T8–T13 are exposed using monopolar electrocautery. The transverse processes are then removed using a rongeur in order to place pedicle screws at the T6 and T8 or T11 and T13 levels, using 3.5×25 mm poly-axial screws (Vertex screws, Medtronic, Memphis, TN, USA) that are designed for human cervical spine fixation. The location of screw insertion can vary depending on the experimental design. A titanium rod is fixed with the locking caps to mount

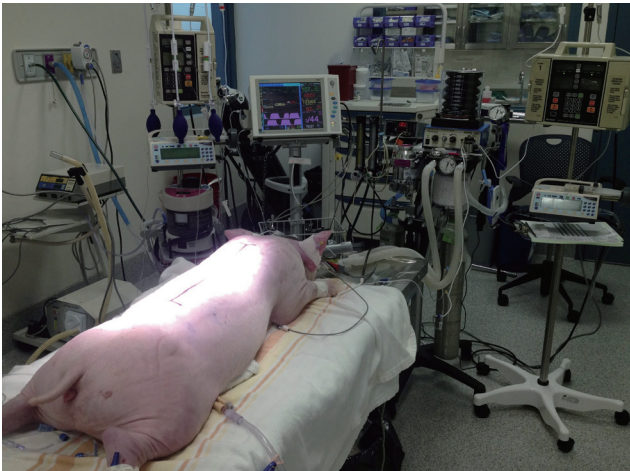

Fig. 2. The pig in prone position on the surgical table. Standard monitoring is performed for heart rate, respiratory rate, blood pressure, end tidal carbon dioxide, inspired and expired isoflurane levels, and oxygen saturation.

the weight drop guidance system, to rigidly fix the T9–12 segments during the weight drop, and to provide stability to the spine after SCI. A laminectomy is performed at the T8–T11 level and widened to ensure that a circular window measuring at least 1.2 cm in diameter (impactor diameter, 0.95 cm) is made to expose the dura and spinal cord.

SCI

Five minutes before SCI, isoflurane is increased to 3.0% from 0.5% to minimize involuntary movement as a result of the SCI. The weight drop apparatus consists of a guidance rail along which a 50 g impactor falls onto the exposed spinal cord from a defined height (Fig. 3)^{5,15}. The guidance system for the impactor is secured rigidly to the rods held by the pedicle screws, and by adjusting the articulating arm, it is positioned directly over the laminectomy defect. The rail guidance system is leveled to ensure that it is aligned vertically in both the coronal and sagittal planes. The laminectomy defect size is checked to ensure that the impactor tip can fall freely on the midline of the dura and spinal cord without any interference. A load cell (LLB215, Futek Advanced Sensor Technology, Irvine, CA, USA) is installed at the end of the impact device to record the force during impact. Finally, the impactor is released and falls along the guidance rail system, and impacts the spinal cord. Immediately after the contusion injury, we placed a 100 g weight on top of the 50 g weight impactor to




Fig. 3. Weight drop impactor devices. This system provides a mechanism to induce a contusion with compression injury, the most commonly observed type of injury in human SCI patients. A and B : The individual components of the injury device: guide rail, position sensor, trigger system, weight drop with force sensing cylindrical tip, static weight and an articulating fixation arm. C : Impactor mounted on the animals after weight drop injury. After the 50 g weight drop an additional 100 g static weight is applied for the determined period of time.

simulate sustained compression (total 150 g). The duration of compression can be adjusted depending upon the experiment – typically we use 5 minutes of sustained compression. Following 5 minutes of sustained compression, the weight drop apparatus is removed and the wound is closed by layer. However, we could control the degree of cord damage by the impactor height, weight, and the additional compression duration. In the previous study, we analyzed the effect of impactor height on tissue damage by dropping it from various heights – 50, 40, 30, 20, and 10 cm¹⁵. The height of the impactor drop was very well correlated with the histologic and function outcomes. Also, the additional compression duration and weight after primary impact could be another important factor in SCI, because the contusion from a height of 20 cm with or without sustained compression showed significant metabolic and histologic difference¹⁸. We ultimately chose 20 cm for the height of the impactor drop, combined with 5 minutes of compression, which produces a lower extremity paralysis that recovers to a Porcine Thoracic Injury Behavioral Scale (PTIBS) of approximately 4 at 12 weeks post-injury (described below).

After the surgery, the animal is maintained on a continuous rate infusion of fentanyl for pain control, which requires close observation. The animals are individually housed in recovery kennels for 7 days. The urinary catheter is removed 7–10 days after SCI, once the animals are able to reflexively empty their bladders. Animals are then housed in pairs on sawdust bedding for 12 weeks, during which behavioral recovery analysis is performed weekly.

PARAMETERS ANALYSIS

Biomechanical analysis

The data acquired from the impactor tip during the actual contusive injury is collected using a custom Labview (V8.6, National Instruments, Austin, TX, USA) program at 100 kHz, followed by post-filtering and then customized with Matlab (V2008b, The Mathworks, Matick, MA, USA) using a bi-directional 4-way filter with 5 kHz low-pass cutoff frequency. Injury parameters such as impact force, displacement, velocity, and impulse are measured, providing relevant information on injury severity and variability.

Functional outcome – the PTIBS

To characterize hindlimb locomotor recovery, we created the Porcine Thoracic Injury Behavior Scale (PTIBS)¹⁵. The PTIBS stratifies hind limb locomotor function into ten categories, ranging from absent hind limb movement (score 1) to normal walking (score 10). A PTIBS score of 1–3 reflects “hindlimb dragging”, scores of 4–6 reflect varying degrees of “stepping” ability, and scores of 7–10 reflect varying degrees of “walking” ability. A detailed description and functional components of each PTIBS score are listed in Tables 1 and 2, respectively. Hindlimb function is recorded using three high-definition camcorders located behind the animal, so that the observer can visualize the movement of the hindlimbs and hips as the animal moves away from the camera. One week before the injury, videos are recorded of the animals to establish a “baseline” locomotor behavior score. If an animal fails to achieve a score of 10 at baseline, the animal will be removed from the study. Post-injury, videos are recorded once per week for 12 weeks and subsequently scored by two independent, blinded observers.

The reliability of PTIBS is relatively high under conditions of proper training. In our previous study¹⁵, 154 video clips were scored by three observers (two trained technicians and an undergraduate student) on two occasions, 3 weeks apart. The intra-observer correlation coefficients were 0.954, 0.992, and 0.972 for the three observers and the inter-observer correlation coefficients were 0.961, 0.927, and 0.918. In addition, we analyzed the relationship between the histologic damage of the spinal cord and PTIBS. The PTIBS scores are positively correlated with white and gray matter sparing (see below in the “Histologic analysis”) 12 weeks post-injury. The correlation coefficient between the PTIBS score and the spared white matter was $R=0.888$ ($p<0.001$) and gray matter was $q=0.748$ ($p<0.001$). Also, the PTIBS scores are highly correlated with total (white and gray matter) spared tissue with a coefficient of $q=0.881$ ($p<0.001$). Also, the neurofilament immunoreactivity showed a positive correlation with the PTIBS score as a coefficient of $q=0.663$ ($p=0.002$).

In a recent study²⁶, we analyzed the correlation between the impact degree and PTIBS. The impact degree falls into three groups; mild, moderate, and severe. A mild impact degree represents an injury from a 10 cm drop height, moderate represents 20 cm, and severe represents 40 cm. One week after SCI, functional outcomes were most severely impaired. The

Table 1. Porcine Thoracic Injury Behavioral Scale (PTIBS)

Score	Description
1	No active hindlimb movements, with rump and knees on the ground
2	Active hindlimb movements, with rump and knees on the ground
3	Active hindlimb movements, with “weight-bearing extensions” that lift the rump and knee transiently off the ground (hip joints are flexed but knee joints flexed and extended)
4	Active rhythmic hindlimb crawling with at least 3 reciprocating gait cycles (crawling: left-right-left-right-left-right). Rump off the ground constantly and transient “weight bearing extensions”.
5	The animal can take at least two steps (and up to six steps) with the rump and knee constantly off the ground during the steps. The knees do not fully extend. Hoof placement is a combination of dorsal and plantar. Balance while stepping is impaired.
6	The animal can take more than six steps with the rump and knee constantly off the ground. The knees do not fully extend. Hoof placement is a combination of dorsal and plantar. Balance while stepping is impaired.
7	The animal can take at least two steps (and up to six steps) with the knees fully extended. Hoof placement is a combination of dorsal and plantar. Balance while stepping (walking) is impaired.
8	The animal can take more than six steps with the knees fully extended. Hoof placement is a combination of dorsal and plantar. Balance while stepping (walking) is impaired.
9	The animal can take more than six steps with the knees fully extended. Hoof placement is a plantar. Trunk imbalanced as the animal steps (walks).
10	The animal demonstrates grossly normal ambulation, with normal balance

The PTIBS classified locomotor behavior of pig into 10 stages from the no active hindlimb movement (score 1) to the normal walking (score 10). The PTIBS score of 1–3 reflects “hindlimb dragging”, scores of 4–6 reflect varying degrees of “stepping” ability, and scores of 7–10 reflect varying degrees of “walking” ability

Table 2. Functional components of the PTIBS

PTIBS score	Active hindlimb movements	Rump off ground	Knee off ground	Rhythmic crawling	Stepping partial knee extension	Stepping full knee extension Hoof	Hoof placements dorsal/plantar	Balance
1	N	N	N	N	N	N	N	N
2	Y	N	N	N	N	N	N	N
3	Y	Transient	Transient	N	N	N	N	N
4	Y	Y	Transient	Y	N	N	N	N
5	Y	Y	2≤Y≤6 steps	Y	2≤Y≤6 steps	N	Both	N
6	Y	Y	Y>6 steps	Y	Y>6 steps	N	Both	N
7	Y	Y	Y	Y	Y>6 steps	2≤Y≤6 steps	Both	N
8	Y	Y	Y	-	-	Y>6 steps	Both	N
9	Y	Y	Y	-	-	Y>6 steps	Plantar	N
10	Y	Y	Y	-	-	Y>6 steps	Plantar	Y

PTIBS : Porcine Thoracic Injury Behavioral Scale

average PTIBS score for the mild, moderate, and severe injury groups, were 4.0, 3.2, and 2.0, respectively. At 12 weeks after injury, the average PTIBS scores were 6.5, 4.25, and 3.0, respectively. Impact height had a significant effect on the PTIBS scores ($p<0.0001$) between all injury groups from 6 to 12 weeks after SCI. This data suggests that the impact force is strongly correlated with behavioral recovery.

Histologic analysis

For histological evaluation of damage induced by injury, a 10 cm segment of the thoracic spinal cord centered around the lesion is collected, post-fixed in 4% paraformaldehyde for 86 hours at 4°C, and cryopreserved by transferring the tissue through a series of solutions with gradually increasing sucrose concentrations (12%, 22%, and 30%). Spinal cord segments are divided into 1 cm blocks, one of them centering the im-

pact site, kept frozen at -80°C , and cryo-sectioned with a thickness of $20\ \mu\text{m}$.

For the measurement of spared white and gray matter, a series of cross-sections are stained with Eriochrome Cyanine R as described in Rabchevsky et al.¹⁹⁾ and counterstained with Neutral Red (Fig. 4). The images are then captured with an optical microscope (Leica DM5000B, Leica, Concord, Canada) using a $2.5\times$ or $5.0\times$ objective lens. In the uninjured tissue, the staining allows clear differentiation between the white matter, gray matter and the pia by the color of the stain and the shape. In the injured tissue, the spared white matter is defined as a region showing dense blue staining. We defined uninjured gray matter as tissue containing a normal gray matter cytoarchitecture and keeping the residual blue color with visible neutral red staining speck. The cumulative preserved white and gray matter is calculated by summing the percentage of spared white and gray matter in a segment around epicenter, for example from 1.52 cm rostral to 1.52 cm caudal to the epicenter¹⁶⁾. This provides a general volumetric representation of the extent of the injury.

In a recent study²⁶⁾, we analyzed the correlation between the impact degree (sham, mild, moderate, severe) and histology. The height of injury had a significant effect on the amount of spared tissue, calculated with the area under the curve of the total percent spared tissue from 13.6 mm rostral and 13.6 mm caudal of the epicenter ($p < 0.0001$). Cumulative spared tissue was greatest in the SHAM group (3380 ± 16.0 cumulative%) compared to the mild (2720 ± 98.0 cumulative%, $p = 0.0022$), moderate (1990 ± 140 cumulative%, $p < 0.0001$) and severe (1650 ± 88.0 cumulative%, $p < 0.0001$) groups. The cumulative spared tissue was significantly greater in the mild SCI group as compared to the moderate SCI group ($p = 0.0008$) and the severe SCI group ($p < 0.0001$). The spared tissue was significantly higher between the 3.2 to 11.2 mm sections caudal to

the epicenter in the moderate SCI group comparing with the severe SCI group, but there were no statistical differences between the cumulative areas ($p = 0.12$). This data suggests that the impact force is correlated with tissue damage.

APPLICATIONS OF THE PORCINE SCI MODEL

The pig model represents an important intermediary model for SCI research in which novel therapies that have shown promise in rodents models can be tested to evaluate their robustness prior to human translation. The pig model can also be used to evaluate physiological phenomena of SCI to better inform therapeutic development. A recent example of the use of this pig model for testing preclinical therapies for SCI is the evaluation of magnesium chloride within a polyethylene glycol formulation, which showed promise in many rodent studies^{12,16)}. While we had previously shown this therapy to be effective at improving behavioral recovery in a rodent model of thoracic and cervical SCI^{12,15)}, we found that the magnesium chloride therapy did not reproduce the same promising therapeutic benefits in our pig model, either for improving locomotor recovery or increasing spared tissue at the injury site²²⁾. We have also used the pig model to evaluate the effect of whole-body vibration, which is applicable to individuals who have sustained an SCI and are being transported via air or road²¹⁾. It was established that such vibration was not detrimental to the acutely injured spinal cord, and in fact in some ways may have even been beneficial²¹⁾.

We have also utilized the pig model to better understand the basic physiological responses to acute SCI. We have taken advantage of the size of the spinal cord in the pig to insert monitoring probes into the cord. The technical difficulties with regards to inserting probes into a rodent spinal cord

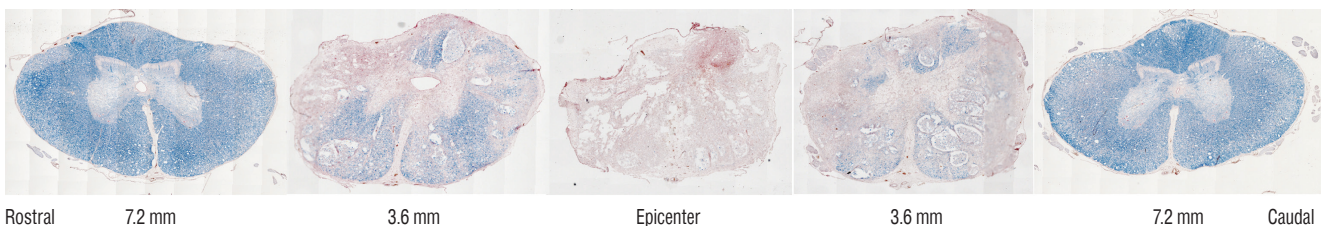


Fig. 4. For the measurement of the white and gray matter preserved areas, a series of cross-sections were stained with Eriochrome cyanide. The spared white matter was defined as a region showing dense blue staining. The preserved gray matter is defined by the color of the stain ($\times 20$) and the shape. We defined uninjured gray matter as tissue containing normal gray matter cytoarchitecture with visible neutral red staining speck.

make such monitoring practically impossible in rodent models of SCI. We began with the placement of microdialysis probes into the spinal cord in order to collect extracellular fluid to measure how the levels of metabolites within the spinal cord change after SCI (Fig. 5)¹⁸. We found that the metabolic responses to spinal cord contusion were very different between animals that received contusive SCI compared to those that received contusive SCI with additional compression. These varied responses highlight the heterogeneity that is applicable to human SCI where there are varying degrees of sustained compression after injury. This shows that our contusion/compression model is more suitable for modeling human injury than the suggested compression model²⁹. In addition to metabolic measurements, we are able to perform intraparenchymal monitoring of spinal cord blood flow, oxygenation, and pressure levels over the course of 7 days post-injury by developing a method for keeping the monitoring probes in place even when the animal is awake²³. These studies have revealed that there are signs of ischemia extending up to (and likely beyond) 7 days post-injury, and that the pressure within the spinal cord remains elevated even after decompression.

Another advantageous application of our pig SCI model is the ability to collect serial samples of enough cerebrospinal fluid (CSF) and blood from the same animals. The size of the pig cord and the volume of CSF contained in the intrathecal space allows for collection of larger volumes of CSF compared to rodents, where typical collection volumes are less than 300 μ L per animal. With our pig model of SCI, we have collected

up to 5 mL of CSF, as well as large volumes of blood, from the same animals over 7 days post-injury, while the animals are awake and freely moving. Using serially collected samples of CSF and blood, we have identified potential biomarkers of injury severity, which will aid in the diagnosis of SCI patients^{20,21}. Interestingly, in a study in which we took parallel CSF and blood samples over the first week post-injury and evaluated microRNAs using next-generation sequencing, we found that the levels of miRNA were very low in the CSF but systemically elevated in the blood; these elevated serum microRNA levels were strongly correlated to poorer PTIBS scores and greater histologic damage²⁶. We have used the pig model to evaluate the effects of vibration associated with transportation in ground or aircraft settings, and have taken advantage of the ability to obtain serial CSF samples to evaluate biomarkers of injury severity and surrogate outcome measures^{20,21}. The ability to take serial CSF samples is also valuable for testing the biodistribution of drugs, as we have shown by measuring CSF levels of magnesium in a study of a magnesium chloride neuroprotective agent in the pig model²².

Recently, Kwon and colleagues reported that the levels of IL-6, tau, S100 β , and glial fibrillary acidic protein were significantly different between patients with baseline ASIA grades of A, B, or C¹³. The levels of all proteins were significantly different between those who improved a grade and those who did not improve over 6 months after SCI. The analysis of CSF can provide valuable biological information for actual cord damage and recovery possibility after SCI. However, human CSF samples could vary in the collecting time from injury, injury

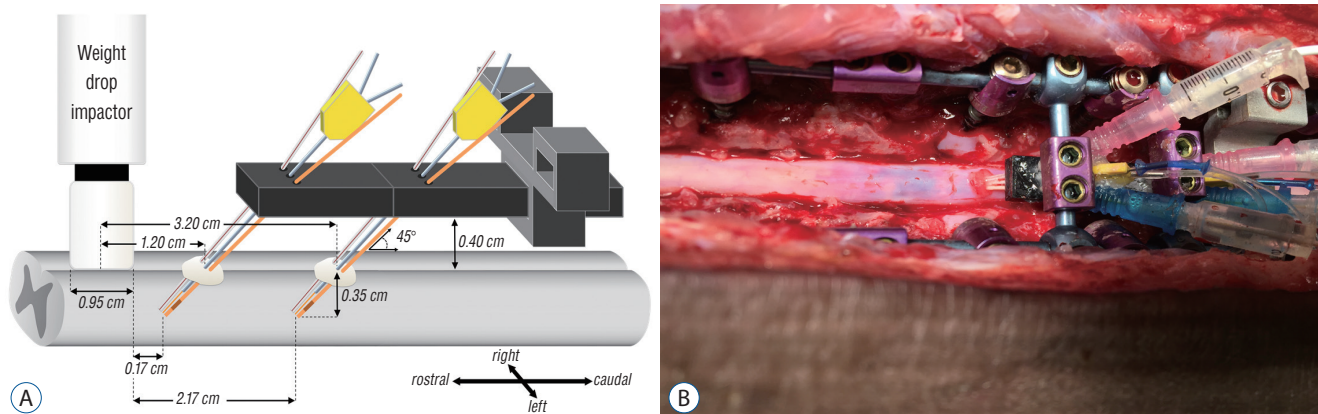


Fig. 5. Microdialysis can be used for evaluating the metabolic changes after spinal cord injury. After laminectomy, probes are inserted into the spinal cord through the dura using customized guide cannulae (A). The microdialysis probe is placed at the center, with the oxygenation and blood flow sensor to the right and the pressure sensor to the left. Probes are inserted into the spinal cord at a 45-degree angle (B) and the probe tips end 0.17 and 2.17 cm from the injury epicenter.

mechanism, injury severity, and patient's demographics. In contrast, many variables could be controlled in a large animal model. Therefore, a large animal study could provide the refined data of CSF in the future.

Lastly, the similarity of the intrathecal space and the volume of CSF between human and pigs also allows for the characterization of fluid impulses, induced in the CSF by experimental SCIs of moderate and high human-like severity⁴⁾. It has been shown that the fluid pressure wave may be sufficient to affect the severity and extent of primary tissue damage close to the injury site.

CONCLUSION

Here we review our work in the development and utilization of a porcine model of SCI that includes elements of contusion and compression, which occur most commonly in human patients with SCI. This large animal injury model may play a vital role as an intermediary testing platform for novel SCI treatment strategies prior to large-scale clinical trials. The larger size of the spinal cord and the cerebrospinal fluid space around the spinal cord of the pig provide an advantage over smaller rodent models of SCI for understanding multiple SCI mechanisms in human.

CONFLICTS OF INTEREST

No potential conflict of interest relevant to this article was reported.

INFORMED CONSENT

Informed consent was obtained from all individual participants included in this study.

• Acknowledgements

This research was supported by Basic Science Research Program through the National Research Foundation of Korea (NRF) funded by the Ministry of Science, ICT & Future Planning (NRF-2015R1C1A1A01056299).

Funding for the pig model studies have been received from

the United States Dept. of Defense, the Craig H. Neilsen Foundation, the Wings for Life Spinal Cord Foundation, the Rick Hansen Institute, and the VGH & UBC Hospital Foundation. BKK is the Canada Research Chair in Spinal Cord Injury.

References

1. Bang WS, Kim KT, Cho DC, Kim HJ, Sung JK : Valproic Acid increases expression of neuronal stem/progenitor cell in spinal cord injury. **J Korean Neurosurg Soc** **54** : 8-13, 2013
2. Browne KD, Chen XH, Meaney DF, Smith DH : Mild traumatic brain injury and diffuse axonal injury in swine. **J Neurotrauma** **28** : 1747-1755, 2011
3. Donati G, Kapetanios A, Dubois-Dauphin M, Pournaras CJ : Caspase-related apoptosis in chronic ischaemic microangiopathy following experimental vein occlusion in mini-pigs. **Acta Ophthalmol** **86** : 302-306, 2008
4. Jones CF, Lee JH, Burstyn U, Okon EB, Kwon BK, Crompton PA : Cerebrospinal fluid pressures resulting from experimental traumatic spinal cord injuries in a pig model. **J Biomech Eng** **135** : 101005, 2013
5. Jones CF, Lee JH, Kwon BK, Crompton PA : Development of a large-animal model to measure dynamic cerebrospinal fluid pressure during spinal cord injury: laboratory investigation. **J Neurosurg Spine** **16** : 624-635, 2012
6. Kim KT, Kim HJ, Cho DC, Bae JS, Park SW : Substance P stimulates proliferation of spinal neural stem cells in spinal cord injury via the mitogen-activated protein kinase signaling pathway. **Spine J** **15** : 2055-2065, 2015
7. Kim KT, Kim MJ, Cho DC, Park SH, Hwang JH, Sung JK, et al. : The neuroprotective effect of treatment with curcumin in acute spinal cord injury: laboratory investigation. **Neurol Med Chir (Tokyo)** **54** : 387-394, 2014
8. Kim KT, Nam TK, Park YS, Kim YB, Park SW : Neuroprotective effect of anthocyanin on experimental traumatic spinal cord injury. **J Korean Neurosurg Soc** **49** : 205-211, 2011
9. Kuluz JW, Prado R, He D, Zhao W, Dietrich WD, Watson B : New pediatric model of ischemic stroke in infant piglets by photothrombosis: acute changes in cerebral blood flow, microvasculature, and early histopathology. **Stroke** **38** : 1932-1937, 2007
10. Kwon BK, Borisoff JF, Tetzlaff W : Molecular targets for therapeutic intervention after spinal cord injury. **Mol Interv** **2** : 244-258, 2002
11. Kwon BK, Hillyer J, Tetzlaff W : Translational research in spinal cord injury: a survey of opinion from the SCI community. **J Neurotrauma** **27** : 21-33, 2010
12. Kwon BK, Roy J, Lee JH, Okon E, Zhang H, Marx JC, et al. : Magnesium chloride in a polyethylene glycol formulation as a neuroprotective therapy for acute spinal cord injury: preclinical refinement and optimization. **J Neurotrauma** **26** : 1379-1393, 2009

13. Kwon BK, Streijger F, Fallah N, Noonan VK, Bélanger LM, Ritchie L, et al. : Cerebrospinal fluid biomarkers to stratify injury severity and predict outcome in human traumatic spinal cord injury. **J Neurotrauma** **34** : 567-580, 2017
14. Kwon BK, Tetzlaff W, Grauer JN, Beiner J, Vaccaro AR : Pathophysiology and pharmacologic treatment of acute spinal cord injury. **Spine J** **4** : 451-464, 2004
15. Lee JH, Jones CF, Okon EB, Anderson L, Tigchelaar S, Kooner P, et al. : A novel porcine model of traumatic thoracic spinal cord injury. **J Neurotrauma** **30** : 142-159, 2013
16. Lee JH, Roy J, Sohn HM, Cheong M, Liu J, Stammers AT, et al. : Magnesium in a polyethylene glycol formulation provides neuroprotection after unilateral cervical spinal cord injury. **Spine (Phila Pa 1976)** **35** : 2041-2048, 2010
17. Mordasini P, Frabetti N, Gralla J, Schroth G, Fischer U, Arnold M, et al. : In vivo evaluation of the first dedicated combined flow-restoration and mechanical thrombectomy device in a swine model of acute vessel occlusion. **AJNR Am J Neuroradiol** **32** : 294-300, 2011
18. Okon EB, Streijger F, Lee JH, Anderson LM, Russell AK, Kwon BK : Intraparenchymal microdialysis after acute spinal cord injury reveals differential metabolic responses to contusive versus compressive mechanisms of injury. **J Neurotrauma** **30** : 1564-1576, 2013
19. Rabchevsky AG, Fugaccia I, Sullivan PG, Scheff SW : Cyclosporin A treatment following spinal cord injury to the rat: behavioral effects and stereological assessment of tissue sparing. **J Neurotrauma** **18** : 513-522, 2001
20. Streijger F, Lee JH, Chak J, Dressler D, Manouchehri N, Okon EB, et al. : The effect of whole-body resonance vibration in a porcine model of spinal cord injury. **J Neurotrauma** **32** : 908-921, 2015
21. Streijger F, Lee JH, Manouchehri N, Melnyk AD, Chak J, Tigchelaar S, et al. : Responses of the acutely injured spinal cord to vibration that simulates transport in helicopters or mine-resistant ambush-protected vehicles. **J Neurotrauma** **33** : 2217-2226, 2016
22. Streijger F, Lee JH, Manouchehri N, Okon EB, Tigchelaar S, Anderson LM, et al. : The evaluation of magnesium chloride within a polyethylene glycol formulation in a porcine model of acute spinal cord injury. **J Neurotrauma** **33** : 2202-2216, 2016
23. Streijger F, So K, Manouchehri N, Lee JHT, Okon EB, Shortt K, et al. : Changes in pressure, hemodynamics and metabolism within the spinal cord during the first 7-days after injury using a porcine model. **J Neurotrauma** **34** : 3336-3350, 2017
24. Tator CH : Review of treatment trials in human spinal cord injury: issues, difficulties, and recommendations. **Neurosurgery** **59** : 957-982; discussion 982-987, 2006
25. Teranishi K, Scultetus A, Haque A, Stern S, Philbin N, Rice J, et al. : Traumatic brain injury and severe uncontrolled haemorrhage with short delay pre-hospital resuscitation in a swine model. **Injury** **43** : 585-593, 2012
26. Tigchelaar S, Streijger F, Sinha S, Flibotte S, Manouchehri N, So K, et al. : Serum MicroRNAs reflect injury severity in a large animal model of thoracic spinal cord injury. **Sci Rep** **7** : 1376, 2017
27. Wernersson R, Schierup MH, Jørgensen FG, Gorodkin J, Panitz F, Staerfeldt HH, et al. : Pigs in sequence space: a 0.66X coverage pig genome survey based on shotgun sequencing. **BMC Genomics** **6** : 70, 2005
28. Wofford KL, Harris JP, Browne KD, Brown DP, Grovola MR, Mietus CJ, et al. : Rapid neuroinflammatory response localized to injured neurons after diffuse traumatic brain injury in swine. **Exp Neurol** **290** : 85-94, 2017
29. Zurita M, Aguayo C, Bonilla C, Otero L, Rico M, Rodríguez A, et al. : The pig model of chronic paraplegia: a challenge for experimental studies in spinal cord injury. **Prog Neurobiol** **97** : 288-303, 2012