



Contents lists available at ScienceDirect

Journal of Orthopaedic Translation

journal homepage: www.journals.elsevier.com/journal-of-orthopaedic-translation

Original Article

Chinese herbal Huo-Gu formula for the treatment of steroid-associated osteonecrosis of femoral head: A 14-year follow-up of convalescent SARS patients



Zeqing Huang^{a,☆}, Fanyu Fu^{b,☆}, Hengli Ye^b, Huanhuan Gao^a, Biao Tan^a, Rongtian Wang^c, Na Lin^d, Ling Qin^{e,f,**}, Weiheng Chen^{c,*}

^a Wanging Hospital, China Academy of Chinese Medical Sciences, PR China

^b Guizhou University of Traditional Chinese Medicine, PR China

^c Orthopaedic Center, The Third Affiliated Hospital of Beijing University of Chinese Medicine, PR China

^d Institute of Chinese Materia Medica, China Academy of Chinese Medical Sciences, PR China

^e Department of Orthopaedics & Traumatology, Musculoskeletal Research Laboratory, Innovative Orthopaedic Biomaterial and Drug Translational Research Laboratory, Li Ka Shing Institute of Health, The Chinese University of Hong Kong, Hong Kong Special Administrative Region

^f Translational Medicine R&D Center, Shenzhen Institutes of Advanced Technology, Chinese Academy of Sciences, PR China

ARTICLE INFO

Keywords:

Chinese herbal medicine

Huo-Gu formula

Osteonecrosis of the femoral head

SARS

Steroid-related osteonecrosis

SUMMARY

Purpose: The coronavirus disease 2019 (COVID-19) reminds us of the severe acute respiratory syndrome (SARS) outbreak in 2003, and up to date, corticosteroid is commonly administrated to severe patients with COVID-19. Osteonecrosis of the femoral head (ONFH) is a common disabling complication among convalescent SARS patients who received corticosteroid therapy. In China, a considerable number of convalescent SARS patients with steroid-associated ONFH had undergone conservative treatment by traditional Chinese medicine, and this study aims to evaluate the long-term results of a spleen-invigorating Huo-Gu formula (HGF) therapy in these patients. **Participants and methods:** A total of 33 convalescent SARS patients (9 males and 24 females) with bilateral steroid-associated ONFH (66 hips) were enrolled in this study. All patients received oral HGF therapy for 6 months when they were confirmed the diagnosis of steroid-associated ONFH. They had been regularly followed up at an interval of 1 year. Harris hip score and medical imaging modalities, including plain radiography, computed tomography and magnetic resonance imaging, were performed to evaluate the outcomes.

Results: Based on average 14 years of follow-up of HGF therapy (ranging from 6 to 16 years), 38 hips (57%) among the 66 hips developed definite osteoarthritis, and 14 hips (26%) in 53 precollapse hips (Association Research Circulation Osseous [ARCO] Stage I or II) progressed to femoral head collapse (ARCO Stage III or IV). Only five patients (also 5 hips) underwent total hip arthroplasty, and the mean hip survival time was over 15 years by the Kaplan–Meier analysis. We observed a mean Harris hip score of 63 points, which represented the reserve of 55% in pain score and 70% in physical function score. The severity of groin pain was not correlated to the severity of osteoarthritis.

Conclusion: Chinese herbal HGF therapy demonstrates beneficial effects on preventing femoral head collapse, delaying total hip arthroplasty, and maintaining physical function in the treatment of steroid-associated ONFH. HGF therapy might be therefore a good alternative for the treatment of steroid-associated ONFH secondary to rheumatologic and infectious diseases.

Translational potential of the article: HGF therapy might be a good alternative for the treatment of steroid-associated ONFH secondary to rheumatologic and infectious diseases.

* Corresponding author. The Third Affiliated Hospital of Beijing University of Chinese Medicine, No. 51 Anwai Xiaoguanjie, Chaoyang District, Beijing, 100029, China.

** Corresponding author. Department of Orthopaedics & Traumatology, Musculoskeletal Research Laboratory, Innovative Orthopaedic Biomaterial and Drug Translational Research Laboratory, Li Ka Shing Institute of Health, The Chinese University of Hong Kong, Prince of Wales Hospital, Rm74026, 5/F, Clinical Science Building, Shatin, Hong Kong Special Administrative Region

E-mail addresses: lingqin@cuhk.edu.hk (L. Qin), drchenweiheng@bcm.edu.cn (W. Chen).

☆ Zeqing Huang and Fanyu Fu contributed equally to this work.

<https://doi.org/10.1016/j.jot.2020.03.014>

Received 16 February 2020; Received in revised form 23 March 2020; Accepted 27 March 2020

Available online 4 April 2020

2214-031X/© 2020 The Author(s). Published by Elsevier (Singapore) Pte Ltd on behalf of Chinese Speaking Orthopaedic Society. This is an open access article under

the CC BY-NC-ND license (<http://creativecommons.org/licenses/by-nc-nd/4.0/>).

Introduction

The coronavirus disease (COVID-19) outbreak in 2019 reminds us of the worldwide outbreak of severe acute respiratory syndrome (SARS) emerged in 2002–2003. Similarly, no specific therapy is available for the coronavirus [1]. It is estimated that corticosteroid therapy was administered to 18% of COVID-19 patients, with a higher percentage among those with severe disease (44%) than nonsevere disease (13%) [2]. Osteonecrosis, pulmonary fibrosis and depression are commonly seen among convalescent SARS patients. Osteonecrosis of the femoral head (ONFH) in SARS survivors could be attributed to the steroid because high cumulative doses of steroids were closely associated with the occurrence of osteonecrosis [3]. Steroid-associated ONFH can progressively break down the underlying bone of the hip joint and thus induce severe premature osteoarthritis of the hip, which would further cause physical disability in these SARS survivors [4].

To date, all treatment strategies currently available for precollapse steroid-associated ONFH, frequently named as hip-preserving treatments, are not able to completely stop the rapid progression to either the collapse of the femoral head or the hip osteoarthritis. A review of pertinent literature indicates that there is no better treatment than total hip arthroplasty (THA) for hips with a postcollapse course [5]. However, patients should be carefully selected for THA because of limited implant lifespan and diverse operative complications.

Not all patients with steroid-associated ONFH have undergone operative treatments [4,6]. Disappointingly, a meta-analysis published in 2019 had concluded that postmarketing drugs, including enoxaparin, statins, bisphosphonates, iloprost and acetylsalicylic acid, were not recommendable for this disease [7]. One of the reasons why these single-component drugs fail to take effect is that steroid-associated ONFH is a multifactorial disease with complex signal pathways involved [8]. This mechanism explains the fact that not all individuals who continue long-term steroid therapy develop steroid-associated ONFH. Chinese medicine may be a potential solution for steroid-associated ONFH, because it is based on network pharmacology through a network-target and multicomponents mechanism [9].

In China, quite a few ONFH patients are undergoing pharmacological treatments, especially treatment by traditional Chinese medicine (TCM) [4,6,10]. In 2012, “Chinese Experts’ Consensus on the Diagnosis and Treatment of Osteonecrosis of the Femoral Head in Adults (2012)” recommended Chinese medicine as one of the pharmacological treatments for ONFH [11]. “Chinese Guideline for the Clinical Diagnosis and Treatment of Femoral Head Necrosis in Adults (2016)” were formulated based on evidence-based medicine [12]. Based on the 2016 version guideline, professional specialists, scholars and orthopaedist from Europe, Asia, America and China jointly develop new guidelines for further standardised and effective clinical diagnosis and treatment of adults ONFH as “Guidelines for clinical diagnosis and treatment of osteonecrosis of the femoral head in adults (2019)” [13]. In addition, a meta-analysis that included 23 randomised controlled trials reported that Chinese medicine helped enhance the effect of core decompression surgery for ONFH [14]. However, the therapeutic outcomes of Chinese medicine treatment used alone are less investigated and reported, especially long-term follow-up studies are lacking.

Huo-Gu formula (HGF) is a Chinese herbal medication that is commonly administrated for patients with ONFH in China. Abnormal lipid metabolism has been reported to be involved in the development of ONFH [15], and the TCM theory believes that phlegm-dampness (Tan-Shi) pathogen is closely associated with the abnormal lipid metabolism [16]. The main TCM function of HGF is to help invigorate the spleen (Pi) to clear dampness, resolve phlegm and activate blood circulation. Previous animal testing had found an allopathic effect of HGF on preventing steroid-treated animals from developing steroid-associated ONFH [17, 18]. Interestingly, we found that HGF also helps improve lipoprotein metabolism [17,18]. Further experiments found that the ethyl acetate fraction of HGF helps inhibit the adipogenic differentiation of the bone

marrow stromal cells [19] whereas the aqueous fraction of HGF promotes the osteogenic differentiation [20]. Here, we conducted a long-term retrospective study to evaluate the outcomes of HGF therapy for steroid-associated ONFH in convalescent SARS patients with an average of 14 years.

Participants and methods

This retrospective cohort study included 33 convalescent SARS patients (Fig. 1) who were referred to Wangjing Hospital once confirmed the diagnosis of ONFH. In our hospital, a total of 45 convalescent SARS patients (94 hips) were treated by HGF therapy alone, but 12 patients were excluded from the present study. The clinical study had been conducted according to the principles expressed in the Declaration of Helsinki and was approved by the institutional review board of Wangjing Hospital. All patients consented to participate in this study.

The diagnosis of ONFH was performed based on distinctive radiographic features seen on magnetic resonance imaging (MRI), including a focal serpentine low signal line with fatty centre on T1 weighted image (reactive interface line), and serpiginous peripheral dark line and inner bright line on T2 weighted image (double line sign), according to the Association Research Circulation Osseous (ARCO) classification system [21]. Inclusion criteria were convalescent SARS patients received steroid therapy, the case with bilateral hips affected, continuously received oral HGF treatment for at least 6 months once confirmed the diagnosis of ONFH. Exclusion criteria were patients with continuous use of steroids, with a history of alcoholism, a history of hip injury, received other treatments for ONFH including operative treatment or nonoperative treatment.

Among these 33 patients, there were nine males and 24 females with an average age of 42.52 ± 8.26 years (range 27–64 years; Table 1). All patients are bilaterally affected (66 hips). The mean interval between the diagnosis of SARS and ONFH was 22.76 ± 26.21 months (range 6–127 months). According to the ARCO classification, 10 hips were classified as Stage I (normal plain radiograph but with specific osteonecrosis findings on MRI), 43 hips as Stage II (abnormal plain radiographs without collapse or a crescent sign), nine hips as Stage III (abnormal plain radiographs with collapse or a crescent sign) and four hips as Stage IV (abnormal plain radiographs with hip arthritis). Based on the lesion size determination criteria, there were 23 hips with a small lesion (<15% of femoral head involvement by necrotic volume), 12 hips with a medium lesion (15–30%) and 31 hips with a large lesion (>30%). According to the Japanese Investigation Committee (JIC) classification criteria, there were 14 hips with a Type A lesion (a lesion occupies the medial one-third or less of the weight-bearing portion), 16 hips with a Type B lesion (a lesion occupies the medial two-thirds or less of the weight-bearing portion) and 36 hips with Type C (a lesion occupies more than the medial two-thirds of the weight-bearing portion). All patients were followed up till November 2019, or they received THA.

Huo-Gu formula treatment

The TCM theory categorised corticosteroid as a drug-induced pathogen, which can act on every aspect of the human body and produces the phlegm-dampness (Tan-Shi) pathogen. Phlegm-dampness blocking meridian (Jing-Luo), which further induces Qi stagnation and blood (Xue) stasis, is believed to be the pathological basis of corticosteroid-associated ONFH [22]. The phlegm-dampness pathogen affects mainly the lower part of the body. The hip (femoral head) is among the most susceptible joints to the phlegm-dampness pathogen. Once the phlegm-dampness pathogen affects the femoral head, the circulation of “Qi” and “Blood” along the meridian around the hip is to be disturbed. When the meridian branches passing through the femoral head can be blocked, the femoral head is to lose the nutrition of “Qi” and “Blood”.

Based on above TCM theories, the management strategy of TCM for the pathogen-induced disorders includes clearing dampness, resolving phlegm and activating blood circulation [11,12]. To implement this

management strategy, we created the HGF therapy. HGF is modified from Lin–Gui–Zhu–Gan–Tang formula and Si–Wu–Tang formula. Lin–Gui–Zhu–Gan–Tang formula is commonly used to clear dampness and resolve phlegm, and the main TCM function of Si–Wu–Tang formula is to activate blood circulation. The addition of *Pinelliae rhizoma praeparatum* (Fabanxia) and *Radix salviae miltiorrhizae* (Dangshen) is to strengthen the TCM function of spleen-invigorating and phlegm-resolving, whereas the addition of *Eupolyphaga steleophaga* and *Cervicornuscolla* (Lujiaojiao) is to strengthen the TCM function of bone-tonifying.

The 33 patients were evenly given HGF treatment for at least 6 months once they were confirmed the diagnosis of ONFH. For the convenience of use, all patients received granulated extract medication (decocting-free Chinese herbal medicine) manufactured by Sichuan Neogreen Pharmaceutical Technology Development CO., Ltd (Sichuan Chengdu, PR China). The standard daily dose of HGF included the essential components extracted from the following 12 crude drugs (Table 2): *Poria* (Fuling) 12.0 g, *Cinnamomi ramulus* (Guizhi) 10.0 g, *Atractylodis macrocephalae rhizoma* (Baizhu) 12.0 g, *Glycyrrhizae radix et rhizoma* (Gaocao) 3.0 g, *P. rhizoma praeparatum* (Fabanxia) 9.0 g, *Radix salviae miltiorrhizae* (Dangshen) 12.0 g, *Angelicae sinensis radix* (Danggui) 9.0 g, *Chuanxiong rhizome* (Chuanxiong) 10.0 g, *Rehmanniae radix praeparatum* (Shudihuang) 12.0 g, *Paeonia radix rubra* (Chishao) 9.0 g, *E. steleophaga* (Tubiechong) 9.0 g and *Cervicornuscolla* (Lujiaojiao) 12.0 g. HGF is generally taken twice a day before or between meals. The patients were also requested to restrict weight-bearing by using two crutches for 1 year. The electronic medical record was checked to make sure all participants had received homogeneous HGF treatment.

Follow-up care

Routine outpatient follow-up took place monthly during HGF treatment, and every year after that. Patients were requested to return to our clinics if they developed relapsing groin pain or other adverse reactions

Table 1

Baseline characteristics of the studied patients.

Index	33 patients (66 hips)
Age [y, mean ± SD (range)]	42.52 ± 8.26 (27–64)
Gender (male/female)	9/24
ARCO classification (Stage I/II/III/IV)	10/43/9/4
Lesion size (small/medium/large)	23/12/31
JIC classification (Type A/B/C)	14/16/36
Latent period [mo, mean ± SD (range)]	22.76 ± 26.21 (6–127)

ARCO = Association Research Circulation Osseous; SD = standard deviation.

related to HGF treatment. All patients were evaluated by radiographs, CT scanning and MRI at their routine clinic visits. Clinical information was also recorded by interviews and physical examinations.

End-point outcome assessment

The most recent follow-up investigation took place in November 2019. Every patient was invited to complete a questionnaire designed largely based on the Harris hip score (HHS; Table 3) [23], core outcome set (COS) for ONFH walking function index [24]. The overall HHS can be divided into pain index and physical function index. The HHS pain index classified the severity of pain by six grades, and the HHS physical function index majorly includes measures of the ability of daily living (ADL; Table 3). Three orthopaedic surgeons who specialised in hip arthritis and were not involved in the present study were invited to evaluate the images. Each decision was made by consensus among the three surgeons. The collapse of the femoral head was defined as a fine radiolucent subchondral fracture line or a depression of articular surface. The degree of hip osteoarthritis was measured according to the Kellgren–Lawrence (K–L) classification [25].

Statistical analysis

With the THA as the end-point, the mean survival time for all studied

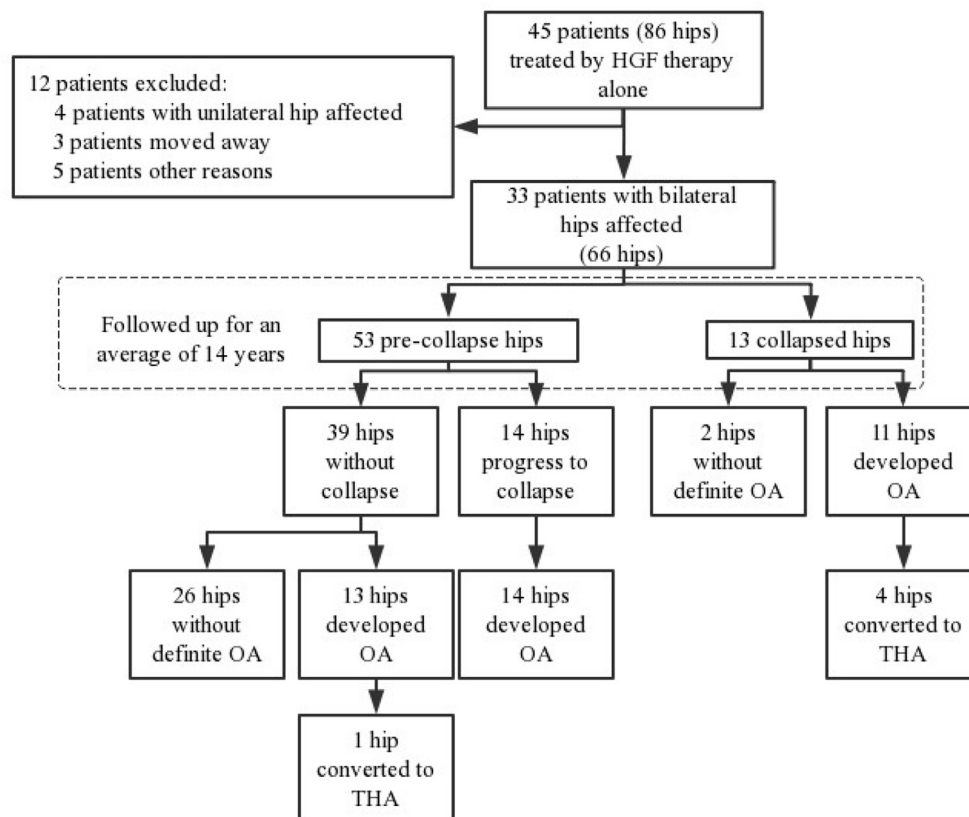


Fig. 1. Flow chart detailing enrollment and follow-up of participants in the study. HGF = Huo-Gu formula; OA = osteoarthritis; THA = total hip arthroplasty.

Table 2
Composition of Huo-Gu formula.

Pharmaceutical name of the herbal compounds	Chinese name	Dosage (g)
<i>Poria</i>	Fuling	12
<i>Cinnamomi ramulus</i>	Guizhi	10
<i>Atractylodis macrocephalae rhizoma</i>	Baizhu	12
<i>Glycyrrhizae radix et rhizoma</i>	Gancao	3
<i>Pinelliae rhizoma praeparatum</i>	Fabanxia	9
<i>Radix salviae miltiorrhizae</i>	Dangshen	12
<i>Angelicae sinensis radix</i>	Danggui	9
<i>Chuanxiong rhizome</i>	Chuanxiong	10
<i>Rehmanniae radix praeparatum</i>	Shudihuang	12
<i>Paeonia radix rubra</i>	Chishao	9
<i>Eupolyphaga steleophaga</i>	Tubiechong	9
<i>Cervicornuscolla</i>	Lujiao	12

Table 3
Outcome assessment measures used in the study.

HHS pain index	Grade 0	None, or ignores it
	Grade 1	Slight, occasional, no compromise in activity
	Grade 2	Mild pain, no effect on average activities, rarely moderate pain with unusual activity, may take aspirin
	Grade 3	Moderate pain, tolerable but makes concessions to pain. Some limitations of ordinary activity or work. May require occasional pain medication stronger than aspirin
	Grade 4	Marked pain, serious limitation of activities
HHS physical function index	Grade 5	Totally disabled, crippled, pain in bed, bedridden
	Support	
	Distance walked	
	Limp	
	Activities—shoes, socks	
	Stairs	
	Public transportation	
COS for ONFH walking function index	Sitting	
	Malformation	
	Motion	
	Grade 0	Indoors only
	Grade 1	<500 m
Kellgren–Lawrence classification	Grade 2	500–1000 m
	Grade 3	Unlimited
	Grade 0	No radiographic features of OA are present
	Grade 1	Doubtful JSN and possible osteophytic lipping
Kellgren–Lawrence classification	Grade 2	Definite osteophytes and possible JSN on anteroposterior weight-bearing radiograph
	Grade 3	Multiple osteophytes, definite JSN, sclerosis, possible bony deformity
	Grade 4	Large osteophytes, marked JSN, severe sclerosis and definite bony deformity

HHS = Harris hip score; JSN = joint space narrowing; OA = osteoarthritis; ONFH = osteonecrosis of the femoral head.

hip was calculated using the Kaplan–Meier method. The differences in the survival distributions between patient groups with different ARCO stages were tested with the log-rank test. Because the HHS is separated into pain index and physical function index, these subindexes were also analysed and compared. As lately occurred groin pain in patients with ONFH are commonly ascribed to ONFH-induced osteoarthritis, we also analysed the correlation between degrees of pain and degrees of osteoarthritis by Kendall's τ -b test. The correlation analysis between degrees of pain and degrees of walking function, as well as the correlation between

degrees of osteoarthritis and degrees of walking function, were conducted by the same method. SPSS version 19.0 (SPSS Inc., Chicago, IL, USA) was used in all data processing.

Results

As of November 2019, all 33 patients provided complete data on the outcome measures at the final follow-up. The mean follow-up period was 14.88 ± 2.25 years (range 6.25–16.83 years).

Therapeutic outcome

A total of five patients were converted to THA because of severe hip osteoarthritis (K–L Grade 4). With the hip replacement as the end-point, the mean hip survival time without collapse was 15.95 years (95% confidence interval: 15.25–16.71 years; Fig. 2A). The hip survival duration largely depended on clinical stages. The conversion rate to THA of patients with ARCO Stage IV was 75.00%, whereas the rate of hips with ARCO Stages I–III was 0.03% in total. A significant difference in hip survival duration was observed between the subgroups divided by ARCO classification ($p < 0.001$, by the log-rank test; Fig. 2B).

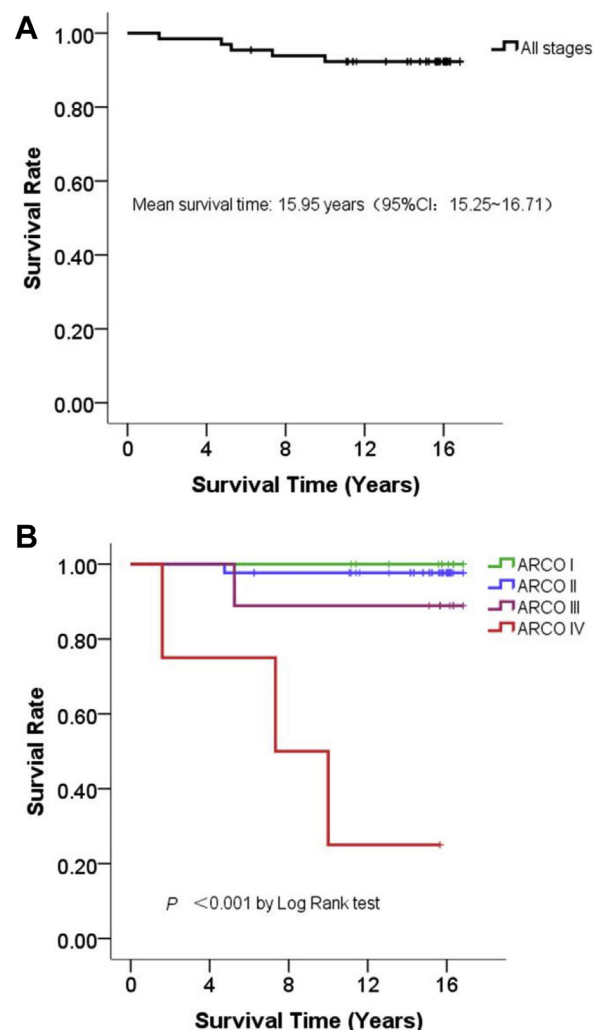


Fig. 2. The Kaplan–Meier plots of 66 hips with steroid-associated ONFH received HGF treatment. Plot A shows the mean survival time of 15.95 years. Plot B shows that hips with ARCO Stage IV (red) have poorer prognosis, as their survival probability is lower than those with ARCO Stages [20] I–III (green, blue and purple). ARCO = Association Research Circulation Osseous; CI = confidence interval; HGF = Huo-Gu formula; ONFH = osteonecrosis of the femoral head.

Harris hip score

As for the 28 patients who did not undergo THA, the most recent follow-up examination showed a mean value of HHS pain index of 24.29 ± 8.35 (range 10–40). This data indicated that each patient had reduced 44.79% (19.71/41) of pain score. That is, these 28 patients commonly experienced moderate pain when taken the calculation method of visual analog scale as a reference. On the other hand, the mean HHS physical function index was 39.61 ± 5.59 (range 28–56), which indicated that each patient had maintained 70.73% (31.71/56) of physical function. Overall, the mean HHS was 63.89 ± 10.30 (range 49–87).

We further analysed the HHS of those five patients who had one of their severer affected hips replaced in our hospital. No significant difference was observed in terms of HHS physical function index between these five patients and the 28 patients mentioned previously. Nevertheless, lower HHS pain index and total HHS were found in these five patients ($p < 0.05$; Fig. 3), which suggested that patients with bilateral ONFH still experienced a considerable loss of hip function although they had already surgical replacement of the severer side of hips.

Radiographic evaluation

At the most recent follow-up visit, we observed that the collapse of the femoral head had occurred in 14 (26.41%) of 53 previously precollapse hips. Meanwhile, osteoarthritis (K–L Grades 2–4) had occurred in 27 (50.94%) of 53 previously precollapse hips and 11 (84.61%) in 13 previously collapsed hips.

Osteoarthritis

We used Kendall's τ -b method to examine the relationship between degrees of severity with regards to hip osteoarthritis, pain and physical function (Fig. 4). However, we failed to observe significant correlations between degrees of osteoarthritis and degrees of HHS pain index, degrees of osteoarthritis and degrees of walking function index, as well as degrees of HHS pain index and degrees of walking function index.

We also observed four patients without osteoarthritis (K–L Grade 0) complained of chronic moderate hip pain, and two patients with doubtful hip osteoarthritis (K–L Grade 1) complained of chronic intense hip pain. These data indicated that osteoarthritis could not fully explain the source of pain, and some other factors which might also be involved in causing pain in these patients. Image series of representative cases were shown in Figs. 5–8.

Discussion

HGF demonstrated a promising effect on the treatment of the steroid-associated ONFH among convalescent SARS patients [26], but the long-term outcome remained uncertain. This retrospective cohort study aimed to evaluate the long-term outcome of HGF therapy on these unique patients. As of November 2019, only five patients were subjected to THA. With THA as the study end-point, survival analysis predicted the mean hip survival time would be over 15 years.

Most patients with steroid-associated ONFH simultaneously suffered from rheumatologic diseases that necessitate continuous corticosteroid therapy. The use of corticosteroids made it difficult to assess the real effect of medical interventions for ONFH. The convalescent SARS patients were a homogeneous and special group of patients to observe the effect of medical interventions for steroid-associated ONFH. On the one hand, SARS itself did not seem to have a connection with the development of ONFH. On the other hand, convalescent SARS patients did not need to restart corticosteroid therapy so that the effect of HGF would not be interfered.

The capacity to prevent femoral head collapse is the major index to evaluate the effect of medical interventions for precollapse ONFH. In the

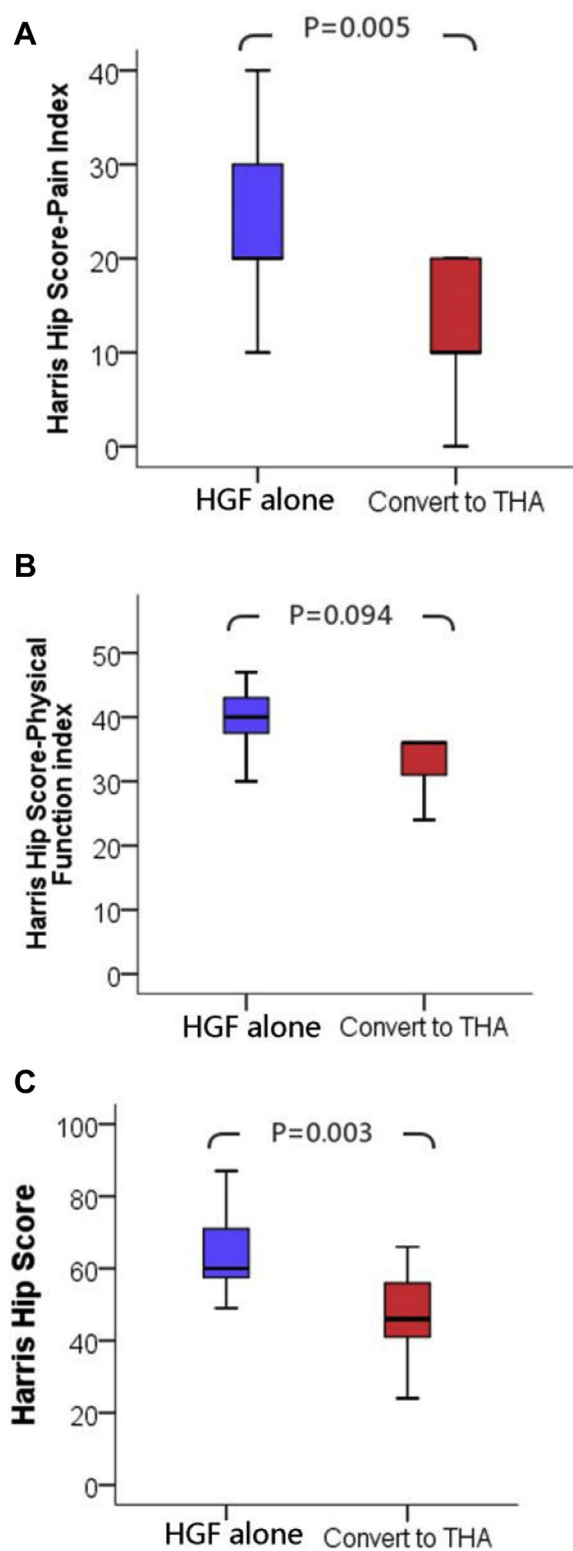


Fig. 3. Box plots of Harris hip score index for the 33 participants in the study (28 patients received HGF treatment alone, with 5 patients ended up with THA surgery). HGF = Huo-Gu formula; THA = total hip arthroplasty.

present study, we observed 14 new collapse cases (26.41%) in 53 patients with precollapse ONFH. According to a systematic review published in 2010, which studied the natural history of 598 hips with ONFH, the overall collapse rate was 49.00% after a mean follow-up duration of 4 years [27]. In 2019, Wei et al. [10] reported a collapse rate of 22.00% in

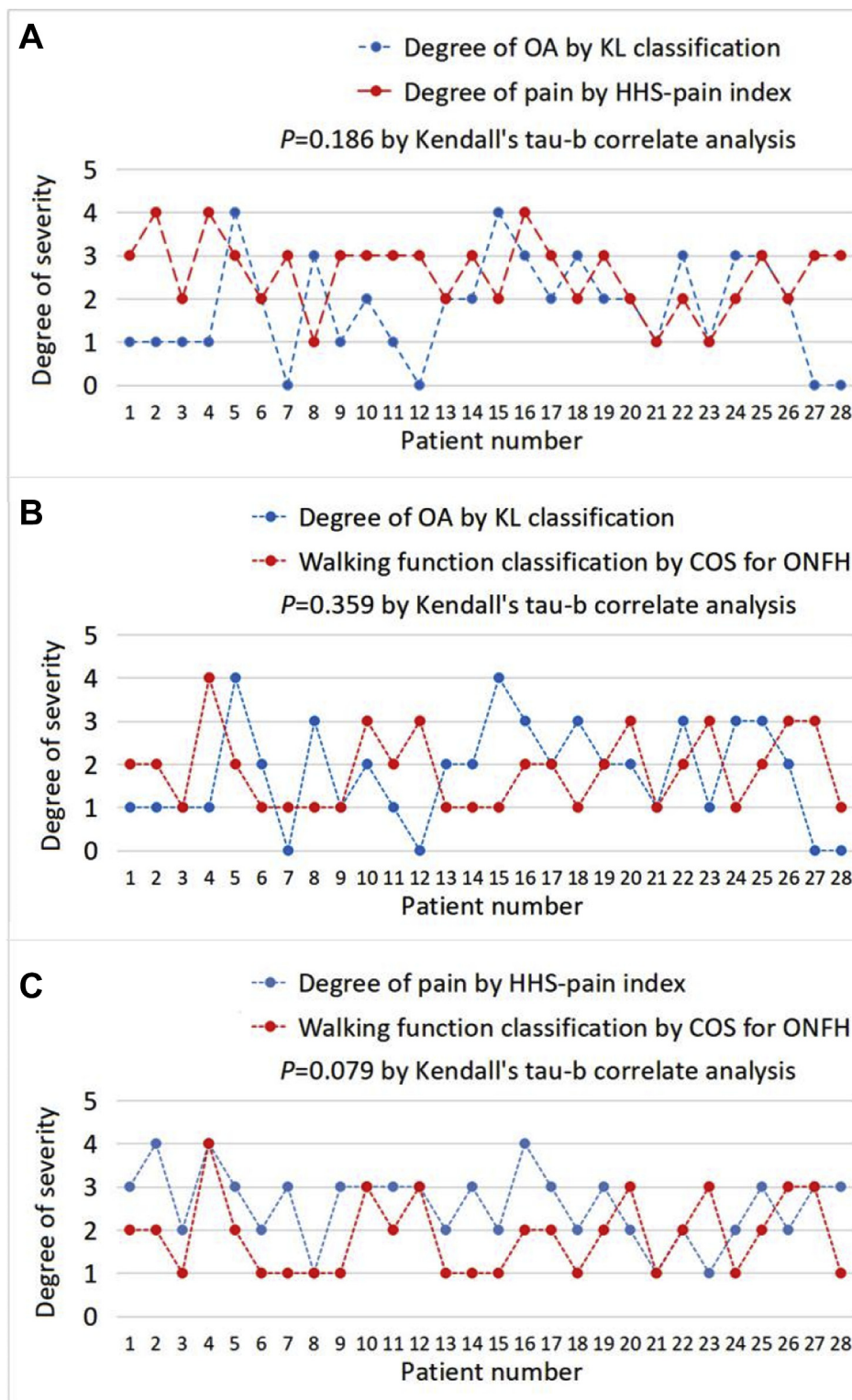


Fig. 4. Scatter plots for correlation analysis of pain, physical function and walking function of the 28 participants who did not undergo THA. HHS = Harris hip score; K-L = Kellgren–Lawrence; OA = osteoarthritis; ONFH = osteonecrosis of the femoral head; THA = total hip arthroplasty.

59 patients receiving oral administration of Huo Xue Tong Luo Capsule (a Chinese medication) after a mean follow-up duration of 4.38 years. Our results consistently support Wei's finding that Chinese medicine helps prevent progression to femoral head collapse and avoid THA with prolonged follow-up data.

The goal of hip-preserving treatments is not only to avoid or delay THA, but also to maintain or restore the physical function of the hip joint.

HHS is an outcome measure frequently used for evaluation of the physical function among patients with hip joint disorders [28,29]. We observed a mean HHS of 63.89 ± 10.30 in 28 patients without THA at the end of the present study. Although the data suggest that HGF therapy only yields poor results (HHS < 70), but our data are still comparable to previous relevant studies [30–33]. Alendronate is one of the most commonly used pharmacological treatments for ONFH [34]. In 2005, an

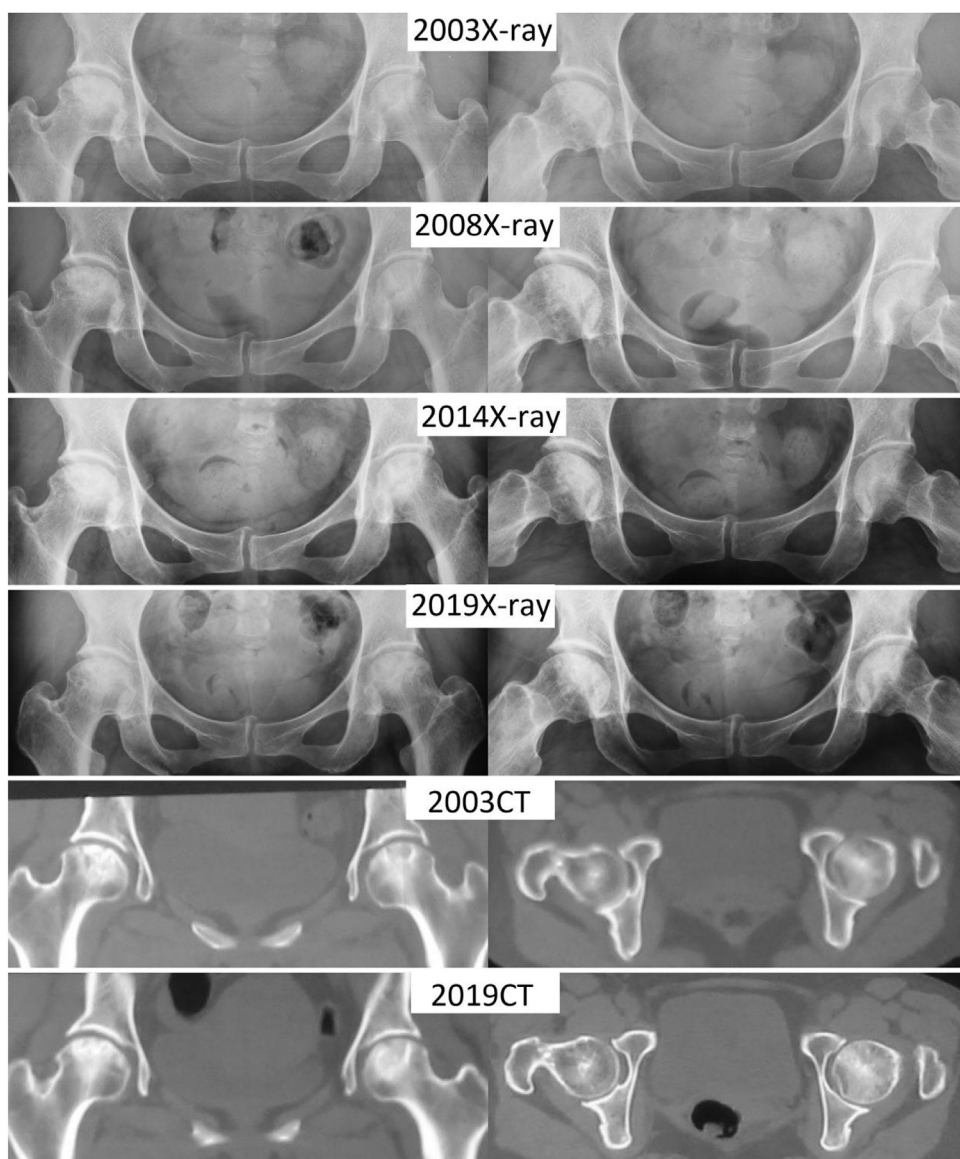


Fig. 5. Medical imaging series from a 35-year-old female (patient number SARS03017) with ONFH received HGF therapy in 2003. Plain radiographs in 2003 suggested bilateral ONFH (left: ARCO Stage III and JIC Type C1, right: ARCO Stage III and JIC Type C1). Plain radiographs series (from 2008 to 2019) showed the development of sclerosis in the necrotic lesions and osteoarthritis in the hip joints. CT images in 2019 confirmed the presence of osteoarthritis (left: K-L Grade 1, right: K-L Grade 2) without severe depression of femoral head. ARCO = Association Research Circulation Osseous; CT = computed tomography; HGF = Huo-Gu formula; ONFH = osteonecrosis of the femoral head.

randomized controlled trial (RCT) included 20 patients who received 25-week alendronate treatment, reported a mean HHS of 74.4 ± 7.8 after a follow-up duration of 2 years [32]. However, the efficacy of alendronate for treating ONFH has been questioned by later studies [35,36]. Core decompression is believed to be the most reliable operative treatment for precollapse ONFH [37]. Even so, an RCT study published in 2017 reported a mean HHS of 68 ± 5 in 21 patients who had undergone core decompression surgery at 3 years follow-up visit [33].

In the present study, we separate the original HHS into the pain index and the physical function index. The latter evaluates diverse ADL, including the need of walking aids, distance walked, limp, wearing shoes and socks, climbing stairs, public transportation, sitting and range of motion. Moreover, we observed that these 28 patients without THA had maintained 70% of the aforementioned ADL after a mean follow-up duration of 14 years, by the rating method of HHS physical function index.

ONFH can cause rapidly worsening hip osteoarthritis, which is believed to be the source of groin pain and reduced physical function. Although we observed high morbidity of osteoarthritis in the studied cohort, the severity of pain was not proportional to the severity of osteoarthritis. We recorded four patients without hip osteoarthritis complained of moderate groin pain, and two patients with doubtful hip osteoarthritis complained of intense groin pain. Because chronic pain is a

complex of subjective sensory and emotional experience, and psycho-behavioural problems are not uncommon among these special patients [38], we daringly hypothesise this inexplicable groin pain can somewhat be ascribed to chronic pain sensitisation or depression.

A significant limitation of our study is the lack of SARS patients with or without medical interventions as control. However, there is still no treatment-as-usual available, and it would not have been ethical to give placebo treatment as well. A similar study reported combined vasoactive pharmacotherapy could successfully prevent collapse, but their 14-year study only included four SARS patients [39]. On the other hand, few clinical trials concerning ONFH can be followed up for a long term. Published studies mostly reported their results after a follow-up duration of only 2 or 3 years [4,33,40], but the previous study had reported that the interval between diagnosis and collapse could be over 4 years in 46% of cases [41]. In comparison to the natural collapse rate of 49% reported by a systematic review that included the most hips with ONFH [27], our study observed a collapse rate of 26% based on prolonged follow-up data, supporting that HGF helps prevent the natural disease progression of ONFH.

To the best of our knowledge, this is the first study that addresses the longest-term outcomes of Chinese medicine therapy for steroid-associated ONFH. The results of this 14-year follow-up study support

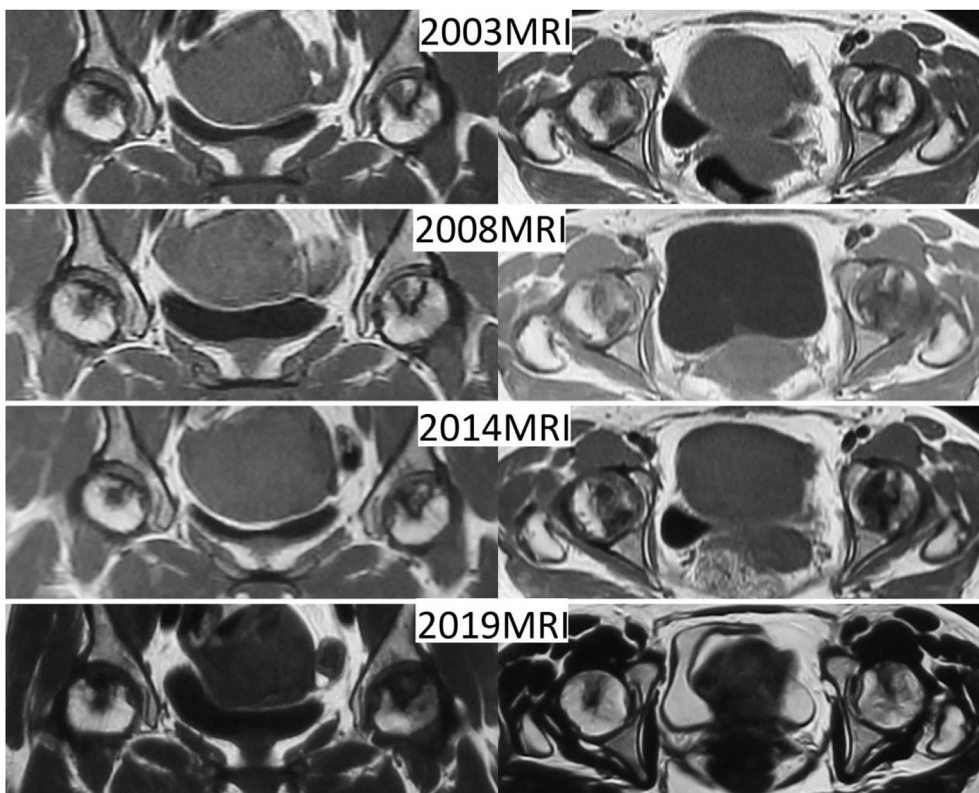


Fig. 6. MRI from a 35-year-old female (patient number SARS03017) with ONFH received HGF therapy in 2003. Series MRI (from 2003 to 2019) showed the development of focal low signal lesion. MRI in 2019 suggested a complete sclerosis (low signal lesion) in the necrotic lesions. HGF = Huo-Gu formula; MRI = magnetic resonance imaging; ONFH = osteonecrosis of the femoral head.

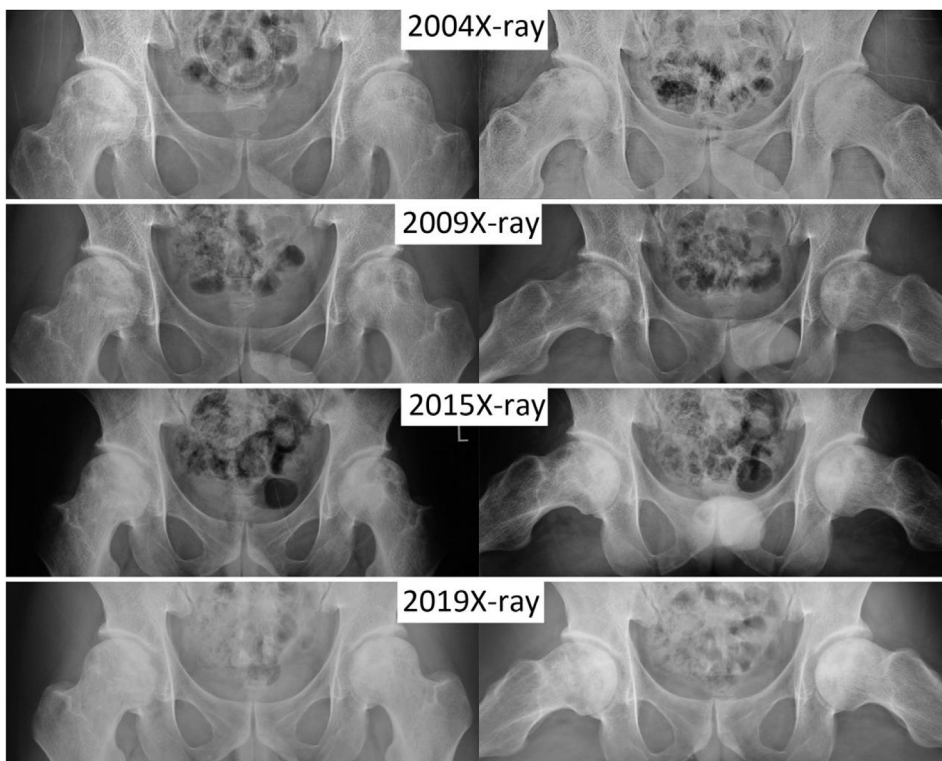


Fig. 7. Medical imaging series from a 43-year-old male (patient number SARS03022) with ONFH received HGF therapy in 2004. Plain radiographs in 2004 suggested bilateral ONFH (left: ARCO Stage III and JIC Type C2, right: ARCO Stage II and JIC Type C2). Plain radiographs series (from 2009 to 2019) showed the development of sclerosis in the necrotic lesions and osteoarthritis in the hip joints. ARCO = Association Research Circulation Osseous; HGF = Huo-Gu formula; ONFH = osteonecrosis of the femoral head.

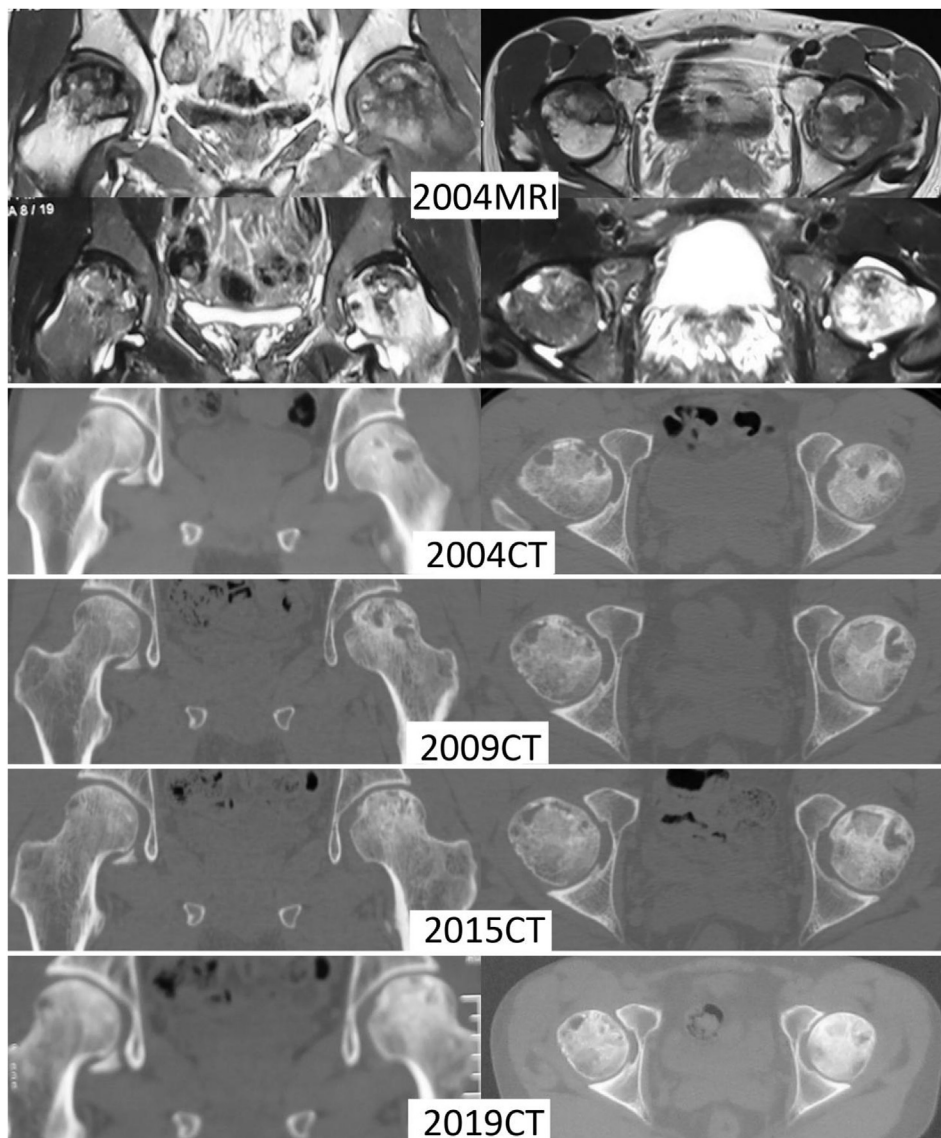


Fig. 8. Medical imaging series from a 43-year-old male (patient number SARS03022) with ONFH received HGF therapy in 2004. MRI in 2004 suggested extensive bone marrow oedema in the left femoral head. Series CT (from 2004 to 2019) showed the development of sclerosis and cyst in the necrotic lesions. CT in 2019 demonstrated a replete sclerosis in the necrotic lesions. CT images in 2019 confirmed the presence of osteoarthritis (left: K–L Grade 2, right: K–L Grade 2) without severe depression of femoral head. CT = computed tomography; HGF = Huo-Gu formula; MRI = magnetic resonance imaging; ONFH = osteonecrosis of the femoral head.

the role of HGF, a spleen-invigorating Chinese herbal medication for the treatment of steroid-associated ONFH, for deferring the time for THA, preventing progression to femoral head collapse, maintaining the physical function. Despite our long-term observation supported high morbidity of hip osteoarthritis, patients experienced inexplicable groin pain that is not correlated to the severity of hip osteoarthritis. Nevertheless, HGF should be considered as an effective therapeutic option for steroid-associated ONFH.

Funding information

This study was supported by grants from “Twelfth Five-Year” National Science and Technology Support Program (No. 2015BAI04B03), National Natural Science Foundation of China (No. 81473695 and 81973888) and Beijing Municipal Natural Science Foundation (No. 7182186).

Informed consent

Informed consent was obtained from the individual participant included in the study.

Data availability statement

Raw data were generated at Wangjing Hospital. Derived data supporting the findings of this study are available from the corresponding authors on request.

Conflict of Interest

The authors have no conflicts of interest to disclose in relation to this article.

References

- [1] Tsang K, Zhong NS. SARS: pharmacotherapy. *Respirology* 2003;8(Suppl):S25–30.
- [2] Guan WJ, Ni ZY, Hu Y, Liang WH, Ou CQ, He JX, et al. Clinical characteristics of coronavirus disease 2019 in China. *N Engl J Med* 2020. <https://doi.org/10.1056/NEJMoa2002032>. In press.
- [3] Zhao R, Wang H, Wang X, Feng F. Steroid therapy and the risk of osteonecrosis in SARS patients: a dose-response meta-analysis. *Osteoporos Int* 2017;28(3):1027–34.
- [4] Li ZR, Cheng LM, Wang KZ, Yang NP, Yang SH, He W, et al. Herbal Fufang Xian Ling Gu Bao prevents corticosteroid-induced osteonecrosis of the femoral head-A first multicentre, randomised, double-blind, placebo-controlled clinical trial. *J Orthop Translat* 2018;12:36–44.

- [5] Mont MA, Cherian JJ, Sierra RJ, Jones LC, Lieberman JR. Nontraumatic osteonecrosis of the femoral head: where do we stand today? A ten-year update. *J Bone Joint Surg Am* 2015;97(19):1604–27.
- [6] Cao H, Guan H, Lai Y, Qin L, Wang X. Review of various treatment options and potential therapies for osteonecrosis of the femoral head. *J Orthop Translat* 2016;4: 57–70.
- [7] Lee YJ, Cui Q, Koo KH. Is there a role of pharmacological treatments in the prevention or treatment of osteonecrosis of the femoral head?: A systematic review. *J Bone Metab* 2019;26(1):13–8.
- [8] Mont MA, Jones LC, Hungerford DS. Nontraumatic osteonecrosis of the femoral head: ten years later. *J Bone Joint Surg Am* 2006;88(5):1117–32.
- [9] Li S, Zhang B. Traditional Chinese medicine network pharmacology: theory, methodology and application. *Chin J Nat Med* 2013;11(2):110–20.
- [10] Wei QS, Hong GJ, Yuan YJ, Chen ZQ, Zhang QW, He W, Huo Xue Tong Luo capsule, a vasoactive herbal formula prevents progression of asymptomatic osteonecrosis of femoral head: a prospective study. *J Orthop Translat* 2019;18:65–73.
- [11] Zhao DW, Hu YC. Chinese experts' consensus on the diagnosis and treatment of osteonecrosis of the femoral head in adults. *Orthop Surg* 2012;4(3):125–30.
- [12] Microsurgery Department of the Orthopedics Branch of the Chinese Medical Doctor Association, Group from the Osteonecrosis and Bone Defect Branch of the Chinese Association of Reparative and Reconstructive Surgery, Microsurgery and Reconstructive Surgery Group of the Orthopedics Branch of the Chinese Medical Association. Chinese guideline for the diagnosis and treatment of osteonecrosis of the femoral head in adults. *Orthop Surg* 2017 Feb;9(1):3–12.
- [13] Zhao DW, Zhang F, Wang BJ, Liu BY, Li L, Kim SY, et al. Guidelines for clinical diagnosis and treatment of osteonecrosis of the femoral head in adults. *J Orthop Translat* 2020;21:100–10.
- [14] Zhang Q, Yang F, Chen Y, Wang H, Chen D, He W, et al. Chinese herbal medicine formulas as adjuvant therapy for osteonecrosis of the femoral head: a systematic review and meta-analysis of randomized controlled trials. *Medicine (Baltim)* 2018; 97(36):e12196.
- [15] Wang A, Ren M, Wang J. The pathogenesis of steroid-induced osteonecrosis of the femoral head: a systematic review of the literature. *Gene* 2018;671:103–9.
- [16] Wang J, Wang Q, Li L, Li Y, Zhang H, Zheng L, et al. Phlegm-dampness constitution: genomics, susceptibility, adjustment and treatment with traditional Chinese medicine. *Am J Chin Med* 2013;41(2):253–62.
- [17] Jiang Y, Liu D, Kong X, Xu Y, Chen W, Lin N. Huogulformula prevents steroid-induced osteonecrosis in rats by down-regulating PPAR γ expression and activating Wnt/LRP5/ β -catenin signaling. *J Tradit Chin Med* 2014;34(3):342–50.
- [18] Chen WH, Kong XY, Wan R, Xiao CS, Li L, Wang ZY, et al. Effects of Huogu I formula (I) on correlated factors of bone regeneration in chickens with steroid-induced necrosis of femoral head. *Chin J Integr Med* 2012;18(5):378–84.
- [19] Kong X, Li X, Zhang C, Zhu L, Liu C, Qin Q, et al. Ethyl acetate fraction of Huogu formula inhibits adipogenic differentiation of bone marrow stromal cells via the BMP and Wnt signaling pathways. *Int J Biol Sci* 2017;13(4):480–91.
- [20] Kong X, Li X, Zhang C, Zhu L, Wan H, Zhu J, et al. Aqueous fraction of huogu formula promotes osteogenic differentiation of bone marrow stromal cells through the BMP and wnt signaling pathways. *Rejuvenation Res* 2016;19(6):509–20.
- [21] Gardeniers JWM. Report of the committee of staging and nomenclature. *ARCO News Letter* 1993;5(2):79–82.
- [22] Guo X, Chen W, Zhao Y. The three-stage syndrome differentiation system for aseptic osteonecrosis of the femoral head: a case series study of 50 patients. *Proc China Sympo aseptic Osteonecrosis Femoral Head* 1992:310–3.
- [23] Harris WH. Traumatic arthritis of the hip after dislocation and acetabular fractures: treatment by mold arthroplasty. An end-result study using a new method of result evaluation. *J Bone Joint Surg Am* 1969;51(4):737–55.
- [24] Xue Z, Sun J, Li T, Huang Z, Chen W. How to evaluate the clinical outcome of joint-preserving treatment for osteonecrosis of the femoral head: development of a core outcome set. *J Orthop Surg Res* 2019;14(1):317.
- [25] Kellgren JH, Lawrence JS. Radiological assessment of osteo-arthrosis. *Ann Rheum Dis* 1957;16(4):494–502.
- [26] Chen W, Liu D, Zhang Q, Sun G, Zhou W, Wang S, et al. The characteristics of TCM syndrome of ONFH in SARS patients and optimized treatment (Part 1). *Chin Med Mod Distance Educ China* 2006;4(10):55–6.
- [27] Mont MA, Zywiell MG, Marker DR, McGrath MS, Delanois RE. The natural history of untreated asymptomatic osteonecrosis of the femoral head: a systematic literature review. *J Bone Joint Surg Am* 2010;92(12):2165–70.
- [28] Nilsson A, Bremander A. Measures of hip function and symptoms: Harris hip score (HHS), hip disability and osteoarthritis outcome score (HOOS), oxford hip score (OHS), lequesne index of severity for osteoarthritis of the hip (LISOH), and American academy of Orthopedic Surgeons (AAOS) hip and knee questionnaire. *Arthritis Care Res* 2011;63(Suppl 11):S200–7.
- [29] Dobson F, Hinman RS, Hall M, Marshall CJ, Sayer T, Anderson C, et al. Reliability and measurement error of the Osteoarthritis Research Society International (OARSI) recommended performance-based tests of physical function in people with hip and knee osteoarthritis. *Osteoarthritis Cartilage* 2017 Nov;25(11):1792–6.
- [30] Haberal B, Şahin O, Şimşek EK, Mahmuti A, Tuncay İC. Outcomes for core decompression with multiple drilling of the osteonecrosis of the femoral head in patients with solid organ transplantation. *Eklem Hastalik Cerrahisi* 2018;29(3): 159–64.
- [31] Hao YQ, Guo H, Zhu T, Xu ZC, Qi HD, Lu C, et al. Core decompression, lesion clearance and bone graft in combination with Tongluo Shenggu decoction for the treatment of osteonecrosis of the femoral head: a retrospective cohort study. *Medicine (Baltim)* 2018 Oct;97(41):e12674.
- [32] Lai KA, Shen WJ, Yang CY, Shao CJ, Hsu JT, Lin RM. The use of alendronate to prevent early collapse of the femoral head in patients with nontraumatic osteonecrosis. A randomized clinical study. *J Bone Joint Surg Am* 2005;87(10): 2155–9.
- [33] Cao L, Guo C, Chen J, Chen Z, Yan Z. Free vascularized fibular grafting improves vascularity compared with core decompression in femoral head osteonecrosis: a randomized clinical trial. *Clin Orthop Relat Res* 2017;475(9):2230–40.
- [34] van der Jagt D, Mokete L, Pietrzak J, Zalavras CG, Lieberman JR. Osteonecrosis of the femoral head: evaluation and treatment. *J Am Acad Orthop Surg* 2015;23(2): 69–70.
- [35] Hong YC, Luo RB, Lin T, Zhong HM, Shi JB. Efficacy of alendronate for preventing collapse of femoral head in adult patients with nontraumatic osteonecrosis. *BioMed Res Int* 2014;2014:716538.
- [36] Chen CH, Chang JK, Lai KA, Hou SM, Chang CH, Wang GJ. Alendronate in the prevention of collapse of the femoral head in nontraumatic osteonecrosis: a two-year multicenter, prospective, randomized, double-blind, placebo-controlled study. *Arthritis Rheum* 2012;64(5):1572–8.
- [37] Hua KC, Yang XG, Feng JT, Wang F, Yang L, Zhang H, et al. The efficacy and safety of core decompression for the treatment of femoral head necrosis: a systematic review and meta-analysis. *J Orthop Surg Res* 2019 Sep 11;14(1):306.
- [38] Liu X, Kakade M, Fuller CJ, Fan B, Fang Y, Kong J, et al. Depression after exposure to stressful events: lessons learned from the severe acute respiratory syndrome epidemic. *Compr Psychiatr* 2012;53(1):15–23.
- [39] Wang W, Zhang N, Guo W, Gao F. Combined pharmacotherapy for osteonecrosis of the femoral head after severe acute respiratory syndrome and interstitial pneumonia: two and a half to fourteen year follow-up. *Int Orthop* 2018;42(7): 1551–6.
- [40] Lee YK, Ha YC, Cho YJ, Suh KT, Kim SY, Won YY, et al. Does zoledronate prevent femoral head collapse from osteonecrosis? A prospective, randomized, open-label, multicenter study. *J Bone Joint Surg Am* 2015 July 15;97(14):1142–8.
- [41] Min BW, Song KS, Cho CH, Lee SM, Lee KJ. Untreated asymptomatic hips in patients with osteonecrosis of the femoral head. *Clin Orthop Relat Res* 2008;466(5): 1087–92.