



Contents lists available at ScienceDirect

## International Journal of Surgery Case Reports

journal homepage: [www.casereports.com](http://www.casereports.com)

## Necrotizing soft tissue infection after liposculpture; Case report

Raul Cuevas Bustos<sup>a</sup>, Oscar Cervantes Gutierrez<sup>a</sup>, Felix Alejandro Perez Tristan<sup>a</sup>, Alejandro Acuña Macouzet<sup>a</sup>, Angel Flores-Huidobro Martinez<sup>b</sup>, Marcos Jafif Cojab<sup>a,\*</sup><sup>a</sup> Department of Surgery Hospital Angeles Lomas, Edo. Mexico, Mexico<sup>b</sup> Universidad Anahuac, Edo. Mexico, Mexico

## ARTICLE INFO

## Article history:

Received 20 October 2020

Received in revised form

11 November 2020

Accepted 12 November 2020

Available online 22 November 2020

## ABSTRACT

**INTRODUCTION:** Liposculpture procedures have a complication rate of 5%, with the majority being minor complications. Infections in isolated liposuction procedures are as low as 0.1 % of cases. Necrotizing infections can occur after major traumatic injuries, as well as after minor breaches of the skin or mucosa. Here we present a case of a 53-year-old female patient who underwent cosmetic surgery and developed a necrotizing soft tissue infection and we will discuss the importance of early diagnosis, risk factors and preventive measures, treatment options and our management of this particular case.

**PRESENTATION OF CASE:** 53-year-old female patient with a history of multiple cosmetic surgeries, with no significant past medical history, she presented fever and disabling pain at the surgical site with extensive bullae formation; during her fourth post operative day, she presented septic shock that required vasopressor support and mechanical ventilation, accompanied by acute renal failure which required admission to the intensive care unit.

The patient's relatives requested air transportation to bring the patient to our center.

The patient remained hospitalized for 42 days in which 15 surgical interventions were performed including multiple surgical wound cleansing and debridement as well as placement of a negative pressure wound therapy system, flaps advancement, lesions reconstruction, graft procurements and insertions.

**DISCUSSION:** Antibiotic prophylaxis is recommended preferably with a second-generation cephalosporin, one hour prior to surgery and should be continued for 5–6 days afterwards. Likewise, prophylaxis with Flucloxacillin or gentamicin is recommended in the case of liposuction and or abdominoplasty. The microorganisms most frequently isolated in post-liposuction infections are Staphylococcus aureus, Streptococcus group A, Streptococcus pyogenes, and synergistic infections with anaerobes and facultative pathogens.

Among the most severe complications of liposuction is necrotizing soft tissue infection (NSTI), which is an infection of the subcutaneous tissue that spreads to the underlying dermis and sometimes beyond including the fascia and muscle.

**CONCLUSION:** Rapid recognition of NSTI is life-saving and urgent, extensive debridement and prophylactic antibiotics are the mainstay treatment for this condition, multiple debridement procedures may be necessary for successful treatment.

© 2020 The Authors. Published by Elsevier Ltd on behalf of IJS Publishing Group Ltd. This is an open access article under the CC BY-NC-ND license (<http://creativecommons.org/licenses/by-nc-nd/4.0/>).

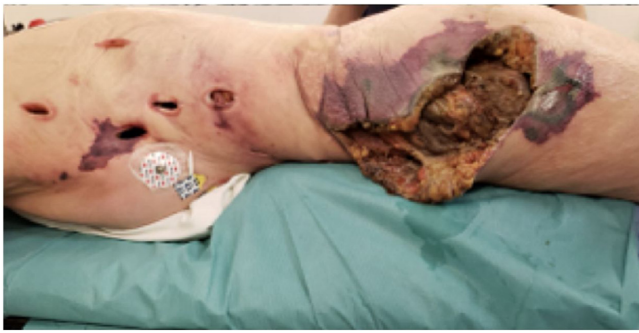## 1. Introduction

Liposculpture is an aesthetic surgical procedure that consists of removing adipose tissue from certain areas and transferring it to where the patients desire to obtain greater volume to improve body contour. This is accomplished by using suction cannulas through small incisions in the skin with minimal scarring and recurrence.

Worldwide, it is estimated that this procedure has a complication rate of 5%, with the majority being minor complications.

The leading cause of death among liposuction complications is pulmonary thromboembolism followed by fat embolism, pulmonary edema, lidocaine intoxication, and intra-abdominal visceral injury [1]. Infections in isolated liposuction procedures are reported as only 0.1 % of cases, however in multiple procedures it raises to 0.7 % of cases, usually after the presence of hematomas [2–4]. Certain risk factor have shown to increase the probability of infections following aesthetic procedures, thus measures have been designed to prevent them, however, in a small percentage of cases, infections can occur even when proper preventive measures are taken. Here we present a case of a 53-year-old female patient who underwent cosmetic surgery and developed a necrotizing soft tissue infection

\* Corresponding author at: Department of Surgery, Vialidad de la barranca S/N, Hospital Angeles Lomas Huixquilucan Edo, 52763, Mexico.  
E-mail address: [drmarcosjafif@gmail.com](mailto:drmarcosjafif@gmail.com) (M. Jafif Cojab).



**Fig. 1.** Initial findings in first surgical wound cleansing and debridement showing extensive soft tissue necrotizing infection with deep tissue penetration around sites of prior liposuction and fat graftings injection.

and we will discuss the importance of early diagnosis, treatment options and our management of this particular case

\*This work has been reported in line with the SCARE criteria ([17])

## 2. Presentation of case

A 53-year-old female patient with a history of multiple cosmetic surgeries, with no additional significant medical history, began her condition after undergoing liposculpture surgery in which wide liposuction of the dorsal region, flanks and thighs with fat graft insertion into the gluteal area was performed in an outpatient surgery clinic at a northern state of Mexico.

Within the first 7 postoperative days, she presented fever and disabling pain at the surgical site with extensive bullae formation; during her fourth postoperative day, she presented signs of septic shock that required vasopressor support and mechanical ventilation, accompanied by acute renal failure, therefore she was admitted to the intensive care unit at her local hospital.

The patient's relatives requested air transportation to bring the patient to our center. Upon admission to our institution, she persisted with septic shock that required vasopressor support and mechanical ventilation; multiple and extensive lesions ranging from the pelvis to the neck were observed with the presence of subcutaneous emphysema, leakage of purulent material, erythema and necrosis at the wound edges (Fig. 1).

A CT scan of the abdomen was requested, which revealed cutaneous dehiscence towards the left and right flanks, extending to the iliac crests, left gluteal region and perineal region. Extensive generalized soft tissue emphysema from the base of the neck to the assessed portion of the upper third of the thighs. The air dissected some of the muscular planes and striation of subcutaneous fatty tissue was also identified at the thoracic and predominantly abdominopelvic level (Figs. 2–4).

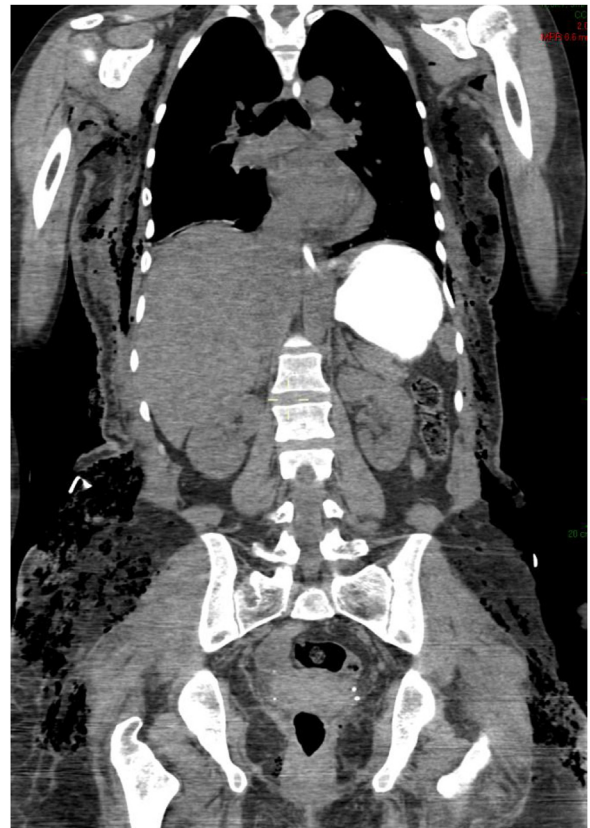
The diagnosis of necrotizing soft tissue infection (NSTI) was integrated, we emphasized surgical wound cleansing by mechanical scrubbing and debridement, use of prophylactic antibiotics and correct identification of the pathogen involved.

It was decided to perform a surgical intervention for drainage, debridement of necrotic tissue and placement of a negative pressure therapy system (Fig. 5) [5–8].

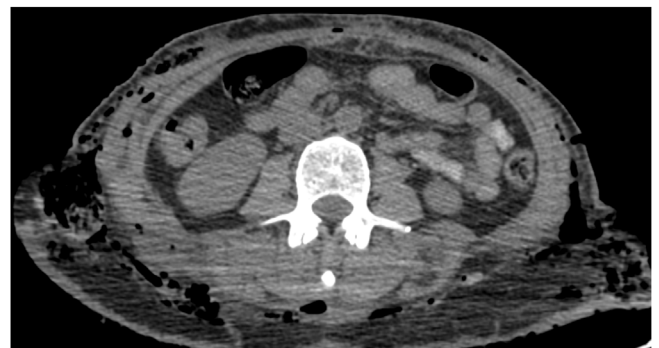
She was admitted to the Intensive Care Unit due to the presence of metabolic acidosis, hyperlactatemia, leukocytosis with a left shift, thrombocytopenia, elevated CRP, ESR, and hyperglycemia.

The patient remained in the intensive care unit for 7 days until the source of infection was controlled and hemodynamic stabilization was achieved.

The patient remained hospitalized for 42 days in which 15 surgical interventions were performed including multiple wound



**Fig. 2.** CT Scan showing subcutaneous emphysema extending from the soft tissues of the thorax to the iliac crests.

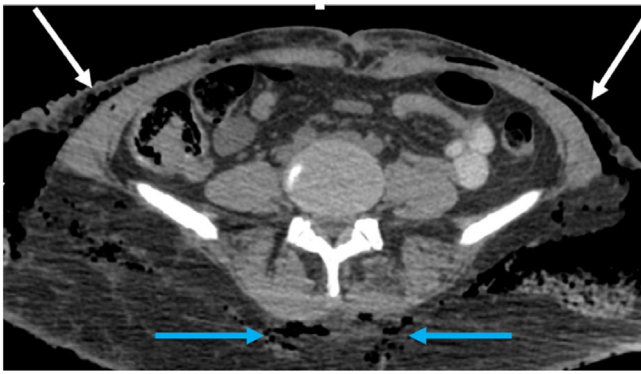


**Fig. 3.** Axial CT scan showing significant gas in subcutaneous soft tissues of the lateral abdominal walls with subcutaneous emphysema (bold arrows) as well as subcutaneous edema surrounding the anterior and posterior abdominal muscles and fascias (thin arrows).

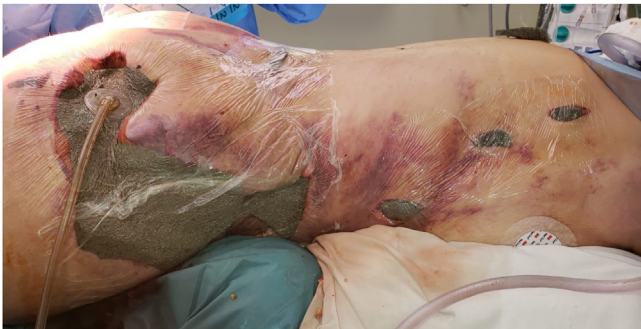cleansing and debridement as well as placement of a negative pressure therapy system, advancement of flaps, lesions reconstruction, procurement and placement of grafts. (Figs. 6–9).

Secretion cultures were requested during the various surgical procedures in which *E. Coli*, *Finegoldia magna* (peptostreptococcus magnus) and *Streptococcus mitis* were found. During the course of treatment, antibiotic management was imperative with Vancomycin, Meropenem and Clindamycin.

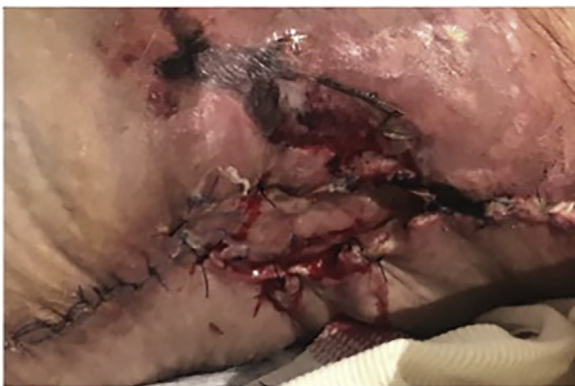After 42 days the patient was discharged without further complications, followed by an intensive rehabilitation program. To our knowledge, there have been no further complications with this patient.



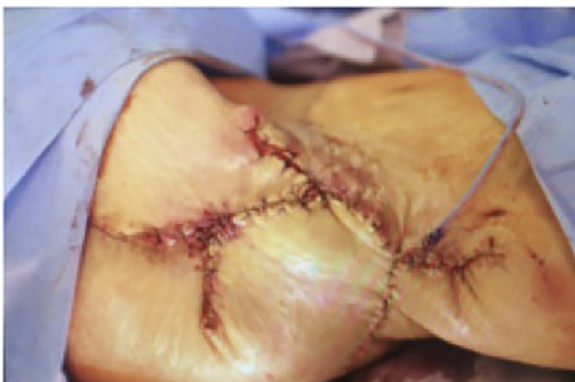**Fig. 4.** Axial CT scan shows subcutaneous emphysema in the fat surrounding the abdominal oblique muscles (thick white arrow) the iliac bones (thin white arrow) and paravertebral muscles (blue arrows).



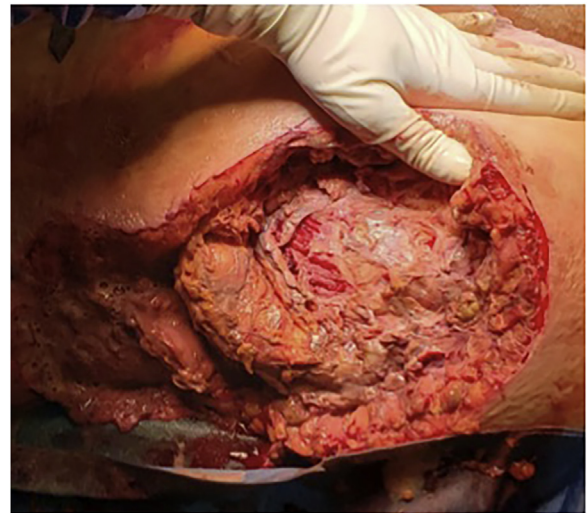
**Fig. 5.** Results after the first wound cleansing, debridement, dressing and starting of negative pressure wound therapy.



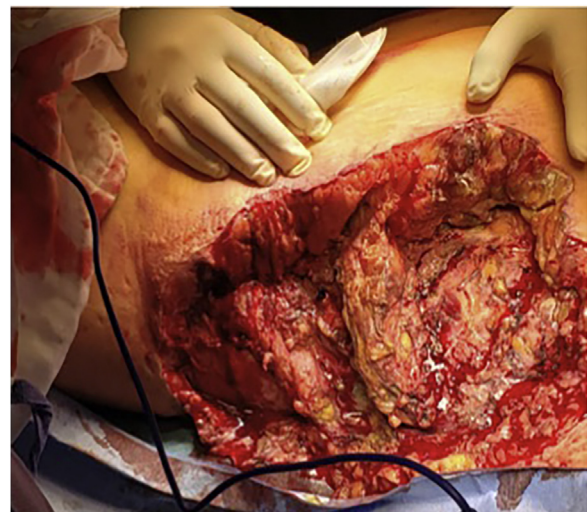
**Fig. 6.** Intra operative image showing extensive wound debridement with multiple areas of necrotic tissue extending to the muscular fascia.



**Fig. 7.** Intra-operative images showing extensive area of necrosis; multiple debridement procedures were required to find healthy tissue to promote healing.



**Fig. 8.** Wound edges re-approximation by delayed primary closure with a partial skin graft after 13 previous debridement and advancements.



**Fig. 9.** All wound edges were re-approximated with tissue healing and cosmesis achieved.

**3. Discussion**

Infections in isolated liposuction procedures are reported as only 0.1 % of cases, within the preparation of a patient for a liposculpture procedure, which is defined as a liposuction of less than 4 L with or without fat grafting. It is recommended to start antibiotic prophylaxis, preferably with a second-generation cephalosporin, one hour prior to scheduled surgery and continue it for 5–6 days afterwards [9,10]. Likewise, prophylaxis with Flucloxacillin or gentamicin is recommended in the case of liposuction and/or abdominoplasty [11–13]. In this case, there is no information on prophylactic or antibiotic treatment prior to the first intervention.

The microorganisms most frequently isolated in post-liposuction infections are *Staphylococcus aureus*, *Streptococcus* group A, *Streptococcus pyogenes*, and synergistic infections with anaerobes and facultative [9,13].

Among the culture results, *Fingoldia magna* was found, gram-positive anaerobic cocci common to the gastrointestinal and genitourinary flora. It can be found in the context of polymicrobial infections, such as the case described here, considered a contami-

nant in cultures that involve access through the oral cavity or skin, however it has been proposed as a possible cause of toxic shock syndrome [14]. Another pathogen isolated in this patient was *Streptococcus mitis*.

In comparison to other cases, we find our case unique because of the extension of the wounds and our management with negative pressure wound therapy. We followed the World Society of Emergency Surgery (WSES) Guidelines for Management of Skin and Soft Tissue Infections recommendations and even when negative pressure wound therapy is not part of the conventional recommendations, and according to other studies, its use is still controversial, we had positive outcomes with this approach in terms of wound healing and pain control [7,17–23].

One of the most serious complications of liposuction is necrotizing soft tissue infection (NSTI), which is an infection of the subcutaneous tissue that spreads to the underlying dermis and sometimes beyond including the fascia and muscle, attributed to perforation of the abdominal viscus, inadequate sterilization of instruments or direct contamination of the wound [9,10,15,16].

Main risk factors for NSTI include: Diabetes Mellitus, peripheral vascular disease, immunosuppression, malnutrition, major traumatic injuries, as well as minor injuries to the skin or mucosa [3,4,10]. Among the highlights of this case, is the fact that NSTI can occur in a small percentage of the population even when appropriate prophylactic measures are taken and no risk factors are present, thus, surgeons must remain aware of this complications and have an early diagnostic suspicion that allows timely management, which as seen in this case, can be lifesaving. Should our patient have not been transferred in a timely manner to a center with the appropriate resources and facilities, outcomes could have been fatal. This case has been reported in line with the SCARE Guideline 2018. [24]

#### 4. Conclusion

In all patients undergoing elective surgery, surgeons must be aware of the degree of pain and abnormal or unusual signs during postoperative follow-up. Consider antibiotic prophylaxis as well as therapy if necessary. Rapid recognition of NSTI is life saving; with urgent extensive debridement and prophylactic antibiotics as the mainstay of treatment for this condition, multiple debridement procedures may be necessary for successful outcomes. Negative pressure wound therapy system was of utmost importance for our case in order to increase tissue perfusion, avoid bacterial overgrowth, pain management and wound edge approximation for primary closure.

#### Declaration of Competing Interest

There was no conflict of interest.

#### Funding

There was no sponsorship for this study.

#### Ethical approval

There was no need for ethical approval.

#### Consent

Written informed consent was obtained from the patient for publication of this case report and accompanying images. A copy of the written consent is available for review by the Editor-in-Chief of this journal on request

#### Author contribution

Raul Alexander; Cuevas Bustos MD: Data collection, data analysis, writing the paper

Oscar Cervantes Gutierrez MD: Data collection, data analysis

Felix Alejandro Perez Trsitán MD: Data collection, data analysis

Alejandro Acuña Macouzet MD: Data collection, data analysis

Angel Flores-Huidobro Martínez MD: Data collection, data analysis

Marcos; Jaff Cojab MD: Data collection, data analysis, writing the paper

#### Guarantor

Raul Alexander; Cuevas Bustos MD

#### References

- [1] L. Cárdenas-Camarena, H. Durán, J.A. Robles-Cervantes, J.E. Bayter-Marín, Critical differences between microscopic (MIFE) and macroscopic (MAFE) fat embolism during liposuction and gluteal lipoinjection, *Plast. Reconstr. Surg.* 141 (4) (2018) 880–890.
- [2] V.V. Dixit, M.S. Wagh, Unfavourable outcomes of liposuction and their management, *Indian J. Plast. Surg.* 46 (2) (2013) 377.
- [3] C. Kaoutzanis, V. Gupta, J. Winocour, J. Layliev, R. Ramirez, J.C. Grotting, et al., Cosmetic liposuction: preoperative risk factors, major complication rates, and safety of combined procedures, *Aesthet. Surg. J.* 37 (6) (2017) 680–694.
- [4] C. Kaoutzanis, V. Gupta, J. Winocour, B. Shack, J.C. Grotting, K. Higdon, Incidence and risk factors for major surgical site infections in aesthetic surgery: analysis of 129,007 patients, *Aesthet. Surg. J.* 37 (1) (2017) 89–99.
- [5] V. Strugala, R. Martin, Meta-analysis of comparative trials evaluating a prophylactic single-use negative pressure wound therapy system for the prevention of surgical site complications, *Surg. Infect.* 18 (7) (2017) 810–819.
- [6] H. Birke-Sorensen, M. Malmsjo, P. Rome, D. Hudson, E. Krug, L. Berg, et al., Evidence-based recommendations for negative pressure wound therapy: treatment variables (pressure levels, wound filler and contact layer)–steps towards an international consensus, *J. Plast. Reconstr. Aesthetic Surg.* 64 (2011) S1–S16.
- [7] R. Cirocchi, A. Birindelli, W.L. Biffl, V. Mutafchyski, G. Popivanov, O. Chiara, et al., What is the effectiveness of the negative pressure wound therapy (NPWT) in patients treated with open abdomen technique? A systematic review and meta-analysis, *J. Trauma Acute Care Surg.* 81 (3) (2016) 575–584.
- [8] S. Fischer, J. Wall, B. Pomahac, R. Rivello, E.G. Halvorson, Extra-large negative pressure wound therapy dressings for burns—initial experience with technique, fluid management, and outcomes, *Burns* 42 (2) (2016) 457–465.
- [9] D.L. Stevens, A.E. Bryant, Necrotizing soft-tissue infections, *N. Engl. J. Med.* 377 (23) (2017) 2253–2265.
- [10] D.C. Elliott, J.A. Kufera, R.A. Myers, Necrotizing soft tissue infections. Risk factors for mortality and strategies for management, *Ann. Surg.* 224 (5) (1996) 672.
- [11] C.-H. Wong, H.-C. Chang, S. Pasupathy, L.-W. Khin, J.-L. Tan, C.-O. Low, Necrotizing fasciitis: clinical presentation, microbiology, and determinants of mortality, *JBJS.* 85 (8) (2003) 1454–1460.
- [12] A. Marchesi, S. Marcelli, P.C. Parodi, R.E. Perrotta, M. Riccio, L. Vaienti, Necrotizing fasciitis in aesthetic surgery: a review of the literature, *Aesthetic Plast. Surg.* 41 (2) (2017) 352–358.
- [13] M.S. Pasternack, Cellulitis, Necrotizing Fasciitis, and Subcutaneous Tissue Infections, Mandell, Douglas, and Bennett's Principles and Practice of Infectious Diseases, 2010, pp. 1289–1312, 1.
- [14] Y. Song, S.M. Finegold, Peptostreptococcus, Finegoldia, Anaerococcus, Peptoniphilus, Veillonella, and other anaerobic cocci, *Manual Clin. Microbiol.* (2015) 909–919.
- [15] E.J. Goldstein, D.A. Anaya, E.P. Dellinger, Necrotizing soft-tissue infection: diagnosis and management, *Clin. Infect. Dis.* 44 (5) (2007) 705–710.
- [16] G. Sattler, S. Eichner, Complications of liposuction, *Hautarzt* 64 (3) (2013) 171–179.
- [17] M. Sartelli, M.A. Malangoni, A.K. May, P. Viale, L.S. Kao, F. Catena, et al., World Society of Emergency Surgery (WSES) guidelines for management of skin and soft tissue infections, *World J. Emerg. Surg.* 9 (1) (2014) 57.
- [18] K. Arvesen, C.B. Nielsen, K. Fogh, Accelerated wound healing with combined NPWT and IPC: a case series, *Br. J. Community Nurs.* 22 (Sup3) (2017), S41–S5.
- [19] J. Hampton, Providing cost-effective treatment of hard-to-heal wounds in the community through use of NPWT, *Br. J. Community Nurs.* 20 (Sup6) (2015) S14–S20.
- [20] C. Monsen, S. Acosta, K. Mani, C. Wann-Hansson, A randomised study of NPWT closure versus alginate dressings in peri-vascular groin infections: quality of life, pain and cost, *Journal of wound care.* 24 (6) (2015) 252–260.

- [21] S. Riot, G. de Bonnecaze, I. Garrido, G. Ferron, J.-L. Grolleau, B. Chaput, Is the use of negative pressure wound therapy for a malignant wound legitimate in a palliative context? "The concept of NPWT ad vitam": a case series, *Palliat. Med.* 29 (5) (2015) 470–473.
- [22] P. Rys, S. Borys, J. Hohendorff, A. Zapala, P. Witek, M. Monica, et al., *NPWT In Diabetic Foot Wounds—a Systematic Review and Meta-analysis of Observational Studies*, Springer, 2020.
- [23] N. Vaidhya, A. Panchal, M. Anchalia, A new cost-effective method of NPWT in diabetic foot wound, *Indian J. Surg.* 77 (2) (2015) 525–529.
- [24] R.A. Agha, M.R. Borrelli, R. Farwana, K. Koshy, A. Fowler, D.P. Orgill, For the SCARE Group. The SCARE, Statement: updating consensus surgical CAse REport (SCARE) guidelines, *Int. J. Surg.* 2018 (60) (2018) 132–136.

#### Open Access

This article is published Open Access at [sciencedirect.com](https://www.sciencedirect.com). It is distributed under the [IJSCR Supplemental terms and conditions](#), which permits unrestricted non commercial use, distribution, and reproduction in any medium, provided the original authors and source are credited.