



Case Report

Recurrent hematuria: A rare presentation of leiomyosarcoma of the prostate



Ahmed Loghmani^{a,*}, Mouna Ben Othmane^a, Oussama Belkacem^b, Khaireddine Bouassida^a,
Wisssem Hmida^a, Mehdi Jaidane^a

^a Urology Department, Sahloul Hospital, Sousse, Tunisia

^b Pathology Department, Sahloul Hospital, Sousse, Tunisia

ARTICLE INFO

Keywords:

Leiomyosarcoma
Hematuria
Prostate
Sarcoma
Case report

ABSTRACT

Introduction and Importance: Prostatic leiomyosarcoma is a rare aggressive tumor. The presentation came with non-specific signs and symptoms likewise other forms of prostatic pathology like benign prostatic hyperplasia. **Case presentation:** A 64 years old man presented to the emergency with a recurrent macroscopic hematuria, he was a heavy smoker and has reported lower urinary tract symptoms. On the physical examination, the patient was hemodynamically stable and afebrile. However, the digital rectal exam revealed an enlarged homogeneous prostate without any palpable nodule. Pelvic transabdominal ultrasound showed an enlarged prostate and a thickening of the bladder's left lateral wall. The CT-scan showed a large and heterogeneous mass arising from the left bladder wall measuring 100 mm, which extends through almost the entire bladder wall. Furthermore, the patient performed cystoscopy, performed by a Urology Professor, showing a normal urethra, a normal prostate gland, and a large solid bladder mass with multiple clots. Subsequently, multiple masses' biopsies were performed. The diagnosis of a primary prostatic leiomyosarcoma was based on the clinical findings and on the histopathological exam. The patient was prepared for a radical cystoprostatectomy, which would be performed by a Urology Professor, but he died of cardiac arrest before undergoing surgery.

Clinical discussion: There are no specific clinical presentations of prostatic sarcoma, patients normally complain of urinary frequency and urinary urgency. Due to the lack of typical clinical symptoms, the tumor is easily overlooked or misdiagnosed as benign prostatic hyperplasia. In this case, the first symptom was a recurrent hematuria in a 64 years-old heavy smoker, which is a relatively rare obvious symptom according to literature. As showed in this case, recurrent hematuria may delay the diagnosis. Concerning the management of prostatic leiomyosarcoma, there are no standard recommendations. Multimodality combination treatments including surgery, pre or postoperative radiotherapy and neo or adjuvant chemotherapy have been used in the management of leiomyosarcoma of prostate.

Conclusion: Prostatic leiomyosarcoma poses a unique diagnostic challenge, as clinical presentation alone may not always be suggestive, an unusual clinical presentation as recurrent hematuria must suggest a prostatic leiomyosarcoma when associated with urinary frequency and urinary urgency. Histopathological examination and the FNCLCC grading system are essential for the definitive diagnosis. Multimodality treatment regimens including surgery, radiotherapy and chemotherapy are recommended.

1. Introduction and importance

Prostatic leiomyosarcoma is a rare aggressive tumor, first described in 1853 by Sambert as stated by Riba and *al.* [1]. It is the most common primary sarcoma of the prostate in adults accounting for 38%–52% [2]. The presentation came with non-specific signs and symptoms likewise other forms of prostatic pathology like benign prostatic hyperplasia [3].

The work has been reported in line with the in line with the SCARE 2020 criteria [4].

2. Case presentation

A 64 years old man presented to the emergency with a recurrent macroscopic hematuria, he was a heavy smoker and has reported lower

* Corresponding author. Hôpital Sahloul Route de la Ceinture. 4011, Hammem, SOUSSE, Tunisia.

E-mail addresses: loghmariamhmed@gmail.com (A. Loghmani), benothmouna@gmail.com (M. Ben Othmane), oussama.belkacem@outlook.com (O. Belkacem), Kayri14@hotmail.com (K. Bouassida), hmidawisssem@gmail.com (W. Hmida), mehdi@jaidane.org (M. Jaidane).

<https://doi.org/10.1016/j.amsu.2022.103634>

Received 23 February 2022; Received in revised form 12 April 2022; Accepted 12 April 2022

Available online 16 April 2022

2049-0801/© 2022 The Authors. Published by Elsevier Ltd on behalf of IJS Publishing Group Ltd. This is an open access article under the CC BY-NC-ND license (<http://creativecommons.org/licenses/by-nc-nd/4.0/>).

urinary tract symptoms in particular nocturia and urinary frequency. He didn't have any personal or family medical history, especially no genitourinary cancer.

On the physical examination, the patient was hemodynamically stable and afebrile. However, the digital rectal exam revealed an enlarged homogeneous prostate without any palpable nodule.

Biologically speaking, Prostate specific antigen (PSA) levels were persistently normal (1,7 ng/ml).

Pelvic transabdominal ultrasound showed an enlarged prostate and a thickening of the bladder's left lateral wall.

The CT-scan showed a large and heterogeneous mass arising from the left bladder wall measuring 100 mm, which extends through almost the entire bladder wall (Fig. 1A and B).

All symptoms, signs, and examinations 'results led to a first diagnosis of bladder cancer.

Furthermore, the patient performed cystoscopy, performed by a Urology Professor, showing a normal urethra, a normal prostate gland, and a large solid bladder mass with multiple clots. Subsequently, multiple masses' biopsies were performed. The patient was discharged with no postoperative complications.

The histopathological examination of the biopsy specimen stained with hematoxylin and eosin (HE) showed randomly, a diffuse proliferation of spindle arranged pattern and infiltrating the prostate tissue with low-grade prostatic intraepithelial neoplasia (LGIN) (Fig. 2A). Rare epithelioid and multinucleated cells were observed. The neoplastic cells had eosinophilic cytoplasm and moderate to severe atypical nuclei with frequent mitoses (11 mitoses per 10 high-power fields with atypical mitotic figures) (Fig. 2B). The tumor had large areas of coagulative necrosis. Immunohistochemistry showed that tumor cells were positive for vimentin and alpha-smooth muscle actin (α -SMA) and negative for pan keratin, S-100 protein, desmin and CD34 (Fig. 3). The histological findings confirmed the diagnosis of high-grade prostate leiomyosarcoma according to the French Federation of Cancer Centers Sarcoma Group (FNCLCC) grading. The diagnosis of a primary prostatic leiomyosarcoma was based on the clinical findings and on the histopathological exam.

The patient was prepared for a radical cystoprostatectomy, which would be performed by a Urology Professor, but he died of cardiac arrest before undergoing surgery.

3. Clinical Discussion

Primary prostate sarcomas account for less than 0.1% of primary prostate tumors. Typically, it occurs in patients aged 41–78 years (mean age 61 years) [3].

There are no specific clinical presentations of prostatic sarcoma, patients normally complain of urinary frequency and urinary urgency. Due to the lack of typical clinical symptoms, the tumor is easily overlooked or misdiagnosed as benign prostatic hyperplasia [3]. In this case, the first symptom was a recurrent hematuria in a 64 years-old heavy

smoker, which is a relatively rare obvious symptom according to literature [5]. As showed in this case, recurrent hematuria may delay the diagnosis.

The lack of non-epithelial origin of the tumor, explains the normal PSA levels which may contribute to a delay of diagnosis [3].

In most patients, the diagnosis of prostate leiomyosarcoma is made by trans rectal ultrasound guided (TRUS) biopsy or transurethral resection [3].

The pathological diagnosis of leiomyosarcoma is based on the identification of a cellular proliferation of spindle neoplastic cells resembling smooth muscle cells showing moderate to severe nuclear atypia and increased mitotic activity with rare epithelioid cells. The tumors typically have an infiltrative growth pattern with focal areas of necrosis [3].

Neoplastic cells commonly express vimentin and α -SMA, whereas cytokeratin, desmin and S-100 protein are expressed in rare cases, while CD117, CD34 and CD99 are negative in the majority of cases [2,3].

Cytogenetic analysis of primary leiomyosarcoma of the prostate gland may show clonal chromosomal rearrangements involving chromosomes 2, 3, 9, 11, and 19 [6].

Histological grading of prostate leiomyosarcoma is an important prognostic factor. The most commonly used histological grading system is the FNCLCC grading modified by Trojani et al. [6]. This grading system is based on several histological parameters: tumor differentiation, the presence of necrosis and mitotic index [6].

Concerning the management of prostatic leiomyosarcoma, there are no standard recommendations. Multimodality combination treatments including surgery, pre or postoperative radiotherapy and neo or adjuvant chemotherapy have been used in the management of leiomyosarcoma of prostate. Whether the tumor is operable, the primary treatment is surgery, followed by chemotherapy and/or radiotherapy.

Early diagnosis and complete surgical resection offer patients the best chance for survival [5].

4. Conclusion

Prostatic leiomyosarcoma poses a unique diagnostic challenge, as clinical presentation alone may not always be suggestive, an unusual clinical presentation as recurrent hematuria must suggest a prostatic leiomyosarcoma when associated with urinary frequency and urinary urgency. Histopathological examination and the FNCLCC grading system are essential for the definitive diagnosis. Multimodality treatment regimens including surgery, radiotherapy and chemotherapy are recommended. However the overall prognosis remains poor.

Ethical approval

Given the nature of the article, a case report, no ethical approval was required.

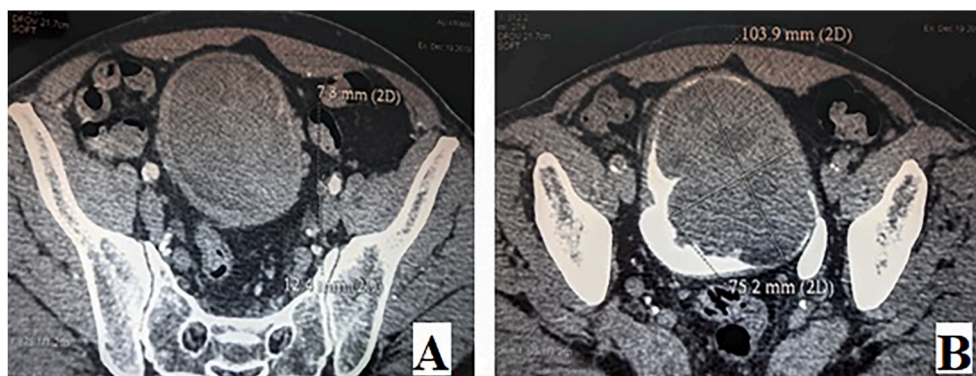


Fig. 1. Contrast Abdominal CT Scan (A) with excretory phase (B) showing a large expansive 100 mm masse on the left bladder wall.

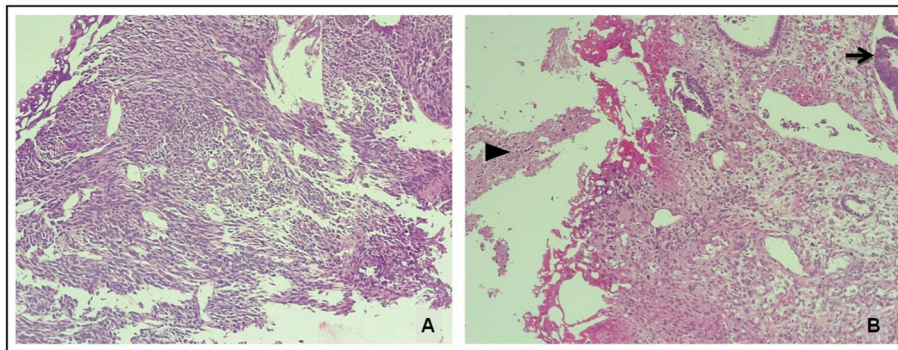


Fig. 2. Photomicrographs of leiomyosarcoma involving the prostate(A)Infiltrative tumor consisting of atypical spindle cells arranged in intersecting fascicular growth pattern(HE, original magnification x100) (B)cellular and atypical neoplasm infiltrating the prostatic parenchyma showing low-grade prostatic intra-epithelialneoplasia(arrow). Note the presence of tumor necrosis(arrowhead) (HE, original magnification x100).

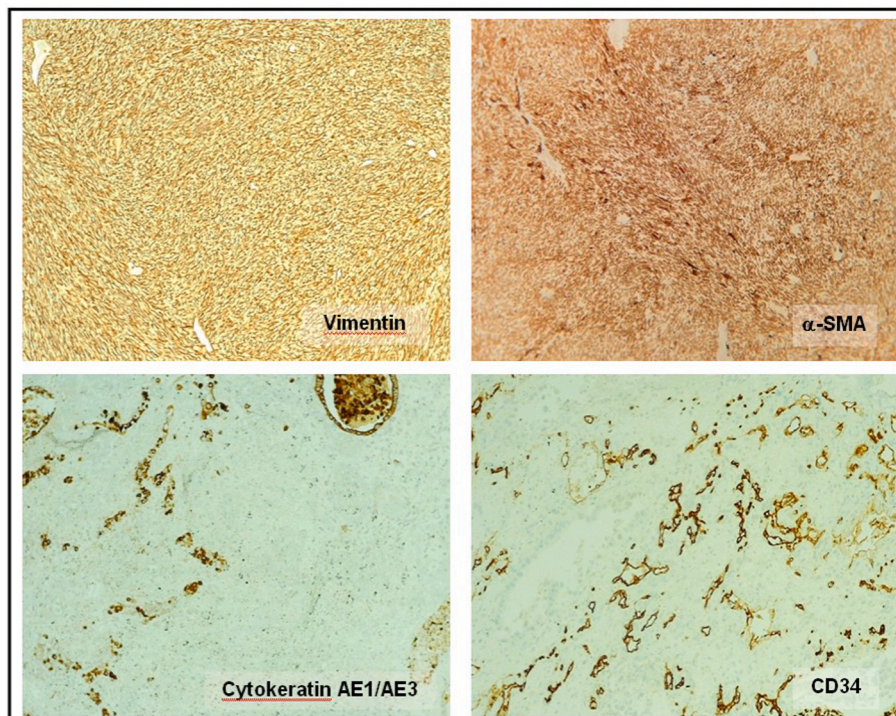


Fig. 3. Immunohistochemical studies showing positivity for vimentin and α -SMA. The neoplastic cells were negative for keratin and CD34.

Sources of funding

This research did not receive any specific grant from funding agencies in the public, commercial, or not-for-profit sectors.

Author contribution

Ahmed Loghmani: Writing - original draft. Mouna Ben Othmen: Project administration writing –review.OussamaBelkacem: writing and editing. KhaireddineBouassida:review and editingWissemHmida: Supervision and reviewing. Mehdi Jaidane: Supervision; reviewing and editing.

Registration of research studies

No registration.

Guarantor

DR. Ahmed Loghmani
loghmariahmed@gmail.com.

Provenance and peer review

Not commissioned, externally peer reviewed.

Consent

Written informed consent was obtained from the patient's close relative for publication of this case report and accompanying images. A copy of the written consent is available for review by the Editor-in-Chief of this journal on request.

Declaration of competing interest

The authors have no conflict of interest to declare.

Appendix A. Supplementary data

Supplementary data to this article can be found online at <https://doi.org/10.1016/j.amsu.2022.103634>.

References

- [1] J.D. Miedler, G.T. MacLennan, Leiomyosarcoma of the prostate, *J. Urol.* 178 (2007) 668, <https://doi.org/10.1016/j.juro.2007.05.036>.
- [2] M. Zazzara, L. Divenuto, M. Scarcia, G. Cardo, F.P. Maselli, G.M. Ludovico, Leiomyosarcoma of prostate: case report and literature review, *Urol Case Rep* 17 (2017) 4–6, <https://doi.org/10.1016/j.eucr.2017.11.024>.
- [3] D.A. Ermann, V.V. Noble, H.M. Fazeel, B. Thomas, P.T. Silberstein, Presentation of a rare malignancy: leiomyosarcoma of the prostate, *Fed. Pract.* 36 (2019) S30–S33.
- [4] R.A. Agha, T. Franchi, C. Sohrabi, G. Mathew, A. Kerwan, A. Thoma, et al., The SCARE 2020 guideline: updating consensus surgical CAse REport (SCARE) guidelines, *Int. J. Surg.* 84 (2020) 226–230, <https://doi.org/10.1016/j.ijsu.2020.10.034>.
- [5] Talapatra, Recurrent episodes of hematuria: a rare presentation of leiomyosarcoma of prostate n.d. <https://www.cancerjournal.net/article.asp?issn=0973-1482;year=2006;volume=2;issue=4;spage=212;epage=214;aulast=Talapatra>. (Accessed 7 March 2022).
- [6] M. Trojani, G. Contesso, J.M. Coindre, J. Rouesse, N.B. Bui, A. De Mascarel, et al., Soft-tissue sarcomas of adults; study of pathological prognostic variables and definition of a histopathological grading system, *Int. J. Cancer* 33 (1984) 37–42, <https://doi.org/10.1002/ijc.2910330108>.