

# Unilateral cilioretinal artery occlusion following cannabis use

Shoaib Ugradar<sup>1</sup>, Alexandra Manta and Declan Flanagan

Ther Adv Ophthalmol

1–4

DOI: 10.1177/  
2515841419838661

© The Author(s), 2019.  
Article reuse guidelines:  
sagepub.com/journals-  
permissions

**Abstract:** There is a growing trend towards the decriminalization of cannabis and this is associated with its increased use over the past decade. Although a variety of adverse effects are attributed to its use, complications involving the eye are rare. We present the case of cilioretinal artery occlusion in a young man with no previous medical history. We discuss the management offered to him and present a review of the literature on this topic. Given the cilioretinal artery occlusion, medical management achieved an excellent result, with his best-corrected visual acuity improving to 6/12. Cilioretinal artery occlusions in healthy young individuals are extremely rare. The only risk factor identified in this patient was the use of cannabis on one occasion prior to his symptoms. There are no other cases in the literature that associate this complication with cannabis use and therefore it serves to raise awareness among the ophthalmic community.

**Keywords:** artery occlusion, cannabis, retina

Received: 6 November 2018; accepted in revised form: 22 February 2019.

## Introduction

Cannabis is the most widely used recreational drug in the United States with an estimated prevalence of up to 19.6%.<sup>1</sup> There is a trend towards legalization of cannabis. Although there are potential therapeutic applications of cannabis, there is a plethora of well-described adverse effects associated with its use.<sup>2–4</sup>

There have been previous reports of cardiovascular, cerebrovascular, and peripheral vascular adverse effects of cannabis use.<sup>5</sup> We present a case of a cilioretinal artery occlusion in a previously healthy young man, who had smoked cannabis only once prior to his admission.

## Case

A 21-year-old man from the Indian Subcontinent experienced right sided, painless, sudden visual loss. He presented on the same day and his best-corrected visual acuity (BCVA) was 6/60 in the right eye and 6/6 in the left. His anterior segment examination was unremarkable and his intraocular pressure was 17 OD and 15 OS. On funduscopy, we found a recent cilioretinal artery occlusion on the right and a normal left fundus.

White retinal oedema was present along the artery course leading into the fovea. No thrombi were seen within the artery lumen. The optic discs were healthy bilaterally and there were no other peripheral retinal or vascular lesions. No signs of inflammation were found in the anterior or posterior chamber.

He had normal eye movements and a neurological examination did not reveal any other signs of stroke. The patient was otherwise well with no other medical history. He was not taking any regular medication and there was no significant family history. He admitted to smoking cannabis three times earlier in the day, before his vision loss. He denied the use of tobacco and informed us that this was his first use of Skunk cannabis. He also denied using any other illicit substance, most pertinently, cocaine.

On general examination, his blood pressure, heart rate, and ECG were within normal limits. His full blood count, kidney, liver, and thyroid function tests were normal. Furthermore, inflammatory markers, glycosylated haemoglobin, plasma homocysteine, lipid panel, coagulation screen, and

Correspondence to:

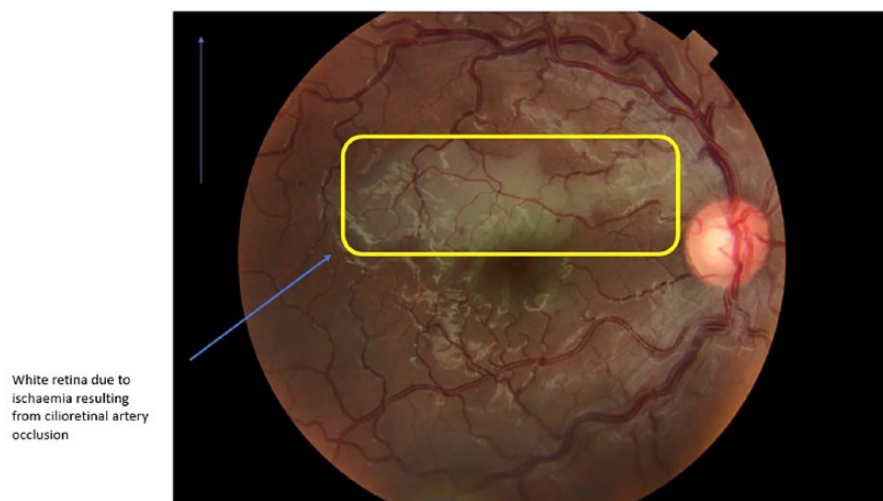
**Shoaib Ugradar**  
Stein Eye Institute, Division  
of Orbital and Ophthalmic  
Plastic Surgery, University  
of California, Los Angeles,  
300 Stein Plaza, 1st Floor,  
Los Angeles, CA 90095,  
USA.

[ugradsahi@aol.com](mailto:ugradsahi@aol.com)

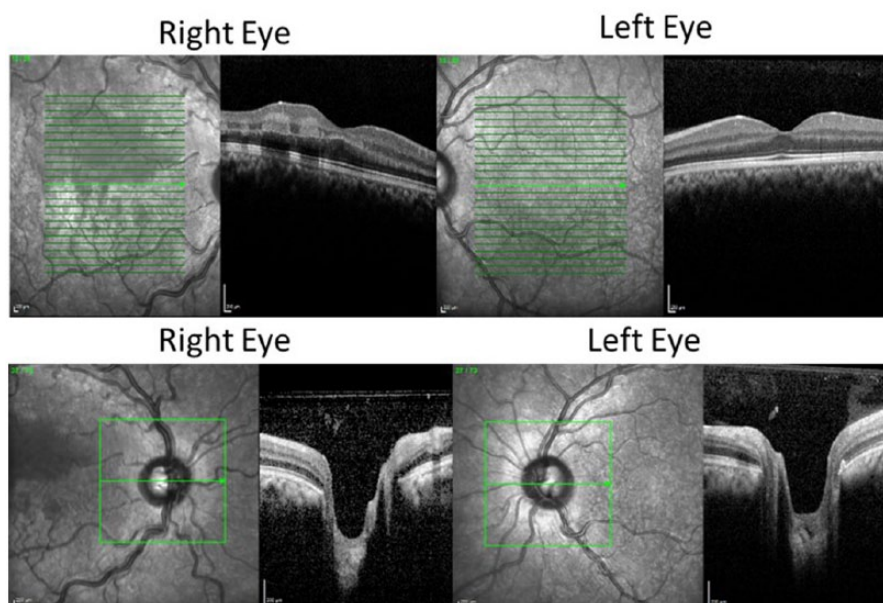
**Shoaib Ugradar**  
Moorfields Eye Hospital,  
London, UK  
Stein Eye Institute, Division  
of Orbital and Ophthalmic  
Plastic Surgery, University  
of California, Los Angeles,  
Los Angeles, CA, USA

**Alexandra Manta**  
**Declan Flanagan**  
Moorfields Eye Hospital,  
London, UK





**Figure 1.** The right fundus shows an acute cilioretinal artery occlusion. The affected ischaemic retina has turned white due to ganglion cell swelling.



**Figure 2.** Bilateral macular and disc HD OCT showing thickening of the right inner retina starting at the disc and continuing along the cilioretinal artery territory indicative on an acute arterial obstructive event.

serum protein electrophoresis were also normal. His blood tests did not reveal any signs of dehydration.

The fundus photograph of the right eye showed neuroretinal thickening along the route of the cilioretinal artery (Figure 1), while the left eye showed normal retinal layers. An optical coherence tomography (OCT) scan confirmed neuroretinal thickening in the distribution of the cilioretinal artery of

the right eye (Figure 2). He was treated with topical beta-blockers (timolol), prostaglandin analogues (latanoprost), apraclonidine, and oral carbonic anhydrase inhibitors (acetazolamide). He was also given aspirin 300 mg PO. We could not offer him hyperbaric oxygen as has previously been recommended by some authors,<sup>2</sup> since we do not have that facility at our institution. His vision improved to 6/24 unaided in the right eye on the next day.

His BCVA improved to 6/12 in the right eye and remained 6/6 in the left over the following 3 months. He was discharged from our service as he had no further complications.

The most common causes of branch or central retinal artery occlusion in individuals younger than 30 are migraines, coagulopathies, trauma, high intraocular pressure, and oral contraceptives. Other causes in younger individuals include hyperhomocysteinaemia, vasculitic processes, cocaine use, and HIV infection.<sup>1</sup> Our patient had none of those present on investigation and his only risk factor appears to be the use of skunk cannabis.

'Skunk' refers to potent cannabis strains that contain high levels of delta-9-tetrahydrocannabinol (THC).<sup>3</sup> This variety is often grown indoors under artificial lighting and has been linked to a greater risk of developing psychosis.<sup>4</sup> A number of published reports have highlighted the cardiovascular, cerebrovascular, and peripheral vascular adverse effects of cannabis.<sup>5</sup> After teasing out potential compounding factors such as parallel tobacco and alcohol use, some have suggested that cannabis may reduce the speed of flow through smaller vessels, in some cases leading to disturbances in the coronary microcirculation.<sup>6,7</sup> Numerous case reports and reviews have highlighted the correlation of cannabis and synthetic cannabinoid consumption to ischaemic strokes.<sup>8,9</sup> Wolff and colleagues recently found that of 334 patients aged below 45 years, who had suffered an ischaemic stroke, 16.8% were regular users of cannabis. These patients did not use any other recreational substances.<sup>10</sup>

The mechanisms underlying the potential link between cannabis use and vascular pathology have not been clearly established. Some studies suggest a role for cerebral vasoconstriction,<sup>11</sup> while others have found that stimulation of the cannabinoid receptor, CB2, leads to vasodilation and subsequent cerebral hypotension.<sup>12</sup> This case report suggests that the ophthalmic vasculature may react in a similar fashion to the cerebral vasculature following cannabis use. Further study is required to elucidate a potential association, in light of the growing trend towards advocating cannabis for medical purposes.

### Acknowledgements

All authors attest that they meet the current ICMJE criteria for authorship.

### Funding

The authors received no financial support for the research, authorship, and/or publication of this article.

### Conflict of interest statement

The authors declared no potential conflicts of interest with respect to the research, authorship, and/or publication of this article.

### Informed consent

A written informed consent was obtained from the patient for publication of medical data and images.

### ORCID iD

Shoaib Ugradar  <https://orcid.org/0000-0003-4479-3033>

### References

1. Azofeifa A, Mattson ME, Schauer G, *et al.* National estimates of marijuana use and related indicators – national survey on drug use and health, United States, 2002–2014. *MMWR Surveill Summ* 2016; 65: 1–28.
2. Soares A, Gomes NL, Mendonça L, *et al.* The efficacy of hyperbaric oxygen therapy in the treatment of central retinal artery occlusion. *BMJ Case Rep* 2017; 2017: bcr-2017-220113.
3. Gulland A. Sixty seconds on . . . skunk. *BMJ* 2017; 356: j1184.
4. Di Forti M, Marconi A, Carra E, *et al.* Proportion of patients in south London with first-episode psychosis attributable to use of high potency cannabis: a case-control study. *Lancet Psychiatry* 2015; 2: 233–238.
5. Thomas G, Kloner RA and Rezkalla S. Adverse cardiovascular, cerebrovascular, and peripheral vascular effects of marijuana inhalation: what cardiologists need to know. *Am J Cardiol* 2014; 113: 187–190.
6. Karabulut A and Cakmak M. ST segment elevation myocardial infarction due to slow coronary flow occurring after cannabis consumption. *Kardiol Pol* 2010; 68: 1266–1268, <http://www.ncbi.nlm.nih.gov/pubmed/21108208> (accessed 23 January 2018).
7. Rezkalla SH, Sharma P and Kloner RA. Coronary no-flow and ventricular tachycardia associated with habitual marijuana use. *Ann Emerg Med* 2003; 42: 365–369.
8. Moeller S, Lücke C, Struffert T, *et al.* Ischemic stroke associated with the use of a synthetic cannabinoid (spice). *Asian J Psychiatr* 2017; 25: 127–130.

Visit SAGE journals online  
[journals.sagepub.com/  
home/oed](http://journals.sagepub.com/home/oed)

 SAGE journals

9. Volpon LC, Sousa CLMM, Moreira SKK, *et al.* Multiple cerebral infarcts in a young patient associated with marijuana use. *J Addict Med* 2017; 11: 405–407.
10. Wolff V, Zinchenko I, Quenardelle V, *et al.* Characteristics and prognosis of ischemic stroke in young cannabis users compared with non-cannabis users. *J Am Coll Cardiol* 2015; 66: 2052–2053.
11. Wolff V, Armspach JP, Beaujeux R, *et al.* High frequency of intracranial arterial stenosis and cannabis use in ischaemic stroke in the young. *Cerebrovasc Dis* 2014; 37: 438–443.
12. Benyó Z, Ruisanchez É, Leszl-Ishiguro M, *et al.* Endocannabinoids in cerebrovascular regulation. *Am J Physiol Heart Circ Physiol* 2016; 310: H785–H801.