

## Update on systemic treatment for newly diagnosed inflammatory breast cancer

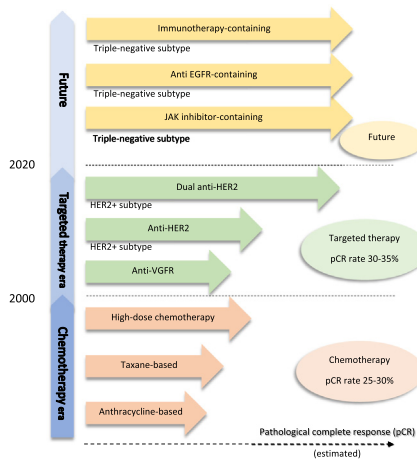


Sudpreeda Chaintitkun<sup>a,b</sup>, Sadia Saleem<sup>a,b</sup>, Bora Lim<sup>a,b</sup>, Vicente Valero<sup>a,b</sup>, Naoto T. Ueno<sup>a,b,\*</sup>

<sup>a</sup> Section of Translational Breast Cancer Research, Department of Breast Medical Oncology, The University of Texas MD Anderson Cancer Center, Houston, Texas 77030, USA

<sup>b</sup> Morgan Welch Inflammatory Breast Cancer Research Program and Clinic, The University of Texas MD Anderson Cancer Center, Houston, Texas 77030, USA

### GRAPHICAL ABSTRACT



### ARTICLE INFO

#### Article history:

Received 16 May 2020

Revised 31 July 2020

Accepted 21 August 2020

Available online 29 August 2020

#### Keywords:

Inflammatory breast cancer

Chemotherapy

Targeted therapy

Immunotherapy

Systemic therapy

### ABSTRACT

**Background:** Inflammatory breast cancer (IBC) is a rare and aggressive disease, accounting for 2–4% of new cases of breast cancer. Owing to its aggressive nature, IBC represent approximately 8–10% of breast cancer deaths. Management of IBC requires a multidisciplinary team for decision-making involving a composite of systemic treatment, surgery, and radiation, or “Trimodality Treatment.” Because of the rarity of the disease, systemic therapy of IBC traditionally has been extrapolated from non-IBC clinical trials. **Aim of Review:** The purpose of this review is to provide an overview of the development of systemic treatment of IBC from the past to the present by focusing on IBC clinical trials, including chemotherapy and targeted therapies.

**Key Scientific Concepts of Review:** We discuss their effects on pathologic complete response (pCR) and survival outcomes, the predictive markers, and the adverse events of these therapies. Further, we summarized the current standard treatment stratified by molecular subtypes based on clinical data. Finally, we discuss the future trend of systemic therapy, including immunotherapy and ongoing IBC clinical trials.

© 2021 The Authors. Published by Elsevier B.V. on behalf of Cairo University. This is an open access article under the CC BY-NC-ND license (<http://creativecommons.org/licenses/by-nc-nd/4.0/>).

Peer review under responsibility of Cairo University.

\* Corresponding author at: Department of Breast Medical Oncology, Unit 1354, The University of Texas MD Anderson Cancer Center, 1515 Holcombe Blvd., Houston, TX 77030, USA.

E-mail address: [nueno@mdanderson.org](mailto:nueno@mdanderson.org) (N.T. Ueno).

<https://doi.org/10.1016/j.jare.2020.08.014>

2090-1232/© 2021 The Authors. Published by Elsevier B.V. on behalf of Cairo University.

This is an open access article under the CC BY-NC-ND license (<http://creativecommons.org/licenses/by-nc-nd/4.0/>).

### Introduction

Over the past two decades, treatment for breast cancer overall has improved, leading to excellent outcomes. Inflammatory breast

cancer (IBC) is a unique, rare entity with more aggressive behavior and worse prognosis than non-IBC or locally advanced breast cancer (LABC) [1]. In the United States, the incidence of IBC is 1.6–3.1 per 100,000 women with a higher incidence among black women and younger women, but owing to its aggressive nature, IBC represents approximately 8–10% of breast cancer deaths. [1,2]. Black women with IBC have worse survival than white women regardless of hormone receptor (HR) status and age [3,4]. Asian women with IBC tend to have longer survival than white women [3]. The survival is significantly shorter in IBC compared with non-IBC [5]. The 5-year overall survival (OS) rate for stage IV IBC is only 25–33% [6]. For de novo stage IV disease, the median OS time is 2.27 years for IBC but 3.40 years for non-IBC [7]. For stage III disease, the median OS is 4.75 years for IBC in contrast to 13.40 years for non-IBC [8]. Therefore, we classify IBC as a high-risk disease because of its high rate of distant metastasis (approximately 30–40%) at first diagnosis, and approximately 80% of stage III IBC has clinical lymph node involvement [9,10].

#### Definition of IBC

According to the American Joint Committee on Cancer (8th edition) [11], diagnostic criteria for IBC (T4d) are based on clinical diagnosis by a rapid onset of diffuse erythema and edema (or peau d'orange) involving approximately at least one-third of breast skin, with or without an underlying palpable mass. The skin changes may be due to lymphedema caused by tumor emboli within dermal lymphatics, which may be present or absent in biopsy specimens. Although tumor emboli are a hallmark of IBC, only around 75% of diagnosed IBC cases show tumor emboli on pathologic analysis [12]. Interestingly, we classify the presence of tumor emboli in dermal lymphatics without any skin changes as non-IBC breast cancer [11]. The onset of symptoms in IBC should be rapid, within no more than 6 months [11,13].

#### Subtypes and characteristics of IBC

Like non-IBC, IBC can be categorized into four subtypes; hormone receptor-positive (HR+)/human epidermal growth factor receptor 2-negative (HER2-), HR+/HER2-positive (HER2+), HR-negative (HR-)/HER2+, and HR-/HER2- (or triple-negative receptor status) [6,14,15]. Bone is the most common metastasis site in all the subtypes; liver metastasis has frequently occurred in the HER2+ subtype; and lung metastasis has frequently occurred in the triple-negative subtype. IBC has lung/pleural effusion metastasis around 21–29% [16]. As in non-IBC, triple-negative IBC has the worst survival outcomes, with a 5-year survival rate of less than 30% [6,17]. Approximately 15% of IBC develop brain metastasis [18]. Data from the Surveillance, Epidemiology, and End Results (SEERs) database and our institute also showed the same results that triple-negative IBC has a higher rate of brain metastasis than non-IBC [18,19]. Our institute also reported that survival after brain metastasis in IBC was shortest in the triple-negative subtype, with a median OS of 3.8 months [18]. In contrast, after brain metastasis, HER2+ subtype IBC showed the longest median OS of 16.6 months, and the improvement of survival in HER2+ subtype relates to the anti-HER2 therapy era [18].

#### Pathological complete response

Pathologic complete response (pCR) is a well-known prognostic marker of neoadjuvant therapy for breast cancer, including IBC. Its definition is the absence of residual invasive cancer in the complete resected breast specimen and all sampled regional lymph nodes following completion of neoadjuvant systemic therapy (ypT0/Tis ypN0 in American Joint Committee on Cancer staging

system [11]). pCR predicts long-term survival outcomes, including event-free survival and OS [15,20–22]. Similar to non-IBC patients, IBC patients who experience pCR status have better survival than non-pCR, and those with HR-/HER2+ IBC have the highest pCR rate among all the subtypes. However, triple-negative IBC remains to have a poor outcome despite achieving pCR [15,23].

#### Treatment of IBC

Historically, local treatment of IBC by surgery or radiation alone has shown poor results, with a 5-year OS rate of less than 5% [24]. Systemic neoadjuvant regimens are a critical part of IBC treatment. Currently, the management of IBC requires a multidisciplinary team comprising a medical oncologist, surgeon, pathologist, diagnostic radiologist, and radiation oncologist. The principal goal of this team is to improve the survival of IBC by determining the optimal combination of systemic treatment, surgery, and radiation, or “trimodal treatment” [25].

However, at present, even though all standard guidelines [26,27] have defined IBC separately from non-IBC disease, the systemic treatment used in the clinic is still the same as that used for non-IBC. Current IBC systemic treatment has been extrapolated from non-IBC clinical trials and stratified by breast cancer molecular subtypes the same way as in non-IBC. In recent years, clinical research, including clinical trials, has investigated the potential role of several new systemic regimens in patients with IBC, but quite limited the number of patients. In this review article, we summarize the clinical data, including clinical trial results, regarding systemic treatment specifically for IBC, and we discuss the efficacy and toxicity of these treatments.

#### Developments of systemic treatment for IBC

Various systemic treatments have been used for breast cancer worldwide. The optimal selection of systemic treatment strategy depends on both tumor and patient characteristics. We discuss the systemic therapy of IBC from the past to the present (chemotherapy and targeted therapy eras). Further, we summarize the current standard treatment in real practice stratified by subtypes based on clinical trials. Finally, we provide the future direction of systemic therapy (immunotherapy era).

#### Chemotherapy

A large retrospective study from MD Anderson reported that 178 IBC patients treated with upfront anthracycline-based chemotherapy, combined with radiation therapy with or without mastectomy, had an objective response rate of 74%, a median OS of 37 months, and a 10-year OS rate of 33% [22]. These results are consistent with those of other anthracycline-based studies in IBC, which have reported a 10-year OS rate of 27–35% [28–30]. As in non-IBC, paclitaxel is well known as an active agent against breast cancer. Cristofanilli et al. [31] showed that adding taxane to a fluorouracil, doxorubicin, and cyclophosphamide (FAC)-based regimen in 240 IBC patients improved the pCR rate from 10% to 25% ( $p = 0.012$ ). Paclitaxel addition regimen also had a numerically longer median OS in the study than did the FAC-based regimen alone (52 vs. 41 months,  $p = 0.11$ ) and a statistically significantly longer OS among estrogen receptor (ER)-negative (ER-) patients than other subtypes [31]. Furthermore, paclitaxel showed benefit in anthracycline-refractory IBC, in which 44% of IBC non-responders who treated with FAC regimen four cycles became resectable after treatment with paclitaxel [32].

Many studies have demonstrated that increased dose intensity improves the efficacy of chemotherapy in breast cancer [33]. For

IBC, studies of chemotherapy dose intensity were undertaken based on data from prospective studies of non-IBC and reported results specific to an IBC cohort. Ditsch et al. [34] reported 101 IBC patients treated preoperatively with either epirubicin followed by paclitaxel every 2 weeks (dose-dense sequential group) with granulocyte colony-stimulating factor (G-CSF) support or standard combination chemotherapy every 3 weeks. After surgery, all patients received adjuvant chemotherapy (cyclophosphamide, methotrexate, and 5-fluorouracil), radiation therapy, and anti-hormonal therapy if clinically indicated. The dose-dense sequential group and the standard group did not significantly differ in pCR rate (12% vs. 10%, respectively; odds ratio = 1.27;  $p = 0.33$ ) or in OS (hazard ratio = 1.4, 95% CI 0.71–2.75,  $p = 0.327$ ). Similarly, Ellis et al. [35] enrolled patients with high-risk breast cancer in a phase 3 randomized clinical trial, including 115 patients with IBC and 249 patients with LABC. All patients were randomized into two groups, treated with a neoadjuvant standard-dose (21-day) doxorubicin and cyclophosphamide (AC) regimen or a weekly AC regimen with G-CSF support (dose-dense), and both groups were subsequently treated with weekly paclitaxel. The pCR rate in IBC patients was numerically higher in the dose-dense group compared with the standard, 21-day group, but the difference was not statistically significant (27% vs. 13%,  $p = 0.60$ ).

The efficacy of neoadjuvant chemotherapy (NAC) depends on the breast cancer subtypes, ER- IBC has a higher pCR rate than ER-positive IBC, as same as in non-IBC [36]. Response evaluation by imaging in the middle of NAC also predicts final pathologic response in IBC; breast MRI, in particular, showed a better correlation than did mammography or sonography [37]. For predictive gene expression signatures, hyperactivation of IFN- $\alpha$  and hypoactivation of EGFR, p53, and TGF- $\beta$  were associated with pCR in IBC after treatment with NAC [38]. This study also found that the predictive gene signatures were significantly enriched for immunity-related genes involved in CD8-positive T-cell lymphocyte activation processes, suggesting that adaptive immunity determined response to chemotherapy in IBC [38].

Today, there are no data from large randomized controlled trials for IBC; therefore, anthracycline- and taxane-based chemotherapy are still recommended as the backbone of primary chemotherapy regimens by international expert consensus. However, the chemotherapy schedule and dose density can differ between centers where have their own IBC specialized clinics [39].

#### *High-dose chemotherapy with autologous hematopoietic stem cell transplant*

Before 2000, high-dose chemotherapy (HDCT) followed by autologous hematopoietic stem cell transplantation (AHST) was extensively investigated for IBC with the same rationale as that of studying dose-intensity relationships. In 1997, the International Blood and Marrow Transplant Registry reported a 3-year OS rate of 52% in 253 IBC patients treated with HDCT with AHST [40]. A larger and updated registry of HDCT with AHST, comprising 527 IBC patients and 2,860 non-IBC patients from the Center for International Blood and Marrow Transplant Research, reported a 10-year OS rate of approximately 30% with no difference between IBC and non-IBC [41]. However, among non-metastatic patients with no evidence of disease at transplant, the 10-year OS was worse for IBC patients than for non-IBC patients (37% vs. 45%, respectively;  $p = 0.03$ ). Multivariate analysis in this study showed worse outcomes for stage III IBC than for stage III non-IBC. Multiple single-arm phase 2 trials of AHST specifically for IBC patients have reported varying pCR rates of 17–39%, 3-year OS rates of 68–72%, and favorable prognostic factors including HR positivity, the involvement of less than four axillary lymph nodes, and receipt of adjuvant radiation [42–44].

Owing to the diversity of these pilot studies [42–44] of HDCT with AHST for IBC, the French PEGASE experience perform larger, randomized comparative studies to demonstrate the survival benefit of HDCT with AHST for non-metastatic IBC: two phase 2 clinical trials (PEGASE 02 and PEGASE 05) and one phase 3 clinical trial (PEGASE 07). PEGASE 02 [45] treated 100 IBC patients with four cycles of high-dose FAC plus G-CSF and with the administration of AHST after cycles 3 and 4. The pCR rate was 32%, and the 3-year OS rate was 70%. Febrile neutropenia was the most frequent adverse event, resulting in 85% of rehospitalizations. One case had treatment-related death by septic shock. The phase 2 trial PEGASE 05 sought to determine the efficacy of adding dose-dense docetaxel to the high-dose AC regimen with AHST. After 54 patients were enrolled, the study was prematurely stopped owing to toxicity (eight cases had a severe infection, and two cases died of febrile neutropenia). In the 48 patients analyzed, the pCR rate was 30%, similar to that of PEGASE 02. The investigators concluded that adding dose-dense docetaxel did not improve the pCR rate and was too toxic [46,47].

In the randomized clinical trial PEGASE 07 [48], 174 IBC patients were treated with HDCT, comprising epirubicin (150 mg/m<sup>2</sup>) and cyclophosphamide (4 g/m<sup>2</sup>), with G-CSF support for four cycles followed by AHST. After surgery and radiation, patients were randomized to either observation or adjuvant therapy with four cycles of docetaxel (85 mg/m<sup>2</sup>) and 5-fluorouracil (3000 mg/m<sup>2</sup>), with continuous infusion for 4 days. There were no differences in 5-year disease-free survival (DFS) (55.0% vs. 55.5%, respectively; hazard ratio = 0.947, 95% CI 0.61–1.48,  $p = 0.810$ ) or in 5-year OS rate (70.2% vs. 70.0%, respectively; hazard ratio = 0.938, 95% CI 0.55–1.60,  $p = 0.814$ ). The pCR of both arms was 20%.

Although many publications have shown the efficacy of HDCT with AHST in IBC, the standard of care did not change because randomized trials of this approach showed a lack of positive benefits, and the presence of toxic risks, including fatal infection, is a major problem. Also, the chemotherapy agents used in high-dose trials are currently not commonly used to treat IBC in the clinic. Furthermore, predictive biomarkers to guide the use of HDCT with AHST in IBC have not been discovered. Finally, HDCT was associated with worse quality of life [49]. Therefore, there is no currently recommended role for this strategy for newly diagnosed IBC.

#### *Targeted therapy*

At present, there are limited targeted therapy studies specific to IBC. Because IBC classified as a high-risk disease, systemic targeted therapy of IBC has mainly based on extrapolation of data available from the high-risk group of non-IBC studies.

##### *a Trastuzumab*

IBC has higher rates of HER2 overexpression than does non-IBC, with an estimated prevalence of 25–35% in IBC [50–53], and trastuzumab has been approved for HER2+ disease in both early and metastatic stages. Many randomized controlled trials have confirmed the survival benefits of NAC combined with trastuzumab for patients with LABC, including IBC [54,55]. However, the number of IBC patients was limited in those trials. The NOAH study [54], a randomized phase 3 clinical trial, enrolled 235 patients with HER2 + LABC (including 47 IBC patients) and evaluated the efficacy of neoadjuvant trastuzumab plus chemotherapy compared with NAC alone. The NAC regimen was doxorubicin and paclitaxel for three cycles, followed by paclitaxel for four cycles, and then cyclophosphamide, methotrexate, and fluorouracil for three cycles. Subgroup analysis in IBC showed that the addition of trastuzumab increased the 5-year event-free survival rate (64% vs. 24%, hazard ratio = 0.34, 95% CI 0.15–0.80) and 5-year OS rate (74% vs. 44%, haz-

ard ratio = 0.38, 95% CI 0.15–0.95) without any serious cardiac events. The efficacy of trastuzumab was confirmed in single-arm studies specifically for IBC [56,57], which reported a high pCR rate of 54–66% for patients with HER2+ IBC treated with an anthracycline-containing regimen plus trastuzumab without relevant cardiac toxicity. The NOAH study also reported that the HER2+/HR– subtype was a predictive marker for the efficacy of trastuzumab addition, with a hazard ratio of 0.51 (95% CI 0.29–0.91) for OS and a hazard ratio of 0.58 (95% CI 0.35–0.94) for event-free survival. Now, trastuzumab is a part of the anti-HER2 backbone for the HER2+ IBC.

#### b Pertuzumab

Pertuzumab is a humanized anti-HER2 monoclonal antibody that binds the HER2 receptor at a different epitope from that bound by trastuzumab, instead of binding to the subdomain II of the HER2 extracellular domain and preventing HER2 from dimerization with other ligands HER receptors, most notably HER3 receptor [58]. Like trastuzumab binding, pertuzumab binding induces antibody-dependent cell-mediated cytotoxicity [59]. Because of these similar but distinct mechanisms of binding to HER2 epitopes, the concept of the synergistic combination of pertuzumab with trastuzumab was tested in clinical trials [55,58,60].

In the NeoSphere trial [55,61], a phase 2 randomized neoadjuvant trial enrolled 417 patients with breast cancer, including 29 IBC patients. All patients were randomized into four neoadjuvant arms: docetaxel plus trastuzumab, docetaxel plus trastuzumab, and pertuzumab (THP), trastuzumab and pertuzumab without docetaxel, and docetaxel and pertuzumab. After surgery, all patients were treated with adjuvant 5-fluorouracil, epirubicin, and cyclophosphamide (FEC) and adjuvant trastuzumab for 1 year. NeoSphere reported promising pCR rates: 45.8%, the highest, in the THP arm; 29.0% for docetaxel plus trastuzumab; 16.8% for trastuzumab and pertuzumab without docetaxel; and 24.0% for pertuzumab plus docetaxel. Rates of cardiac adverse events were similar between all arms (4–5%). At the 5-year follow-up, NeoSphere [61] reported progression-free survival rates of 81% for docetaxel plus trastuzumab, 86% for THP, 73% for trastuzumab and pertuzumab without docetaxel, and 73% for pertuzumab plus docetaxel.

TRYPHAENA [62], a randomized phase 2 study, evaluated the safety and tolerability of dual anti-HER2 antibodies combined with NAC in 225 patients, including 13 IBC patients. All patients were randomized into three groups: FEC regimen plus pertuzumab and trastuzumab followed by THP; FEC followed by THP; and docetaxel and carboplatin plus pertuzumab and trastuzumab (TCHP). The incidence of left ventricular ejection fraction (LVEF) declines was low, around 4–5% in each group. Interestingly, this study reported pCR rates of 50.7%, 45.3%, and 51.9%, respectively. At the 3-year follow-up for TRYPHAENA, DFS and OS did not significantly differ between groups [63].

Overmoyer et al. reported the efficacy of neoadjuvant weekly paclitaxel combined with pertuzumab and trastuzumab, followed by surgery in only IBC patients. All patients received post-mastectomy radiation, maintenance pertuzumab and trastuzumab for 36 weeks, and an adjuvant AC regimen for the non-pCR case. This study was closed owing to slow accrual, with 20 IBC patients. The pCR rate was 56%, and toxicity was minimal [64].

Now, a regimen containing pertuzumab plus trastuzumab is a standard neoadjuvant treatment for HER2+ IBC. In contrast to non-IBC, IBC is classified as a high-risk disease, and escalation strategies are preferred over de-escalation strategies. Therefore, short-duration or lower amounts of anti-HER2 therapy should be avoided.

#### c Lapatinib

Lapatinib is a small-molecule tyrosine kinase inhibitor that blocks intracellular HER2 and EGFR (epidermal growth factor receptor) signaling pathways [65]. The GeparQuinto study [66], a randomized neoadjuvant phase 3 trial, enrolled 620 HER2+ breast cancer patients (including 83 IBC patients). They were then treated with four cycles of epirubicin and cyclophosphamide followed by four cycles of docetaxel combined throughout all cycles with either trastuzumab or lapatinib. The pCR rate was higher in the trastuzumab arm than in the lapatinib arm (30.3% vs. 22.7%, odds ratio = 0.68, 95% CI 0.47–0.97,  $p = 0.04$ ). However, the trastuzumab and lapatinib arms did not differ in 3-year OS rate (91.7% vs. 93.6%, respectively;  $p = 0.297$ ) [67]. Interestingly, the combination of NAC with lapatinib had a lower pCR rate than expected in HER2+ patients. Similarly, a phase 2 IBC trial reported a low pCR rate of 17.6% in 32 patients with HER2+ IBC treated with neoadjuvant paclitaxel and lapatinib [68]. Concerning adverse events seen with lapatinib included diarrhea and rash, found around 50% of cases and sometimes leading to dose reduction or discontinuation of treatment [66,68]. One IBC study of NAC plus lapatinib was prematurely stopped owing to severe toxicity (>15% of patients) [69]. Combination chemotherapy plus lapatinib is currently not recommended to treat newly diagnosed IBC due to a low response rate and concerning toxicity.

Like trastuzumab, the HER2+ subtype is a strong predictive marker for lapatinib efficacy [68]. One study also reported that co-expression of phosphorylated (p) HER2 and pHER3 in IBC patients was associated with response to lapatinib [70]. Furthermore, a proof of concept for the synergistic combination of lapatinib and trastuzumab has been demonstrated in the clinical trial. The NeoALTO trial [71] reported promising results of dual antibody treatment with trastuzumab plus lapatinib combined with paclitaxel in HER2+ early breast cancer; the pCR rate for dual anti-HER2 combination was 51.3%, higher than that of paclitaxel combined with single-antibody treatment with trastuzumab (29.5%) or lapatinib (24.7%). However, most combination trastuzumab and lapatinib studies have excluded IBC patients or did not report their inclusion.

#### d Trastuzumab emtansine

Trastuzumab emtansine (T-DM1) is an antibody-drug conjugate that has efficacy against breast cancer and acceptable toxicity. The conjugate comprises trastuzumab linked with the cytotoxic antimicrotubule agent DM1 (emtansine) and acts by directly binding on HER2 receptors of tumor cells. T-DM1 gains intracellular entry via endocytosis, and DM1 is released by lysosomal degradation [72]. Notably, T-DM1 is cytotoxic by itself, without coupling with chemotherapy. The KRISTINE trial [73], a randomized phase 3 trial, evaluated neoadjuvant treatment with a T-DM1 plus pertuzumab regimen or a TCHP regimen in 444 patients with HER2+ breast cancer, including IBC. Unfortunately, the pCR rate was significantly higher for the TCHP regimen than for T-DM1 plus pertuzumab (56% vs. 44%, respectively;  $p = 0.016$ ). However, the TCHP regimen had a higher rate of serious adverse events (31% vs. 29%), including febrile neutropenia, diarrhea, and vomiting. Therefore, T-DM1 plus pertuzumab in the neoadjuvant setting is not superior to trastuzumab plus pertuzumab-containing regimen in terms of response; however, T-DM1 is more favorable in terms of toxicity. Therefore, the T-DM1 plus pertuzumab regimen is another option for patients in whom the TCHP regimen is not well tolerated.

Recently, the KATERINE trial [74] evaluated adjuvant therapy in patients with HER2+ breast cancer who did not experience a pCR after treatment with a taxane-based regimen plus trastuzumab. A total of 1,486 patients, including 22 IBC patients, were randomized



to treatment with either adjuvant T-DM1 or trastuzumab for 14 cycles. The primary endpoint, invasive DFS, defined as freedom from invasive breast cancer recurrence or death, was 88.3% in the T-DM1 group and 77% in the trastuzumab group with a hazard ratio of 0.50 (95%CI 0.39–0.64,  $p < 0.001$ ). However, adjuvant anti-HER2 therapy should be considered, as shown by a previously published study. An APHINITY trial [75] showed greater benefit from adjuvant pertuzumab plus trastuzumab than adjuvant trastuzumab alone in lymph node-positive disease or high-risk node-negative disease: 3-year invasive DFS rates were 94.1% and 93.2%, respectively, with a hazard ratio of 0.81 (95% CI 0.66–1.00,  $P = 0.045$ ). In summary, adjuvant pertuzumab plus trastuzumab are recommended in HER2+ IBC who achieve a pCR, and adjuvant T-DM1 is recommended in IBC cases with a non-pCR.

#### e Neratinib

Neratinib is a tyrosine kinase inhibitor that irreversibly binds to EGFR, HER2, and HER4. The ExteNET study showed benefit from adjuvant neratinib for 1 year after completion of adjuvant trastuzumab, with an invasive DFS rate of 90.2% compared with 87.7% from placebo (hazard ratio = 0.73, 95% CI 0.57–0.92,  $p = 0.008$ ) [76]. After amendments, the eligibility of the ExteNET study was restricted to patients with high-risk recurrent disease (e.g., node-positive disease). Therefore, the role of adjuvant neratinib should be considered with high-risk recurrent disease like IBC. However, the toxicity risk of neratinib should also be considered, particularly diarrhea, which is the most common adverse event (grade 3, 40%; grade 4, 0.1%).

#### f Bevacizumab

Bevacizumab is a monoclonal antibody against circulating vascular endothelial growth factor (VEGF), a known angiogenesis activator in tumors. In preclinical data, the combination of bevacizumab with taxane-based chemotherapy inhibited tumor growth and metastasis of IBC cells (SUM149) [77]. In clinical data, three studies evaluated the addition of bevacizumab to neoadjuvant therapy, specifically in IBC patients.

The BEVERLY-1 and BEVERLY-2 studies, with similar study designs, evaluated the pCR rate in non-metastatic IBC patients with both HER2- (BEVERLY-1) and HER2+ (BEVERLY-2) disease. BEVERLY-1 [78], a single-arm phase 2 study, treated HER2- IBC patients ( $n = 100$ ) with an FEC regimen plus bevacizumab for four cycles followed by docetaxel plus bevacizumab for four cycles. After surgery, patients received adjuvant radiation, adjuvant bevacizumab for ten cycles, and adjuvant hormonal therapy as clinically indicated. Results were disappointing, with a low pCR rate of 19%, similar to the pCR rates in the studies of chemotherapy without the targeted therapy mentioned above. Around one-third of all patients had serious adverse events, including febrile neutropenia, mucositis, and peritonitis. Rates of toxicity related to bevacizumab were 20–40% (e.g., hypertension, proteinuria, and wound-healing complications). The 3-year DFS was 57%, and the 3-year OS was 75%.

The BEVERLY-2 study investigated neoadjuvant therapy plus bevacizumab in non-metastatic HER2+ IBC ( $n = 52$ ). All patients received neoadjuvant therapy with FEC plus bevacizumab for four cycles, followed by docetaxel plus trastuzumab combined with bevacizumab for four cycles. As in BEVERLY-1, after surgery, all patients received adjuvant radiation, adjuvant trastuzumab plus bevacizumab continuing up to about 1 year, and adjuvant hormonal therapy as clinically indicated. In contrast to BEVERLY-1, BEVERLY-2 showed a promising pCR rate of 63%. The 3-year DFS rate was 68%, and the 3-year OS was 90% [79]. Again, around one-third of patients had serious adverse events, including febrile

neutropenia, anal abscess, and LVEF decrease. BEVERLY-2 also reported that among patients with no detection of circulating tumor cells at baseline ( $<1$  cell/7.5 ml) and achieved a pCR were a good prognosis with a high 3-year DFS rate of 98% [79].

The third study, by Palazzo et al., assessed the pCR rate in 34 IBC patients treated with paclitaxel, carboplatin, and oral cyclophosphamide combined with bevacizumab for 24 weeks before surgery. If tumors were HER2+ or HR+, trastuzumab and endocrine therapy were added as indicated. The pCR rate was 29% overall, 57% in HER2+ cases, 20% in triple-negative cases, and 0% in the HR+ subtype. The treatment was well tolerated; only one patient developed a serious adverse event of grade 4 neutropenia [80].

Concerning predictive biomarkers, a pooled analysis of BEVERLY-1 and BEVERLY-2 [81] again reported that patients with no detection of circulating tumor cells at baseline ( $<1$  cell/7.5 ml) and a pCR showed good prognosis, with a high 3-year OS rate of 94%. The AVEREL study [82], a randomized phase 3 trial, aimed to evaluate first-line therapy with docetaxel and trastuzumab with or without bevacizumab in HER2+ metastatic breast cancer. The study reported that VEGF-A showed potential as a biomarker for bevacizumab efficacy; a high plasma concentration of VEGF-A was associated with greater benefit from therapy than a low concentration. This result was consistent with the BEATRICE study [83], which also found that high plasma VEGF-A concentration was associated with greater benefit from adding bevacizumab to neoadjuvant therapy. However, the absolute differences in the benefits associated with VEGF-A were not statistically significant. Bevacizumab was approved by the U.S. Food and Drug Administration for metastatic breast cancer; however, the approval was withdrawn after safety and efficacy concerns arose. At present, the role of bevacizumab is used in certain circumstances with paclitaxel for metastatic breast cancer [26].

#### g Panitumumab

Around one-third of IBC cases typically express EGFR, and higher EGFR expression correlates with worse prognosis [84,85]. The humanized anti-EGFR antibody, panitumumab, besides being approved for the treatment of colorectal cancer, also has clinical efficacy in breast cancer. In a single-arm phase 2 study, panitumumab was combined with preoperative carboplatin and nab-paclitaxel for four cycles, followed by an FEC regimen for four cycles in 47 patients with newly diagnosed HER2- IBC regardless EGFR expression status, leading to a pCR rate of 28% [86]. The triple-negative IBC subtype had the highest pCR at 42%. Among the expressed proteins of baseline tissues, only pEGFR expression was associated with pCR ( $p = 0.05$ ), but EGFR was not ( $p = 0.14$ ). Hematologic toxicity was moderate, 30% of patients had grade 4 neutropenia, and 15% had grade 3 or 4 thrombocytopenia. The most frequent non-hematologic toxicity related to panitumumab affected the skin; six patients (15%) had grade 3 skin rash. To our knowledge, this targeted therapy study is the first to show a high pCR for the poor-prognosis disease triple-negative IBC [86]. Now, an ongoing clinical trial is evaluating combination NAC plus panitumumab for IBC (NCT01036087) in Table 1.

#### h Pazopanib

Pazopanib is a small-molecule multi-tyrosine kinase inhibitor of VEGFR1-3, FGFR1 and -3, PDGFR $\alpha$  and - $\beta$ , and c-Kit. A randomized phase 2 study, VEG20007 [87], evaluated first-line lapatinib plus pazopanib therapy or lapatinib monotherapy in patients with HER2+ locally advanced and metastatic breast cancer ( $n = 190$ ), including IBC. HER2+ status was defined as 3+ by immunohistochemistry or HER2 gene amplification by fluorescence in situ hybridization. The primary endpoint was the rate of progressive

**Table 1**  
Ongoing clinical trials for IBC.

Identifier (Status)	Population	Phase	Regimen	Endpoint
NCT03515798 (Recruiting)	HER2-, IBC	Randomized phase 2	Arm 1: (FEC + weekly paclitaxel) + pembrolizumab Arm 2: FEC + weekly paclitaxel	pCR rate
NCT02971748 (Recruiting)	HR+, IBC	Single-arm phase 2	Non-pCR case treated with adjuvant pembrolizumab + hormone therapy	2-year DFS
NCT02876302 (Recruiting)	Triple-negative IBC	Phase 2	Weekly paclitaxel + ruxolitinib then AC regimen	Change of JAK expression
NCT01036087 (Active, not recruiting)	Triple-negative IBC	Randomized phase 2	Arm 1: panitumumab + carboplatin + nab-paclitaxel then FEC Arm 2: carboplatin + nab-paclitaxel then FEC	pCR rate
NCT02623972 (Recruiting)	HER2-, IBC	Phase 2	AC then eribulin	pCR rate
NCT03598257 (Recruiting)	Non-metastatic IBC	Phase 2	Concurrent radiation + olaparib vs radiation alone	Invasive DFS
NCT03101748 (Recruiting)	LABC or metastatic IBC	Phase 1b/2	Neratinib + paclitaxel + pertuzumab + trastuzumab	pCR rate
NCT03202316 (Recruiting)	Recurrent or metastatic IBC	Single-arm phase 2	Atezolizumab + cobimetinib + eribulin	Response rate
NCT02411656 (Recruiting)	Stage IV, IBC or triple-negative	Single-arm phase 2	Maintenance pembrolizumab in non-PD cases after chemotherapy	Disease control rate
NCT03101748 (Recruiting)	HER2+ or -, IBC	Single-arm phase 2	Cohort 1: paclitaxel + pertuzumab + trastuzumab + neratinib then AC regimen Cohort 2: paclitaxel + neratinib then AC regimen	pCR rate
NCT03742986 (Recruiting)	Newly diagnosed IBC	Non-randomized phase 2	Cohort HER2-: weekly paclitaxel + nivolumab then AC Cohort HER2+: same regimen plus pertuzumab + trastuzumab	pCR rate
NCT02658812 (Active, not recruiting)	Local recurrence IBC or inoperable non-IBC	Single-arm phase 2	Talimogene laherparepvec	Response rate

Abbreviations: IBC, inflammatory breast cancer; HER2, human epidermal growth factor receptor 2; pCR, pathologic complete response; FEC, 5-fluorouracil, epirubicin and cyclophosphamide; AC, doxorubicin and cyclophosphamide; LABC, locally advanced breast cancer; DFS, disease-free survival; PD, progressive disease (accessed clinical-trial.gov on April 23, 2020).

disease after 12 weeks. Progression rates did not differ between the combination therapy and lapatinib monotherapy (36.2% vs. 38.9%,  $p = 0.37$ ). However, the most common grade 3–4 adverse events were twice as frequent in the combination arm compared with the monotherapy, e.g., diarrhea (9% vs. 5%), hypertension (5% vs. 0%), and fatigue (4% vs. 0%) [87]. Another study [88] specifically for metastatic HER2+ IBC patients included 76 IBC patients treated with lapatinib (1500 mg) plus pazopanib (800 mg); this cohort was prematurely closed because of a high incidence of grade 3–4 toxicity. In a second cohort, 88 IBC patients were randomized to treatment with pazopanib (400 mg) plus lapatinib (1000 mg) or monotherapy with either lapatinib (1500 mg) or pazopanib (800 mg). The overall response rate was numerically highest in the combination arm, at 58%; response rates for monotherapy lapatinib and pazopanib were 47% and 31%, respectively. Median progression-free survival was the same in the combination and lapatinib monotherapy arms (16 weeks) and was 11.4 weeks for pazopanib monotherapy. Again, combination therapy had a higher rate of serious adverse events than did lapatinib monotherapy (24% vs. 11%, respectively). There are no further clinical trials of pazopanib for breast cancer to date.

#### i Other targeted therapies

Afatinib is an irreversible ErbB family blocker that has shown preclinical activity in trastuzumab-resistant cell lines [89]. A phase 2 clinical trial evaluated afatinib with or without vinorelbine in metastatic HER2+ IBC. However, the trial was stopped early after another study showed that afatinib was associated with shorter survival, 26 IBC patients who remained showed a clinical benefit rate of 35% from afatinib monotherapy [90]. An oral multi-tyrosine kinase inhibitor, sunitinib, was evaluated in a phase 2 trial in combination with NAC in patients with HER2- LABC or IBC ( $n = 70$ ). The neoadjuvant treatment was sunitinib combined with

weekly paclitaxel followed by AC regimens with G-CSF. Disappointingly, overall results showed a low pCR rate of 24% [91].

Over two decades, there have been many changes in systemic treatment leading to improved survival outcomes for breast cancer, specifically IBC (Fig. 1). We had chemotherapy as a tool against breast cancer in the past, and today we have a combination of targeted therapy and chemotherapy, which has a higher pCR rate. Not all strategies or agents are effective in IBC (e.g., the HDCT strategy has a higher pCR rate than conventional chemotherapy but has too great a toxicity risk). Now, we know that the identification of breast cancer subtypes dictates the prognosis and specific treatment. Therefore, practical treatment guidelines in the era of personalized medicine are classified by subtypes.

#### The current standard of care for newly diagnosed IBC

Based on the above information and international consensus on IBC [39], based on collaboration with experts from high-volume centers, there is broad agreement that upfront systemic treatment should be administered before surgery. This systemic treatment comprises sequential treatment with anthracycline-based and taxane-based chemotherapy, with or without carboplatin. Although different centers with IBC clinics may administer slightly different systemic regimens, the backbone chemotherapy regimen is the same. We present the current neoadjuvant and adjuvant therapy for IBC from our center in Table 2. These recommendations differ according to the IBC subtype.

##### a Triple-negative

Anthracycline- and taxane-based chemotherapy remain the backbone of neoadjuvant therapy for triple-negative IBC. A dose-dense regimen may be integrated into some situations, but both risks and benefits need to be considered. The addition of carbo-

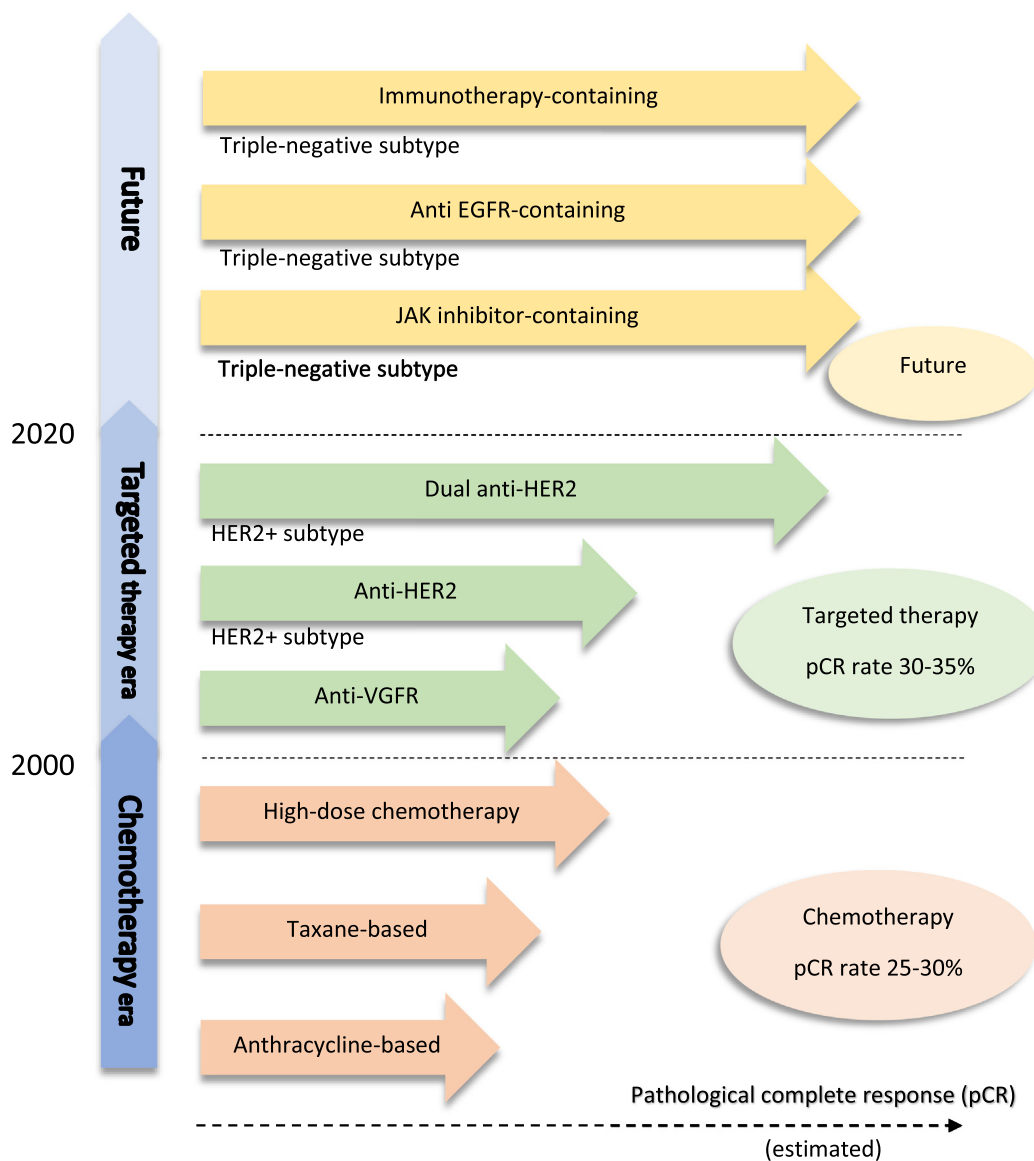


Fig. 1. Timeline of systemic treatment for inflammatory breast cancer.

platin to a neoadjuvant regimen increases the pCR rate in TNBC [92,93], but these data do not include IBC patients. Hence, there are no data to support carboplatin for IBC [39]. A randomized phase 3 study, CREATE-X [94], showed that patients with HER2- non-pCR breast cancer treated with adjuvant capecitabine had longer OS than those given an adjuvant placebo (hazard ratio = 0.59, 95% CI 0.39–0.90), suggesting that adjuvant capecitabine for six to eight cycles can be considered in cases without a pCR. Interestingly, a more pronounced OS benefit was observed in triple-negative disease (hazard ratio = 0.52, 95% CI 0.30–0.90).

b *HR-positive*

The response rate to NAC is low in HR+ breast cancer compared with TNBC. Nevertheless, NAC, similar to that used in TNBC, is recommended for HR+ breast cancer. As for adjuvant therapy, a key consideration is that IBC carries a high risk for recurrence. Furthermore, ER+ breast cancer has a risk of recurrence after 5 years. Therefore, extended adjuvant endocrine therapy can help reduce recurrence risk. The use of either tamoxifen or aromatase inhibitors for extended adjuvant therapy for up to 10 years has been

associated with improved survival outcomes in breast cancer [95–98]. Among premenopausal breast cancer patients, based on the TEXT and SOFT trials, the addition of ovarian suppression to adjuvant endocrine therapy showed higher rates of DFS and OS in high-risk patients than endocrine therapy alone [99].

Despite the potential survival benefit of extended adjuvant endocrine therapy and ovarian suppression, these approaches also may incur their own adverse events and long-term toxicity. For example, the addition of ovarian suppression increased the rate of osteoporosis, diabetes, cardiovascular disease, and depression [99]. Some of these adverse effects may be treatable; for example, the use of bisphosphonate can increase bone density and may also improve survival in breast cancer patients [100]. Now, an ongoing trial of adjuvant endocrine therapy plus immune checkpoint inhibitors in patients with non-pCR, HR+/HER2- breast cancer after neoadjuvant therapy is enrolling (NCT02971748).

c *HER2-positive*

For HER2+ IBC, based on the NeoSphere and TRYPHAENA trials, the recommended neoadjuvant therapy is a regimen containing

**Table 2**

Current regimen for newly diagnosed inflammatory breast cancer from Morgan Welch Inflammatory Breast Cancer Clinic, The University of Texas MD Anderson Cancer Center.

Subtype	Regimen	Comment	
Neoadjuvant therapy	Triple-negative	Weekly paclitaxel (or DD paclitaxel) followed by standard AC regimen (or DD AC regimen)	Consider carboplatin to paclitaxel if patient is eligible
	ER-positive	Weekly paclitaxel (or DD paclitaxel) followed by standard AC regimen (or DD AC regimen)	
	HER2-positive	THP × 4 cycles followed by AC × 4 cycles or AC × 4 followed by THP × 4 cycles (DD or every 3 weeks)	TCHP × 6 cycles as a second option
Adjuvant therapy	Triple-negative	Non-pCR: capecitabine	
	ER-positive	(1st choice) Aromatase inhibitor +/- ovarian function suppression for 10 years (2nd choice) Tamoxifen for 10 years	Adjuvant bisphosphonate
	HER2-positive	pCR: trastuzumab + pertuzumab Non-pCR: T-DM1	Offer neratinib

Abbreviations: ER, estrogen receptor; HER2, human epidermal growth factor receptor 2; pCR, pathologic complete response; DD, dose-dense; AC, doxorubicin and cyclophosphamide; THP, docetaxel plus trastuzumab and pertuzumab; TCHP, docetaxel, and carboplatin plus pertuzumab and trastuzumab.

pertuzumab plus trastuzumab (dual anti-HER2 antibodies) in combination with an anthracycline-containing regimen (specifically, THP for four cycles followed by an anthracycline-containing regimen for four cycles). No data are demonstrating the superiority of dual anti-HER2 antibodies with a non-anthracycline regimen (TCHP regimen for six cycles) over the dual anti-HER2 antibodies with the anthracycline-containing regimen, because the primary endpoint of TRYPHAENA trial [62] was safety and tolerability, which cannot be used to determine conclusions about the efficacy of each regimen. Therefore, we still have recommended the dual anti-HER2 antibodies in combination with an anthracycline-containing regimen for HER2+ IBC.

Even for patients who experience a pCR after neoadjuvant therapy, those with HER2+ IBC are still at a high risk of recurrence [15]. Adjuvant pertuzumab plus trastuzumab for 1 year are recommended in HER2+ breast cancer based on the APHINITY trial [75], which showed benefit from adjuvant dual anti-HER2 antibodies in high-risk patients. In HER2+ IBC cases without a pCR, adjuvant T-DM1 is recommended (KATERINE trial [74]). After the completion of adjuvant anti-HER2 therapy, neratinib is recommended in the high-risk situation, especially non-pCR patients, and should discuss to risk-benefit assessment for pCR patients [76]. However, grade 3–4 diarrhea was commonly found (40%) with neratinib compared with placebo (2%), leading to discontinuation of neratinib in up to 28% of patients treated with neratinib [76]; anti-diarrheal prophylaxis should be offered.

#### d De novo stage IV IBC

For patients with de novo stage IV IBC, we recommend similar systemic treatment to that of non-metastatic IBC, intending to achieve optimal response. Patients should then be evaluated for surgery and radiation therapy by a multidisciplinary team. In cases that show a response or stable disease after neoadjuvant therapy, local therapy at the primary breast tumor (e.g., modified radical mastectomy followed by radiation) should be discussed working

with a multidisciplinary team. Although the survival impact of local therapy of the primary tumor in the metastatic setting is controversial, loco-regional progression in IBC can lead to serious morbidity [39].

## Immunotherapy and future directions

### Role of immunotherapy in clinical data

Recently, the U.S. Food and Drug Administration accelerated approval of the anti-PD-L1 immune checkpoint inhibitor atezolizumab in combination with nab-paclitaxel in patients with unresectable or metastatic triple-negative breast cancer (TNBC) whose tumor expresses PD-L1 ( $\geq 1\%$ ), based on phase 3 randomized trial (IMpassion130) [101]. In the neoadjuvant setting, immunotherapy for breast cancer has been investigated in two randomized trials, KEYNOTE-522 [102] and I-SPY2 [103]. KEYNOTE-522 studied the combination of anti-PD-1 (pembrolizumab) with preoperative chemotherapy, carboplatin plus paclitaxel followed by the AC regimen, in patients with TNBC (including IBC patients), followed by adjuvant pembrolizumab, met one of the dual-primary endpoints (pCR rate). The combination of pembrolizumab and chemotherapy showed significant improvement in pCR rate compared with placebo plus chemotherapy (64.8% vs. 51.2%,  $P < 0.001$ ). The improved benefit was consistent with respect to the pCR rate across subgroups, including both PD-L1 expressions positive or negative. Besides, an ongoing phase 2 trial, the adaptively randomized I-SPY2 trial [103], is evaluating the effect of pembrolizumab on pCR rate in high-risk stage II-III breast cancer. This study is using multiple investigational arms in parallel and using the standard neoadjuvant arm as the common control arm; weekly paclitaxel for 12 cycles followed by AC regimen for 4 cycles. They reported the pCR rate of HER2- patient treated with weekly paclitaxel plus every 3 weeks of pembrolizumab for 12 weeks, then AC regime for 4 cycles was 44% compared with pCR rate of control arm 17%. For the triple-negative subtype and the HR+/HER2- subtype, pCR rates were 60% and 30%, respectively, in the pembrolizumab arm but 22% and 13%, respectively in the control arm.

### Future directions

Previously mentioned studies suggest that the combination of an immune checkpoint inhibitor and chemotherapy increases response rate and efficacy in breast cancer; however, the number of IBC patients in those trials was limited. A study from our institute showed that PD-L1 was expressed in 36.8% of IBC tumor cells on immunohistochemical staining (monoclonal rabbit anti-PD-L1 antibody, clone 28-8). PD-L1 expression in the tumor was not associated with clinicopathologic characters, including histologic type, tumor grade, or ER, progesterone receptor, or HER2 status; however, PD-L1-positive tumors ( $>1\%$  of tumor cells) were associated with worse OS [104]. The incidence of PD-L1 expression in this study was similar to that of a study by Bertucci et al., which reported PD-L1 overexpression in 38% of IBC tumor cells and 28% in non-IBC tumors, according to mRNA expression using DNA microarray [105]. On the other hand, PD-L1 mRNA overexpression was associated with ER- status, basal and HER2+ subtypes, and higher pCR rate after NAC, but not OS [105]. PD-L1 expression is found not only in tumor cells but also in tumor-infiltrating lymphocytes (TILs), which are considered to be the main effector of immunotherapy. Arias-Pulido et al. reported 221 IBC samples had PD-L1 positivity of 66% in the TILs and more than 8% in the tumor cells and also showed that PD-L1 expression ( $\geq 5\%$ ) in the TILs was associated with the better DFS [106]. Berckelaer et al. reported 105



IBC samples had PD-L1 positivity ( $\geq 1\%$ ) in the TILs, more than in the TILs of non-IBC samples, 42.9% vs. 23.7%, respectively [107].

Taken together, these findings indicate that PD-L1 is an immune checkpoint molecule that is found in both the tumor cells and the TILs of IBC more frequently than in non-IBC, and thus is a potential predictive biomarker for immunotherapy. Beyond the combination of chemotherapy and an immune checkpoint inhibitor, as used in the KEYNOTE-522 and I-SPY2 trials, our institute also demonstrates IBC preclinical data supporting a combination of targeted therapy and an immune checkpoint inhibitor [108]. Further, an anti-EGFR agent combined with an anti-PD-L1 antibody inhibited the growth of IBC tumors more than either single-agent treatment (unpublished data). Even if immunotherapy studies conducted specifically in IBC patients have not been established, these findings provide a rationale for future studies of the use of immune checkpoint inhibitors as a part of IBC treatment. To fill this gap in knowledge, ongoing immunotherapy studies are enrolling patients with IBC in many trials, as shown in Table 1. Another issue is a slow accrual problem of IBC clinical trials; multicenter clinical trials are an important key to resolve this problem. Hopefully, clinicians and researchers will be motivated to cooperate.

## Conclusion

Frequent distant metastases and poor prognosis indicate that IBC is a unique entity rather than a subtype of LABC. IBC has high potential for fatality, urgently necessitating the development of novel systemic treatments. This review shows that anthracycline and taxane are the backbone of chemotherapy and remain a current treatment. We do not have scientific evidence to deescalate the treatment as in non-IBC settings. We have learned from the past that high-dose chemotherapy with AHST is too toxic a strategy, with no apparent benefit. In the targeted therapy era, only anti-HER2 therapies have been incorporated into the current standard IBC treatment. Recently, a high pCR rate has been produced by immune checkpoint inhibitors for non-IBC; the preclinical findings suggest a possible role for immunotherapy in IBC in the future. We hope this review provides a foundation of knowledge for the development of new treatment approaches, especially for IBC-specific clinical trials. Utilizing a multicenter approach in a global level is a key to improved success of IBC clinical trials.

## Compliance with Ethics Requirements

*This article does not contain any studies with human or animal subjects.*

## Declaration of Competing Interest

Naoto T. Ueno has a research agreement with Amgen, Celgene and PUMA Oncology. The other authors declare that they have no known competing financial interests or personal relationships that could have appeared to influence the work reported in this paper.

## Acknowledgment

We would like to thank Sarah Bronson of Scientific Publications, Research Medical Library, MD Anderson Cancer Center for her help in editing this article.

## Funding

This review article is supported by the Morgan Welch Inflammatory Breast Cancer Research Program, a State of Texas Rare and Aggressive Breast Cancer Research Program Grant, National

Institutes of Health and The MD Anderson Cancer Center Support Grant from the US National Cancer Institute (CA016672).

## References

- [1] Hance KW, Anderson WF, Devesa SS, Young HA, Levine PH. Trends in inflammatory breast carcinoma incidence and survival: the surveillance, epidemiology, and end results program at the National Cancer Institute. *J Natl Cancer Inst* 2005;97(13):966–75.
- [2] Goldner B, Behrendt CE, Schoellhammer HF, Lee B, Chen SL. Incidence of inflammatory breast cancer in women, 1992–2009. *United States Ann Surg Oncol* 2014;21(4):1267–70.
- [3] Schinkel JK, Zahm SH, Jatoi I, McGlynn KA, Gallagher C, Schairer C, et al. Racial/ethnic differences in breast cancer survival by inflammatory status and hormonal receptor status: an analysis of the Surveillance, Epidemiology, and End Results data. *Cancer Causes Control* 2014;25(8):959–68.
- [4] Zhang H, Ma G, Du S, Sun J, Zhang Q, Yuan B, et al. Nomogram for predicting cancer specific survival in inflammatory breast carcinoma: a SEER population-based study. *PeerJ* 2019;7:e7659.
- [5] Dawood S, Ueno NT, Valero V, Woodward WA, Buchholz TA, Hortobagyi GN, et al. Differences in survival among women with stage III inflammatory and noninflammatory locally advanced breast cancer appear early: a large population-based study. *Cancer* 2011;117(9):1819–26.
- [6] van Uden DJP, van Maaren MC, Strobbe LJA, Bult P, van der Hoeven JJ, Siesling S, et al. Metastatic behavior and overall survival according to breast cancer subtypes in stage IV inflammatory breast cancer. *Breast Cancer Res* 2019;21(1).
- [7] Fouad TM, Kogawa T, Liu DD, Shen Y, Masuda H, El-Zein R, et al. Overall survival differences between patients with inflammatory and noninflammatory breast cancer presenting with distant metastasis at diagnosis. *Breast Cancer Res Treat* 2015;152(2):407–16.
- [8] Schlichting JA, Soliman AS, Schairer C, Schottenfeld D, Merajver SD. Inflammatory and non-inflammatory breast cancer survival by socioeconomic position in the Surveillance, Epidemiology, and End Results database, 1990–2008. *Breast Cancer Res Treat* 2012;134(3):1257–68.
- [9] van Uden DJ, Bretveld R, Siesling S, de Wilt JH, Blanken-Peeters CF. Inflammatory breast cancer in the Netherlands; improved survival over the last decades. *Breast Cancer Res Treat* 2017;162(2):365–74.
- [10] Fayanju OM, Ren Y, Greenup RA, Plichta JK, Rosenberger LH, Force J, et al. Extent of axillary surgery in inflammatory breast cancer: a survival analysis of 3500 patients. *Breast Cancer Res Treat* 2020;180(1):207–17.
- [11] Giuliano AE, Edge SB, Hortobagyi GN. Eighth Edition of the AJCC Cancer Staging Manual: Breast Cancer. *Ann Surg Oncol* 2018;25(7):1783–5.
- [12] Bonnier P, Charpin C, Lejeune C, Romain S, Tubiana N, Beedassy B, et al. Inflammatory carcinomas of the breast: a clinical, pathological, or a clinical and pathological definition?. *Int J Cancer* 1995;62(4):382–5.
- [13] Dawood S, Merajver SD, Viens P, Vermeulen PB, Swain SM, Buchholz TA, et al. International expert panel on inflammatory breast cancer: consensus statement for standardized diagnosis and treatment. *Ann Oncol* 2011;22(3):515–23.
- [14] Wu SG, Zhang WW, Wang J, Dong Y, Sun JY, Chen YX, et al. Inflammatory breast cancer outcomes by breast cancer subtype: A population-based study. *Future Oncol* 2019;15(5):507–16.
- [15] Masuda H, Brewer TM, Liu DD, Iwamoto T, Shen Y, Hsu L, et al. Long-term treatment efficacy in primary inflammatory breast cancer by hormonal receptor- and HER2-defined subtypes. *Ann Oncol* 2014;25(2):384–91.
- [16] Matro JM, Li T, Cristofanilli M, Hughes ME, Ottesen RA, Weeks JC, et al. Inflammatory breast cancer management in the national comprehensive cancer network: the disease, recurrence pattern, and outcome. *Clin Breast Cancer* 2015;15(1):1–7.
- [17] Biswas T, Efrid JT, Walker PR, James SE, Prasad S, Zagar T. Inflammatory TNBC breast cancer: Demography and clinical outcome in a large cohort of TNBC patients. *Journal of Clinical Oncology Conference* 2014;32(15 SUPPL. 1).
- [18] Uemura MI, French JT, Hess KR, Liu D, Raghav K, Hortobagyi GN, et al. Development of CNS metastases and survival in patients with inflammatory breast cancer. *Cancer* 2018;124(11):2299–305.
- [19] Wang Z, Chen M, Pan J, Wang X, Chen XS, Shen KW. Pattern of distant metastases in inflammatory breast cancer - A large-cohort retrospective study. *J Cancer* 2020;11(2):292–300.
- [20] Cortazar P, Zhang L, Untch M, Mehta K, Costantino JP, Wolmark N, et al. Pathological complete response and long-term clinical benefit in breast cancer: the CTNeoBC pooled analysis. *Lancet (London, England)* 2014;384(9938):164–72.
- [21] Yee D, DeMichele A, Isaacs C, Symmans F, Yau C, Albain K, et al. Abstract GS3-08: Pathological complete response predicts event-free and distant disease-free survival in the I-SPY2 TRIAL. *Cancer Res* 2018;78(4 Supplement). GS3-08-GS3.
- [22] Ueno NT, Buzdar AU, Singletary SE, Ames FC, McNeese MD, Holmes FA, et al. Combined-modality treatment of inflammatory breast carcinoma: twenty years of experience at M. D. Anderson Cancer Center. *Cancer Chemother Pharmacol* 1997;40(4):321–9.
- [23] van Uden DJP, van Maaren MC, Bult P, Strobbe LJA, van der Hoeven JJM, Blanken-Peeters C, et al. Pathologic complete response and overall survival in breast cancer subtypes in stage III inflammatory breast cancer. *Breast Cancer Res Treat* 2019;176(1):217–26.

- [24] Koh EH, Buzdar AU, Ames FC, Singletary SE, McNeese MD, Frye D, et al. Inflammatory carcinoma of the breast: results of a combined-modality approach—M.D. Anderson Cancer Center experience. *Cancer Chemother Pharmacol* 1990;27(2):94–100.
- [25] Rueth NM, Lin HY, Bedrosian I, Shaitelman SF, Ueno NT, Shen Y, et al. Underuse of trimodality treatment affects survival for patients with inflammatory breast cancer: an analysis of treatment and survival trends from the National Cancer Database. *J Clin Oncol* 2014;32(19):2018–24.
- [26] National Comprehensive Cancer Network. *Breast Cancer (Version 3.2020)*; 2020 [Available from: [https://www.nccn.org/professionals/physician\\_gls/pdf/breast.pdf](https://www.nccn.org/professionals/physician_gls/pdf/breast.pdf)].
- [27] Cardoso F, Kyriakides S, Ohno S, Penault-Llorca F, Poortmans P, Rubio IT, et al. Early breast cancer: ESMO Clinical Practice Guidelines for diagnosis, treatment and follow-up. *Ann Oncol* 2019;30(10):1674.
- [28] Harris EE, Schultz D, Bertsch H, Fox K, Glick J, Solin LJ. Ten-year outcome after combined modality therapy for inflammatory breast cancer. *Int J Radiat Oncol Biol Phys* 2003;55(5):1200–8.
- [29] Baldini E, Gardin G, Evagelista G, Prochilo T, Collecchi P, Lionetto R. Long-term results of combined-modality therapy for inflammatory breast carcinoma. *Clin Breast Cancer* 2004;5(5):358–63.
- [30] Low JA, Berman AW, Steinberg SM, Danforth DN, Lippman ME, Swain SM. Long-term follow-up for locally advanced and inflammatory breast cancer patients treated with multimodality therapy. *J Clin Oncol* 2004;22(20):4067–74.
- [31] Cristofanilli M, Gonzalez-Angulo AM, Buzdar AU, Kau SW, Frye DK, Hortobagyi GN. Paclitaxel improves the prognosis in estrogen receptor negative inflammatory breast cancer: the M. D. Anderson Cancer Center experience. *Clin Breast Cancer* 2004;4(6):415–9.
- [32] Cristofanilli M, Buzdar AU, Sneige N, Smith T, Wasaff B, Ibrahim N, et al. Paclitaxel in the multimodality treatment for inflammatory breast carcinoma. *Cancer* 2001;92(7):1775–82.
- [33] Bonadonna G, Zambetti M, Valagussa P. Sequential or alternating doxorubicin and CMF regimens in breast cancer with more than three positive nodes. Ten-year results. *JAMA* 1995;273(7):542–7.
- [34] Ditsch N, Vodermaier A, Hinke A, Burghardt S, Lenhard M, Lohrs B, et al. Dose-intensified sequential versus conventionally-dosed anthracycline and taxane-containing neoadjuvant therapy in patients with inflammatory breast cancer. *Anticancer Res* 2012;32(8):3539–45.
- [35] Ellis GK, Barlow WE, Gralow JR, Hortobagyi GN, Russell CA, Royce ME, et al. Phase III comparison of standard doxorubicin and cyclophosphamide versus weekly doxorubicin and daily oral cyclophosphamide plus granulocyte colony-stimulating factor as neoadjuvant therapy for inflammatory and locally advanced breast cancer: SWOG 0012. *J Clin Oncol* 2011;29(8):1014–21.
- [36] Masuda H, Iwamoto T, Brewer T, Hsu L, Kai K, Woodward WA, et al. Response to neoadjuvant systemic therapy (NST) in inflammatory breast cancer (IBC) according to estrogen receptor (ER) and HER2 expression. *Cancer Research Conference: 35th Annual CTRC AACR San Antonio Breast Cancer Symposium San Antonio, TX United States Conference. Publication* 2012;72(24 SUPPL. 3).
- [37] Shin HJ, Kim HH, Ahn JH, Kim SB, Jung KH, Gong G, et al. Comparison of mammography, sonography, MRI and clinical examination in patients with locally advanced or inflammatory breast cancer who underwent neoadjuvant chemotherapy. *Br J Radiol* 2011;84(1003):612–20.
- [38] Bertucci F, Ueno NT, Finetti P, Vermeulen P, Lucci A, Robertson FM, et al. Gene expression profiles of inflammatory breast cancer: correlation with response to neoadjuvant chemotherapy and metastasis-free survival. *Ann Oncol* 2014;25(2):358–65.
- [39] Ueno NT, Espinosa Fernandez JR, Cristofanilli M, Overmoyer B, Rea D, Berdichevski F, et al. International consensus on the clinical management of Inflammatory Breast Cancer from the Morgan Welch Inflammatory Breast Cancer research program 10th anniversary conference. *J Cancer* 2018;9(8):1437–47.
- [40] Antman KH, Rowlings PA, Vaughan WP, Pelz CJ, Fay JW, Fields KK, et al. High-dose chemotherapy with autologous hematopoietic stem-cell support for breast cancer in North America. *J Clin Oncol* 1997;15(5):1870–9.
- [41] Cheng YC, Shi Y, Zhang MJ, Brazauskas R, Hemmer MT, Bishop MR, et al. Long-Term Outcome of Inflammatory Breast Cancer Compared to Non-Inflammatory Breast Cancer in the Setting of High-Dose Chemotherapy with Autologous Hematopoietic Cell Transplantation. *J Cancer* 2017;8(6):1009–17.
- [42] Viens P, Penault-Llorca F, Jacquemier J, Gravis G, Cowen D, Bertucci F, et al. High-dose chemotherapy and haematopoietic stem cell transplantation for inflammatory breast cancer: pathologic response and outcome. *Bone Marrow Transplant* 1998;21(3):249–54.
- [43] Schwartzberg L, Weaver C, Lewkow L, McAneny B, Zhen B, Birch R, et al. High-dose chemotherapy with peripheral blood stem cell support for stage IIIB inflammatory carcinoma of the breast. *Bone Marrow Transplant* 1999;24(9):981–7.
- [44] Somlo G, Frankel P, Chow W, Leong L, Margolin K, Morgan Jr R, et al. Prognostic indicators and survival in patients with stage IIIB inflammatory breast carcinoma after dose-intense chemotherapy. *J Clin Oncol* 2004;22(10):1839–48.
- [45] Viens P, Palangie T, Janvier M, Fabbro M, Roche H, Delozier T, et al. First-line high-dose sequential chemotherapy with rG-CSF and repeated blood stem cell transplantation in untreated inflammatory breast cancer: toxicity and response (PEGASE 02 trial). *Br J Cancer* 1999;81(3):449–56.
- [46] Palangie T, Viens P, Roché H, Beuzeboc P, Dieras V, Dorval T, et al. Dose-intensified chemotherapy and additional Docetaxel may improve inflammatory breast cancer patients outcome over two decades: Results from Institut Curie protocols 1977–1987 and two consecutive French multicenter trials Pegase 02 (1995–96) and Pegase 05 (1997–99). *J Clin Oncol* 2004;22(14\_suppl):848.
- [47] Goncalves A, Monneur A, Viens P, Bertucci F. The use of systemic therapies to prevent progression of inflammatory breast cancer: which targeted therapies to add on cytotoxic combinations?. *Expert Rev Anticancer Ther* 2017;17(7):593–606.
- [48] Goncalves A, Pierga JY, Ferrero JM, Mouret-Reynier MA, Bachelot T, Delva R, et al. UNICANCER-PEGASE 07 study: a randomized phase III trial evaluating postoperative docetaxel-5FU regimen after neoadjuvant dose-intense chemotherapy for treatment of inflammatory breast cancer. *Ann Oncol* 2015;26(8):1692–7.
- [49] Carlson LE, Koski T, Gluck S. Longitudinal effects of high-dose chemotherapy and autologous stem cell transplantation on quality of life in the treatment of metastatic breast cancer. *Bone Marrow Transplant* 2001;27(9):989–98.
- [50] Parton M, Dowsett M, Ashley S, Hills M, Lowe F, Smith IE. High incidence of HER-2 positivity in inflammatory breast cancer. *Breast* 2004;13(2):97–103.
- [51] Dawood S, Broglio K, Gong Y, Yang WT, Cristofanilli M, Kau SW, et al. Prognostic significance of HER-2 status in women with inflammatory breast cancer. *Cancer* 2008;112(9):1905–11.
- [52] Zell JA, Tsang WY, Taylor TH, Mehta RS, Anton-Culver H. Prognostic impact of human epidermal growth factor-like receptor 2 and hormone receptor status in inflammatory breast cancer (IBC): Analysis of 2,014 IBC patient cases from the California Cancer Registry. *Breast Cancer Res* 2009;11(1) (no pagination) (R9).
- [53] Li J, Xia Y, Wu Q, Zhu S, Chen C, Yang W, et al. Outcomes of patients with inflammatory breast cancer by hormone receptor- and HER2-defined molecular subtypes: A population-based study from the SEER program. *Oncotarget* 2017;8(30):49370–9.
- [54] Gianni L, Eiermann W, Semiglazov V, Lluch A, Tjulandin S, Zambetti M, et al. Neoadjuvant and adjuvant trastuzumab in patients with HER2-positive locally advanced breast cancer (NOAH): follow-up of a randomised controlled superiority trial with a parallel HER2-negative cohort. *Lancet Oncol* 2014;15(6):640–7.
- [55] Gianni L, Pienkowski T, Im YH, Roman L, Tseng LM, Liu MC, et al. Efficacy and safety of neoadjuvant pertuzumab and trastuzumab in women with locally advanced, inflammatory, or early HER2-positive breast cancer (NeoSphere): a randomised multicentre, open-label, phase 2 trial. *Lancet Oncol* 2012;13(1):25–32.
- [56] Pizzuti L, Barba M, Giannarelli D, Sergi D, Botti C, Marchetti P, et al. Neoadjuvant Sequential Docetaxel Followed by High-Dose Epirubicin in Combination With Cyclophosphamide Administered Concurrently With Trastuzumab. *The DECT Trial J Cell Physiol* 2016;231(11):2541–7.
- [57] Torrisi R, Cardillo A, Cancelli G, Dellapasqua S, Balduzzi A, Ghisini R, et al. Phase II trial of combination of pegylated liposomal doxorubicin, cisplatin, and infusional 5-fluorouracil (CCF) plus trastuzumab as preoperative treatment for locally advanced and inflammatory breast cancer. *Clin Breast Cancer* 2010;10(6):483–8.
- [58] Baselga J, Cortes J, Kim SB, Im SA, Hegg R, Im YH, et al. Pertuzumab plus trastuzumab plus docetaxel for metastatic breast cancer. *N Engl J Med* 2012;366(2):109–19.
- [59] Baselga J, Swain SM. Novel anticancer targets: revisiting ERBB2 and discovering ERBB3. *Nat Rev Cancer* 2009;9(7):463–75.
- [60] Swain SM, Ewer MS, Viale G, Delalogue S, Ferrero JM, Verrill M, et al. Pertuzumab, trastuzumab, and standard anthracycline- and taxane-based chemotherapy for the neoadjuvant treatment of patients with HER2-positive localized breast cancer (BERENICE): a phase II, open-label, multicenter, multinational cardiac safety study. *Ann Oncol* 2018;29(3):646–53.
- [61] Gianni L, Pienkowski T, Im YH, Tseng LM, Liu MC, Lluch A, et al. 5-year analysis of neoadjuvant pertuzumab and trastuzumab in patients with locally advanced, inflammatory, or early-stage HER2-positive breast cancer (NeoSphere): a multicentre, open-label, phase 2 randomised trial. *Lancet Oncol* 2016;17(6):791–800.
- [62] Schneeweiss A, Chia S, Hickish T, Harvey V, Eniu A, Hegg R, et al. Pertuzumab plus trastuzumab in combination with standard neoadjuvant anthracycline-containing and anthracycline-free chemotherapy regimens in patients with HER2-positive early breast cancer: a randomized phase II cardiac safety study (TRYPHAENA). *Ann Oncol* 2013;24(9):2278–84.
- [63] Schneeweiss A, Chia S, Hickish T, Harvey V, Eniu A, Waldron-Lynch M, et al. Long-term efficacy analysis of the randomised, phase II TRYPHAENA cardiac safety study: Evaluating pertuzumab and trastuzumab plus standard neoadjuvant anthracycline-containing and anthracycline-free chemotherapy regimens in patients with HER2-positive early breast cancer. *Eur J Cancer* 2018;89:27–35.
- [64] Overmoyer B, Regan M, Hu J, Nakhli F, Dominici L, Lin N, et al. Abstract P6-15-11: Weekly paclitaxel, pertuzumab and trastuzumab (TPH) neoadjuvant therapy for HER2 positive inflammatory breast cancer. *Cancer Res* 2018;78(4 Supplement). P6-15-1-P6-1.
- [65] Scaltriti M, Verma C, Guzman M, Jimenez J, Parra JL, Pedersen K, et al. Lapatinib, a HER2 tyrosine kinase inhibitor, induces stabilization and accumulation of HER2 and potentiates trastuzumab-dependent cell cytotoxicity. *Oncogene* 2009;28(6):803–14.

- [66] Untch M, Loibl S, Bischoff J, Eidtmann H, Kaufmann M, Blohmer JU, et al. Lapatinib versus trastuzumab in combination with neoadjuvant anthracycline-taxane-based chemotherapy (GeparQuinto, GBG 44): a randomised phase 3 trial. *Lancet Oncol* 2012;13(2):135–44.
- [67] Untch M, von Minckwitz G, Gerber B, Schem C, Rezai M, Fasching PA, et al. Survival Analysis After Neoadjuvant Chemotherapy With Trastuzumab or Lapatinib in Patients With Human Epidermal Growth Factor Receptor 2-Positive Breast Cancer in the GeparQuinto (G5) Study (GBG 44). *J Clin Oncol* 2018;36(13):1308–16.
- [68] Bousсен H, Cristofanilli M, Zaks T, DeSilvio M, Salazar V, Spector N. Phase II study to evaluate the efficacy and safety of neoadjuvant lapatinib plus paclitaxel in patients with inflammatory breast cancer. *J Clin Oncol* 2010;28(20):3248–55.
- [69] Alvarez RH, Cristofanilli M, Ensor J, Lucci A, Yang WT, Huang TLP, et al. Limited efficacy and significant toxicities of lapatinib (Lap) plus chemotherapy as neoadjuvant therapy (NAC) for HER2-positive inflammatory breast cancer (IBC) patients (Pts). *J Clin Oncol Conf* 2012;30(15 SUPPL. 1).
- [70] Johnston S, Trudeau M, Kaufman B, Bousсен H, Blackwell K, LoRusso P, et al. Phase II study of predictive biomarker profiles for response targeting human epidermal growth factor receptor 2 (HER-2) in advanced inflammatory breast cancer with lapatinib monotherapy. *J Clin Oncol* 2008;26(7):1066–72.
- [71] Baselga J, Bradbury I, Eidtmann H, Di Cosimo S, de Azambuja E, Aura C, et al. Lapatinib with trastuzumab for HER2-positive early breast cancer (NeoALTTO): a randomised, open-label, multicentre, phase 3 trial. *Lancet (London, England)* 2012;379(9816):633–40.
- [72] Barok M, Joensuu H, Isola J. Trastuzumab emtansine: mechanisms of action and drug resistance. *Breast Cancer Res* 2014;16(2):209.
- [73] Hurvitz SA, Martin M, Symmans WF, Jung KH, Huang CS, Thompson AM, et al. Neoadjuvant trastuzumab, pertuzumab, and chemotherapy versus trastuzumab emtansine plus pertuzumab in patients with HER2-positive breast cancer (KRISTINE): a randomised, open-label, multicentre, phase 3 trial. *Lancet Oncol* 2018;19(1):115–26.
- [74] von Minckwitz G, Huang CS, Mano MS, Loibl S, Mamounas EP, Untch M, et al. Trastuzumab Emtansine for Residual Invasive HER2-Positive Breast Cancer. *N Engl J Med* 2019;380(7):617–28.
- [75] von Minckwitz G, Procter M, de Azambuja E, Zardavas D, Benyunes M, Viale G, et al. Adjuvant Pertuzumab and Trastuzumab in Early HER2-Positive Breast Cancer. *N Engl J Med* 2017;377(2):122–31.
- [76] Chan A, Delaloge S, Holmes FA, Moy B, Iwata H, Harvey VJ, et al. Neratinib after trastuzumab-based adjuvant therapy in patients with HER2-positive breast cancer (ExteNET): a multicentre, randomised, double-blind, placebo-controlled, phase 3 trial. *Lancet Oncol* 2016;17(3):367–77.
- [77] Volk L, Wilber A, Desai N, Trieu V, Ran S. Nab-paclitaxel and bevacizumab treatment in new models of inflammatory breast cancer, SUM149-RR and SUM149-GL. In: *Cancer Research Conference: 101st Annual Meeting of the American Association for Cancer Research, AACR, vol. 70, no. suppl. 1: 2010.*
- [78] Bertucci F, Fekih M, Autret A, Petit T, Dalenc F, Levy C, et al. Bevacizumab plus neoadjuvant chemotherapy in patients with HER2-negative inflammatory breast cancer (BEVERLY-1): A multicentre, single-arm, phase 2 study. *Lancet Oncol* 2016;17(5):600–11.
- [79] Pierga JY, Petit T, Levy C, Ferrero JM, Campone M, Gligorov J, et al. Pathological response and circulating tumor cell count identifies treated HER2+ inflammatory breast cancer patients with excellent prognosis: BEVERLY-2 survival data. *Clin Cancer Res* 2015;21(6):1298–304.
- [80] Palazzo A, Dellapasqua S, Munzone E, Bagnardi V, Mazza M, Cancellato G, et al. Phase II Trial of Bevacizumab Plus Weekly Paclitaxel, Carboplatin, and Metronomic Cyclophosphamide With or Without Trastuzumab and Endocrine Therapy as Preoperative Treatment of Inflammatory Breast Cancer. *Clin Breast Cancer* 2018;18(4):328–35.
- [81] Pierga JY, Bidard FC, Autret A, Petit T, Andre F, Dalenc F, et al. Circulating tumour cells and pathological complete response: independent prognostic factors in inflammatory breast cancer in a pooled analysis of two multicentre phase II trials (BEVERLY-1 and -2) of neoadjuvant chemotherapy combined with bevacizumab. *Ann Oncol* 2017;28(1):103–9.
- [82] Gianni L, Romieu GH, Lichinitser M, Serrano SV, Mansutti M, Pivrot X, et al. AVEREL: a randomized phase III Trial evaluating bevacizumab in combination with docetaxel and trastuzumab as first-line therapy for HER2-positive locally recurrent/metastatic breast cancer. *J Clin Oncol Off J Am Soc Clin Oncol* 2013;31(14):1719–25.
- [83] Cameron D, Brown J, Dent R, Jackisch C, Mackey J, Pivrot X, et al. Adjuvant bevacizumab-containing therapy in triple-negative breast cancer (BEATRICE): primary results of a randomised, phase 3 trial. *Lancet Oncol* 2013;14(10):933–42.
- [84] Matsuda N, Lim B, Wang X, Ueno NT. Early clinical development of epidermal growth factor receptor targeted therapy in breast cancer. *Expert Opin Invest Drugs* 2017;26(4):463–79.
- [85] Cabioglu N, Gong Y, Islam R, Broglio KR, Sneige N, Sahin A, et al. Expression of growth factor and chemokine receptors: new insights in the biology of inflammatory breast cancer. *Ann Oncol* 2007;18(6):1021–9.
- [86] Matsuda N, Wang X, Lim B, Krishnamurthy S, Alvarez RH, Willey JS, et al. Safety and Efficacy of Panitumumab Plus Neoadjuvant Chemotherapy in Patients With Primary HER2-Negative Inflammatory Breast Cancer. *JAMA Oncol* 2018;4(9):1207–13.
- [87] Johnston SR, Gomez H, Stemmer SM, Richie M, Durante M, Pandite L, et al. A randomized and open-label trial evaluating the addition of pazopanib to lapatinib as first-line therapy in patients with HER2-positive advanced breast cancer. *Breast Cancer Res Treat* 2013;137(3):755–66.
- [88] Cristofanilli M, Johnston SR, Manikhas A, Gomez HL, Gladkov O, Shao Z, et al. A randomized phase II study of lapatinib + pazopanib versus lapatinib in patients with HER2+ inflammatory breast cancer. *Breast Cancer Res Treat* 2013;137(2):471–82.
- [89] Swanton C, Cromer J. Open-label, phase II trial of afatinib, with or without vinorelbine (V), for the treatment of HER2-overexpressing inflammatory breast cancer (IBC). *J Clin Oncol Conf* 2012;30(15 SUPPL. 1).
- [90] Goh G, Schmid R, Guiver K, Arpornwirat W, Chitapanarux I, Ganju V, et al. Clonal Evolutionary Analysis during HER2 Blockade in HER2-Positive Inflammatory Breast Cancer: A Phase II Open-Label Clinical Trial of Afatinib +/- Vinorelbine. *PLoS Med* 2016;13(12):e1002136.
- [91] Specht JM, Kurland BF, Linden HM, Gralow J, Gadi VK, Ellis GK, et al. A phase II study evaluating the safety and efficacy of sunitinib with weekly paclitaxel followed by doxorubicin and daily oral cyclophosphamide plus G-CSF as neoadjuvant chemotherapy (NC) for locally advanced (LABC) or inflammatory breast cancer (IBC). *J Clin Oncol Conf* 2013;31(15 SUPPL. 1).
- [92] von Minckwitz G, Schneeweiss A, Loibl S, Salat C, Denkert C, Rezai M, et al. Neoadjuvant carboplatin in patients with triple-negative and HER2-positive early breast cancer (GeparSixto; GBG 66): a randomised phase 2 trial. *Lancet Oncol* 2014;15(7):747–56.
- [93] Sikow WM, Berry DA, Perou CM, Singh B, Cirrincione CT, Tolaney SM, et al. Impact of the addition of carboplatin and/or bevacizumab to neoadjuvant once-per-week paclitaxel followed by dose-dense doxorubicin and cyclophosphamide on pathologic complete response rates in stage II to III triple-negative breast cancer: CALGB 40603 (Alliance). *J Clin Oncol* 2015;33(1):13–21.
- [94] Masuda N, Lee SJ, Ohtani S, Im YH, Lee ES, Yokota I, et al. Adjuvant Capecitabine for Breast Cancer after Preoperative Chemotherapy. *N Engl J Med* 2017;376(22):2147–59.
- [95] Davies C, Pan H, Godwin J, Gray R, Arriagada R, Raina V, et al. Long-term effects of continuing adjuvant tamoxifen to 10 years versus stopping at 5 years after diagnosis of oestrogen receptor-positive breast cancer: ATLAS, a randomised trial. *Lancet (London, England)* 2013;381(9869):805–16.
- [96] Gray RG, Rea D, Handley K, Bowden SJ, Perry P, Earl HM, et al. aTOM: Long-term effects of continuing adjuvant tamoxifen to 10 years versus stopping at 5 years in 6,953 women with early breast cancer. *J Clin Oncol* 2013;31(18 suppl):5.
- [97] Goss PE, Ingle JN, Martino S, Robert NJ, Muss HB, Piccart MJ, et al. A randomized trial of letrozole in postmenopausal women after five years of tamoxifen therapy for early-stage breast cancer. *N Engl J Med* 2003;349(19):1793–802.
- [98] Goss PE, Ingle JN, Pritchard KI, Robert NJ, Muss H, Gralow J, et al. Extending Aromatase-Inhibitor Adjuvant Therapy to 10 Years. *N Engl J Med* 2016;375(3):209–19.
- [99] Francis PA, Pagani O, Fleming GF, Walley BA, Colleoni M, Lang I, et al. Tailoring Adjuvant Endocrine Therapy for Premenopausal Breast Cancer. *N Engl J Med* 2018;379(2):122–37.
- [100] Gnant M, Mlineritsch B, Stoeger H, Luschin-Ebengreuth G, Knauer M, Moik M, et al. Zoledronic acid combined with adjuvant endocrine therapy of tamoxifen versus anastrozole plus ovarian function suppression in premenopausal early breast cancer: final analysis of the Austrian Breast and Colorectal Cancer Study Group Trial 12. *Ann Oncol* 2015;26(2):313–20.
- [101] Schmid P, Adams S, Rugo HS, Schneeweiss A, Barrios CH, Iwata H, et al. Atezolizumab and Nab-Paclitaxel in Advanced Triple-Negative Breast Cancer. *N Engl J Med* 2018;379(22):2108–21.
- [102] Schmid P, Cortes J, Pusztai L, McArthur H, Kummel S, Bergh J, et al. Pembrolizumab for Early Triple-Negative Breast Cancer. *N Engl J Med* 2020;382(9):810–21.
- [103] Nanda R, Liu MC, Yau C, Shatsky R, Pusztai L, Wallace A, et al. Effect of Pembrolizumab Plus Neoadjuvant Chemotherapy on Pathologic Complete Response in Women With Early-Stage Breast Cancer: An Analysis of the Ongoing Phase 2 Adaptively Randomized I-SPY2 Trial. *JAMA Oncol* 2020.
- [104] He J, Huo L, Ma J, Zhao J, Bassett RL, Sun X, et al. Expression of Programmed Death Ligand 1 (PD-L1) in Posttreatment Primary Inflammatory Breast Cancers and Clinical Implications. *Am J Clin Pathol* 2018;149(3):253–61.
- [105] Bertucci F, Finetti P, Colpaert C, Mamessier E, Parizel M, Dirix L, et al. PDL1 expression in inflammatory breast cancer is frequent and predicts for the pathological response to chemotherapy. *Oncotarget* 2015;6(15):13506–19.
- [106] Arias-Pulido H, Cimino-Mathews A, Chaher N, Qualls C, Joste N, Colpaert C, et al. The combined presence of CD20 + B cells and PD-L1 + tumor-infiltrating lymphocytes in inflammatory breast cancer is prognostic of improved patient outcome. *Breast Cancer Res Treat* 2018;171(2):273–82.
- [107] Van Berckelaer C, Rypens C, van Dam P, Pouillon L, Parizel M, Schats KA, et al. Infiltrating stromal immune cells in inflammatory breast cancer are associated with an improved outcome and increased PD-L1 expression. *Breast Cancer Res* 2019;21(1):28.



[108] Wang X, Shao S, Semba T, Pearson T, Re JM, Tripathy D, et al. Abstract 4492: Humanized anti-EGFR antibody panitumumab inhibits tumor growth of inflammatory breast cancer by inducing antitumor immunity. *Cancer Res* 2019.



**Sudpreeda Chaititkun** graduated with a fellowship in medical oncology in 2015 at King Chulalongkorn Memorial Hospital, Chulalongkorn University, Thailand. Then, he worked as a medical oncologist at King Chulalongkorn Memorial Hospital and Mahachai Hospital, where he had extensive experience in the oncology field and patient service. Currently, he is in a training program as a postdoctoral fellow in the Department of Breast Medical Oncology–Research at The University of Texas MD Anderson Cancer Center, Houston, Texas, USA. His research is focusing on clinical research of breast cancer treatment.



**Sadia Saleem** is an assistant professor in the department of Breast Medical Oncology at The University of Texas MD Anderson Cancer Center, Houston, Texas, USA. She completed her fellowship in hematology and oncology at UT Southwestern in Dallas, Texas. She serves as co-investigator on multiple breast cancer clinical trials. Dr. Saleem’s key interests include management of IBC, TNBC, and metastatic breast cancer. She strives to increase patient access to clinical trial protocols at the Houston area locations to improve patient care opportunities and outcomes.



**Bora Lim** is an assistant professor at The University of Texas MD Anderson Cancer Center, Houston, Texas, USA. She is a translational investigator who seeks to discover a novel therapeutic strategy to halt or treat aggressive breast cancer by apoptosis (effective cancer cell killing) induction strategy. She also studies new ways of delivering these novel agents and seeks to determine a correct target population using new diagnostic methods such as liquid biopsy and single-cell genomics. She is a member of IBC and TNBC working groups and serves as faculty in an advanced breast cancer clinic.



**Vicente Valero** has been with The University of Texas MD Anderson Cancer Center, Houston, Texas, USA, since June 1991. He is an actively involved teacher in the Breast Medical Oncology Clinic for fellows and residents at MD Anderson Cancer Center, where he was honored as Teacher of the Year for the 1993-1994 and 1996-1997 academic years and the Educator of the Month for December 2003. He has more than 200 publications including articles in peer-reviewed journals, editorials, invited articles, book chapters, and abstracts.



**Naoto T. Ueno** is a professor of medicine at The University of Texas MD Anderson Cancer Center, Houston, Texas, USA. He is breast medical oncologist who specializes in IBC, TNBC, and metastatic breast cancer. He is the executive director of the Morgan Welch Inflammatory Breast Cancer Program and Clinic and section chief of the Translational Breast Cancer Research at the Department of Breast Medical Oncology. He also directly supervises numerous medical students, graduate students, postdoctoral fellows, junior faculty, and clinical residents and fellows. Currently, he has more than 200 related breast cancer publications.