

Case Report

Aseptic loosening of an APTIS distal radioulnar joint arthroplasty – Case report

Karis Bennett, Srinath Kamineni*

University of Kentucky (Orthopaedic Surgery & Sports Medicine), Lexington, KY 40536, United States of America

ARTICLE INFO

Keywords:

APTIS
Aseptic loosening
DRUJ

ABSTRACT

Dysfunction of the distal radioulnar joint can cause significant pain and instability. The self-stabilizing APTIS distal radioulnar joint prosthesis is used as a solution for severe distal radioulnar joint pathologies. We present a case of a 60-year-old male, who received an APTIS distal radioulnar joint prosthesis which resulted in aseptic loosening within five years of the initial implantation. Infection, incorrect implantation, demographic differences and over-activity were all excluded as the source; therefore, mechanical aseptic loosening was concluded. Ultimately, two surgeries were required to resolve the patient's pain, which resulted in a one-bone forearm once the implant was extracted. The solution to a failed APTIS implant, a one bone forearm, is difficult and protracted, so every effort should be attempted to preserve distal ulna bone stock before resorting to the implantation of this device.

Introduction

A stable distal radioulnar joint (DRUJ) is one of several crucial elements in load transmission between the hand and elbow, and pathologies that dysfunction the DRUJ cause painful deficits of this weight-bearing function [1,2]. Several pathologies including inflammatory arthritis and post-traumatic arthritis can cause DRUJ dysfunction and instability and can occasionally lead to an irreparable DRUJ [3,4]. In DRUJ pathologies with significant distal ulna bone loss, forearm function may be restored by performing, among other procedures, a DRUJ arthroplasty [1,3].

Prosthetic DRUJ arthroplasties have become increasingly more common, as they improve the strength of the fingers, forearm and wrist while, also, improving one's ability to lift heavy objects [1]. One such prosthetic DRUJ arthroplasty that is available is the APTIS DRUJ implant (Manufactured by APTIS Medical located in Louisville, Kentucky, US), with most published studies reporting a 95% or greater survival rate after 60 months [5]. This prosthesis does not require attachment to the triangular fibrocartilage complex, like many other DRUJ prostheses, as it replaces the sigmoid notch function; therefore it is self-stabilizing [1,6,7].

We present a case of an APTIS arthroplasty loosening and the subsequent management to resolve the patient's debilitating symptoms. We discuss the sequence of procedures performed prior to the DRUJ arthroplasty, while, also describing the revision procedures that were required.

* Corresponding author at: Room K412, Dept. of Orthopaedics and Sports Medicine, Elbow Shoulder Research Center (ESRC), Kentucky Clinic, University of Kentucky, 740 S. Limestone, Lexington, KY 40536, United States of America.

E-mail address: srinathkamineni@gmail.com (S. Kamineni).

<https://doi.org/10.1016/j.tcr.2019.100196>

Accepted 7 April 2019

Available online 15 April 2019

2352-6440/ © 2019 Published by Elsevier Ltd. This is an open access article under the CC BY-NC-ND license (<http://creativecommons.org/licenses/by-nc-nd/4.0/>).

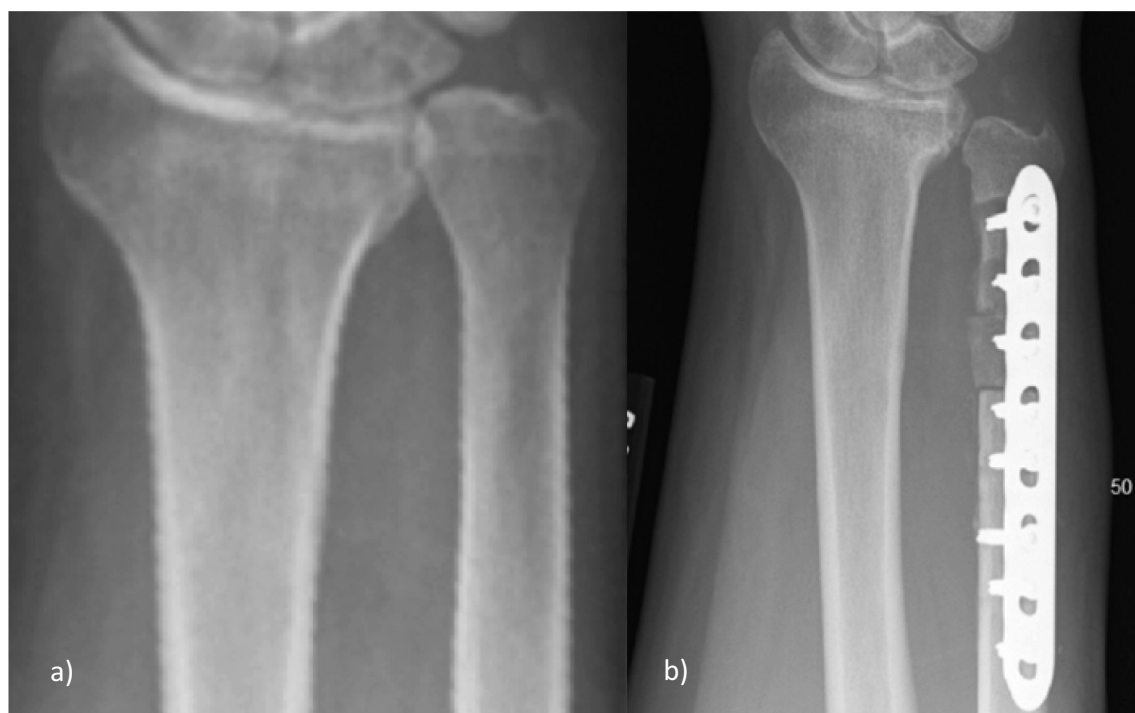

Fig. 1. a: This image shows the initial ulnar positive variance that caused the patient great pain. b: This image shows that the patient's ulnar shortening osteotomy was unsuccessful, as the distal part of the ulna resulted in a non-union.

Case report

A 60-year-old male presented to the senior author with a painful wrist/forearm, having had an APTIS arthroplasty for distal ulna loss and DRUJ instability five years previously. Since all conservative managements had failed, he sought pain relief and wrist/DRUJ stability.

The original clinical presentation was of a painful wrist with ulnar positive variance (Fig. 1a), which was treated with an ulna shortening osteotomy, resulting in a non-union (Fig. 1b). A revision surgery also failed, which resulted in a structurally compromised distal ulna and unstable DRUJ (Fig. 2). Due to the ongoing significant symptoms, a fellowship-trained hand surgeon implanted an APTIS arthroplasty to treat the loss of distal ulna and the unstable DRUJ. The initial post-operative radiographs looked unremarkable (Fig. 3a), but at a five-month follow-up visit, the patient started to complain of pain in the mid-forearm, and radiographs revealed early loosening of the ulna stem.

Routine inflammatory markers were negative for infection, and his activities were sedentary. He was managed conservatively for five years, with increasing pain, increasing regular analgesic usage, and radiographic increasing ulna stem loosening, resulting in a 'windscreen wiper' ballooning of the proximal ulna (Fig. 3b). The radiographs clearly show a loose stem, ballooned cortices and a disengaged distal articulation due to proximal migration of the stem. He was, at this stage, referred with intractable pain of 8–9/10 on a visual analogue score (VAS), to our service.

The pre-operative hematological indices did not reveal any results suspicious for infection, and an initial operation was performed to remove the APTIS implant, and to attempt a fusion of the radius to ulna by removing intervening soft-tissues between them and decorticating the facing surfaces. The patient was maintained in a long arm cast for six weeks, but the bones did not heal to form a single bone forearm. The ulna intramedullary curettage material was sent for microbiological testing, but resulted in no bacterial/fungal growth after 30 days. Allergy testing did not reveal nickel or other sensitivities. Having eliminated infection as a source for loosening and pain, in a second operation, the remaining proximal ulna was fused to the radius, in a 15° pronated forearm position, with three 3.5 mm stainless steel screws and iliac crest derived stem cells, harvested with the Biomet Biocue® system mixed with demineralized bone matrix. The patient was maintained in a long arm cast for three months, and a long arm splint for a further 3 months, with serial x-rays to assess the progress of the fusion. Once the fusion was confirmed with clinical examination and radiographs by the sixth month (Fig. 4), the patient rated his pain as 2/10 on a VAS. At his four-year clinic follow-up, his radiographs revealed a solid bony radio-ulnar fusion and his VAS is 1–2/10, and he has returned to most activities of daily living, limited by the loss of forearm rotation. His active elbow arc of motion was 15°–120°, and his wrist arc of motion was 15° extension, 30° flexion, 10° ulna deviation, and 15° radial deviation.

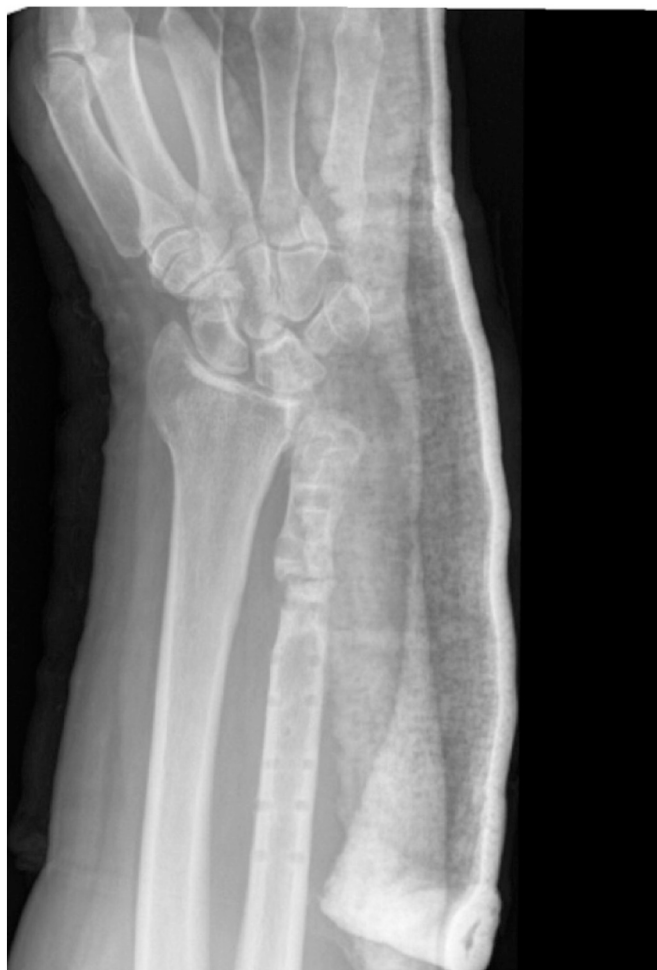

Fig. 2. This image shows that the failed revision surgery resulted in a structurally compromised distal ulna and unstable DRUJ.

Discussion

The DRUJ functions as a stabilizer of the wrist, allows force transmission across the wrist to the forearm, and allows supination and pronation of the forearm [8]. Painful dysfunction and instability of the DRUJ has a dramatically negative impact on the ability to perform activities of daily living. Several strategies to relieve DRUJ pain and instability have been documented in the literature, including distal ulnar replacement [3,8] and allograft reconstruction [5] with varying results/clinical outcomes. DRUJ implants are treatment options once other more conservative treatments that preserve the ulnar head, such as osteotomies, ligament reconstructions, and triangular fibrocartilage reconstructions, have been unsuccessful in lessening the patient's pain [5].

The APTIS arthroplasty has been documented in the literature with at least a 95% survival rate over five years and few failures have been published [5,8]. In a recent retrospective study, it was reported that 35% (18/51) of patients with an APTIS DRUJ arthroplasty required revision surgeries within eight years of initial implantation to relieve their pain [8]. Out of the 18 complications, only one patient required an explant and one-bone forearm fusion, as the most common complication was periprosthetic fracture, which was treated by open reduction and internal fixation (ORIF) [8]. Aseptic loosening of the APTIS DRUJ prosthesis was, also, reported as a possible complication within eight years of the initial implantation, but aseptic loosening has not been reported to occur in patients as early as five months after implantation, as we report in this case [8]. The case presented reveals an aseptic loosening of the APTIS stem, and subsequent radiographs suggest a toggling effect with ballooning both proximal and distal to the center point of the stem. The consequences of the stem loosening resulted in a proximal migration of the stem within the ulnar shaft and a resultant uncoupling from the distal articulation. Although we have a second referred patient with a loose APTIS stem with manageable symptoms, the current presented case report demonstrates a patient with sufficient symptoms to warrant revision surgery. Due to the age of the patient, functional demands, and painful symptomatology, the management required ex-plantation of the APTIS implant and the subsequent difficult fusion of the ulnar shaft to the radius.

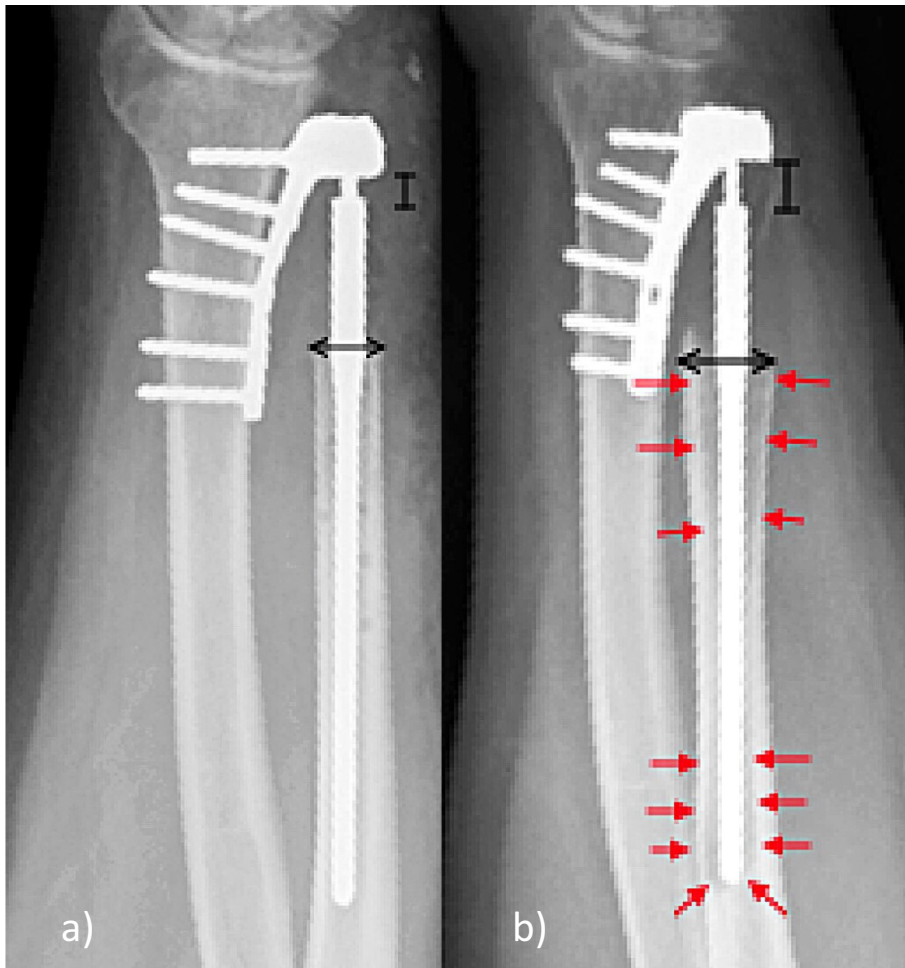


Fig. 3. a: This image is the initial post-operative radiograph of the APTIS arthroplasty implantation, which reveals that the DRUJ appears stable. b: This image shows the loosening of the APTIS arthroplasty, as the ulna is ballooned and the stem is subsided. This image was taken 5 years after Fig. 4, the initial APTIS arthroplasty implantation.

The mechanism of loosening of this implant is not clear. Hematological indices and intra-operative cultures excluded infection as a source. A radiographic analysis of the implantation images at the original post-operative visit revealed that the implant was well-seated and correctly sized. Since the patient had a relatively sedentary lifestyle, excessive load-bearing is not an obvious mechanism, especially since radiographic loosening was evident as early as five months post-surgery. Previous published studies reveal that patient demographics, notably age, smoking, injury incidence, and number of prior procedures, do not have a significant impact on the success or complication of the APTIS implant [9,10]. Therefore, as infection, incorrect sizing, over-activity, and demographic differences have been ruled out as the source of this loosening, the cause of the implant failure is indistinct. However, the consequence of this loosening consisted of multiple surgeries to create a one bone forearm with a reduced range of motion, in forearm rotation, which ultimately resulted in pain relief and improved function for the patient.

Conclusion

Due to the difficulty of achieving a fusion between the remnant of the ulna to the radius, following a failed APTIS arthroplasty, every effort should be made to preserve the distal ulna and DRUJ stability. Only if other reconstructive attempts have failed should an APTIS implant be used.

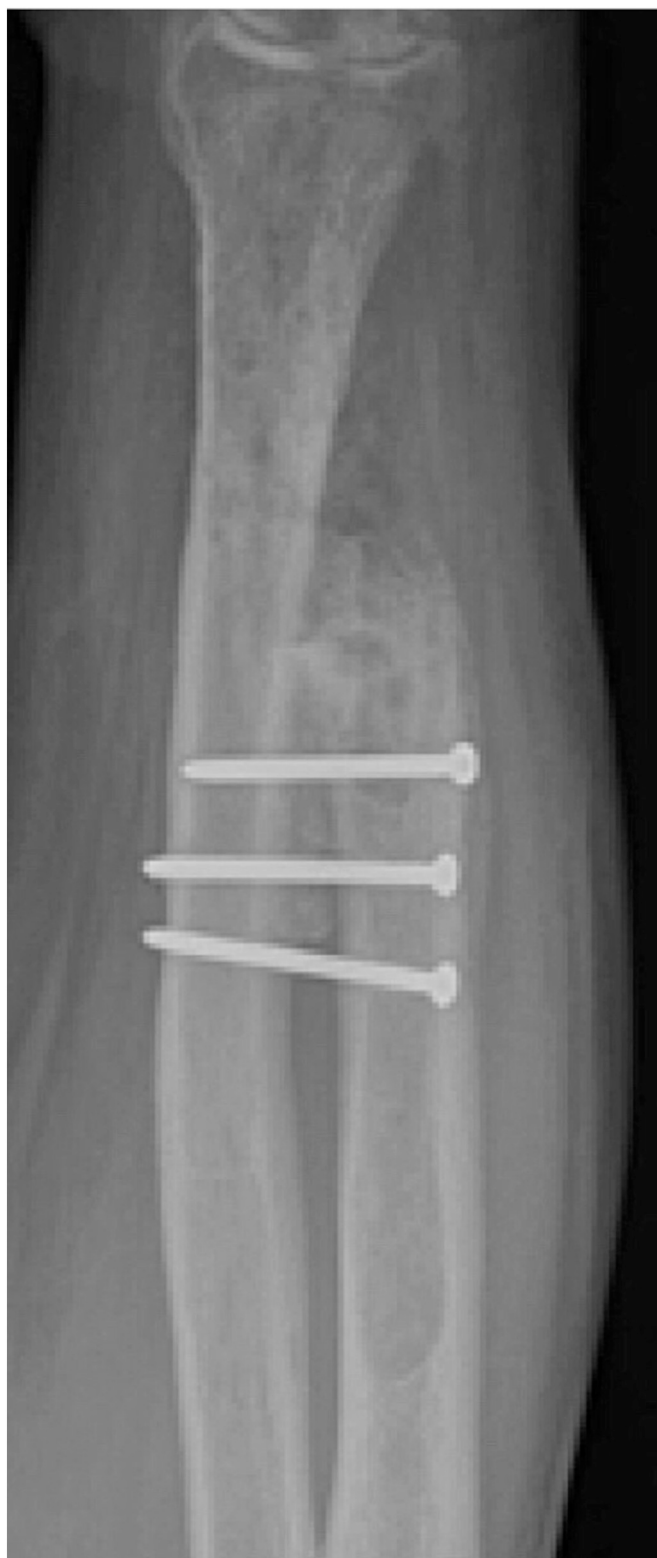

Fig. 4. This image reveals the subsequent outcome procedure of a fused ulna and radius once the APTIS implant was removed.

Acknowledgements

No financial remunerations for either author exist.

References

- [1] A. Rampazzo, B.B. Gharb, G. Brock, L.R. Scheker, Functional outcomes of the Aptis-Scheker distal radioulnar joint replacement in patients under 40 years old, *J. Hand. Surg. [Am.]* 40 (7) (2015) 1397–1403, <https://doi.org/10.1016/j.jhsa.2015.04.028>.
- [2] L.R. Scheker, Arthritis of the distal radioulnar joint, *Tech. Orthop.* 24 (1) (2009) 32–41, <https://doi.org/10.1097/bto.0b013e3181a07edc>.
- [3] E.J. Galvis, J. Pessa, L.R. Scheker, Total joint arthroplasty of the distal radioulnar joint for rheumatoid arthritis, *J. Hand. Surg. [Am.]* 39 (9) (2014) 1699–1703, <https://doi.org/10.1016/j.jhsa.2014.03.043>.
- [4] G.L. Kaiser, L.S. Bodell, R.A. Berger, Functional outcomes after arthroplasty of the distal radioulnar joint and hand therapy: a case series, *J. Hand Ther.* 21 (4) (2008) 398–407, <https://doi.org/10.1197/j.jht.2008.06.002>.
- [5] W.P. Cooney III, R.A. Berger, Distal radioulnar joint implant arthroplasty, *American Society for Surg of the Hand* 5 (4) (2005) 217–219, <https://doi.org/10.1016/j.jassh.2005.08.004>.
- [6] L.R. Scheker, Replacement of distal radioulnar joint, *Over Tech Orthop* 22 (2012) 112–118, <https://doi.org/10.1053/j.oto.2012.04.001>.
- [7] R.M. Strigel, M.L. Richardson, Distal radioulnar joint arthroplasty with a Scheker prosthesis, *Radiol. Case Rep.* 1 (2) (2006) 65–67, <https://doi.org/10.2484/rcr.v1i2.29>.
- [8] K.D. Bellevue, M.K. Thayer, M.P. Pouliot, J.I. Huang, D. Hanel, Complications of Aptis DRUJ arthroplasty, *J. Hand. Surg. [Am.]* 22 (3) (2017) S14–S15, <https://doi.org/10.1016/j.jhsa.2017.06.039>.
- [9] L.R. Scheker, D.W. Martineau, Distal radioulnar joint constrained arthroplasty, *Hand Clin.* 29 (1) (2013) 113–121, <https://doi.org/10.1016/j.hcl.2012.08.023>.
- [10] Willis AA, Berger RA, Cooney III WP. Arthroplasty of the distal radioulnar joint using a new ulnar head endoprosthesis: preliminary report. *J. Hand. Surg. [Am.]* 2007;32A:177–89. DOI:<https://doi.org/10.1016/j.jhsa.2006.12.004>.