

Neurologic Wilson disease: case series on a diagnostic and therapeutic emergency

Romeo V. Porlas Jr, MD; Lennie Lynn C. de Castillo, MD;
Carissa Paz C. Dioquino, MD



Introduction

In 1912, a British neurologist, Samuel Wilson, described a neurologic disorder with pathologic findings of degeneration of the lenticular nucleus in the brain and hepatocytes in the liver. It was then called progressive hepatolenticular degeneration, better known by its eponym, Wilson disease (WD).^{1,2,4}

WD is attributed to a rare autosomal recessive genetic defect on ATP7B, a metal-transporting P-type adenosine triphosphate on chromosome 13q14.3. Deficiency or absence of the transporter protein results to decreased biliary excretion of copper and thereby excessive deposition of copper in the liver, central nervous system, cornea, kidney, and cardiac muscles.³

WD has a prevalence rate of 15 to 30 cases per million, qualifying as a rare disease based on the criterion of European Commission on Public Health and Institute of Human Genetics.⁴

The manifestations of WD are more likely to be hepatic in early childhood, and neurologic in adolescents and young adults. WD has varied presentations, classified into three movement disorder syndromes:

1. Dystonia (dystonic postures and choreoathetosis)
2. Ataxia (ataxia with postural and intentional tremors)
3. Parkinsonian symptoms (hypokinesia, rigidity, and resting tremors)²

Wilson disease is a rare genetic disease causing pathologic deposition of copper in the liver, brain, cornea, kidney, and cardiac muscles. Presented are two cases of neurologic Wilson disease with progressive movement disorder and Kayser-Fleischer rings with low serum copper, low ceruloplasmin, and increased 24-hour urine copper against a background of normal transaminases. Cranial imaging revealed symmetric basal ganglia hyperintensities in T2/FLAIR. More often than not, these cases go unnoticed and misdiagnosed because of its rarity and varied presentation. Extensive workup is necessary to confirm the diagnosis. As for management, the earlier the intervention is initiated, the better prognosis would be for recovery. There are several treatment options and should be tailored to every patient with neurologic Wilson disease. Neurologic Wilson disease is considered as a copper toxicity; immediate diagnostic evaluation and early treatment initiation is a must.

© 2018, AICH – Servier Group

Dialogues Clin Neurosci. 2018;20:341-345.

Keywords: copper toxicity; Kayser-Fleischer rings; progressive hepatolenticular degeneration; Wilson disease

Author affiliations: Department of Neurosciences, College of Medicine and Philippine General Hospital, University of the Philippines, Manila (Romeo Porlas, Lennie Lynn C. de Castillo, Carissa Paz C. Dioquino); National

Poison Management and Control Center, Philippine General Hospital, University of the Philippines, Manila, Philippines (Carissa Paz C. Dioquino)

Address for correspondence: Romeo V. Porlas, Jr, Sampaloc, Manila, National Capital Region, Philippines (email: rom916@yahoo.com)

Free paper

Emphasis should be given to reviewing vignettes, diagnostics, and treatment of patients in order to catch these rare conditions early and subsequently initiate treatment. We present two vignettes of WD.

Clinical vignettes

Case 1

A 20-year-old female presented with 12-month history of slowing of movement and difficulty writing legibly, with occasional reports of postural tremors, right more than the left and blurring of vision. She developed slurring of speech and involuntary hand movements.

Pertinent neurologic examination revealed a Mini-Mental Status Examination (MMSE) score of 29/30, with deficit in attention and choreiform movements in upper and lower extremities coupled with athetoid movements of the hands. Classic wing-beating tremors were observed in the right arm. On passive range of motion, there was mild rigidity, right more than the left, and bradykinesia noted on rapid fine movements of fingers. Generalized hyperreflexia and tendency to fall backward on walking were observed.

Case 2

A 21-year-old female presented initially with spontaneous abortion, and then had slurring of speech and stiffness of the jaw, with occasional reports of cramps of facial muscles. She then developed tremors and stiffening of right extremities, which progressed to involve the contralateral side with accompanying weakness over a span of 18 months. Over the succeeding 4 months, there was progression of stiffness causing posturing of legs and difficulty ambulating, and worsening kinetic tremors. There were also episodes of freezing of gait and uncontrolled grin.

Relevant neurologic findings were: MMSE of 27/28, with deficit in recall. Poor gutturals and tongue fasciculations were noted on cranial nerve examination. There was marked atrophy of the intrinsic muscles of the hand and posterior leg muscles with paradoxical hypertrophy of triceps and quadriceps. Dystonic inversion posturing of both feet was notable on walking. The patient also had generalized rigidity and kinetic tremors, more prominent on the right than the left.

Diagnostic workup

The two cases were worked up for WD and can be classified differently; the first case falls into the ataxic type with parkinsonian symptoms and the second case fits the dystonic with parkinsonian symptoms (*Table I*).^{5,6}

Both of the patients were subjected to slit-lamp examination revealing the presence of Kayser-Fleischer rings (*Figure 1*). A complete hepatic workup was done, revealing normal liver function: transaminases and clotting factors but with gross structural abnormalities noted on sonography (*Table II*). Diagnostic workup for copper accumulation revealed low serum copper,

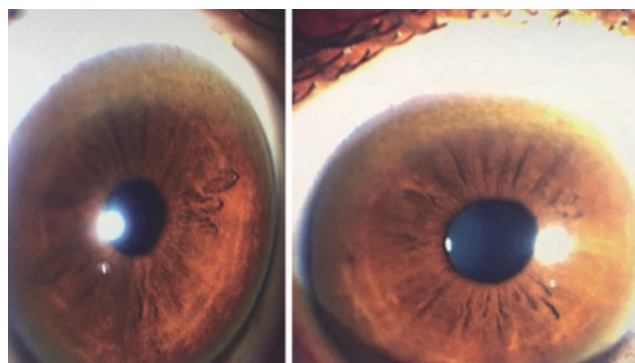


Figure 1. Kayser-Fleischer rings, copper deposition over Descemet's membrane. Kayser-Fleischer rings were said to be present in 50% of those with hepatic presentation and 99% of neurologic presentation.

Vignette	Age/sex	Time to diagnosis	Presenting symptoms	Initial diagnosis	Neurologic progression	Classification	UWDRS
Case 1	20/ Female	12 months	Worsening handwriting	Essential tremors	Micrographia → tremors → imbalance → choreoathetoid movements	N2 (Ataxic with Parkinsonian)	I 0 II 13 III 32
Case 2	21/ Female	18 months	Slurring of speech	Spasmodic dysphonia	Dysphonia → tremors → rigidity → dystonia	N2 (Dystonic)	I 0 II 18 III 54

Table I. Clinical vignette summary; Wilson disease phenotypic classification; unified Wilson's Disease Rating Scale (UWDRS).

low ceruloplasmin, and increased urinary excretion of copper.^{7,8,9,10} Genetic testing was not done on these patients.

Magnetic resonance imaging of the brain did not reveal the typical double panda sign but showed symmetrical T2/FLAIR hyperintensities over the putamen, caudate and thalami nucleus (*Figure 2 and Figure 3*).^{11,12}

Both findings were highly suggestive of mineral deposition. Furthermore, following the scoring by Leipzig et al, the two vignettes are definite cases of WD.^{8,13,16}

Because of the rarity of the disease, it is not cost-effective to initiate population-based screening. Screening however should be compulsory for patients presenting with unexplained neurological

Vignette	Slit lamp examination	HoloAbdominal ultrasound	Liver function tests	Coagulation studies	Serum copper	Serum ceruloplasmin	24-hour urine copper	Leipzig score
Case 1	(+) Kayser-Fleischer rings	Normal sized liver with diffuse parenchymal disease hyperechoic solid nodule, segment IV of the liver	AST 25 (nv 15-41) ALT 20 (nv 14-54)	PT 14.0/13.2/0.96/1.02 PTT 29.5/38.7	0.37 µg/mL (nv 0.75-1.45 µg/mL)	< 2.00 (nv 22.00-58.00 mg/dL)	105 µg/mL (nv 15-60 µg/specimen)	8
Case 2	(+) Kayser-Fleischer rings	Cirrhotic liver changes with multiple hepatic nodules	AST 27 (nv 10-35) ALT 25 (nv 10-35)	PT 14.0/12.7/83.1/1.11 PTT 40/30.40	0.30 µg/mL (nv 0.75-1.45 µg/mL)	3.0 (nv 20.00-60.00 mg/dL)	143 µg/mL (nv 15-60 µg/specimen)	8

Serum ceruloplasmin: alpha2-globulin copper binding protein, cleaved from apoceruloplasmin when copper is introduced by the ATP7B transporter protein

8th International Meeting on Wilson Disease Scoring System (Leipzig Score)

Clinical symptoms and signs with initial diagnostics		Additional workup and genetic testing	
Kayser-Fleischer rings Present Absent	2	Liver copper (in the absence of cholestasis) >5x of upper limit (>4 mol/g) 0.8-4mol/g Normal (<0.8 mol/g) Rhodanine-positive granules	2
	0		1
			-1
			1
Neurologic symptoms Severe Mild Absent	2	Urinary copper (in the absence of acute hepatitis) Normal, but > 5x of upper limit after chelation > 2x of upper limit 1-2x of upper limit Normal	2
	1		2
	0		1
			0
Serum ceruloplasmin <0.1 g/L 0.1 – 0.2 g/L Normal (>0.2 g/L)	2	Mutation analysis On both chromosomes detected On 1 chromosome detected No mutation detected	4
	1		1
	0		0
Coombs-negative hemolytic anemia Present Absent	1		
	0		
Total score			
4 or more:	Diagnosis established		
3:	Diagnosis possible, more tests needed		
2:	Diagnosis very unlikely		

Table II. Diagnostic examination summary; 8th International Meeting on Wilson disease scoring system.

Free paper

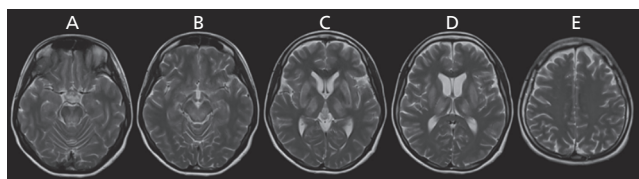


Figure 2. Representative images of T2-weighted sequence of Case 1. **A.** Upper pontine and lower midbrain axial cut; there are hyperintensities over the dorsal region **B.** Upper midbrain axial cut; there are confluent hyperintensities over the midbrain tegmentum **C.** Sylvian fissure axial cut; there are prominent hyperintensities over the lateral thalami, caudate, and putaminal region **D.** Insular region axial cut; extensive bilateral hyperintensities over the thalami and basal ganglia are seen **E.** Corona radiata axial cut; bilateral centum semiovale were spared of any signal abnormality

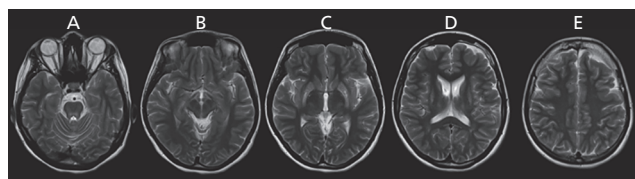


Figure 3. Representative images of T2-weighted sequences of Case 2. **A.** Upper pontine axial cut; there are hyperintensities over the dorsal pontine region **B.** Upper midbrain axial cut; there is normal looking red nucleus with hyperintensities over the area of substantia nigra **C.** Sylvian fissure axial cut; there are prominent hyperintensities over the putamen with areas of magnetic susceptibility artifacts, left more than the right **D.** Lateral ventricle region axial cut, continuous extensive hyperintensities over the putamen and caudate are seen **E.** Corona radiata axial cut, bilateral centum semiovale were spared of any signal abnormality

disease with or without associated liver disease. WD must be distinguished from mimickers such as essential tremor, young-onset Parkinson's disease, generalized dystonia, and other rare movement disorders like Huntington disease, Hallervorden-Spatz disease,

idiopathic torsion dystonia, chorea-acanthocytosis and benign familial chorea. WD is therefore a diagnostic emergency, needing a complete and immediate work-up.²

Drug	Mechanism of action	Starting dose	Administration	Side effects	Effect on WD	Monitoring
D-penicillamine	Chelator, acts by increasing urinary excretion of copper	250 mg/tab 1 tab every 6 hours	Should be given 1 hour before or 2 hours meals	Rash, immune complex nephropathy, thrombocytopenia, leucocytopenia, systemic lupus erythematosus	50% chance of neurologic worsening	24-hour urine copper, complete blood count and liver function tests
Trientine	Chelator, acts by increasing urinary excretion of copper	750-1500 mg in divided doses	Should be given 1 hour before or 2 hours meals	Proteinuria, bone marrow suppression and autoimmune disease, gastric disturbance	25% chance of neurologic worsening during the initial course of medications	24-hour urine copper, complete blood count and liver function tests, creatinine and urinalysis
Zinc salts	Induces intestinal cell metallothionein that prevents absorption of food copper and salivary copper	50 mg/tab 1 tab thrice a day	Should be taken on an empty stomach	Gastric disturbances: bloating and nausea	Decoppering effect is slow, taking 4-8 months to be effective	24-hour urine copper, complete blood count and liver function tests, creatinine and urinalysis
Tetrathiomolybdate	Acts by forming a tripartite complex with copper and protein, preventing copper absorption	20 mg/tab 1 tab thrice a day	Should be given with food, higher doses are required if given without	Bone marrow suppression	Good only for short-term use (8 weeks)	Complete blood count and liver function tests

Table III. Summary of treatment options for neurologic Wilson disease.

Management

As for the treatment, definitive treatment includes liver transplantation, especially for those with acute hepatitis or fulminant hepatic failure. For those with serious and debilitating neurologic sequelae, the best option is either to increase urinary excretion of copper directly ie, D-penicillamine and trientine or block gastrointestinal absorption of copper ie, zinc acetate/salts and tetrathiomolybdate (*Table III*).^{14,15,16,17}

For both cases, low copper diet was a mainstay of treatment. Zinc supplementation was also initiated, with subsequent noting of remarkable improvements in speech, tremors, and stiffening of extremities. The first case underwent D-penicillamine treatment with slow up-titration of the drug to avoid hematologic consequences and to monitor for paradoxical neurological deterioration. As for the second case, the patient was maintained on zinc supplementation because of relatively severe baseline neurologic status and high risk for paradoxical neurologic worsening. Treatment

should still be individualized since no two patients with WD are the same.^{8,15,16}

For patients with debilitating movement disorder refractory to chelation and medical treatment, botulinum toxin injection maybe offered. Screening of siblings of the patient and monitoring of their serum ceruloplasmin is also a big part of management.¹⁸ Early intervention signifies better prognosis, thus can be considered as a therapeutic emergency as well.

Synthesis

Educating medical doctors about this neurologic condition and having a high index of suspicion can improve treatment of this debilitating condition. Familiarization of this rare genetic conditions may also pave way for future researches to ascertain the prevalence, to facilitate detection and to improve outcomes. □

Disclosure/Acknowledgments: Dr Porlas, Dr de Castillo, and Dr Dioquino have nothing to disclose.

REFERENCES

1. Walshe JM. History of Wilson disease: a personal account. In: Członkowska A, Schilsky ML, eds. *Handbook of Clinical Neurology*. Volume 142 (3rd series), Amsterdam, the Netherlands: Elsevier; 2017.
2. Lorincz MT. Neurologic Wilson's disease. *Ann N Y Acad Sci*. 2010;1184:173-187. doi: 10.1111/j.1749-6632.2009.05109.x.
3. Wu F, Wang J, Pu C, Qiao L, Jiang C. Wilson's disease: a comprehensive review of the molecular mechanisms. *Int J Mol Sci*. 2015;16(3):6419-6431. doi:10.3390/ijms16036419.
4. Mak CM, Lam CW. Diagnosis of Wilson's disease: a comprehensive review. *Crit Rev Clin Lab Sci*. 2008;45(3):263-290. doi: 10.1080/10408360801991055.
5. Volpert HM, Pfeiffenberger J, Gröner JB, Stremmel W, Gotthardt DN, Schäfer M, Weiss KH, Weiler M. Comparative assessment of clinical rating scales in Wilson's disease. *BMC Neurol*. 2017;17(1):140. doi: 10.1186/s12883-017-0921-3.
6. Członkowska A, Tarnacka B, Möller JC, et al. Unified Wilson's Disease Rating Scale - a proposal for the neurological scoring of Wilson's disease patients. *Neurol Neurochir Pol*. 2007;41(1):1-12.
7. Bandmann O, Weiss KH, Kaler SG. Wilson's disease and other neurological copper disorders. *Lancet Neurol*. 2015;14(1):103-113. doi:10.1016/S1474-4422(14)70190-5.
8. Rodriguez-Castro KI, Hevia-Urrutia FJ, Sturniolo GC. Wilson's disease: A review of what we have learned. *World J Hepatol*. 2015;7(29):2859-2870. doi: 10.4254/wjh.v7.i29.2859.
9. Ala A, Walker AP, Ashkan K, Dooley JS, Schilsky ML. Wilson's disease. *Lancet*. 2007;369(9559):397-408.
10. Medici V, Rossaro L and Sturniolo GC. Wilson Disease – A practical approach to diagnosis, treatment and follow-up. *Dig Liver Dis*. 2007;39:601-609.
11. Członkowska A, Litwin T, Chabik G. Wilson's disease – neurologic features. In: Członkowska A, Schilsky ML, eds. *Handbook of Clinical Neurology*. Volume 142 (3rd series), Amsterdam, the Netherlands: Elsevier; 2017.
12. Cetlin RS, Rodrigues GR, Pena-Pereira MA, Oliveira DS, Souza CP, Tumas V. Teaching video neuroimages: excessive grinning in Wilson disease. *Neurology*. 2009;73(14):e73. doi: 10.1212/WNL.0b013e3181bacef0.
13. Ferenci P, Caca K, Loudianos G, Mieli-Vergani G, Tanner S, Sternlieb I, Schilsky M, Cox D, Berr F. Diagnosis and phenotypic classification of Wilson disease. *Liver Int*. 2003;23(3):139-142.
14. Brewer GJ. Wilson's Disease. In: Frucht SJ, ed. *Movement Disorder Emergencies: Diagnosis and Treatment*. Totowa, NJ: Human Press; 2013.
15. Brewer, GJ. Zinc acetate for the treatment of Wilson's disease. *Exp Opin Pharmacother*. 2001;2(9):1473-1477. <https://doi.org/10.1517/14656566.2.9.1473>.
16. Brewer GJ, Hill GM, Prasad AS, Cossack ST, and Rabbani P. Oral zinc therapy for Wilson's Disease. *Ann Intern Med*. 1983;99(3):314-320. <https://doi.org/10.7326/0003-4819-99-3-314>.
17. Brewer GJ. Zinc and tetrathiomolybdate for the treatment of Wilson's disease and the potential efficacy of anticopper therapy in a wide variety of diseases. *Metallomics*. 2009;1(3):199-206. doi: 10.1039/b901614g.
18. European Association for the Study of the Liver. EASL Clinical Practice Guidelines: Wilson's Disease. *J Hepatol*. 56(3), 671-685. <https://doi.org/10.1016/j.jhep.2011.11.007>.

Enfermedad de Wilson neurológica: serie de casos de urgencia diagnóstica y terapéutica

La Enfermedad de Wilson es una enfermedad genética rara provocada por un depósito patológico de cobre en el hígado, cerebro, córnea, riñón y músculo cardíaco. Se presentan dos casos de Enfermedad de Wilson neurológica con trastorno progresivo del movimiento y anillos de Kayser-Fleischer con cobre y ceruloplasmina séricos bajos, y aumento de cobre en orina de 24 horas, con transaminasas normales. Las imágenes craneales revelan hiperintensidad simétrica en T2/FLAIR de los ganglios basales. Lo más frecuente es que estos casos pasen inadvertidos o no se realice el diagnóstico correcto debido a la rareza y variedad de sus presentaciones. Se requiere de un completo trabajo para poder precisar el diagnóstico. Respecto al manejo, cuanto antes se inicie la intervención, mejor será el pronóstico para la recuperación. Existen diversas opciones terapéuticas y deben adaptarse a cada paciente con Enfermedad de Wilson neurológica. La Enfermedad de Wilson neurológica se considera una toxicidad al cobre, por lo que es una necesidad la evaluación diagnóstica inmediata y el tratamiento precoz.

Une série de cas sur une urgence diagnostique et thérapeutique dans la forme neurologique de la maladie de Wilson

La maladie de Wilson est une maladie génétique rare qui provoque un dépôt de cuivre pathologique dans le foie, le cerveau, la cornée, le rein et le muscle cardiaque. Nous présentons deux cas de maladie de Wilson dans sa forme neurologique avec un trouble kinétique progressif et des anneaux de Kayser-Fleischer, avec une hypocuprémie, une hypocéruleplasminémie et une hypercuprurie des 24 h, les transaminases étant normales. L'IRM cérébrale montre des hypersignaux symétriques en FLAIR et T2 des ganglions de la base. Le plus souvent ces cas ne sont pas diagnostiqués et passent inaperçus en raison de la rareté et de la présentation variée de la maladie. Un bilan approfondi est nécessaire pour établir le diagnostic. De même que pour la prise en charge, plus tôt le traitement est instauré, meilleur est le pronostic de guérison. Plusieurs options de traitement sont disponibles qui doivent être adaptées à chaque patient atteint de la maladie de Wilson. La maladie de Wilson sous sa forme neurologique est considérée comme une toxicité au cuivre ; elle nécessite une évaluation diagnostique immédiate et un traitement précoce.