

Combined upregulation of matrix metalloproteinase-1 and proteinase-activated receptor-1 predicts unfavorable prognosis in human nasopharyngeal carcinoma

Rui Yang¹
Yu Xu²
Peizhong Li²
Xin Zhang²
Junying Wang²
Dongsheng Gu²
Yao Wang³

¹ State Key Laboratory of Cancer Biology, Cell Engineering Research Center and Department of Cell Biology, Department of Clinical Nursing, School of Nursing, The Fourth Military Medical University, Xi'an, People's Republic of China;

² Department of Otorhinolaryngology, Huai'an First People's Hospital, Nanjing Medical University, Huai'an, Jiangsu, People's Republic of China;

³ Pharmaceutical Preparation Section, Huai'an First People's Hospital, Nanjing Medical University, Huai'an, Jiangsu, People's Republic of China

Background: The upregulation of matrix metalloproteinase-1 (MMP-1) has been demonstrated to be correlated with lymph node metastasis of nasopharyngeal carcinoma (NPC), while the activation of protease-activated receptor-1 (PAR-1) mediates proliferation and invasion of NPC cells. The present study investigated the clinical significance of the coexpression of MMP-1 and PAR-1 in NPC patients in determining the prognosis.

Methods: Immunohistochemistry was performed to detect the expression of MMP-1 and PAR-1 in tumor tissue samples from 266 NPC patients.

Results: Overexpression of MMP-1 and PAR-1 proteins were, respectively, detected in 190 (71.43%) and 182 (68.42%) of the 266 NPC patients. In addition, the combined MMP-1 and PAR-1 expression was significantly associated with advanced T-stage ($P = 0.01$), advanced clinical stage ($P = 0.002$), positive recurrence ($P = 0.01$), and metastatic status ($P = 0.01$) of NPC. Moreover, the overall survival in NPC patients with MMP-1 and PAR-1 dual overexpression was significantly shorter than in those with dual low expression ($P < 0.001$). Furthermore, the multivariate analyses indicated that the combined MMP-1 and PAR-1 overexpression was an independent prognostic factor for overall survival ($P = 0.001$) in NPC patients, but the upregulation of MMP-1 and PAR-1 alone was, in each case, not an independent prognostic factor for this disease.

Conclusion: Our data provide convincing evidence, for the first time, that the activation of the MMP-1 and PAR-1 axis may be involved in the tumorigenesis and progression of NPC. The upregulation of MMP-1 in combination with PAR-1 overexpression is an unfavorable prognostic marker for NPC and might offer the possibility of future therapeutic targets.

Keywords: MMP-1, PAR-1, nasopharyngeal carcinoma, coexpression, prognosis

Introduction

Nasopharyngeal carcinoma (NPC) is one of the most common malignant diseases, with a high prevalence in Southern China, Southeast Asia, and North Africa.¹ Worldwide, NPC accounts for 80,000 new cases and 50,000 deaths annually, predominantly in men.² NPC is an Epstein-Barr virus (EBV)-related cancer and differs from other head and neck cancers in its etiology, epidemiology, and potential therapeutic options.³ Generally, enlarged lymph nodes in the neck region are the first sign of NPC; however, neck biopsy or neck dissection is not recommended, as this may reduce cure probability. The majority (75%–90%) of newly diagnosed NPC patients have locoregionally advanced disease, commonly with cervical nodal metastases.⁴

Correspondence: Yu Xu
Department of Otorhinolaryngology,
Huai'an First People's Hospital,
Nanjing Medical University, 6 Beijing
Road West, Huai'an, Jiangsu 223300,
People's Republic of China
Tel +86 517 8490 7171
Fax +86 517 8492 2412
Email xuyuhay@163.com

Currently, the standard of care for NPC patients consists of concurrent chemoradiotherapy with cisplatin-based regimens, generally followed by adjuvant chemotherapy. This treatment approach leads to cure for the vast majority of patients, with 3-year disease-free and overall survival rates of approximately 70% and 80%, respectively.⁵ Despite cure for the majority of the patients, it is still a challenge to prevent the disease relapse, to treat the patients with refractory or metastatic NPC, and to manage the long-term toxicities. Thus, there is an urgent need to identify the valuable factors for early diagnosis, prognosis, and novel therapeutic strategies.

Matrix metalloproteinases (MMPs) comprise a closely related family of 28 zinc-dependent endopeptidases that cleave extracellular matrix (ECM) proteins during tissue remodeling processes, such as wound healing, angiogenesis, and tumor invasion.⁶ Among MMPs, MMP-1, together with MMP-8 and MMP-13, is known as the interstitial collagenase and is capable of initiating the degradation of fibrillar-type collagens by cleaving at the N-terminus. MMP-1 presents specific substrates for collagenases I, II, III, VII, VIII, and X, and for proteoglycans.^{7,8} It has been identified as one of the most highly upregulated proteins in various cancers. In particular, tumor expression of MMP-1 is associated with poor prognosis in malignant melanoma,⁹ breast cancer,¹⁰ ovarian cancer,¹¹ colorectal carcinoma,¹² pancreatic cancer,¹³ and gastric cancer.¹⁴ Recent studies have demonstrated that the collagenase activity of MMP-1 may be associated with tumor cell invasion and increased angiogenesis in xenograft models of malignant melanoma,¹⁵ breast cancer,¹⁶ and prostate cancer.¹⁷ In NPC, Lu et al¹⁸ showed clearly that the amounts of transcripts, proteins, and enzyme activities of MMP-1 were increased in cells expressing EBV proteins, suggesting that these viral proteins may be capable of regulating MMP-1 and may provide clues for the role of EBV in NPC progression; Ben Nasr et al¹⁹ indicated that the expression of MMP-1 may be correlated with lymph node metastasis in NPC patients. Although the collagenolytic activity of MMP-1 may contribute to the tumor progression of NPC, its prognostic value in this carcinoma remains largely undefined.

Recently, a novel MMP-1 signaling axis (through activation of the protease-activated receptor [PAR]-1 to promote tumorigenesis and tumor invasion) has been identified in various cancers, such as breast cancer,²⁰ epithelial ovarian cancer,²¹ esophageal squamous cell carcinoma,²² glioma,²³ and hepatocellular carcinoma.²⁴ The PARs are known as the cellular seven transmembrane G protein-coupled receptors (GPCRs) for thrombin.²⁵ Four different PARs have

been identified: PAR-1, PAR-2, PAR-3, and PAR-4. PARs are widely expressed in vascular and extravascular tissues and are involved in responses to vascular injury and in the regulation of inflammation.²⁶ PAR-1 and PAR-3 are activated by thrombin, PAR-2 is activated by tryptase or trypsin, and PAR-4 is activated by both thrombin and tryptase or trypsin. Among the PARs, the abnormal expression of PAR-1 has been demonstrated to be associated with the metastatic potentials of various malignancies, including breast cancer, prostate cancer,²⁷ and melanoma.²⁸ In particular, Zhu et al²⁹ indicated that the activation of PAR-1 may mediate the proliferation and invasion of NPC cells. Since the MMP-1/PAR-1 signal transduction axis facilitates tumor invasion, angiogenesis, and metastasis by inducing the expression of the genes associated with cell adhesion, invasion, and survival, it is of great significance to explore the expression and prognostic value of MMP-1 and PAR-1 in NPC. However, to date, there has been no investigation of the clinicopathologic relevance of combined MMP-1 and PAR-1 expression in NPC tissues. Therefore, the aim of the present study was to evaluate the potential association of the coexpression of MMP-1 and PAR-1 in NPC tissues with clinicopathologic findings and with postresectional survival, by an immunohistochemical analysis.

Materials and methods

Patients and tissue samples

The study was approved by the Research Ethics Committee of the Ministry of Public Health of the People's Republic of China. Informed consent was obtained from all of the patients.

A total of 266 archival formalin-fixed, paraffin-embedded NPC specimens and 100 noncancerous nasopharyngeal specimens were obtained from Huai'an First People's Hospital, Nanjing Medical University, People's Republic of China during 1996–2006. In the 266 NPC group of patients, there were 166 males and 100 females, with age ranging from 16 to 80 years (median, 48 years). None of the patients recruited in this study had chemotherapy or radiotherapy before the surgery. Clinical information was obtained by reviewing the medical record of radiographic images, by telephone or written correspondence, and by review of death certificates. All specimens had a confirmed pathological diagnosis and were staged according to the 1992 NPC staging system of the People's Republic of China.³¹ The clinical characteristics of these patients are summarized in Table 1.

For the analysis of survival and follow up, the date of surgery was used to represent the beginning of the

Table I Association of MMP-1 and/or PAR-1 expression patterns with clinicopathologic parameters of nasopharyngeal carcinoma patients

Parameters	N	MMP-1 expression (n, %)		PAR-1 expression (n, %)		MMP-1/PAR-1 expression (n, %)	
		High	P	High	P	High/high	P
Age							
<48	100	72 (72.00)	NS	70 (70.00)	NS	62 (62.00)	NS
≥48	166	118 (71.08)		112 (67.47)		100 (60.24)	
Gender							
Male	166	116 (69.88)	NS	110 (66.27)	NS	106 (63.86)	NS
Female	100	74 (74.00)		72 (72.00)		56 (56.00)	
Clinical stage							
I–II	68	34 (50.00)	0.008	34 (50.00)	0.008	20 (29.41)	0.002
III–IV	198	156 (78.79)		148 (74.75)		142 (71.72)	
T-stage							
T1–T2	90	57 (63.33)	0.02	56 (62.22)	NS	42 (46.67)	0.01
T3–T4	176	133 (75.57)		126 (71.59)		120 (68.18)	
N-stage							
N0	78	50 (64.10)	NS	50 (64.10)	NS	48 (61.54)	NS
N1–N3	188	140 (74.47)		138 (73.40)		114 (60.64)	
WHO histological type							
II	76	50 (65.79)	NS	49 (64.47)	NS	42 (55.26)	NS
III	190	140 (73.68)		133 (70.00)		120 (63.16)	
Recurrence							
No	196	140 (73.68)	NS	123 (62.76)	0.01	110 (56.12)	0.01
Yes	70	50 (65.79)		59 (84.29)		52 (74.29)	
Metastasis							
No	211	142 (67.30)	0.01	134 (63.51)	0.01	117 (55.45)	0.01
Yes	55	48 (87.27)		48 (87.27)		45 (81.82)	

Note: NS refers to the difference without statistical significance.

Abbreviations: MMP, matrix metalloproteinases; PAR, protease-activated receptor; WHO, World Health Organization.

follow-up period. All the patients who died from diseases other than NPC or from unexpected events were excluded from the case collection. The study follow-up period terminated at March 8, 2012. The median follow-up period was 46 months (range, 3–126 months). Treatment modalities after relapse were given according to a uniform guideline, as described.³¹

Immunohistochemistry analysis

The expression patterns of the MMP-1 and PAR-1 proteins in the 266 NPC specimens and 100 noncancerous nasopharyngeal specimens were detected by immunohistochemical staining. In brief, all tissue specimens were retrieved and cut into 4 µm sections and then, mounted on precoated slides. After deparaffinizing in xylene (Chemical Industry Co., Ltd., Shenzhen, People's Republic of China) and washing in a graded series of ethanol (Chemical Industry Co., Ltd.), the sections were submerged into ethylenediaminetetraacetic acid (EDTA) antigenic retrieval buffer (Chemical Industry Co., Ltd.) and microwaved for antigenic retrieval. The slides were incubated with primary antibodies raised against MMP-1 (1:1000 dilution) (MMP-1 [3B6] Antibody;

#sc-21731, Santa Cruz Biotechnology, Inc, Dallas, TX, USA) and against PAR-1 (1:1000 dilution) (Antibody; #sc-33732, Santa Cruz Biotechnology, Inc). All incubations with primary antibodies were carried out overnight at 4°C. After washing in tris(hydroxymethyl) aminomethane (Tris)-buffered saline (TBS) (Sigma Aldrich Corp, St Louis, MO, USA), the tissue sections were treated with biotinylated anti-rabbit secondary antibody (Antibody; #sc-2775, Santa Cruz Biotechnology, Inc), followed by further incubation with streptavidin–horseradish peroxidase complex (Life Technologies Corp, Carlsbad, CA, USA). The tissue sections were immersed in 3-amino-9-ethyl carbazole (Chemical Industry Co., Ltd.) and counterstained with 10% Mayer's hematoxylin (Chemical Industry Co., Ltd.), dehydrated, and mounted in Crystal Mount™ Aqueous Mounting Medium (Chemical Industry Co., Ltd). In each immunohistochemistry run, noncancerous nasopharyngeal specimens were used as control tissues, and omission of the primary antibody served as a negative control. All the tissue samples were stained at one time.

Following the hematoxylin counterstaining, immunostaining was scored by two independent observers who were

blinded to the clinicopathological parameters and clinical outcomes of the patients. The scores of the two observers were compared, and in the event of a discrepant score, the specimen was reexamined by both pathologists to achieve a consensus score. The number of positive-staining cells showing immunoreactivity on the cell membrane and/or cytoplasm (for MMP-1) and cytoplasm (for PAR-1) in ten representative microscopic fields was counted, and the percentage of positive cells was calculated. The frequency of MMP-1 and PAR-1 immunoreactivity in tissue sections was evaluated as negative (0), when no positive cells were observed within the tumor; as weak (1), when <30% of the tumor cells were positive; moderate (2), when 30% to 60% of the tumor cells were positive; and strong (3), when >60% of tumor cells were positive. The intensity of staining was evaluated as 0, 1, 2, and 3 for no staining, weak staining, medium staining, and strong staining, respectively. The immunohistochemical scores were determined as the sum of the frequency and intensity scores for the tumor cells. The cutoff values for the immunohistochemical scores of MMP-1 and PAR-1 proteins were chosen on the basis of a measure of heterogeneity, with the logrank test statistic, with respect to overall survival. An optimal cutoff value was identified. An immunohistochemical score of ≥ 4 was used to classify tumors with high expression, while a < 4 immunohistochemical score classified tumors with low expression of MMP-1 or PAR-1 antigens.

Statistical analysis

SPSS for Windows version 16.0 (SPSS Inc, Chicago, IL, USA) and SAS 9.1 (SAS Institute, Cary, NC, USA) were used for statistical analysis. Continuous variables were expressed as $\bar{X} \pm s$. Associations between the expression of MMP-1 and/or PAR-1 and clinicopathological parameters were assessed using a Chi-square test. The Spearman rank correlation test was used to analyze the correlation between the MMP-1 expression level and the PAR-1 expression level. Survival curves were plotted by Kaplan–Meier analysis and compared by the logrank test. Cox regression analysis was performed to assess the significance of various variables for survival. Differences were considered statistically significant when the *P*-value was less than 0.05.

Results

Upregulation of MMP-1 and PAR-1 in human NPC

The expression patterns and cellular distribution of MMP-1 and PAR-1 in 266 specimens of patients with NPC and

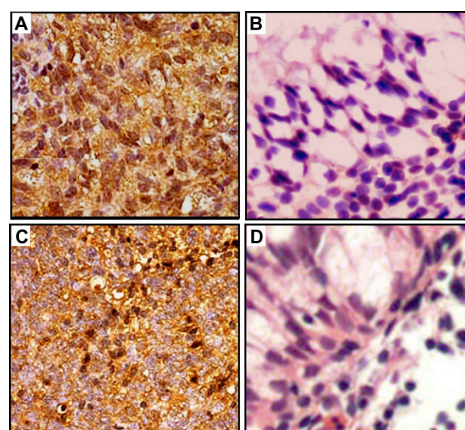


Figure 1 Immunohistochemical staining of MMP-1 and PAR-1 proteins in tumor cells of patients with NPC (A and C, respectively) and noncancerous nasopharyngeal tissues (B and D, respectively). Intense staining of MMP-1 and PAR-1 is seen in the cell membrane and/or cytoplasm of tumors cells and is intensive in NPC tissues (A and C); in contrast, negative immunostaining of MMP-1 (B) and PAR-1 (D) was observed in the noncancerous nasopharyngeal tissues.

Note: Original magnification $\times 400$.

Abbreviations: NPC, nasopharyngeal carcinoma; MMP, matrix metalloproteinases; PAR, protease-activated receptor.

100 noncancerous nasopharyngeal tissues were examined using immunohistochemical staining. As shown in Figure 1, the cell membrane and/or cytoplasm of most tumor cells in the NPC sections stained intensely with MMP-1 antibody (Figure 1A), while negative immunostaining was observed in all noncancerous nasopharyngeal tissues (Figure 1B). High MMP-1 expression was observed in tumor cells of 71.43% (190/266) of the NPC patients. For PAR-1, positive immunostaining was observed in the cytoplasm of the tumor cells (Figure 1C). In contrast, little or no expression of PAR-1 was observed in the noncancerous nasopharyngeal tissues (Figure 1D). High PAR-1 expression was observed in tumor cells of 68.42% (182/266) of the NPC patients. In particular, high MMP-1 expression was positively correlated with high PAR-1 expression in the tissue from patients with NPC ($r = 0.86$) ($P < 0.0001$) (Table 2).

Association of MMP-1 and/or PAR-1 protein expression with the clinicopathological characteristics of human NPC

Table 1 summarizes the association of MMP-1 and/or PAR-1 protein expression in the 266 NPC specimens, detected by immunohistochemical staining. Expression of MMP-1 was significantly associated with the T-stage ($P = 0.02$), clinical stage ($P = 0.008$), and metastatic status ($P = 0.01$). No significant association between MMP-1 expression and age, gender, N-stage, World Health Organization (WHO)

Table 2 Correlations between MMP-1 and PAR-1 expression in nasopharyngeal carcinoma tissues

	High PAR-1 expression	Low PAR-1 expression	Spearman rank correlation coefficient
High MMP-1 expression	162 (85.26%)	28 (14.74%)	0.86
Low MMP-1 expression	20 (26.32%)	56 (73.68%)	

Abbreviations: MMP, matrix metalloproteinases; PAR, protease-activated receptor.

histological type,³¹ or recurrence was observed (Table 1). Regarding PAR-1, its overexpression was significantly associated with advanced clinical stage ($P = 0.008$), positive recurrence ($P = 0.01$), and positive metastasis ($P = 0.01$). Chi-square test showed no significant statistical association of PAR-1 immunostaining with age, gender, T-stage, N-stage, or WHO histological type (all $P > 0.05$), suggesting that these variables might not affect the expression of PAR-1.

In addition, the biologic significance of the combined expression of MMP-1 and PAR-1 was also evaluated by correlating the expression levels with the clinicopathologic characteristics. As shown in Table 1, the coexpression of MMP-1 and PAR-1 in NPC was associated with advanced T-stage ($P = 0.01$), advanced clinical stage ($P = 0.002$), positive recurrence ($P = 0.01$), and metastatic status ($P = 0.01$), but not with gender, age, N-stage, or WHO histological type (all $P > 0.05$).

Association of MMP-1 and/or PAR-1 protein expression with the prognosis of human NPC

The association of MMP-1 and/or PAR-1 protein expression with the prognosis of human NPC was also evaluated. The 5-year overall survival rate of the cohort of 266 NPC patients was 66.17% (196/266). Kaplan–Meier survival analysis revealed that the NPC patients overexpressing both MMP-1 and PAR-1 proteins exhibited markedly poorer overall survival ($P = 0.01$) (Figure 2A and B). Regarding their combined expression, the overall survival in NPC patients with MMP-1 and PAR-1 dual overexpression was significantly shorter than those with dual low expression ($P < 0.001$) (Figure 2C).

Univariate Cox proportional hazard regression analysis revealed that high MMP-1 expression (hazard ratio [HR] = 5.796, 95% confidence interval [CI]: 0.826–12.013) ($P = 0.01$), high PAR-1 expression (HR = 5.282, 95% CI: 0.701–11.819) ($P = 0.01$), and MMP-1-high/PAR-1-high expression (HR = 13.882, 95% CI: 1.986–29.331) ($P < 0.001$) were significant predictive factors for poor prognosis in NPC

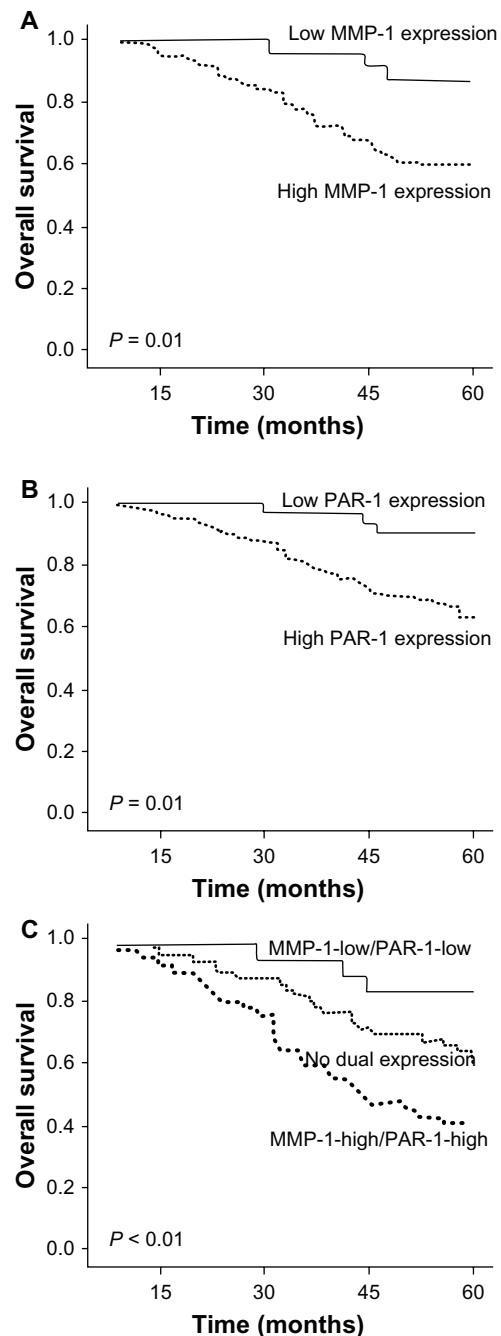


Figure 2 Kaplan–Meier survival plots of MMP-1 (A), PAR-1 (B), and MMP-1/PAR-1 (C) expression. Kaplan–Meier survival analysis revealed that the NPC patients overexpressing MMP-1 and PAR-1 proteins both exhibited markedly poorer overall survival (both $P = 0.01$). Regarding their combined expression, the overall survival in NPC patients with MMP-1 and PAR-1 dual overexpression was significantly shorter than those with dual low expression ($P < 0.001$).

Abbreviations: NPC, nasopharyngeal carcinoma; MMP, matrix metalloproteinases; PAR, protease-activated receptor.

patients. Other clinicopathologic parameters, including clinical stage (HR = 7.382, 95% CI: 1.031–16.613) ($P = 0.002$), recurrence (HR = 8.892, 95% CI: 1.021–18.656) ($P = 0.001$), and metastasis (HR = 8.788, 95% CI: 1.042–19.052) ($P = 0.001$), were also found to be prognostic predictors

Table 3 Univariate analysis of different prognostic variables in 266 nasopharyngeal carcinoma patients

Variables	Subset	HR	95% CI	P
Patient gender	Male vs female	1.987	0.608–4.092	NS
Patient age	<48 vs ≥48	1.566	0.465–3.853	NS
Clinical stage	I–II vs III–IV	7.382	1.031–16.613	0.002
T-stage	T1–T2 vs T3–T4	2.380	0.738–5.046	NS
N-stage	N0 vs N1–N3	1.778	0.732–4.028	NS
WHO	II vs III	1.458	0.689–3.076	NS
histological type				
Recurrence	No vs yes	8.892	1.021–18.656	0.001
Metastasis	No vs yes	8.788	1.042–19.052	0.001
MMP-1	Low vs high	5.796	0.826–12.013	0.01
PAR-1	Low vs high	5.282	0.701–11.819	0.01
MMP-1/PAR-1	MMP-1-high/PAR-1-high vs MMP-1-low/PAR-1-low	13.882	1.986–29.331	<0.001

Note: NS refers to the difference without statistical significance.

Abbreviations: CI, confidence interval; HR, hazard ratio; MMP, matrix metalloproteinases; PAR, protease-activated receptor; WHO, World Health Organization.

of overall survival in NPC patients (Table 3). Furthermore, multivariate Cox proportional hazards regression analysis indicated that combined MMP-1 and PAR-1 overexpression (HR = 9.167, 95% CI: 1.332–23.836) ($P = 0.001$), clinical stage (HR = 6.193, 95% CI: 1.011–13.392) ($P = 0.006$), recurrence (HR = 6.928, 95% CI: 0.922–13.556) ($P = 0.005$), and metastasis (HR = 6.893, 95% CI: 1.023–13.528) ($P = 0.005$) were independent prognostic factors for overall survival in NPC patients, but the upregulation of MMP-1 and PAR-1 alone was, in each case, not an independent prognostic factor for this disease (Table 4).

Discussion

NPC is an EBV-related cancer with a high metastatic potential compared to other head and neck cancers. There is a significant need for the identification of potential biomarkers to screen

Table 4 Multivariate Cox regression analysis of different prognostic variables in 266 nasopharyngeal carcinoma patients

Variables	Subset	HR	95% CI	P
Clinical stage	I–II vs III–IV	6.193	1.011–13.392	0.006
Recurrence	No vs yes	6.928	0.922–13.556	0.005
Metastasis	No vs yes	6.893	1.023–13.528	0.005
MMP-1	Low vs high	3.269	0.732–7.038	NS
PAR-1	Low vs high	3.203	0.722–7.012	NS
MMP-1/PAR-1	MMP-1-high/PAR-1-high vs MMP-1-low/PAR-1-low	9.167	1.332–23.836	0.001

Note: NS refers to the difference without statistical significance.

Abbreviations: CI, confidence interval; HR, hazard ratio; MMP, matrix metalloproteinases; PAR, protease-activated receptor.

patients who are at the great risk of relapse after their primary treatment. In the present study, we analyzed the expression of MMP-1 and/or PAR-1 together with clinicopathologic parameters in NPC patients. We observed the coexpression of MMP-1 and PAR-1 in NPC tissues to be associated with advanced T-stage, advanced clinical stage, positive recurrence and metastatic status, and poor prognosis. These findings suggest that the coexpression of MMP-1 and PAR-1 may be a novel, independent marker for progression and prognosis in NPC patients. To the best of our knowledge, this is the first research on the role of the combined expression of MMP-1 and PAR-1 in a large cohort of NPC patients.

Cellular migration is a complex process that involves the breakdown of ECM, detachment of cells from the basal membrane, migration of cells from the original location, survival of cells during the migration process, intravasation into the target tissue, and finally, interaction of the migrated cells with the target microenvironment.³⁰ Cellular migration is a critical aspect of tumor progression. The degradation of the ECM during the tumor migration and invasion processes requires the action of proteolytic enzymes, such as MMPs, which are critical for remodeling the ECM, thereby affecting cell behavior under physiologic and pathophysiologic circumstances, such as embryogenesis and tumor progression.³² Among the 24 MMP members, the type I collagenase activity of MMP-1 has long been associated with tumor growth, invasion, and metastasis by its dual functions of both modifying the matrix and promoting vessel formation. In addition, recent studies have indicated that MMP-1 may proteolytically activate PAR-1, suggesting that MMP-1 may play a greater role in tumor progression by activating signal transduction pathways and modulating cell behavior.³³ PAR-1, as the thrombin receptor, becomes activated when thrombin cleaves a specific residue sequence (R41–S42) within the receptor's N-terminal extracellular domain.³⁴ PAR-1 expression has been similarly demonstrated to correlate with tumor progression both in vitro and in vivo. In light of the potential significance of MMP-1 and PAR-1 in the tumorigenesis and tumor progression of various cancers, accumulating studies^{22–24} have been performed to investigate the role of the MMP-1/PAR-1 axis in cancers. For example, the blockage of the MMP-1/PAR-1 interaction by a monoclonal antibody against PAR-1 has been shown to significantly reduce the migration ability of human mesenchymal stem cells.³⁵ Here, the information for tumor cell invasiveness flows from the stroma, which produces the PAR-1 activator MMP-1, to the tumor cells, which express PAR-1. This result suggests that the level of MMP-1 expression and the specific

interaction of MMP-1 with PAR-1 proteins determine the differential migration ability of tumor cells.^{36,37}

Recently, Agarwal et al³⁸ showed a strong correlation between pro-MMP-1 levels in patient fluid samples and malignancy, as well as the ability to induce migration of high PAR1-expressing OVCAR-4 cells, indicating the involvement of MMP-1/PAR-1 signaling in ovarian cancer progression. Peng et al²² reported that the MMP-1/PAR-1 signal transduction axis might be a new therapeutic target for future therapies tailored against esophageal squamous cell carcinoma. Liao et al²⁴ found that both the overexpression of MMP-1 and PAR-1 was significantly associated with poor prognosis in hepatocellular carcinoma. Zhang et al²³ demonstrated that the upregulation of MMP-1 and PAR-1 may be correlated with the histological malignancy grade and clinical outcome of glioma patients. Based on these observations, we hypothesized that the MMP-1/PAR-1 axis may play a role in NPC. According to our data in this study, MMP-1 and PAR-1 were both overexpressed in NPC tissues, which is consistent with the previous studies of Ben Nasr et al¹⁹ and Zhu et al.³⁰ Interestingly, the expression levels of MMP-1 in the NPC specimens were significantly correlated with those of PAR-1, suggesting a regulatory relationship between MMP-1 and PAR-1. In addition, we found that MMP-1 and/or PAR-1 expression levels were all associated with aggressive tumor progression and poor overall survival of the NPC patients, which is also similar with the previous findings in other cancers.^{22–24} More importantly, the multivariate analyses here showed that the combined MMP-1 and PAR-1 overexpression was an independent prognostic factor for overall survival ($P = 0.001$) in NPC patients, but the upregulation of MMP-1 and PAR-1 alone was, in each case, not an independent prognostic factors for this disease, suggesting the importance of the interaction between MMP-1 and PAR-1 in the clinical outcome of NPC patients.

In conclusion, our data provide the convincing evidence, for the first time, that the activation of the MMP-1/PAR-1 axis may be involved in the tumorigenesis and progression of NPC. The upregulation of MMP-1 in combination with PAR-1 overexpression is an unfavorable prognostic marker for NPC, which might offer the possibility of future therapeutic targets.

Disclosure

The authors report no conflicts of interest in this work.

References

- Glastonbury CM, Salzman KL. Pitfalls in the staging of cancer of nasopharyngeal carcinoma. *Neuroimaging Clin N Am*. 2013;23(1):9–25.
- Han BL, Xu XY, Zhang CZ, et al. Systematic review on Epstein-Barr virus (EBV) DNA in diagnosis of nasopharyngeal carcinoma in Asian populations. *Asian Pac J Cancer Prev*. 2012;13(6):2577–2581.
- Lee AW, Lin JC, Ng WT. Current management of nasopharyngeal cancer. *Semin Radiat Oncol*. 2012;22(3):233–244.
- Hughes J, Alusi G, Wang Y. Gene therapy and nasopharyngeal carcinoma. *Rhinology*. 2012;50(2):115–121.
- Ho FC, Tham IW, Earnest A, Lee KM, Lu JJ. Patterns of regional lymph node metastasis of nasopharyngeal carcinoma: a meta-analysis of clinical evidence. *BMC Cancer*. 2012;12:98.
- Pei D. Matrix metalloproteinases target protease-activated receptors on the tumor cell surface. *Cancer Cell*. 2005;7(3):207–208.
- Heppner KJ, Matrisian LM, Jensen RA, Rodgers WH. Expression of most matrix metalloproteinase family members in breast cancer represents a tumor-induced host response. *Am J Pathol*. 1996;149(1):273–282.
- Poola I, DeWitty RL, Marshalleck JJ, Bhatnagar R, Abraham J, Leffall LD. Identification of MMP-1 as a putative breast cancer predictive marker by global gene expression analysis. *Nat Med*. 2005;11(5):481–483.
- Kähäri VM, Ala-Aho R. Stromal collagenase in melanoma: a vascular connection. *J Invest Dermatol*. 2009;129(11):2545–2547.
- Benson CS, Babu SD, Radhakrishna S, Selvamurugan N, Ravi Sankar B. Expression of matrix metalloproteinases in human breast cancer tissues. *Dis Markers*. 2013;34(6):395–405.
- Wang FQ, Fisher J, Fishman DA. MMP-1-PAR1 axis mediates LPA-induced epithelial ovarian cancer (EOC) invasion. *Gynecol Oncol*. 2011;120(2):247–255.
- Langenskiöld M, Ivarsson ML, Holmdahl L, Falk P, Kåbjörn-Gustafsson C, Angenete E. Intestinal mucosal MMP-1 – a prognostic factor in colon cancer. *Scand J Gastroenterol*. 2013;48(5):563–569.
- Ito T, Ito M, Shiozawa J, Naito S, Kanematsu T, Sekine I. Expression of the MMP-1 in human pancreatic carcinoma: relationship with prognostic factor. *Mod Pathol*. 1999;12(7):669–674.
- Cai QW, Li J, Li XQ, Wang JQ, Huang Y. Expression of STAT3, MMP-1 and TIMP-1 in gastric cancer and correlation with pathological features. *Mol Med Rep*. 2012;5(6):1438–1442.
- Shalinsky DR, Brekken J, Zou H, et al. Broad antitumor and antiangiogenic activities of AG3340, a potent and selective MMP inhibitor undergoing advanced oncology clinical trials. *Ann N Y Acad Sci*. 1999;878:236–270.
- Boire A, Covic L, Agarwal A, Jacques S, Sherifi S, Kuliopulos A. PAR1 is a matrix metalloprotease-1 receptor that promotes invasion and tumorigenesis of breast cancer cells. *Cell*. 2005;120(3):303–313.
- Ozden F, Saygin C, Uzunaslan D, Onal B, Durak H, Aki H. Expression of MMP-1, MMP-9 and TIMP-2 in prostate carcinoma and their influence on prognosis and survival. *J Cancer Res Clin Oncol*. 2013;139(8):1373–1382.
- Lu J, Chua HH, Chen SY, Chen JY, Tsai CH. Regulation of matrix metalloproteinase-1 by Epstein-Barr virus proteins. *Cancer Res*. 2003;63(1):256–262.
- Ben Nasr H, Chahed K, Remadi S, Zakhama A, Chouchane L. Expression and clinical significance of latent membrane protein-1, matrix metalloproteinase-1 and Ets-1 transcription factor in tunisian nasopharyngeal carcinoma patients. *Arch Med Res*. 2009;40(3):196–203.
- Hernández NA, Correa E, Avila EP, Vela TA, Pérez VM. PAR1 is selectively over expressed in high grade breast cancer patients: a cohort study. *J Transl Med*. 2009;7:47.
- Naldini A, Morena E, Belotti D, Carraro F, Allavena P, Giavazzi R. Identification of thrombin-like activity in ovarian cancer associated ascites and modulation of multiple cytokine networks. *Thromb Haemost*. 2011;106(4):705–711.
- Peng HH, Zhang X, Cao PG. MMP-1/PAR-1 signal transduction axis and its prognostic impact in esophageal squamous cell carcinoma. *Braz J Med Biol Res*. 2012;45(1):86–92.

23. Zhang Y, Zhan H, Xu W, et al. Upregulation of matrix metalloproteinase-1 and proteinase-activated receptor-1 promotes the progression of human gliomas. *Pathol Res Pract*. 2011;207(1):24–29.
24. Liao M, Tong P, Zhao J, et al. Prognostic value of matrix metalloproteinase-1/proteinase-activated receptor-1 signaling axis in hepatocellular carcinoma. *Pathol Oncol Res*. 2012;18(2):397–403.
25. Leonardi S, Becker RC. PAR-1 inhibitors: a novel class of antiplatelet agents for the treatment of patients with atherothrombosis. *Handb Exp Pharmacol*. 2012:239–260.
26. Serebruany VL, Malinin A, Eisert C, Ong S. AGI-1067, a novel vascular protectant, anti-inflammatory drug and mild antiplatelet agent for treatment of atherosclerosis. *Expert Rev Cardiovasc Ther*. 2007;5(4):635–641.
27. Salah Z, Uziely B, Jaber M, et al. Regulation of human protease-activated receptor 1 (hPar1) gene expression in breast cancer by estrogen. *FASEB J*. 2012;26(5):2031–2042.
28. Zhang X, Wang W, True LD, Vessella RL, Takayama TK. Protease-activated receptor-1 is upregulated in reactive stroma of primary prostate cancer and bone metastasis. *Prostate*. 2009;69(7):727–736.
29. Zigler M, Kamiya T, Brantley EC, Villares GJ, Bar-Eli M. PAR-1 and thrombin: the ties that bind the microenvironment to melanoma metastasis. *Cancer Res*. 2011;71(21):6561–6566.
30. Zhu Q, Luo J, Wang T, Ren J, Hu K, Wu G. The activation of protease-activated receptor 1 mediates proliferation and invasion of nasopharyngeal carcinoma cells. *Oncol Rep*. 2012;28(1):255–261.
31. Pan J, Xu Y, Qiu S, Zong J, Guo Q, Zhang Y, Lin S, Lu JJ. A Comparison Between the Chinese 2008 and the 7th Edition AJCC Staging Systems for Nasopharyngeal Carcinoma. *Am J Clin Oncol*. 2013 In press.
32. Blackburn JS, Liu I, Coon CI, Brinckerhoff CE. A matrix metalloproteinase-1/ protease activated receptor-1 signaling axis promotes melanoma invasion and metastasis. *Oncogene*. 2009;28(48): 4237–4248.
33. Eck SM, Blackburn JS, Schmucker AC, Burrage PS, Brinckerhoff CE. Matrix metalloproteinase and G protein coupled receptors: co-conspirators in the pathogenesis of autoimmune disease and cancer. *J Autoimmun*. 2009;33(3–4):214–221.
34. Estrada-Gutierrez G, Cappello RE, Mishra N, Romero R, Strauss JF, Walsh SW. Increased expression of matrix metalloproteinase-1 in systemic vessels of preeclamptic women: a critical mediator of vascular dysfunction. *Am J Pathol*. 2011;178(1):451–460.
35. Austin KM, Covic L, Kuliopulos A. Matrix metalloproteases and PAR1 activation. *Blood*. 2013;121(3):431–439.
36. Hatziapostolou M, Polytaichou C, Panutsopoulos D, Covic L, Tsihchlis PN. Proteinase-activated receptor-1-triggered activation of tumor progression locus-2 promotes actin cytoskeleton reorganization and cell migration. *Cancer Res*. 2008;68(6):1851–1861.
37. Goerge T, Barg A, Schnaeker EM, et al. Tumor-derived matrix metalloproteinase-1 targets endothelial proteinase-activated receptor 1 promoting endothelial cell activation. *Cancer Res*. 2006;66(15):7766–7774.
38. Agarwal A, Covic L, Sevigny LM, et al. Targeting a metalloprotease-PAR1 signaling system with cell-penetrating pepducins inhibits angiogenesis, ascites, and progression of ovarian cancer. *Mol Cancer Ther*. 2008;7(9):2746–2757.

OncoTargets and Therapy

Publish your work in this journal

OncoTargets and Therapy is an international, peer-reviewed, open access journal focusing on the pathological basis of all cancers, potential targets for therapy and treatment protocols employed to improve the management of cancer patients. The journal also focuses on the impact of management programs and new therapeutic agents and protocols on

Submit your manuscript here: <http://www.dovepress.com/oncotargets-and-therapy-journal>

patient perspectives such as quality of life, adherence and satisfaction. The manuscript management system is completely online and includes a very quick and fair peer-review system, which is all easy to use. Visit <http://www.dovepress.com/testimonials.php> to read real quotes from published authors.

Dovepress