

Lateral Epicondylitis Debridement and Repair Using Knotless Suture Anchor



Christopher T. Donaldson, M.D., Zachary J. Finley, M.D., and Michael J. O'Brien, M.D.

Abstract: Lateral epicondylitis, or tennis elbow, involves degeneration of the extensor carpi radialis brevis tendon and is often self-limiting, with surgery reserved for recalcitrant cases. Surgical management of tennis elbow consists primarily of either debridement alone or debridement with repair. Surgical repair is often performed using either a suture or a suture anchor. Good outcomes have been reported using standard repair methods; however, complications exist. Complications include potential loss of grip strength with debridement alone, as well as soft-tissue irritation caused by a prominent suture or knot stack after suture repair and suture anchor techniques. We describe a technique for debridement and repair of the extensor carpi radialis brevis tendon to the lateral epicondyle of the humerus using a knotless suture anchor, allowing for a watertight anatomic repair, maximum preservation of grip strength, and absence of a knot stack and resultant suture prominence.

Lateral epicondylitis, or tennis elbow, is the most common cause of elbow pain. The condition involves degeneration of the extensor carpi radialis brevis (ECRB) tendon near the attachment site to the lateral epicondyle of the humerus. First described by Runge¹ in 1873, it involves a noninflammatory degenerative process leading to angiofibroblastic hyperplasia, likely from repetitive microtrauma.² Typically, this is a self-limiting condition, with most cases resolving within 1 year of symptom onset.³ Nonoperative management is the mainstay of treatment, using activity modification, bracing, and anti-inflammatories, as well as therapeutic injections with corticosteroids, whole blood, and platelet-rich plasma.⁴ Surgical treatment has been reserved for patients with recalcitrant pain despite

nonoperative treatment. The optimal surgical treatment has been the subject of controversy. Options include open and arthroscopic release, radiofrequency tenotomy, debridement, and/or repair, as well as a combination of these.⁵⁻⁸ There is a relative paucity of comparative outcome studies investigating these methods, although most have seen good outcomes individually. Loss of grip strength with debridement alone has been reported.⁹ In addition, given the proximity of the joint space, synovial fistula formation remains a concern, as does skin irritation from prominent suture knots in the subcutaneous location after repair.

We present a surgical technique involving open debridement followed by repair of the ECRB using a knotless bioabsorbable suture anchor (SutureTak; Arthrex, Naples, FL). We believe this allows for maximum preservation of grip strength while minimizing the risks of fistula formation and skin irritation by performing a watertight tendon repair with a knotless anchor. In addition, use of the short knotless SutureTak insertion handle improves intraoperative handling and manageability compared with longer suture anchor handles when applied to the small, open environment of the lateral side of the elbow.

Surgical Technique

The surgical technique is shown in [Video 1](#).

Patient Positioning and Setup

The patient is placed on the operating table in the supine position with the operative arm resting in slight

From Orthopedic Medical Group of Tampa Bay (C.T.D.), Brandon, Florida; and Tulane Institute of Sports Medicine, Department of Orthopaedic Surgery, Tulane University School of Medicine (Z.J.F., M.J.O.), New Orleans, Louisiana, U.S.A.

The authors report the following potential conflicts of interest or sources of funding: C.T.D. receives personal fees from Arthrex. M.J.O. receives support from Smith & Nephew and Stryker. Full ICMJE author disclosure forms are available for this article online, as [Supplementary Material](#).

Received February 1, 2019; accepted March 13, 2019.

Address correspondence to Christopher T. Donaldson, M.D., Orthopedic Medical Group of Tampa Bay, 615 Vonderburg Dr, Brandon, FL 33511, U.S.A. E-mail: c.donaldson.md@gmail.com

© 2019 by the Arthroscopy Association of North America. Published by Elsevier. This is an open access article under the CC BY-NC-ND license (<http://creativecommons.org/licenses/by-nc-nd/4.0/>).

2212-6287/19138

<https://doi.org/10.1016/j.eats.2019.03.016>

pronation on an arm board (Fig 1). A nonsterile tourniquet is placed as proximally on the arm as possible. The operative extremity is then prepared and draped in the usual sterile fashion. After exsanguination, the tourniquet is inflated to 250 mm Hg.

Exposure

A 3-cm incision centered over the lateral epicondyle of the distal humerus is made. This incision is dissected sharply onto the fascia overlying the common extensor tendon origin. Full-thickness skin flaps are raised both medially and laterally. Next, the lateral column is palpated, and the origin of the extensor carpi radialis longus (ECRL) is identified. A longitudinal incision is made in line with the tendon fibers, dividing the origin of the ECRL tendon and revealing the ECRB origin underneath. This incision is carried proximally to the lateral epicondyle and distally for approximately 2 cm.

Tendon Debridement and Repair

The disorganized tissue of the ECRB origin is identified, visualized as grayish tissue representing angiofibroblastic hyperplasia. This dysplastic tissue is sharply dissected with a scalpel and excised (Fig 2). This reveals the site of origin of the ECRB tendon, a diamond-shaped area in the anterior-superior quadrant of the lateral epicondyle of the humerus, as the site for suture anchor placement (Fig 3). At this point, the ECRB tendon origin is clearly visible, bordered by the ECRL tendon with intact fibers dorsally and volarly. Identification of the lateral collateral ligament complex dorsal to the aponeurosis is paramount to avoid ligament damage or incorporation into the repair.

Next, by use of a drill guide, a 2.6-mm drill hole is made perpendicular to the bony surface at the site of the ECRB origin. A 3.0-mm knotless SutureTak anchor is then placed through the drill guide, and the anchor

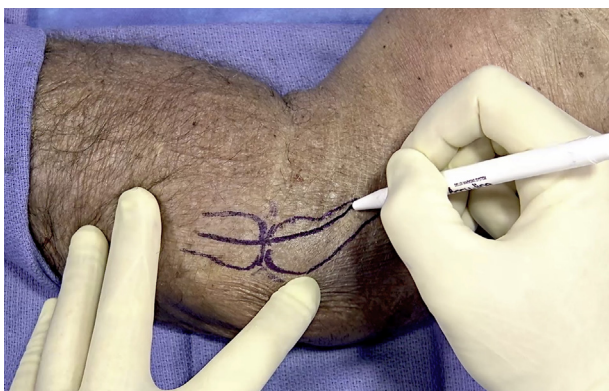

Fig 1. The patient is placed in the supine position with the left arm resting in slight pronation on an arm board. The borders of the capitellum and the radial head are depicted for reference. An approximately 3-cm curvilinear incision is used directly over the lateral column of the elbow. Our incision is extended here for demonstration purposes.

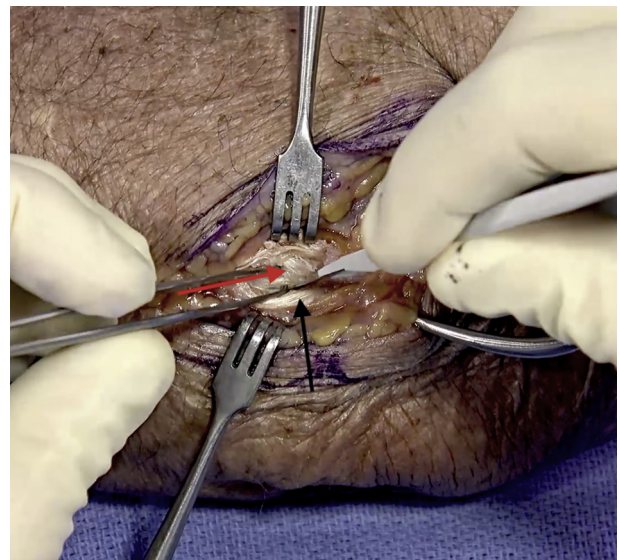


Fig 2. A longitudinal incision is made in line with the tendon fibers of the extensor carpi radialis longus (black arrow), revealing the extensor carpi radialis brevis underneath. The disorganized tissue of the extensor carpi radialis brevis origin is identified (red arrow), visualized as grayish tissue representing angiofibroblastic hyperplasia. This dysplastic tissue is sharply dissected with a scalpel, as shown here, and excised.

is impacted into the drill hole with a mallet. Loaded in the anchor are a single strand of No. 2 FiberWire CL repair suture (Arthrex) and a double-strand No. 2-0 FiberLink shuttling suture (Arthrex) (Fig 4). The No. 2 FiberWire repair suture is passed with a free needle in a running, figure-of-8, double-mattress, buried fashion starting approximately 2 cm distal to the anchor and moving proximally, with the last throw just proximal to the anchor (Fig 5). The needle is removed, and the tapered passing end of the FiberWire repair suture is passed through the FiberLink shuttling loop and folded back on itself (Fig 6). The nonlooped end of the FiberLink is pulled, shuttling the FiberWire repair suture back through the anchor (Fig 7). Laxity in the repair suture passed through the tissue is removed. The repair is then secured by adequately tensioning the repair suture tail, allowing the “finger-trap” locking mechanism in the anchor to function as a 1-way stop. The suture is cut flush with the anchor, leaving a knotless watertight repair (Fig 8). The wound is then thoroughly irrigated, and the skin is closed with a subcutaneous No. 2-0 Monocryl suture (Ethicon, Somerville, NJ) and a subcuticular No. 3-0 Monocryl suture. Finally, the wound is dressed with a soft bandage around the elbow, and a wrist brace is placed on the wrist in the neutral position.

Postoperative Protocol

The first postoperative visit occurs at 1 to 2 weeks. The patient remains in a wrist brace or wrist

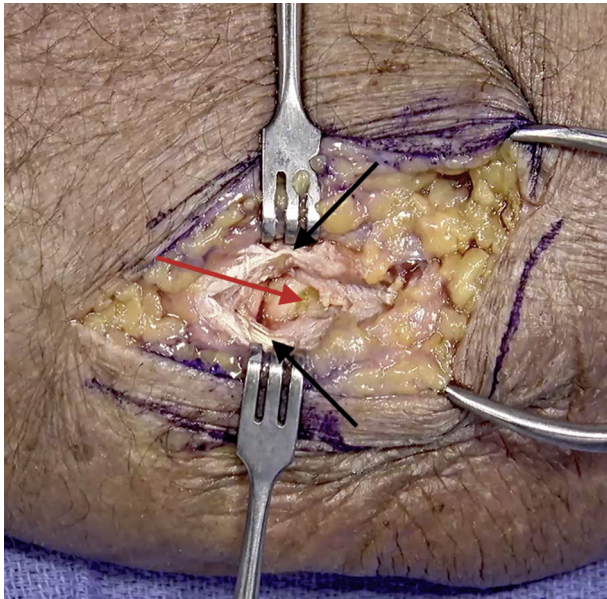


Fig 3. The site of origin of the extensor carpi radialis brevis tendon is visualized (red arrow). This is a diamond-shaped area in the anterior-superior quadrant of the lateral epicondyle of the humerus and is the site for placement of the suture anchor. The extensor carpi radialis brevis tendon origin is bordered by the extensor carpi radialis longus tendon with intact fibers dorsally and volarly (black arrows).

immobilizer for 4 weeks to rest the extensor musculature. The wrist brace is worn full time, being removed only for bathing and dressing. Full active and passive elbow range of motion is encouraged. Physical therapy is initiated at the first postoperative visit, focusing on

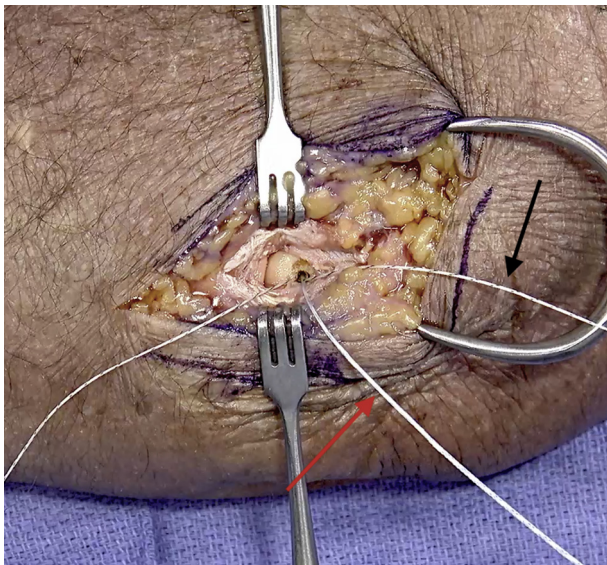


Fig 4. The anchor is placed at the site of origin of the extensor carpi radialis brevis. It is loaded with a single strand of No. 2 FiberWire CL repair suture (red arrow) and a double-strand No. 2-0 FiberLink shuttling suture (black arrow).

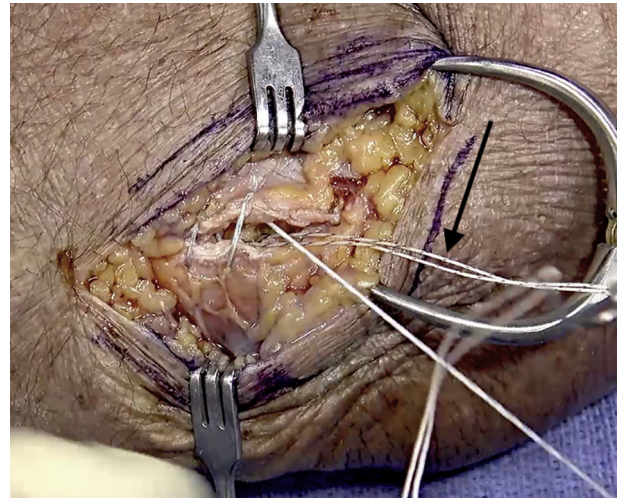


Fig 5. The No. 2 FiberWire repair suture is passed through the extensor carpi radialis longus with a free needle in a running, figure-of-8, double-mattress, buried fashion starting approximately 2 cm distal to the anchor and moving proximally. The last throw should be just proximal to the anchor. Both strands of the shuttling suture (arrow) are set aside proximally to avoid being incorporated into the repair.

full range of motion and edema control. At 4 weeks postoperatively, use of the wrist immobilizer is discontinued, and the patient is placed into a counterforce elbow strap to protect the repair. Use of the counterforce strap is continued until 8 weeks. Strengthening begins at 6 weeks with the expectation of full recovery at 2 to 3 months from the time of surgery. The pearls and pitfalls of our surgical technique are outlined in [Table 1](#).

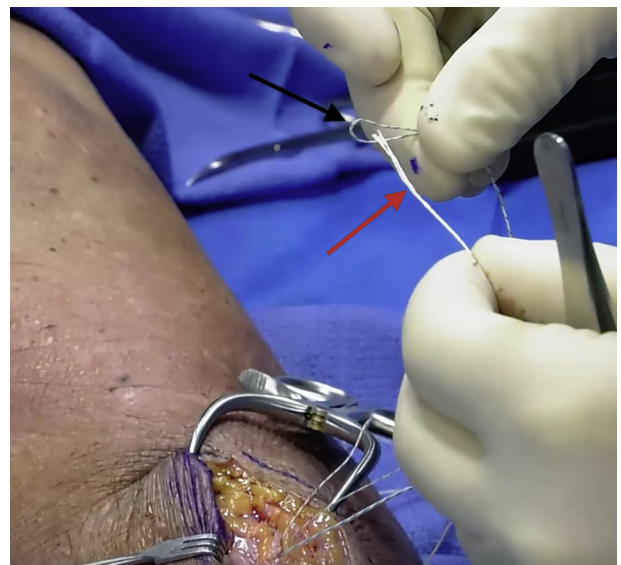

Fig 6. After the free needle is removed, the tapered passing end of the FiberWire repair suture (red arrow) is passed through the FiberLink shuttling loop (black arrow).

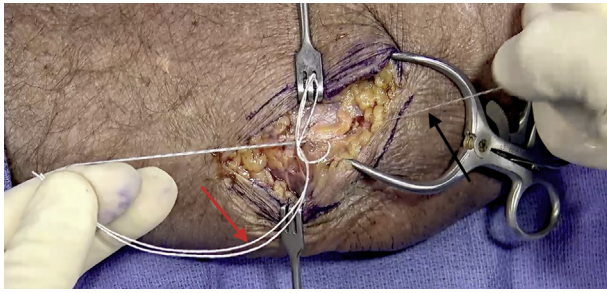


Fig 7. After the FiberWire repair suture is passed through the FiberLink shuttling loop, the repair suture is folded back on itself (red arrow). The nonlooped end of the FiberLink (black arrow) is pulled, shuttling the FiberWire repair suture back through the anchor. The free end of the repair suture can then be used to set the tension for the repair.

Discussion

Treatment of recalcitrant lateral epicondylitis remains controversial. Both open and arthroscopic techniques involving tendon debridement, repair, and release of the ECRB origin, as well as combinations thereof, have been described. Nirschl and Pettrone² were the first authors to report on the outcomes of surgical treatment of lateral epicondylitis, in 1979. They performed open debridement and primary repair of the tendon in 88 elbows over a 6-year period. Overall, they reported excellent results in 66 elbows, good results in 9, fair results in 11, and failure in 2 at 25 months

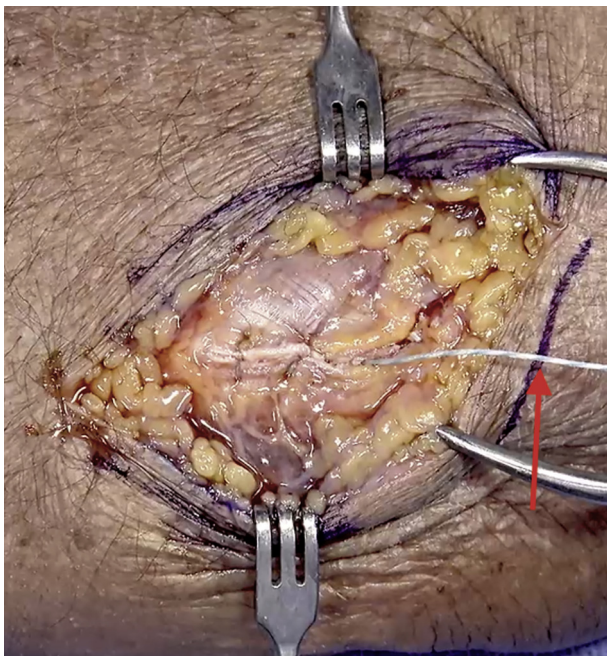


Fig 8. The repair is secured by adequately tensioning the repair suture tail (arrow), allowing the finger-trap locking mechanism in the anchor to function as a 1-way stop. The suture is then cut flush with the anchor, leaving a knotless watertight repair.

Table 1. Pearls and Pitfalls of Lateral Epicondylitis Debridement and Repair Using Knotless Suture Anchor

Completely visualize the bony anchor insertion point for accurate and safe anchor placement.
Have the anchor immediately available for insertion prior to commencing drilling.
Maintain the drill guide position during anchor insertion.
Gently "seat" the anchor through the drill guide by hand pressure prior to mallet insertion.
Remove slack in the repair suture prior to shuttling the suture through the anchor and final tensioning.
Use a knot pusher on the suture anchor to minimize pullout during final suture tensioning.
Avoid anchor pullout by opposing tissue and trying not to over-tighten the repair construct.

postoperatively. Eighty-five percent of patients returned to full preinjury activity. Thornton et al.⁸ reported excellent outcomes at an average of over 4 years postoperatively after debridement and repair in 22 elbows with recalcitrant lateral epicondylitis. They saw an increase in grip and pinch strength, reporting 110% and 106%, respectively, compared with the contralateral limb at last follow-up.

Pruzansky et al.⁷ reported the results of repair using bone tunnels, suture anchors, or tendon autograft at an average of 64.7 months postoperatively. Their study included 24 elbows, and all patients reported good outcomes. Grip strength was not reported at last follow-up, although all patients returned to the preinjury level of functioning within 8 months. Baker and Baker¹⁰ reported on long-term follow-up after arthroscopic management of lateral epicondylitis. Their technique involved debridement alone, and the study involved 30 elbows with a follow-up averaging more than 10 years. Eighty-seven percent of patients reported being satisfied with their outcome, and no patients required further surgery or injections after initial surgical treatment.

Table 2. Advantages and Disadvantages of Open Lateral Epicondylitis Debridement and Repair Using Knotless Suture Anchor

Advantages
The procedure can be performed in any patient position (supine, lateral decubitus, or prone) depending on surgeon preference.
The procedure is performed through a small, cosmetic, minimally invasive incision.
The use of a knotless anchor provides watertight closure and avoids a painful subcutaneous knot stack.
The suture anchor provides anatomic repair of the ECRB tendon back to its anatomic origin compared with debridement alone.
If indicated, elbow arthroscopy can be performed prior to tendon repair to allow for thorough joint assessment and treatment of other intra-articular pathology.
Disadvantages
Implant cost of including an anchor for fixation
Limited elbow "real estate" for anchor placement
ECRB, extensor carpi radialis brevis.

Knotless suture anchors have previously been described for use in the shoulder,¹¹ hip,¹² knee,¹³ and elbow.¹⁴ Our technique for the treatment of chronic lateral epicondylitis involves open debridement followed by repair with a knotless bioabsorbable suture anchor. We believe this technique allows for maximum preservation of grip strength while providing a watertight repair. In addition, the absence of a prominent suture knot will help eliminate the concern for soft-tissue irritation after repair.

One possible limitation of this technique as described relates to the open approach. Both open surgical treatment and arthroscopic surgical treatment of lateral epicondylitis have been described and are successful. However, open techniques for surgical treatment of lateral epicondylitis have shown a higher rate of pain-free outcomes compared with arthroscopic techniques.¹⁵ An open approach could potentially pose a higher risk of infection as well as more prominent scarring. We advocate the use of the open technique for several reasons. First, there is no need for additional arthroscopic equipment and special positioning. Second, use of a small incision with limited equipment creates efficiency of operative time and safety of direct visualization of the lateral collateral ligament attachment with minimal impact on cosmesis. Alternatively, arthroscopic repair of the lateral ulnar collateral ligament has been described using a knotless suture anchor and could potentially be used similarly in repair of the ECRB.¹⁴ Advantages and disadvantages of our surgical technique are summarized in Table 2. In conclusion, our technique of open debridement with repair using a knotless suture anchor is a safe technique that allows for maximum strength preservation while minimizing the risk of synovial fistula formation and soft-tissue irritation in the surgical treatment of recalcitrant lateral epicondylitis of the elbow.

References

1. Runge F. Genese und behandlung des schreibkrampfes. *Berl Klin Wochenschr* 1873;21:245-248 [in German].
2. Nirschl RP, Pettrone FA. Tennis elbow. The surgical treatment of lateral epicondylitis. *J Bone Joint Surg Am* 1979;61:832-839.
3. Haahr JP, Andersen JH. Prognostic factors in lateral epicondylitis: A randomized trial with one-year follow-up in 266 new cases treated with minimal occupational intervention of the usual approach in general practice. *Rheumatology (Oxford)* 2003;42:1216-1225.
4. Gautam VK, Verma S, Batra S, Bhatnagar N, Arora S. Platelet-rich plasma versus corticosteroid injection for recalcitrant lateralepicondylitis: Clinical and ultrasonographic evaluation. *J Orthop Surg (Hong Kong)* 2015;23:1-5.
5. Savoie FH III, VanSice W, O'Brien MJ. Arthroscopic tennis elbow release. *J Shoulder Elbow Surg* 2010;19:31-36 (suppl).
6. Lattermann C, Romeo AA, Anbari A, et al. Arthroscopic debridement of the extensor carpi radialis brevis for recalcitrant lateral epicondylitis. *J Shoulder Elbow Surg* 2010;19:651-656.
7. Pruzansky ME, Gantsoudes GD, Watters N. Late surgical results of reattachment to bone in repair of chronic lateral epicondylitis. *Am J Orthop (Belle Mead NJ)* 2009;38:295-299.
8. Thornton SJ, Rogers JR, Prickett WD, Dunn WR, Allen AA, Hannafin JA. Treatment of recalcitrant lateral epicondylitis with suture anchor repair. *Am J Sports Med* 2005;33:1558-1564.
9. Khashaba A. Nirschl tennis elbow release with or without drilling. *Br J Sports Med* 2001;35:200-201.
10. Baker CL Jr, Baker CL III. Long-term follow-up of arthroscopic treatment of lateral epicondylitis. *Am J Sport Med* 2008;36:254-260.
11. Pietschmann MF, Froehlich V, Ficklscherer A, Wegener B, Jansson V, Müller PE. Biomechanical testing of a new knotless suture anchor compared with established anchors for rotator cuff repair. *J Shoulder Elbow Surg* 2008;17:642-646.
12. Suarez-Ahedo C, Martin TJ, Walsh JP, Chandrasekaran S, Lodhia P, Domb BG. Anatomic labral repair in the hip using a knotless tensionable suture anchor. *Arthrosc Tech* 2016;5:e1089-e1094.
13. Tapasvi SR, Shekhar A, Patil SS. Knotless medial meniscus posterior root repair. *Arthrosc Tech* 2018;7:e429-e435.
14. Ek ET, Wang KK. Arthroscopic repair of the lateral ulnar collateral ligament of the elbow using a knotless suture anchor. *Arthrosc Tech* 2018;7:e77-e81.
15. Riff AJ, Saltzman BM, Cvetanovich G, Frank JM, Hemu MR, Wysocki RW. Open vs percutaneous vs arthroscopic surgical treatment of lateral epicondylitis: An updated systemic review. *Am J Orthop (Belle Mead NJ)* 2018;47.