



Case Report

Primary Pure Uterine Lipoma: A Report of two Cases and Review of the Literature

Deniz Tunçel,¹ Rabia Doğukan,¹ Fatih Mert Doğukan,¹ Fevziye Kabukçuoğlu,¹ Hakan Erenel,² Işıl Ayhan²

¹Department of Pathology, Sisli Hamidiye Etfal Training and Research Hospital, Istanbul, Turkey

²Department of Obstetrics and Gynecology, Sisli Hamidiye Etfal Training and Research Hospital, Istanbul, Turkey

Abstract

Pure uterine lipomas are rare diagnoses despite lipoma being a common entity. The histogenesis of these lesions remains unknown, and its clinical symptoms are similar to those of uterine leiomyomas.

In this report, two cases of uterine lipomas were presented with their histopathological and clinical aspects.

Keywords: Lipoma; soft tissue tumor; uterine neoplasm.

Please cite this article as "Tunçel D., Doğukan R., Doğukan F.M., Kabukçuoğlu F., Erenel H., Ayhan I. Primary Pure Uterine Lipoma: A Report of two Cases and Review of the Literature. Med Bull Sisli Etfal Hosp 2018;52(2):135–137".

Pure lipoma of the uterus is an uncommon entity, and only few cases have been reported in the literature. The histogenesis of these lesions has been unknown. The neoplasms commonly occur in 20%–40% of women aged >30 years and more frequently affect postmenopausal women. The clinical symptoms and physical signs are similar to those found in leiomyomas, the most common uterine lesions. The diagnosis can be easily made at the time of surgery or autopsy. However, uterine lipomas may lead to many problems in the differential diagnosis compared with other uterine tumors. Recent studies have suggested the possibility of a preoperative diagnosis using computed tomography and magnetic resonance imaging (MRI).

Case Reports

Case 1– A 64-year-old woman presented with abdominal pain. Transabdominal ultrasonography revealed a uterine mass of 3-cm diameter, which was consistent with an intramural leiomyomatous lesion. Total abdominal hyster-

ectomy and bilateral salpingo-oophorectomy were performed. On gross examination, a 3-cm well-circumscribed intramural lesion with a cut surface of adipose tissue-like appearance was observed (Fig. 1). On histopathological evaluation, uniform cytoplasmic vacuoles confirmed the diagnosis of uterine lipoma (Figs. 2, 3).

Case 2– A 56-year-old woman with a complaint of abdominal pain presented to the gynecology department. Transabdominal ultrasonography suspected an incidental leiomyoma. Total abdominal hysterectomy and bilateral salpingo-oophorectomy were performed, and an 8.5-cm, well-circumscribed, yellowish, lipomatous lesion filling the uterine cavity was observed. Histopathologically, the lesion showed similar morphology with that of case 1 and was diagnosed as uterine lipoma.

Discussion

Lipomatous uterine tumors, especially pure lipomas, are very rare uterine benign neoplasms.⁽¹⁾ Their incidence has

Address for correspondence: Fatih Mert Doğukan, MD. Department of Pathology, Sisli Hamidiye Etfal Training and Research Hospital, Istanbul, Turkey

Phone: +90 536 713 56 93 **E-mail:** fmdogukan@hotmail.com

Submitted Date: December 16, 2016 **Accepted Date:** February 15, 2017 **Available Online Date:** May 25, 2018

©Copyright 2018 by The Medical Bulletin of Sisli Etfal Hospital - Available online at www.sislietfalthip.org

This is an open access article under the CC BY-NC-ND license (<http://creativecommons.org/licenses/by-nc/4.0/>).



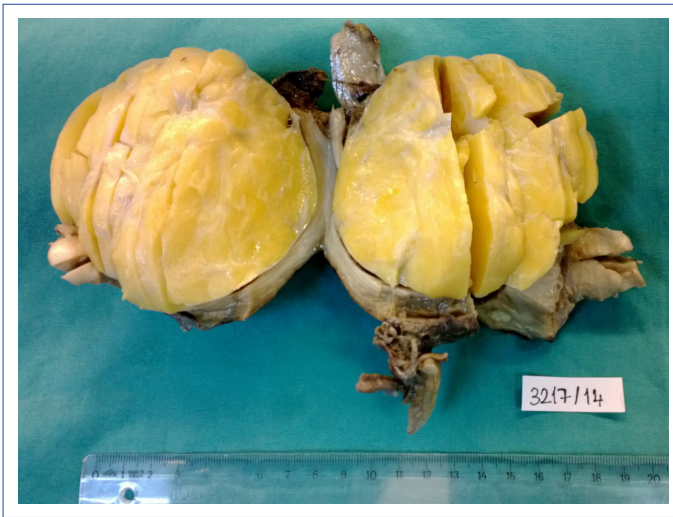

Figure 1. Well-circumscribed, yellowish intrauterine mass lesion (intramural lipoma).

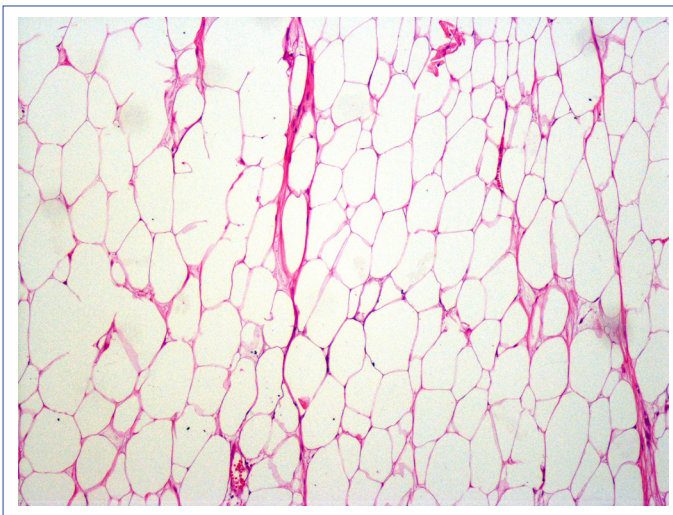


Figure 2. Mature adipocytes, including uniform cytoplasmic vacuoles (H&E, $\times 10$).

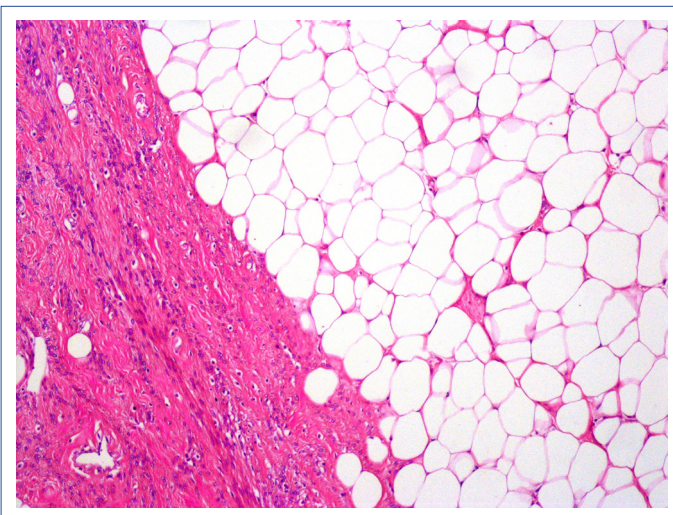


Figure 3. Adipocytes and smooth muscle fibers (H&E, $\times 10$).

been reported between 0.03% and 0.2%.^[2, 4] In the current study, two cases of uterine lipomas were presented. Mixed-type lipomas (lipoleiomyoma, angiomyolipoma, and fibrolipoma) are more commonly encountered than pure lipomatous tumors.^[2, 3] In our study, no components other than lipoma were seen. Uterine lipoleiomyoma is generally the most common type of uterine lipomatous tumor and is mostly seen in the postmenopausal age group.^[2, 5] According to Willen et al.,^[6] pure lipoma should have been the proper diagnosis for cases with a tumor consisting of adipocytes and peripherally displaced smooth muscle cells.

Despite some pathogenetic theories in previous reports, such as misplaced embryonic fat cells, perivascular extension of peritoneal/retroperitoneal fat, lipocytic differentiation of primitive connective or mesenchymal tissue, and adipocytic metaplasia of smooth muscle or connective tissue cells,^[3, 7, 8] the pathogenesis of the lesion remains unknown.^[5]

Histologically, pure uterine lipomas comprise mature adipose cells, with no invasion of the surrounding myometrium.^[9, 10] In our two cases, similar morphology was observed. When a large uterine tumor develops in a postmenopausal woman, the possibility of malignancy should always be considered. Thus, to rule out liposarcoma, a final pathological examination is ultimately required.^[10]

Preoperative imaging techniques bare critical importance to differentiate a uterine lipomatous tumor from other uterine lesions, such as leiomyoma and several adnexial tumors.^[10] Preoperative diagnosis can be made to avoid unnecessary surgery using these current imaging modalities. MRI is the best tool for diagnosing a pelvic fatty tumor such that the correct preoperative diagnosis can circumvent unnecessary surgery in an asymptomatic patient.^[10] In our cases, preoperative investigation could not differentiate the lipomatous entities from other uterine lesions; therefore, further pathological examination became essential. Histopathological and immunohistochemical examinations may become crucial in the differential diagnosis of uterine lipomas from other possible malignant neoplasms. In the current cases, histopathological examination was performed, and the diagnosis of pure uterine lipoma was established.

In conclusion, uterine lipomas have an excellent prognosis and can be considered as differential diagnosis of uterine mass in postmenopausal women.

Disclosures

Peer-review: Externally peer-reviewed.

Conflict of Interest: None declared.

Authorship contributions: Concept – D.T., R.D.; Design – R.D., F.M.D.; Supervision – D.T., F.K.; Materials – D.T., H.E., I.A.; Data collection &/or processing – D.T., R.D.; Analysis and/or interpretation – D.T., R.D., F.M.D.; Literature search – F.M.D.; Writing – D.T., R.D.; Critical review – F.K.

References

1. Imenpour H, Petrogalli F, Anselmi L. Pure uterine lipoma. *Pathologica* 2013;105:24–7.
2. Kitajima K, Kaji Y, Imanaka K, Sugihara R, Sugimura K. MRI findings of uterine lipoleiomyoma correlated with pathologic findings. *AJR Am J Roentgenol* 2007;189:W100–4.
3. Coumbaras M, Validire P, Strauss C, Herry M, Dahan H, Palau R. Uterine lipoma: MRI features with pathologic correlation. *Abdom Imaging* 2005;30:239–41.
4. Erdem G, Celik O, Karakas HM, Alkan A, Hascalik S. Pure uterine lipoma. *Magn Reson Imaging* 2007;25:1232–6.
5. Maebayashi T, Imai K, Takekawa Y, Sasaki J, Otsuka H, Katsura Y, et al. Radiologic features of uterine lipoleiomyoma. *J Comput Assist Tomogr* 2003;27:162–5.
6. Willén R, Gad A, Willén H. Lipomatous lesions of the uterus. *Virchows Arch A Pathol Anat Histol* 1978;377:351–61.
7. Loffroy R, Nezzal N, Mejean N, Sagot P, Krausé D. Lipoleiomyoma of the uterus: imaging features. *Gynecol Obstet Invest* 2008;66:73–5.
8. Chu CY, Tang YK, Chan TS, Wan YH, Fung KH. Diagnostic challenge of lipomatous uterine tumors in three patients. *World J Radiol* 2012;4:58–62.
9. Kabukçuoğlu F, Tanık C, Evren İ. İntramural lipom olgusu. *Med J Okmeydanı Train Res Hosp* 1995;13:81–2.
10. Fujimoto Y, Matsumoto T, Honda N, Tojo R, Furuya M, Kasai K, et al. Prenatal diagnosis of long QT syndrome by non-invasive fetal electrocardiography. *J Obstet Gynaecol Res* 2009;35:555–61.