

# Should We Consider Preparing Patients for Future Face Transplant when Managing Complex Facial Trauma?

Matthew R. Zeiderman, MD  
Joseph M. Firriolo, MD  
Dattesh R. Dave, MD, MSc  
Lee L.Q. Pu, MD, PhD, FACS

**Summary:** With advancements in microsurgical technique and experience, face transplantation is becoming a clinical reality and acceptable procedure. Preparation of the maxillofacial skeleton and initial soft-tissue coverage for face transplant candidates is essential for optimizing the ultimate outcome by providing immediate coverage of vital structures, functionality, and a stable skeletal framework. We present our experience of preparing such a patient who underwent a successful face transplant, with an excellent outcome. A 24-year-old man sustained a self-inflicted ballistic injury to his face. Composite tissue deficits included significant soft-tissue loss in the central lower and midface, comminuted fractures of midface, and large bone gaps of the maxilla and mandible. He underwent open reduction internal fixation of bilateral LeFort III, zygomaticomaxillary complex, and complex maxillary and mandibular fractures with titanium plates and a free anterolateral thigh perforator flap to the midface with concomitant pedicled left supraclavicular artery fasciocutaneous flap to the lower face. He subsequently underwent a second free anterolateral thigh perforator for the exposed mandibular hardware due to partial necrosis of the supraclavicular artery fasciocutaneous flap. The patient achieved stable bone reconstruction and soft-tissue coverage and was discharged home. He was placed on the waiting list for a face transplant by another center in the country and eventually underwent a successful face transplant. We believe that the preparation of the patient with complex craniomaxillofacial trauma for face transplant should be considered when the extent of injury exceeds conventional reconstructive limits. Our approach provides the best opportunity for an optimal face transplant outcome while minimizing flap donor site morbidity. (*Plast Reconstr Surg Glob Open* 2020;8:e2962; doi: [10.1097/GOX.0000000000002962](https://doi.org/10.1097/GOX.0000000000002962); Published online 14 July 2020.)

## INTRODUCTION

Management of complex facial trauma remains challenging. Achieving a satisfactory outcome is difficult with conventional reconstructive approaches.<sup>1</sup> Microvascular free tissue transfer has expanded the reconstructive surgeon's options for attempting to replace "like-with-like" when local options are insufficient or unavailable. However, limitations in donor site availability, skeletal size,

and soft-tissue characteristics result in suboptimal aesthetic and functional outcomes. Tissue deficits can lead to oral incompetence, difficulty with normal breathing, speech, and mastication, and visual disturbance. Poor aesthetic outcomes after conventional reconstructive procedures often lead to the social isolation of the patient.

With advancements in microsurgical technique and experience, face transplantation is becoming a clinical reality and an acceptable procedure. Preoperative preparation of the maxillofacial skeleton and initial soft-tissue coverage for face transplant candidates is essential for optimizing the ultimate outcome by providing immediate coverage of vital structures, functionality, a stable skeletal framework, and time to assess the patient's psychiatric stability and desire for reconstructive efforts or transplant. An abundance of literature exists on the technical difficulty of face transplantation, lessons learned, complications, and outcomes.<sup>2-4</sup> Literature is very limited regarding the initial operative preparation of the maxillofacial skeleton

*From the Division of Plastic Surgery, Department of Surgery, University of California at Davis, Sacramento, Calif.*

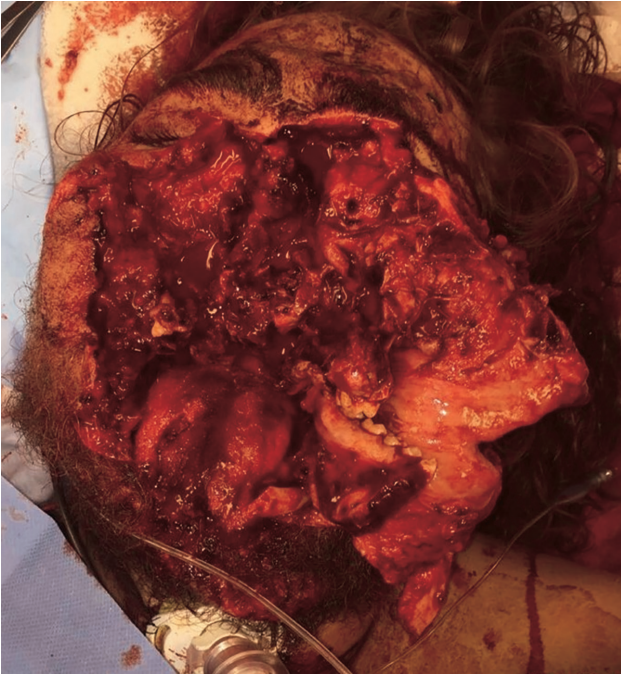
*Received for publication March 18, 2020; accepted May 15, 2020.*

*Presented at the 2019 Meeting of the Mountain West Society of Plastic Surgeons, March 7–10, 2019, Squaw Valley, Calif.*

*Copyright © 2020 The Authors. Published by Wolters Kluwer Health, Inc. on behalf of The American Society of Plastic Surgeons. This is an open-access article distributed under the terms of the [Creative Commons Attribution-Non Commercial-No Derivatives License 4.0 \(CCBY-NC-ND\)](https://creativecommons.org/licenses/by-nc-nd/4.0/), where it is permissible to download and share the work provided it is properly cited. The work cannot be changed in any way or used commercially without permission from the journal.*

**DOI:** [10.1097/GOX.0000000000002962](https://doi.org/10.1097/GOX.0000000000002962)

**Disclosure:** *The authors have no financial interest to declare in relation to the content of this article.*

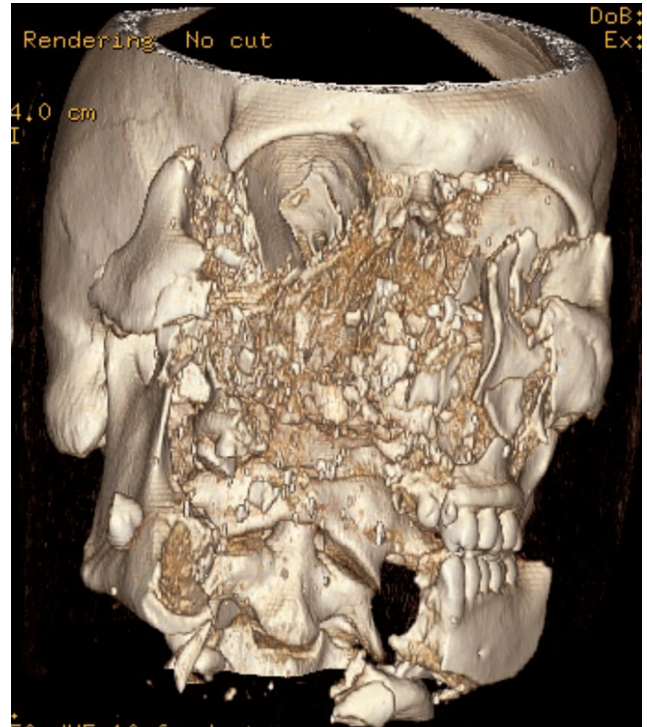

**Fig. 1.** Extensive composite facial tissue losses during initial presentation after self-inflicted gunshot wound (GSW).

for a face transplant. We present our experience and management strategy to prepare such a patient who recently underwent a successful face transplant with an excellent outcome.<sup>5</sup>

### PATIENTS AND METHODS

A 24-year-old man sustained a self-inflicted ballistic injury. He was quickly transferred to our hospital, a level I trauma center, for “definitive care.” Composite tissue deficits included a significant soft-tissue loss in the central portion of the mid and lower face, with a 7 cm maxillary defect and 4 cm mandibular defect. He also lost anterior palate, right orbital rim, anterior nasal spine and septum, the entire ethmoid, and 50% of the right upper and lower lip soft tissues (Figs. 1 and 2). However, his vision was intact. The sequence of procedures after tracheotomy and gastric feeding tube placement and initial wound debridement and bone stabilization of the mandible and midface on admission was as follows: (1) detailed examination was performed under general anesthesia, and all soft tissue and bone defects were accurately assessed; (2) definitive bone stabilization including redo open reduction internal fixation of bilateral LeFort III, bilateral zygomaticomaxillary complex, complex maxillary and mandibular fractures with titanium plates followed by definitive soft-tissue reconstruction with a free anterolateral thigh perforator (ALT) flap to the midface to fill dead space and cover a temporary maxillary plate and a concomitant left supraclavicular artery fasciocutaneous (SCA) flap was used to cover exposed mandible bone and reconstruction plate 6 days later; (3) debridement of distal left SCA flap necrosis and elevation of a right SCA flap for coverage of additional



**Fig. 2.** Three-dimensional (3D) facial bone CT (computed tomography) scan image showing comminuted and multiple facial fractures during initial presentation after self-inflicted GSW.

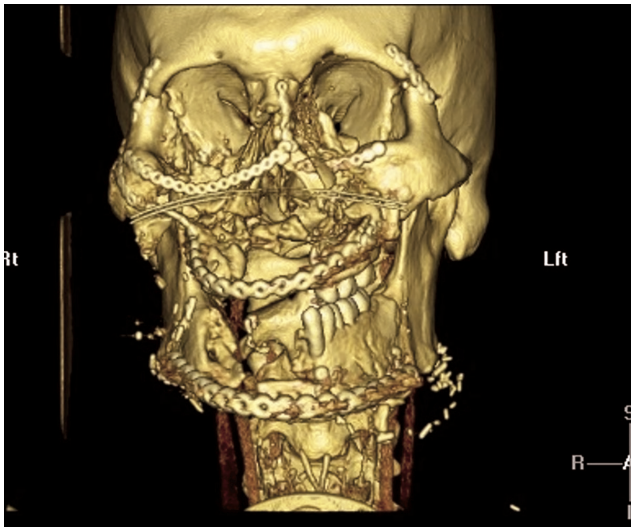
exposed mandibular hardware 8 days later; (4) debridement of distal right SCA flap necrosis and a second free ALT to cover exposed mandible and its reconstruction plate 2 weeks later; (4) local tissue rearrangements were performed for small partial wound dehiscence 10 days later; (5) open reduction internal fixation of the right orbital floor fracture with a Medpor implant (Stryker, Kalamazoo, MI) 3 months later; and (6) additional local tissue rearrangements were performed for small partial wound dehiscence 2 weeks later.

### RESULTS

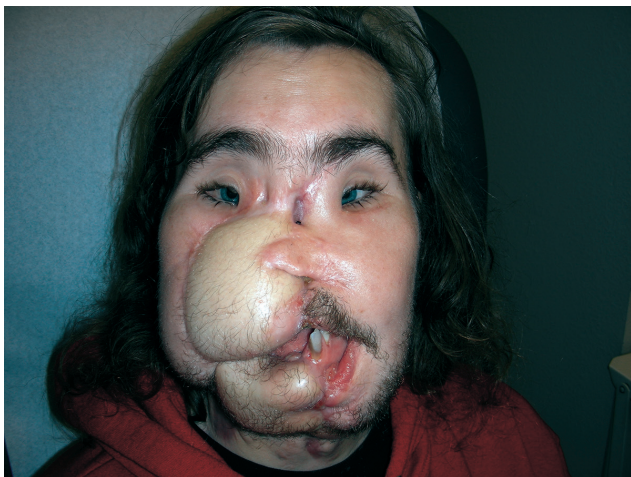
After those reconstructive procedures, the patient achieved stable bone reconstructions and healed soft-tissue wounds with the application of only local or free fasciocutaneous flaps and facial reconstructive plates (Fig. 3). He was discharged home after nearly a 5-month hospital stay (Fig. 4). He was subsequently selected by a face transplant center in the country as a good candidate and underwent a successful composite face transplant 1 year later, with a very optimal outcome.

### DISCUSSION

Preparation of the patient with extremely complex facial trauma for future face transplant can be considered when the extent of the injury is beyond conventional reconstructive limits. This is particularly true when central face has a significant ballistic injury, which is also associated with comminuted fractures of the nasal and palatal bones and ethmoid, such as in this



**Fig. 3.** Three-dimensional (3D) facial bone CT (computed tomography) scan image showing ORIF (open reduction internal fixation) of multiple comminuted facial fractures after “definitive” restoration of the facial skeletal structures.



**Fig. 4.** The result at 6 months after multiple reconstructive procedures when the patient was discharged home. All those procedures were performed to prepare him for a possible future face transplant.

case. Therefore, face transplantation is indicated for this patient because of his “irreparable facial injury,” and because both anatomic structures and functional rehabilitations can be provided by the face transplant.<sup>5</sup> Immediate face transplantation has been performed, but is controversial and often not feasible due to limited donor supply.<sup>6</sup> In this case, the option for future face transplant was considered and offered to the patient in the beginning of care because of the extent of the ballistic injury after his psychological evaluation. He was determined as a competent patient who desired to look “normal” after reconstruction to his face. His psychiatric condition was under control with medications, and we believed that he could be a reasonably good candidate for future face transplant. Our assessment was later confirmed by the transplant center in the country. Therefore,

all initial reconstructions would focus on achieving bone stabilization with reconstructive plates and soft-tissue coverage for wound healing with local or free fasciocutaneous flaps. All those reconstructions would allow “initial healing” of the patient’s extensive traumatic facial wounds and restore the near-normal facial bone structure, allowing hospital discharge and placement on a face transplant wait list. All reconstructive procedures selected for this patient minimized donor site morbidity except for surgical scars. In addition, restoration of the near-normal facial skeleton could facilitate easier bone inset and soft-tissue draping at future transplant.<sup>5</sup>

Contemporary reconstructions focus on bone healing and soft-tissue coverage when selected for managing an extensive facial traumatic patient. Often, the functional and aesthetic goals of reconstruction are beyond what can be achieved with contemporary reconstructive techniques, typically requiring many procedures over several years for a suboptimal result.<sup>7</sup> The authors believe that a free ALT flap and an SCA flap are 2 main flaps that can be selected for initial facial soft-tissue reconstructions. The right SCA flap was again harvested but inset differently to cover the exposed reconstruction plate after partial necrosis of the left SCA flap because we planned to give a second try with the same kind of the flap. Unfortunately, the second free ALT flap was eventually needed to provide reliable soft-tissue coverage. Obviously, those local or free fasciocutaneous flaps, selected for this patient, can also be used to cover exposed facial skeleton or fractures if the patient’s injuries were mostly soft tissue.

Common functional issues that cannot be addressed by conventional reconstruction include oral incompetence, difficulty breathing, absent nasal breathing, dysphagia, and dysphonia. Given the multitude of tissue types and qualities and intricately designed 3-dimensional structures of the human face, particularly the midface, vascularized composite allotransplantation offers the best opportunity to replace like-with-like and restore a “normal” face.<sup>8</sup> Recreation of an aesthetically pleasing midface is not possible with contemporary reconstructions. Initial reconstructive efforts serve as a bridge to transplant and meet functional needs such as separation of oral and nasal cavities. Face transplant is needed to restore structures necessary for rehabilitation, normal eating, drinking, speaking, and breathing.<sup>7</sup> Despite the risks of vascularized composite allotransplantation, notably psychological risk and the risks of chronic immunosuppression, proceeding with face transplant may best address the patient’s quality of life goals and promote reintegration into society.<sup>2</sup> Several studies and a systematic review report show improved psychosocial well-being after transplant, but these results may not be generalizable and more longitudinal studies are needed, given the small number of patients.<sup>9,10</sup>

## CONCLUSIONS

Face transplantation has become an accepted procedure and often provides a better cosmetic and functional outcome that cannot be achieved with conventional reconstructions. When caring for the patient with

extensive facial trauma, especially involving the central face, candidacy for facial reconstruction can be offered to the patient and should be considered as a long-term goal for the patient. Initial reconstructions should minimize donor site morbidity if face transplant is a viable option for the patient and appropriate reconstructive procedures should be selected to achieve restoration of facial skeleton and healing of the soft-tissue wound.

**Lee L.Q. Pu, MD, PhD, FACS**

Division of Plastic Surgery  
University of California at Davis  
2335 Stockton Blvd., Room 6008  
Sacramento, CA 95817  
E-mail: llpu@ucdavis.edu

#### PATIENT CONSENT

*The patient provided written consent for the use of his image.*

#### REFERENCES

1. Pribaz JJ, Caterson EJ. Evolution and limitations of conventional autologous reconstruction of the head and neck. *J Craniofac Surg*. 2013;24:99–107.
2. Lantieri L, Hivelin M, Audard V, et al. Feasibility, reproducibility, risks and benefits of face transplantation: a prospective study of outcomes. *Am J Transplant*. 2011;11:367–378.
3. Lantieri L, Grimbert P, Ortonne N, et al. Face transplant: long-term follow-up and results of a prospective open study. *Lancet*. 2016;388:1398–1407.
4. Rifkin WJ, David JA, Plana NM, et al. Achievements and challenges in facial transplantation. *Ann Surg*. 2018;268:260–270.
5. Kantar RS, Ceradini DJ, Gelb BE, et al. Facial transplantation for an irreparable central and lower face injury: a modernized approach to a classic challenge. *Plast Reconstr Surg*. 2019;144:264e–283e.
6. Maciejewski A, Krakowczyk Ł, Szymczyk C, et al. The first immediate face transplant in the world. *Ann Surg*. 2016;263:e36–e39.
7. Janis JE, Khansa I, Lehrman CR, et al. Reconstructive management of devastating electrical injuries to the face. *Plast Reconstr Surg*. 2015;136:839–847.
8. Pomahac B, Bueno EM, Sisk GC, et al. Current principles of facial allotransplantation: the Brigham and Women's Hospital Experience. *Plast Reconstr Surg*. 2013;131:1069–1076.
9. Oser ML, Nizzi MC, Zinser JL, et al. Quality of life and psychosocial functioning 2 years following facial transplantation. *Psychosomatics*. 2018;59:591–600.
10. Aycart MA, Kiwanuka H, Krezdorn N, et al. Quality of life after face transplantation: outcomes, assessment tools, and future directions. *Plast Reconstr Surg*. 2017;139:194–203.