

Trigeminal neuralgia caused by brain arteriovenous malformations: A case report and literature review

YONGJIE YUAN¹, YANDONG ZHANG², QI LUO¹ and JINLU YU¹

Departments of ¹Neurosurgery and ²Medicine, First Hospital of Jilin University, Changchun, Jilin 130021, P.R. China

Received January 17, 2015; Accepted March 1, 2016

DOI: 10.3892/etm.2016.3277

Abstract. Few cases of trigeminal neuralgia (TGN) induced by brain arteriovenous malformations (bAVMs) have previously been reported. The present case report described one case of TGN caused by bAVMs in a 32-year-old male patient who suffered from recurrent pain in his right cheek for a period of two years, for whom the seizure frequency and duration of pain increased for 6 months. Magnetic resonance imaging was performed, which demonstrated flow-void signals in the abnormal vessels in the right cerebellopontine angle. Subsequent digital subtraction angiography confirmed the diagnosis of bAVMs, and showed the nidus was fed by the right superior cerebellar and the right anterior inferior cerebellar, and drained into the adjacent venous sinuses on the same side. The patient underwent an interventional embolization treatment. TGN was completely relieved following embolization of the majority of the bAVMs. Pain relief may be associated with blocking of the pulsatile compression of the feeding arteries of the bAVMs, the arterialized draining veins or the malformed niduses following embolization, which is similar to the effects induced by microvascular decompression surgery of the trigeminal nerve. In the present case study and review, the underlying mechanism and treatment strategy of TGN caused by bAVMs were discussed in the context of present case, and a literature review was carried out.

Introduction

Trigeminal neuralgia (TGN) is a transient, recurrent and intense pain in the area on the face where the trigeminal (TG) nerve is distributed (1-3). Previous studies have demonstrated that 80-90% of primary TGN cases are induced by vascular compression of the TG nerve at the root entry zone (REZ) (1,4).

Superior cerebellar artery (SCA) and the anterior inferior cerebellar artery (AICA) are the predominant vessels responsible for the compression, followed by venous vessels (5,6). Brain arteriovenous malformations (bAVMs) often manifest as cerebral hemorrhage, particularly in young patients; therefore, patients with unruptured bAVMs have a 2-4% risk of rupture and bleeding each year, and each bleeding event is associated with an ~18% risk of mortality (7,8). In addition, bAVMs also manifest as chronic headaches, epilepsy and neurological deficits (8-11). However, there have been relatively few reports of cases of TGN caused by bAVM (4,12). The present case report describes a case of TGN caused by bAVMs in the cerebellopontine angle (CPA). Facial pain was successfully relieved after the patient received partial embolization treatment, which may be associated with the blockade of the pulsatile compression of the feeding arteries, the arterialized draining veins or the malformed niduses. Therefore, TGN caused by bAVMs is a vascular nerve compression disease. In the present case study and review, the underlying mechanism and treatment strategy of TGN caused by bAVMs were discussed in the context of present case, and a literature review was carried out.

Case report

A 32-year-old male was admitted to the First Hospital of Jilin University (Changchun, China) on December 6, 2014, suffering from recurrent pain in his right cheek for two years, which had increased in severity over the previous 6 months. The patient reported that the pain began three years previously as a stabbing-like, intense pain that occurred suddenly on the right lower lip and mandible without any prior signs; each episode of pain lasted for 10-30 sec. The first period of pain lasted ~1 week and was self-relieved without medication. The pain recurred following a period of 6 months, and the duration of each episode of pain extended to 2-3 min. The patient was administered 800 mg oral carbamazepine (Novartis, Basel, Switzerland) daily, which was effective at relieving the pain on the right side of the face of the patient. In the 6 months prior to hospital admission, the frequency of the pain in the right cheek of the patient increased. The pain occurred >6 times every day and each episode lasted 10-30 min, and daily oral administration of 1,200 mg carbamazepine was not effective at controlling the pain. Clinical examination demonstrated that no significant trigger point could be palpated and there were no abnormalities in corneal reflexes or facial sensation. Subsequent magnetic

Correspondence to: Dr Jinlu Yu or Dr Qi Luo, Department of Neurosurgery, First Hospital of Jilin University, 71 Xinmin Avenue, Changchun, Jilin 130021, P.R. China
E-mail: jinluyu@hotmail.com
E-mail: LuoQiJilin@hotmail.com

Key words: brain arteriovenous malformation, trigeminal neuralgia, treatment

resonance imaging (MRI) demonstrated the presence of flow-void signals in the abnormal vessels in the right CPA (Fig. 1). Digital subtraction angiography (DSA) further confirmed the diagnosis of bAVMs, and demonstrated that the malformed niduses were fed by the right SCA and the AICA, and drained into the adjacent venous sinuses on the same side (Fig. 2). Although the patient only exhibited symptoms of TGN, the patient was treated with interventional embolization, due to the risk that the bAVMs may bleed in the future. Embolization was conducted under general anesthesia with intravenous 0.05-0.1 mg/kg midazolam (Nhwa, Jiangsu, China), 1.0-1.5 μ g/kg remifentanyl (Renfu, Yichang, China), 0.2-0.3 mg/kg etomidate (Nhwa), 0.6 mg/kg rocuronium (Organon, Brussels, Belgium), and was maintained with 0.6 mg/kg propofol (Nhwa), 5-10 mg/(kg/h) and 0.1-0.2 μ g/(kg/min) remifentanyl (Renfu, Yichang, China). Following arterial puncture and sheath insertion in the femoral artery using the Seldinger technique (13), a 6F-guiding catheter (Cordis Co., Miami, FL, USA) was inserted into the left vertebral artery. Under the guidance of a Mirage micro-wire (ev3, Irvine, California, USA), a Marathon micro-catheter was inserted into the bAVMs. The micro-catheter entered the bAVMs via the right AICA and onyx-18 glue (ev3) was slowly injected. Onyx-18 glue diffused well in the bAVMs and embolized the majority of the malformations. Angiography was conducted immediately following surgery, which demonstrated that the majority of the bAVMs had disappeared and the draining veins were patent (Fig. 2). There were no complications following the surgical procedure and the pain in the right cheek of the patient was completely relieved one week following the surgical procedure. The patient was satisfied with the outcome of the embolization surgery. Post-surgical follow-ups were conducted for a period of two years via telephone. The patient experienced no further pain in his right cheek, and thus chose not to return to the hospital for a follow-up reexamination. The present study was approved by the Ethics Committee of the First Hospital of Jilin University and patient informed consent was obtained prior to the study.

Literature review

A total of 29 studies (4,12,14-40) which reported TGN caused by bAVMs were retrieved from the PubMed database, the majority of which were clinical reports that described individual cases. We searched the PubMed database up to 2015 using the key words 'AVM', 'bAVM', 'arteriovenous malformation', 'cerebral arteriovenous malformation', 'brain arteriovenous malformation', 'Cerebral vascular malformation' in combination with 'trigeminal neuralgia' and 'TGN'. Abstracts were reviewed to identify relevant literature, only the TGN caused by bAVM related literatures were enrolled.

A total of 40 patients with TGN caused by bAVMs were reported in these 29 studies (Table I; 4,12,14-40). Excluding two patients for whom the information was incomplete (27,33), there were 24 male and 14 female patients (male:female ratio, ~1.71) aged between 23 and 69 years with a mean age of 46.8 \pm 14.7 years. These patients presented with bAVMs located in the CPA (n=19)(12,16,17,20,23,27-33,36,38), cerebellar hemisphere (n=8)(15,18,21,26,34,35,40), the TG nerve (n=7) (22,25,39), the cerebellar vermis (n=3)(4,14,24), the pontine (n=1)(37), the septum pellucidum (n=1)(19) and both the

cerebellar hemisphere and cerebellar vermis (n=1)(38) (Fig. 3). Five of these patients had a confirmed history of repeated hemorrhage (19,29,32,33,35). The majority of these patients suffered from TGN on the same side as the bAVM lesions; however, one patient suffered from TGN on the contralateral side of the bAVMs lesions (40), and two patients suffered from coexistent TGN and hemifacial spasm on the same side (14,16). In terms of treatment, 2 patients received drug therapy (17) and 1 patient was without mention of treatment (12). The other 37 patients received non-drug treatment (4,14-40), 11 patients received surgical resection alone (19,25,27-30,32), 2 patients received surgical resection following partial embolization (23,26), 1 patient received surgical resection following destructive neurosurgical manipulation of the TG nerve(31), 3 patients received surgical resection of bAVMs combined with microvascular decompression (MVD; 14,15,18,20,24), 5 patients received an interventional embolization treatment, 2 patients received radiotherapy following embolization (4,21), 6 patients received MVD treatment alone (37-39), 2 patients received radiotherapy following MVD (36,40), 4 patients received destructive neurosurgical manipulation of the TG nerve (16,17,33,38), and 1 patient received stereotactic radiotherapy (SRS; 22) (Fig. 4).

Discussion

TGN is one of the most common symptoms of neurovascular compression, and is a demyelinating lesion of the sensory fibers of the TG nerve caused by compression of the TG nerve at REZ by the SCA and the AICA (1-4). However, TGN caused by bAVMs remains rare, accounting for 0.22-1.78% of primary TGN cases (12,16,38). The present case study described a case of TGN caused by bAVMs in a middle-aged male patient suffering from recurrent pain in the right cheek. MRI and DSA analyses demonstrated bAVMs in the CPA of the posterior fossa on the affected side. As it remains difficult to distinguishing the symptoms of TGN caused by bAVMs, particularly TGN induced by insignificant bAVMs, which is usually negative in angiography, the symptoms of primary TGN can be easily misdiagnosed (12,25). However, the majority of patients can be accurately diagnosed through MRI and cerebral angiography (4,20,21,36). Previous studies have demonstrated that combined use of three-dimensional (3D) constructive interference in steady state MRI and 3D time of flight angiography clearly demonstrate the anatomic association between the TG nerve and the surrounding vessels, as well as other neighboring structures (41,42). DSA clearly shows the bAVMs, including the feeding arteries, niduses and draining veins, and determines whether they are associated with aneurysms, which is beneficial for the preoperative evaluation of patients (17). Among the 40 previous case reports (4,12,14-40), 39 patients (97.5%) presented with bAVMs in the posterior fossa. bAVMs located in the posterior fossa are more likely to result in TGN (4,12,14-18,20-40). García-Pastor (38) conducted a study on 375 cases of bAVMs, which demonstrated that 1.3% of the patients with bAVMs developed TGN, whereas 9.8% of the patients with bAVMs in the posterior fossa developed TGN. The majority of the patients suffered from TGN on the same side as the bAVMs, and only one patient suffered from TGN on the contralateral side of the lesions, which was predominantly caused by the

Table I. Literature review of patients with trigeminal neuralgia caused by bAVMs.

Author	Gender/age	bAVMs location	History of drug therapy			Non-drug therapy			Notes	Refs.
			Compressing vessels	Drugs	Therapeutic effects	Treatment methods	Complications	Therapeutic effects		
Kikuchi <i>et al</i>	Male/45	CPA	Feeding arteries	Not mentioned	Not mentioned	Resection of bAVMs	Not mentioned	Immediate complete relief	The patient had a history of SAH 15 years prior	(29)
Figueiredo <i>et al</i>	Male/18	CPA	Not mentioned	Not mentioned	Poor	Resection of bAVMs	Transient numbness in V3	Immediate complete relief		(30)
Kawano <i>et al</i>	Male/48	CPA	Malformed niduses and draining veins	Not mentioned	Pain aggravated after 2 years	Glycerol rhizolysis was performed on either side of the semilunar ganglion of the TG nerve, and shown to be ineffective; subsequent resection of the bAVM was performed	Not mentioned	Immediate complete relief		(31,32)
Kawano <i>et al</i>	Female/61	CPA	Not mentioned	Not mentioned	Not mentioned	Resection of bAVMs	Not mentioned	Not mentioned	The patient had a history of hemorrhage in the left CPA 10 days prior to admission to the hospital	(20)
Johnson and Salmon	N/A	CPA	Not mentioned	Not mentioned	Not mentioned	Resection of the TG nerve	Not mentioned	Pain relief	The patient had a history of SAH and multiple events of transient loss of consciousness	(33)
Niwa <i>et al</i>	Female/44	Cerebellar hemisphere	Feeding arteries and draining veins	Not mentioned	Not mentioned	Resection of bAVMs and MVD	Not mentioned	Immediate complete relief		(34)
Nishizawa <i>et al</i>	Male/42	Cerebellar hemisphere	Feeding arteries	Not mentioned	Not mentioned	TGN recurred 6 months after TG nerve was blocked. Resection of the bAVMs and MVD was subsequently performed	Not mentioned	Immediate complete relief	The patient had a history of SAH 10 years prior	(35)

Table I. Continued.

Author	Gender/age	bAVMs location	History of drug therapy			Non-drug therapy			Notes	Refs.
			Compressing vessels	Drugs	Therapeutic effects of pain	Treatment methods	Complications	Therapeutic effects of pain		
Edwards <i>et al</i>	Male/38	Intrinsic TG nerve	Draining veins, malformed niduses, and feeding arteries	Carbamazepine	Poor	Resection of the bAVMs and MVD	Mild V1 hypesthesia	Immediate relief		(25)
	Female/55	Intrinsic TG nerve	Draining veins and malformed niduses	Carbamazepine	Poor	Resection of bAVMs	Mild V1-3 hypesthesia and corneal areflexia	Immediate relief		
	Female/46	Intrinsic TG nerve	Draining veins and malformed niduses	Carbamazepine	Poor	Resection of bAVMs	Mild V1 & V2 hypesthesia and occasional mild dysesthesia	Immediate relief		
	Female/35	Intrinsic TG nerve	Draining veins and malformed niduses	Carbamazepine	Poor	Resection of bAVMs	None	Immediate relief	TGN recurred 4 years later; the be relieved by drugs	
	Female/36	Intrinsic TG nerve	Draining veins and malformed niduses	Carbamazepine	Poor	Resection of bAVMs	Small pontine hematoma, transient ataxia, VII weakness, nausea, vomiting, permanent V2 & V3 anesthesia, V1 hypesthesia, and corneal areflexia	Immediate relief		(26)
Mineura <i>et al</i>	Male/21	Cerebellar hemisphere	Draining veins	Not mentioned	Not mentioned	Embolization and resection of bAVMs	Mild cerebellar ataxia	Complete relief		(27)
Nomura <i>et al</i>	N/A	CPA	Not mentioned	Not mentioned	Not mentioned	Resection of bAVMs	Not mentioned	Complete relief		(27)
	Male/44	CPA	Malformed niduses	Not mentioned	Not mentioned	Resection of bAVMs	Not mentioned	Complete relief		
Mendelowitsch <i>et al</i>	Female/47	CPA	Feeding arteries	Not mentioned	Poor	Resection of bAVMs	Pulmonary embolism	Complete relief		(28)

Table I. Continued.

Author	Gender/age	bAVMs location	Compressing vessels	History of drug therapy		Non-drug therapy			Notes	Refs.
				Drugs	Therapeutic effects of pain	Treatment methods	Complications	Therapeutic effects of pain		
Anderson <i>et al</i>	Female/39	Intrinsic TG nerve CPA	Not mentioned	Not mentioned	Poor	SRS	Not mentioned	Complete relief	(22)	
Wanke <i>et al</i>	Male/56	CPA	Not mentioned	Carbamazepine	Poor	Embolization and resection of bAVMs	Hydrocephalus and SAH occurred after embolization. Surgical resection was subsequently performed. Paresis of the III, VII and XII cranial nerves occurred, and the trigeminal neural sensation was reduced. Every function except the trigeminal neural sensation recovered after 3 months	Complete relief following resection	(23)	
Athanasίου <i>et al</i>	Male/56	Cerebellar vermis CPA	Feeding arteries	Carbamazepine	Little effect	Embolization	None	Complete relief	(24)	
García-Pastor <i>et al</i>	Male/57	CPA	Malformed niduses	Not mentioned	Poor	The effect of radiofrequency thermocoagulation of the TG nerve was poor; micro-balloon compression of the TG nerve was subsequently performed.	Not mentioned	Complete relief	(38)	
	Male/68	CPA	Malformed niduses	Not mentioned	Poor	MVD	Not mentioned	Complete relief		
	Male/40	Cerebellar hemisphere and vermis CPA	Feeding arteries	Not mentioned	Poor	MVD	Not mentioned	Complete relief		
	Male/54	CPA	Malformed niduses	Not mentioned	Poor	MVD	Not mentioned	Complete relief		

Table I. Continued.

Author	Gender/age	bAVMs location	History of drug therapy			Non-drug therapy			Refs.	
			Compressing vessels	Drugs	Therapeutic effects of pain	Treatment methods	Complications	Therapeutic effects of pain		Notes
Levitt <i>et al</i>	Female/13	Cerebellar hemisphere	Not mentioned	Carbamazepine	Poor	Multiple embolization treatments of bAVMs had no effect; the artery of the foramen rotundum (the blood-supplying artery of the TG nerve V2 branch) was subsequently embolized, following which the pain was relieved	A small area of hypesthesia on the left cheek	Immediate relief following embolization of the artery of the foramen rotundum	(18)	
Talanov <i>et al</i>	Male/16	Septum pellucidum	Draining veins	Not mentioned		Resection of bAVMs	None	Not mentioned	Pain on the left side of the TG nerve combined with hemorrhage	(19)
Simon <i>et al</i>	Male/72	CPA	Not mentioned	Carbamazepine	The pain increased after 1 year	Embolization	None	Immediate complete relief. The pain recurred 17 months later; but was relieved following secondary embolization		(20)
Lesley	Male/55	Cerebellar hemisphere	Feeding arteries and draining veins	No history of drug therapy		Staged embolization and SRS	None	Complete relief		(21)
Ferrolli <i>et al</i>	Female/52	Pontine	Draining veins	Carbamazepine	Poor	MVD	None	50% free after 1 month		(37)
	Male/38	Cerebellar hemisphere	Feeding arteries and draining veins	Not mentioned	Poor	Radiofrequency thermocoagulation of TG nerve was poor; MVD was subsequently performed	Not mentioned	Complete relief		
Karibe <i>et al</i>	Male/55	Intrinsic TG nerve	Feeding arteries	Carbamazepine	Little effect	MVD	None	Immediate and complete relief		(39)
Sato <i>et al</i>	Female/49	Cerebellar hemisphere	Draining veins	Not mentioned	Not mentioned	MVD + SRS	None	Complete relief after 1 year. The size of the bAVMs was reduced	The patient had pain on the contralateral TG nerve	(40)

Table I. Continued.

Author	Gender/age	bAVMs location	History of drug therapy			Non-drug therapy			Notes	Refs.
			Compressing vessels	Drugs	Therapeutic effects of pain	Treatment methods	Complications	Therapeutic effects of pain		
Mori <i>et al</i>	Male/69	Cerebellar vermis	Feeding arteries	Carbamazepine	The pain was relieved for 5 years, then gradually reappeared	Embolization and SRS	Temporary truncal ataxia following embolization	Partial relief was achieved following embolization. Complete pain relief was achieved following subsequent radiotherapy	(4)	
Yip <i>et al</i>	Female/64	CPA	Malformed niduses	Carbamazepine	Poor	Not mentioned	None	HFS and TNG was completely relieved	(12)	
Dou <i>et al</i>	Female/24	Cerebellar vermis	Not mentioned	Carbamazepine	Poor	Embolization	None	The pain was completely relieved after 1 month	(14)	
Kono <i>et al</i>	Male/53	Cerebellar hemisphere	Feeding arteries	Anti-TN medication	The pain increased gradually	Embolization	None	The pain was completely relieved after 1 month	(15)	
Son <i>et al</i>	Male/42	CPA	Not mentioned	Non-specific	Poor	Radiofrequency thermocoagulation of TG nerve and injection of carnitine	None	The pain was relieved; carnitine was regularly injected to relieve facial spasm (every 3-4 months)	(16)	
Machet <i>et al</i>	Male/61	CPA	Not mentioned	Oxcarbazepine	Follow-up was conducted for 10 months; the pain was relieved	None	Not mentioned		(17)	
Sumioka <i>et al</i>	Male/66	CPA	Feeding arteries and malformed niduses	Not mentioned		MVD + SRS	Not mentioned	Immediate complete relief. MRI showed that the bAVMs disappeared	(36)	
	Female/64	CPA	Not mentioned	Carbamazepine	Follow-up was conducted for 18 months; the pain was relieved	None	Not mentioned			
	Male/50	CPA	Not mentioned	Carbamazepine	The pain was partially relieved	Micro-balloon compression of the TG nerve	Not mentioned	Pain partially disappeared		

TGN, trigeminal neuralgia; CPA, cerebellopontine angle; N/A, not available; bAVMs, brain arteriovenous malformations; TG nerve, trigeminal nerve; MVD, microvascular decompression; SRS, stereotactic radiotherapy; HFS, hemifacial spasm; SAH, subarachnoid hemorrhage.

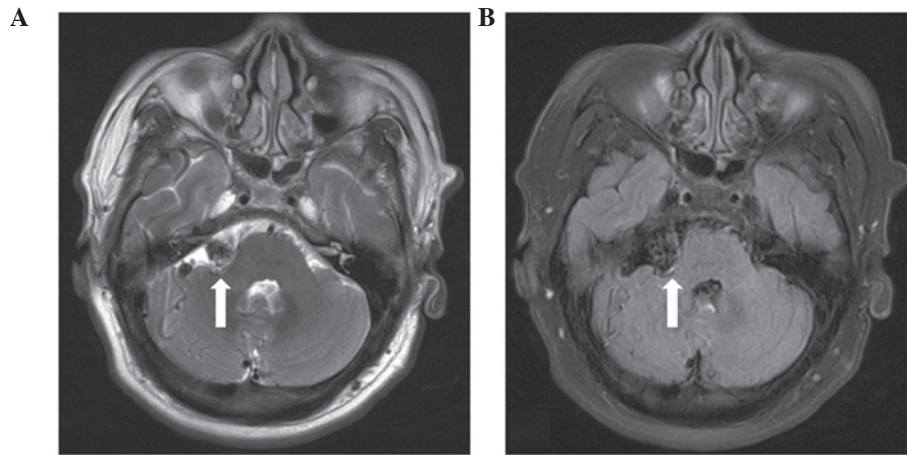


Figure 1. (A) T2-weighted axial MRI and (B) T1-weighted axial MRI showing flow-void signals (arrows) of abnormal vessels in the right cerebellopontine angle prior to the surgical procedure. MRI, magnetic resonance imaging.

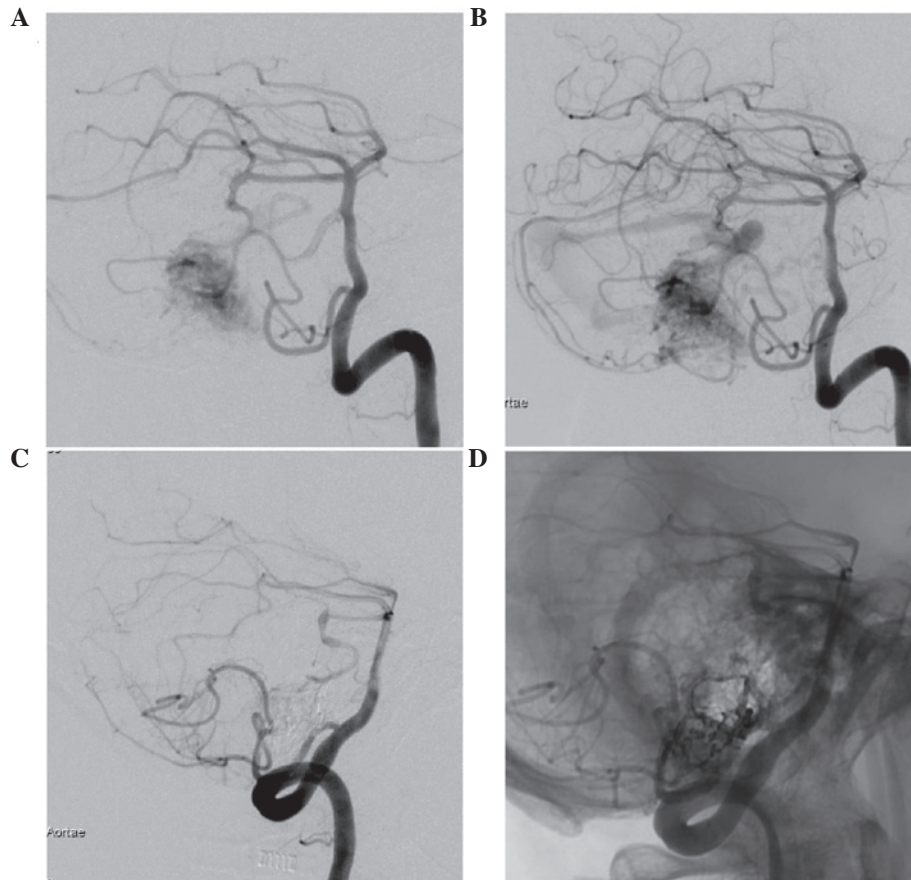


Figure 2. (A and B) Lateral views of DSA prior to embolization shows the bAVMs, which are associated with the right superior cerebellar and the right anterior inferior cerebellar, and draining rapidly into the adjacent venous sinuses on the same side. (C and D) Lateral views of the DSA following embolization show that the majority of the bAVMs were embolized. DSA, digital subtraction angiography; bAVMs, brain arteriovenous malformations.

compression of the contralateral TG nerve REZ by the arterIALIZED draining veins (40). The aforementioned findings also demonstrated that TGN caused by bAVMs is a symptom of neurovascular compression, caused by the pulsatile compression of vessels. Pulsatile compression of the vessels may be caused by the feeding arteries of bAVMs, arterIALIZED draining veins or malformation niduses (38,40,43). Among the 40 patients evaluated (4,12,14-40), there were 27 patients

(4,12,15,19,21,24-29,31,34-40) in whom TGN was demonstrated to originate from vascular compression as determined by angiography or during the surgical procedure. Of these 27 patients, TGN was caused by compression by the feeding arteries of bAVMs ($n=8$)(4,15,24,28,29,35,38,39), the draining venous system ($n=4$)(19,26,37,40), malformation niduses ($n=5$)(12,27,38), simultaneous compression by the feeding arteries and the draining venous system ($n=3$)(21,34,38), simultaneous

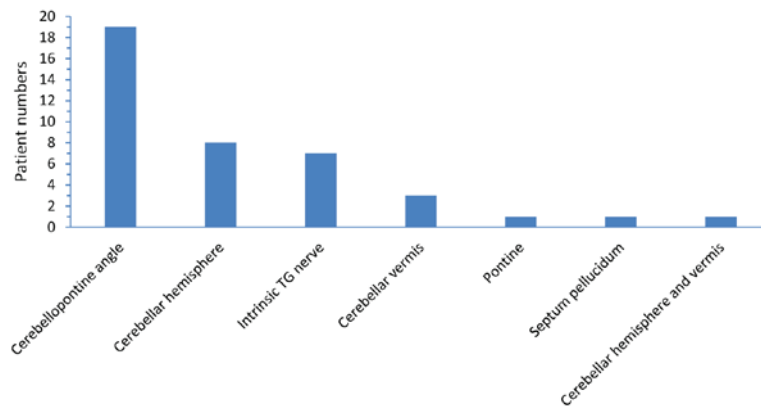


Figure 3. Respective locations of the bAVMs in patients with trigeminal neuralgia caused by bAVMs as reported in previous studies (n=40). bAVMs, brain arteriovenous malformations.

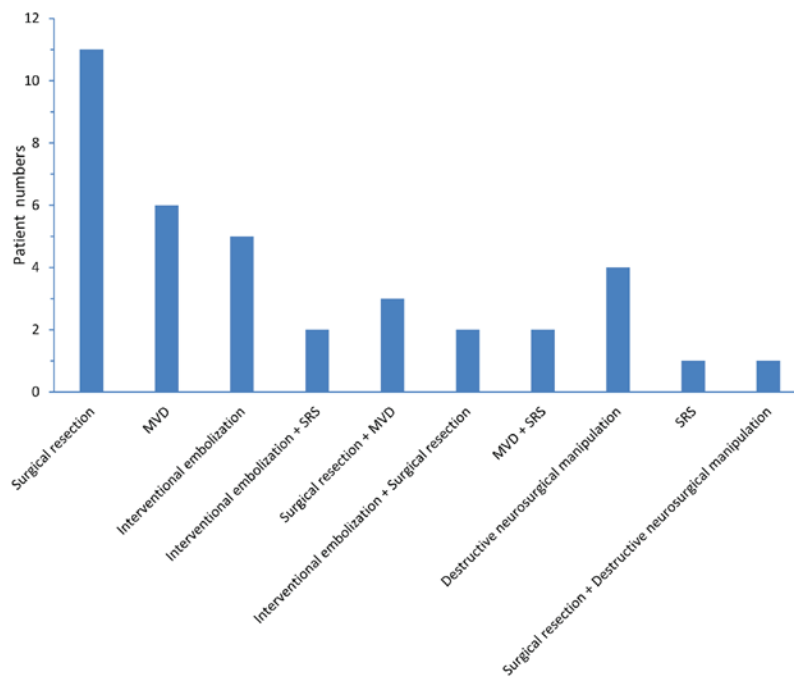


Figure 4. Non-drug treatment methods used for patients with trigeminal neuralgia caused by brain arteriovenous malformations, as reported in previous studies (n=37). MVD, microvascular decompression; SRS, stereotactic radiotherapy.

compression by the feeding arteries and the malformation niduses (n=1)(36), the simultaneous compression by the draining venous system and the malformation niduses (n=5) (25,31) and simultaneous compression by the feeding arteries, the draining venous system and the malformation niduses (n=1) (25). Since the origin of vascular compression could not be confirmed by image analysis in certain patients, and these patients had also received drug therapy, interventional embolization, and destructive neurosurgical manipulation of the TG nerve, the incidence of TGN originating from vascular compression may be even higher.

Currently, the majority of treatments for TGN caused by bAVMs are determined on an individual basis, and there has been no consistent conclusion as to the optimal treatment for TGN caused by bAVMs (14-16). Drug therapy did not yield an ideal therapeutic effect in the majority of cases, and the patients who received drug therapy predominantly proceeded

to seek non-drug treatments (4,12,14-16,22,23,25,28,30-32). Non-drug treatments include surgical resection of bAVMs, MVD, SRS, and destructive neurosurgical manipulation of the TG nerve (4,16,33,36,37). Therefore, when selecting a treatment, it is necessary to comprehensively consider whether the patient has a history of hemorrhage, whether the bAVMs are associated with aneurysms and the origin of the compression of the TG nerve.

Theoretically, complete surgical resection is the ideal therapeutic option, as it eliminates the compression on the TG nerve and avoids the potential risk of hemorrhage of bAVMs, which is particularly important for patients with a history of hemorrhage. In addition, the craniotomy for resection of bAVMs may also confirm whether the feeding arteries and the draining veins compress the TG nerve root; if necessary, MVD can be performed simultaneously (44). Among the 40 patients evaluated (4,12,14-40), 42.5% of the patients

received surgical resection (n=17), and amongst these 17 patients (19,23,25-32,34,35), 11 patients received surgical resection alone (19,25,27-30,32), 3 patients received surgical resection combined with MVD (25,34,35), and 2 patients received surgical resection due to complications following embolization (23,26), and 1 patient received surgical resection due poor effect after destructive neurosurgical manipulation of the TG nerve (31). The pain caused by TGN was immediately relieved in all the patients who received surgical resection. The longest duration of follow-up visits in these previous studies was 109 months (25). According to the long-term follow-up visits reported, relapsed pain was only reported in one patient at a four-year post-surgical follow-up, and this pain was controlled by 400 mg/day carbamazepine (25). The majority of these lesions were located deep in the posterior fossa adjacent to the brain stem and surrounding important nerves (23,26,27). Furthermore, there were numerous complications during surgical resection, particularly for patients with bAVMs in the TG nerve REZ. Edwards *et al* (25) reported the treatment of five patients with bAVMs in the TG nerve REZ through surgical resection, and following the surgical procedure, four of these patients experienced varying levels of dysesthesia of the TG nerve, and one patient also experienced weakening of the facial neurological function, short-term ataxia and cerebellar hematoma. Although the remission rate of TNG is very high after surgical resection, there are also many complications. Thus it is a necessary to weigh the benefits and risks before the operation.

It is sometimes difficult to perform complete surgical resection of bAVMs, and this procedure may also be unnecessary for some patients. Among the 40 patients (4,12,14-40) with TGN caused by bAVMs, 55% of patients (n=22) (4,15,19,21,24-26,28,29,33-40) presented with TGN which partially or completely originated from the compression of feeding arteries or the draining veins, which was confirmed by image analysis or during the surgical procedure. Therefore, surgical resection of bAVMs was unnecessary in these patients with TGN with no history of hemorrhage, and MVD surgery would have been sufficient. MVD surgery of the TG nerve is >90% effective and is capable of preserving neurological function relatively well; thus, MVD surgery has become the first choice of surgical treatment for primary TGN (45). Furthermore, bAVMs in the CPA, and even malformed niduses in the TG nerve, may not necessarily result in TGN (39,43,46). Therefore, focusing on complete resection of bAVMs as the predominant therapeutic option may cause further complications. The mid-term results of a multicenter, randomized control study which investigated the treatments of unruptured bAVMs demonstrated that the effects of drug therapies are superior to those of invasive therapies when treating unruptured bAVMs (47). Among the 40 patients evaluated in the present review (4,12,14-40), 27% of patients (n=11) received MVD surgery, with the longest duration of follow-up being 18 months (36). A 100% overall effective rate was achieved and no surgery-associated complications occurred (34-40).

Interventional embolization can be used to reduce the size of bAVMs by reducing blood supply to bAVMs (4,21,23,26). This procedure is predominantly performed to surgically treat bAVMs or as an adjuvant therapy prior to SRS (4,21,23,26). However, when treating TGN caused by bAVMs, TGN may be

effectively relieved following partial embolization of bAVMs due to the change in hemodynamics, which also demonstrates that TGN caused by bAVMs is a symptom of neurovascular compression (20). Due to these characteristics, interventional embolization was performed on the present patient and TGN was completely relieved following successful embolization of the majority of the bAVMs. Post-embolization follow-ups were conducted for two years, and the therapeutic effect of this treatment option remained satisfactory. Among the 40 patients (4,12,14-40) evaluated in the present review, 22.5% of patients (n=9)(4,14,15,18,20,21,23,24,26) underwent interventional embolization and experienced significantly relieved TGN following embolization. Among these 9 patients, 5 patients received an interventional embolization treatment alone (14,15,18,20,24), 2 patients received subsequent SRS (4,21) and 2 patients received secondary surgical resection(23,26). The longest duration of follow-up visits for patients who underwent interventional embolization was six years (4). One patient reported relapsed pain 17 months post-embolization and the pain was subsequently relieved following a secondary embolization (4). The pain relief may be associated with the blocking of the pulsatile compression of the feeding arteries of the bAVMs, the arterialized draining veins or the malformed niduses that compressed the TG nerve following embolization, which appears to have a similar mechanism to the MVD of the TG nerve. However, caution should be taken with this therapeutic option as interventional embolization and the change in hemodynamics following embolization may induce ischemia, hemorrhage or embolization of the venous system (4,23,26). Among the aforementioned eight patients who received embolization, one patient experienced transient ataxia (4), one patient received secondary surgical resection of bAVMs due to subarachnoid hemorrhage and hydrocephalus following the embolization (23), and one patient suffered from severe paresis and sensory disturbance due to the dilated draining veins following embolization, which required surgical resection (26). Furthermore, since the rate of complete embolization is restricted when treating bAVMs with interventional therapy alone, and post-embolization recanalization is relatively common, embolization alone may not result in a long-term therapeutic effect. Simon *et al* (20) reported the case of a patient with TGN caused by bAVMs whose pain was relieved following embolization; however, the pain recurred 17 months later. It has also been demonstrated that only short-term pain relief was achieved following multiple embolization procedures (18), which may be associated with the recanalization of bAVMs.

SRS is often performed following partial embolization or combined with other treatment methods (4,21,36,40). Among the 40 patients evaluated in the present review (4,12,14-40), there was only one report (22) of the achievement of an effective therapeutic effect of SRS alone. In this case, the bAVMs were located inside the TG nerve and the size of the malformation niduses was ~1.2x0.8x0.9 cm; the TGN was completely relieved following 13 months of SRS (22). Notably, Levitt *et al* (18) treated a patient with TGN by embolizing the supplying artery of the V2 branch of the TG nerve, an artery of the foramen rotundum, which induced sustained relief from TGN, but resulted in hypoesthesia of the cheeks on the same side. Previous studies have also reported other

palliative destructive neurosurgical techniques of the TG nerve root (16,17,33,38), including radiofrequency thermo-coagulation, glycerol rhizolysis, balloon compression and resection of the TG nerve; however, these palliative therapies may result in complications, such as facial numbness and weakened corneal reflexes (16,17,33,38). Furthermore, the therapeutic effects of these palliative therapies remain uncertain, and TGN has a relatively high recurrence rate when treated with these therapeutic strategies (16,17,33,38).

In conclusion, surgical resection of the malformed vessels is an ideal therapeutic option in theory, as this approach relieves TGN and eliminates the risk of hemorrhage of bAVMs; whereas MVD surgery is a recommended treatment for patients who cannot receive surgical resection of bAVMs. Good therapeutic outcomes have also been achieved with interventional embolization in certain patients, including the patient described in the present case study. Destructive neurosurgical manipulation of the TG nerve may result in facial numbness and weakened corneal reflexes, and has a high recurrence rate; therefore, this approach is only recommended as an alternative for elderly surgery-intolerant patients.

References

- Love S and Coakham HB: Trigeminal neuralgia: Pathology and pathogenesis. *Brain* 124: 2347-2360, 2001.
- Cruccu G, Gronseth G, Alksne J, Argoff C, Brainin M, Burchiel K, Nurmikko T and Zakrzewska JM; American Academy of Neurology Society; European Federation of Neurological Society: AAN-EFNS guidelines on trigeminal neuralgia management. *Eur J Neurol* 15: 1013-1028, 2008.
- Headache Classification Committee of the International Headache Society (IHS): The international classification of headache disorders, 3rd edition (beta version). *Cephalalgia* 33: 629-808, 2013.
- Mori Y, Kobayashi T, Miyachi S, Hashizume C, Tsugawa T and Shibamoto Y: Trigeminal neuralgia caused by nerve compression by dilated superior cerebellar artery associated with cerebellar arteriovenous malformation: Case report. *Neurol Med Chir (Tokyo)* 54: 236-241, 2014.
- Ishikawa M, Nishi S, Aoki T, Takase T, Wada E, Ohwaki H, Katsuki T and Fukuda H: Operative findings in cases of trigeminal neuralgia without vascular compression: Proposal of a different mechanism. *J Clin Neurosci* 9: 200-204, 2002.
- McLaughlin MR, Jannetta PJ, Clyde BL, Subach BR, Comey CH and Resnick DK: Microvascular decompression of cranial nerves: Lessons learned after 4400 operations. *J Neurosurg* 90: 1-8, 1999.
- Mast H, Young WL, Koennecke H-C, et al: Risk of spontaneous haemorrhage after diagnosis of cerebral arteriovenous malformation. *The Lancet* 350: 1065-1068, 1997.
- Nataraj A, Mohamed MB, Gholkar A, Vivar R, Watkins L, Aspoas R, Gregson B, Mitchell P and Mendelow AD: Multimodality treatment of cerebral arteriovenous malformations. *World Neurosurg* 82: 149-159, 2014.
- Whitehead KJ, Smith MC and Li DY: Arteriovenous malformations and other vascular malformation syndromes. *Cold Spring Harb Perspect Med* 3: a006635, 2013.
- Rodríguez-Hernández A, Kim H, Pourmohamad T, Young WL and Lawton MT; University of California, San Francisco Arteriovenous Malformation Study Project: Cerebellar arteriovenous malformations: Anatomic subtypes, surgical results, and increased predictive accuracy of the supplementary grading system. *Neurosurgery* 71: 1111-1124, 2012.
- Mast H, Young WL, Koennecke HC, Sciacca RR, Osipov A, Pile-Spellman J, Haccin-Bey L, Duong H, Stein BM and Mohr JP: Risk of spontaneous haemorrhage after diagnosis of cerebral arteriovenous malformation. *Lancet* 350: 1065-1068, 1997.
- Yip V, Michael BD, Nahser HC and Smith D: Arteriovenous malformation: a rare cause of trigeminal neuralgia identified by magnetic resonance imaging with constructive interference in steady state sequences. *QJM: monthly journal of the Association of Physicians* 105: 895-898, 2012.
- Seldinger SI: Catheter replacement of the needle in percutaneous arteriography: a new technique. *Acta Radiol* 39: 368-376, 1953.
- Dou NN, Hua XM, Zhong J and Li ST: A successful treatment of coexistent hemifacial spasm and trigeminal neuralgia caused by a huge cerebellar arteriovenous malformation: A case report. *J Craniofac Surg* 25: 907-910, 2014.
- Kono K, Matsuda Y and Terada T: Resolution of trigeminal neuralgia following minimal coil embolization of a primitive trigeminal artery associated with a cerebellar arteriovenous malformation. *Acta Neurochir (Wien)* 155: 1699-1701, 2013.
- Son BC, Kim DR, Sung JH and Lee SW: Painful tic convulsif caused by an arteriovenous malformation. *Clin Neuroradiol* 22: 365-369, 2012.
- Machet A, Aggour M, Estrade L, Chays A and Pierot L: Trigeminal neuralgia related to arteriovenous malformation of the posterior fossa: Three case reports and a review of the literature. *J Neuroradiol* 39: 64-69, 2012.
- Levitt MR, Ramanathan D, Vaidya SS, Hallam DK and Ghodke BV: Endovascular palliation of AVM-associated intractable trigeminal neuralgia via embolization of the artery of the foramen rotundum. *Pain Med* 12: 1824-1830, 2011.
- Talanov AB, Filatov Iu M, Eliava ShSh, Novikov AE and Kulishova IaG: Arteriovenous malformation of septum pellucidum in combination with persistent trigeminal neuralgia. *Zh Vopr Neirokhir Im N N Burdenko* 50-53; discussion 53-54, 2009 (In Russian).
- Simon SD, Yao TL, Rosenbaum BP, Reig A and Mericle RA: Resolution of trigeminal neuralgia after palliative embolization of a cerebellopontine angle arteriovenous malformation. *Cent Eur Neurosurg* 70: 161-163, 2009.
- Lesley WS: Resolution of trigeminal neuralgia following cerebellar AVM embolization with Onyx. *Cephalalgia* 29: 980-985, 2009.
- Anderson WS, Wang PP and Rigamonti D: Case of microarteriovenous malformation-induced trigeminal neuralgia treated with radiosurgery. *J Headache Pain* 7: 217-221, 2006.
- Wanke I, Dietrich U, Oppel F and Puchner MJ: Endovascular treatment of trigeminal neuralgia caused by arteriovenous malformation: Is surgery really necessary? *Zentralbl Neurochir* 66: 213-216, 2005.
- Athanasioiu TC, Nair S, Coakham HB and Lewis TT: Arteriovenous malformation presenting with trigeminal neuralgia and treated with endovascular coiling. *Neurol India* 53: 247-248, 2005.
- Edwards RJ, Clarke Y, Renowden SA and Coakham HB: Trigeminal neuralgia caused by microarteriovenous malformations of the trigeminal nerve root entry zone: Symptomatic relief following complete excision of the lesion with nerve root preservation. *J Neurosurg* 97: 874-880, 2002.
- Mineura K, Sasajima H, Itoh Y, Kowada M, Tomura N and Goto K: Development of a huge varix following endovascular embolization for cerebellar arteriovenous malformation. A case report. *Acta Radiol* 39: 189-192, 1998.
- Nomura T, Ikezaki K, Matsushima T and Fukui M: Trigeminal neuralgia: Differentiation between intracranial mass lesions and ordinary vascular compression as causative lesions. *Neurosurg Rev* 17: 51-57, 1994.
- Mendelowitsch A, Radue EW and Gratzl O: Aneurysm, arteriovenous malformation and arteriovenous fistula in posterior fossa compression syndrome. *Eur Neurol* 30: 338-342, 1990.
- Kikuchi K, Kamisato N, Sasanuma J, Watanabe K and Kowada M: Trigeminal neuralgia associated with posterior fossa arteriovenous malformation and aneurysm fed by the same artery. Case report. *Neurol Med Chir (Tokyo)* 30: 918-921, 1990 (In Japanese).
- Figueiredo PC, Brock M, De Oliveira AM Júnior and Prill A: Arteriovenous malformation in the cerebellopontine angle presenting as trigeminal neuralgia. *Arq Neuropsiquiatr* 47: 61-71, 1989.
- Kawano H, Hayashi M, Kobayashi H, Tsuji T, Kabuto M and Kubota T: Gas CT cisternography of trigeminal neuralgia caused by AVM of the cerebellopontine angle. *AJNR Am J Neuroradiol* 8: 161-162, 1987.
- Kawano H, Kobayashi H, Hayashi M, Tsuji T, Kabuto M and Nozaki J: Trigeminal neuralgia caused by arteriovenous malformation of the cerebellopontine angle-report of two cases. *No to Shinkei* 36: 1175-1179, 1984 (In Japanese).

33. Johnson MC and Salmon JH: Arteriovenous malformation presenting as trigeminal neuralgia. Case report. *J Neurosurg* 29: 287-289, 1968.
34. Niwa J, Yamamura A and Hashi K: Cerebellar arteriovenous malformation presenting as trigeminal neuralgia. *No Shinkei Geka* 16: 753-756, 1988 (In Japanese).
35. Nishizawa Y, Tsuiki K, Miura K, Murakami M, Kirikae M, Hakozaiki S, Saiki I and Kanaya H: Multiple arteriovenous malformations of left parietal lobe and left cerebellar hemisphere with symptomatic trigeminal neuralgia: A case report. *No Shinkei Geka* 16 (Suppl 5): S625-S630, 1988 (In Japanese).
36. Sumioka S, Kondo A, Tanabe H and Yasuda S: Intrinsic arteriovenous malformation embedded in the trigeminal nerve of a patient with trigeminal neuralgia. *Neurol Med Chir (Tokyo)* 51: 639-641, 2011.
37. Ferroli P, Acerbi F, Broggi M and Broggi G: Arteriovenous micromalformation of the trigeminal root: Intraoperative diagnosis with indocyanine green videoangiography: Case report. *Neurosurgery* 67 (3 Suppl Operative): onsE309-onsE310; discussion onsE310, 2010.
38. García-Pastor C, López-González F, Revuelta R and Nathal E: Trigeminal neuralgia secondary to arteriovenous malformations of the posterior fossa. *Surg Neurol* 66: 207-211; discussion 211, 2006.
39. Karibe H, Shirane R, Jokura H and Yoshimoto T: Intrinsic arteriovenous malformation of the trigeminal nerve in a patient with trigeminal neuralgia: Case report. *Neurosurgery* 55: 1433, 2004.
40. Sato K, Jokura H, Shirane R, Akabane T, Karibe H and Yoshimoto T: Trigeminal neuralgia associated with contralateral cerebellar arteriovenous malformation. Case illustration. *J Neurosurg* 98: 1318, 2003.
41. Garcia M, Naraghi R, Zumbrunn T, Rösch J, Hastreiter P and Dörfler A: High-resolution 3D-constructive interference in steady-state MR imaging and 3D time-of-flight MR angiography in neurovascular compression: A comparison between 3T and 1.5T. *AJNR Am J Neuroradiol* 33: 1251-1256, 2012.
42. Linn J, Moriggl B, Schwarz F, Naidich TP, Schmid UD, Wiesmann M, Bruckmann H and Yousry I: Cisternal segments of the glossopharyngeal, vagus, and accessory nerves: Detailed magnetic resonance imaging-demonstrated anatomy and neurovascular relationships. *J Neurosurg* 110: 1026-1041, 2009.
43. Krischek B, Yamaguchi S, Sure U, Benes L, Bien S and Bertalanffy H: Arteriovenous malformation surrounding the trigeminal nerve-case report. *Neurol Med Chir (Tokyo)* 44: 68-71, 2004.
44. Abla AA, Nelson J, Rutledge WC, Young WL, Kim H and Lawton MT: The natural history of AVM hemorrhage in the posterior fossa: Comparison of hematoma volumes and neurological outcomes in patients with ruptured infra- and supratentorial AVMs. *Neurosurg Focus* 37: E6, 2014.
45. Zakrzewska JM and Linskey ME: Trigeminal neuralgia. *Clin Evid (Online)* 10: 1207, 2014.
46. Maher CO, Atkinson JL and Lane JI: Arteriovenous malformation in the trigeminal nerve. Case report. *J Neurosurg* 98: 908-912, 2003.
47. Mohr JP, Parides MK, Stapf C, Moquete E, Moy CS, Overbey JR, Al-Shahi Salman R, Vicaut E, Young WL, Houdart E, *et al*: Medical management with or without interventional therapy for unruptured brain arteriovenous malformations (ARUBA): A multicentre, non-blinded, randomised trial. *Lancet* 383: 614-621, 2014.