

Ruptured Spleen Following Laparoscopic Cholecystectomy

Daniel Leff, MRCS, Mei Nortley, MBBS, Lucy Melly, MBBS, Rajinder P Bhutiani, MS, FRCS

ABSTRACT

Background: Laparoscopic cholecystectomy is generally a safe and well-accepted procedure. However, in a small percentage of patients, it is associated with complications, such as bleeding and injury to the bile duct and other viscera. Splenic injury as a result of laparoscopic surgery has been reported only in the context of direct trauma, for example due to retraction in hand-assisted urologic surgery. To date, there have been no reported cases of patients requiring splenectomy following laparoscopic cholecystectomy. We report an unusual case of ruptured spleen presenting less than 28 days following “uncomplicated” laparoscopic cholecystectomy.

Results: A 52-year-old female presented to our Accident and Emergency department 3 weeks following “uncomplicated” laparoscopic cholecystectomy, complaining of severe left upper quadrant pain radiating to the left shoulder tip. Clinical examination revealed a patient in hypovolemic shock, with localized left upper quadrant peritonism. Abdominal computed tomography supported a diagnosis of splenic rupture, and the patient required an emergency splenectomy.

Discussion: Splenic injury rarely complicates laparoscopic cholecystectomy. We postulate that either congenital or posttraumatic adhesions of the parietal peritoneum to the spleen may have caused the capsule to tear away from the spleen when the pneumoperitoneum was established, resulting in subcapsular hematoma and subsequent rupture in this patient. Videoscopic assessment of the spleen at the end of laparoscopic cholecystectomy

might be a worthwhile exercise to aid early recognition and management in such cases.

Key Words: Splenic injury, Ruptured spleen, Laparoscopy, Laparoscopic cholecystectomy.

INTRODUCTION

Elective laparoscopic cholecystectomy is the treatment of choice for cholecystitis with cholelithiasis and a common general surgical procedure performed in the United Kingdom. Despite being a safe and well-tolerated procedure, elective laparoscopic cholecystectomy can be complicated by bleeding, infection, common bile duct injury, retained gallstones, persistent pain, and more rarely damage to the bowel and other viscera. Solid organ injury as a result of videoscopic surgery, per se, is a rare phenomenon, but isolated reports do exist in the literature. For example, Hedican,¹ outlined the risks of splenic injury associated with hand-assisted laparoscopic urologic surgery, and Janes et al² witnessed bleeding from the splenic pedicle in a patient 24 hours following routine colonoscopy. Zyromski,³ reported a case of splenic injury in a 33-year-old female secondary to endoscopic retrograde cholangiopancreatography and noted significant delays in the time to diagnosis in similar reported cases. Injury to the spleen specifically as a consequence of laparoscopic cholecystectomy on the other hand has only been reported in the literature on 2 occasions. Kienzle⁴ noted that one case, “a lesion of the splenic capsule” following laparoscopic cholecystectomy, had been brought to the Expert Commission for medical malpractice but was ultimately ruled as nonmalpractice. Mrksic et al⁵ site splenic injury as a potential complication of trocar insertion but quote a series in which a case was complicated by a subcapsular hematoma of the liver.⁶ An extensive literature search failed to identify case studies in which a patient had required a splenectomy following a laparoscopic cholecystectomy. We present an unusual case of a patient requiring an emergency splenectomy for a ruptured subcapsular hematoma less than 28 days following an “uncomplicated” elective laparoscopic cholecystectomy for cholelithiasis.

Department of General Surgery, Central Middlesex Hospital London, UK (Drs Leff, Nortley, Bhutiani).

Department of Surgical Oncology and Technology, Imperial College, St Mary's Campus, London, UK (Dr Leff).

Department of Histopathology, Northwick Park Hospital, London, UK (Dr Melly).

Address reprint requests to: Mr Rajinder P Bhutiani, Consultant General Surgeon, Department of General Surgery, North West London Hospitals NHS Trust, Northwick Park and Central Middlesex Hospitals, Watford Road, Harrow, Middlesex, United Kingdom. Telephone: 07762137050, Fax: 0208 421 0907, E-mail: Bhutiani@aol.com

© 2007 by JSLs, *Journal of the Society of Laparoendoscopic Surgeons*. Published by the Society of Laparoendoscopic Surgeons, Inc.

METHODS

A 52-year-old lady presented to our Accident and Emergency department with a 2-day history of agonizing constant left upper quadrant pain radiating to the left shoulder (Kehr's sign). The pain was exacerbated by both movement and deep inspiration and was associated with abdominal distension, nausea, and anorexia. Relevant past medical history included intravenous drug abuse, well-controlled complex partial seizures, and hepatitis C. She was noted to be taking methadone 60 mg and carbamazepine 200 mg per day.

She had undergone an elective laparoscopic cholecystectomy as an outpatient procedure for cholelithiasis some 3 weeks before this presentation. The operation notes reflect a standard 4-port "uncomplicated" laparoscopic cholecystectomy. There was no record of the patient having suffered any trauma during surgery or on transfer to the recovery unit. The postoperative records revealed that she had complained of pain soon after the operation, which was described as being "out of proportion" to the pain experienced by other patients who had undergone laparoscopic cholecystectomy by the same surgeon on the same day.

One week following the operation, she presented to her general practitioner complaining of marked upper abdominal pain. An abdominal ultrasound scan at that time reported a thick-walled cystic mass with some internal echoes in the right upper quadrant measuring 5.6 cm by 5.8 cm consistent with a postoperative collection. All internal organs including the spleen were reported to be normal. The patient was reassured and discharged back to the care of her general practitioner. However, she continued to complain of pain in the left upper quadrant exacerbated on movement, which forced her to stay in bed.

On presentation, she was in hypovolemic shock, with a pulse of 120 beats/minute, thready and low volume, a blood pressure of 90/50 mm Hg with cold and clammy peripheries. She was noted to have a distended abdomen with left upper quadrant tenderness, guarding, and rebound tenderness. Her hemoglobin was 7.8 g/dL, and arterial blood gas analysis revealed a well-compensated metabolic acidosis [pH 7.46, pO₂ 10.9 KPa, pCO₂ 3.4 Kpa, HCO₃ 18.5 mmol/L]. In addition, her inflammatory markers were elevated with a WBC of 17.7 x 10⁹/L and a CRP of 32 mg/L. Liver function tests were essentially normal aside from an isolated raised alkaline phosphatase (ALP=225 IU/L).

An erect chest x-ray revealed an elevated left hemidia-

phragm. An urgent CT scan of the abdomen was requested, and this revealed a heterogeneous poorly enhancing soft tissue mass in the left upper quadrant inseparable from the spleen, measuring 11 cm by 13 cm, associated with a large volume of free intraperitoneal fluid highly suggestive of splenic rupture (**Figure 1**). At emergency laparotomy, the spleen was completely denuded off the capsule as seen in cases of ruptured subcapsular hematoma. A splenectomy was performed following which the patient made a full and uneventful recovery. The histology revealed subcapsular hematoma and normal architectural splenic pulp (**Figure 2**).

RESULTS

She was discharged home approximately one week following splenectomy, having received the standard vaccinations against encapsulated organisms (pneumococcal, meningococcal, and haemophilus influenza vaccinations) a medic-alert bracelet, advice regarding meticulous hygiene and prompt management of infections, in addition to oral penicillin V 250 mg twice daily dosing for life.

DISCUSSION

This represents a rare case of a ruptured splenic subcapsular hematoma presenting 3 weeks following laparoscopic cholecystectomy. Splenic injury following laparoscopic cholecystectomy has only been cited in the

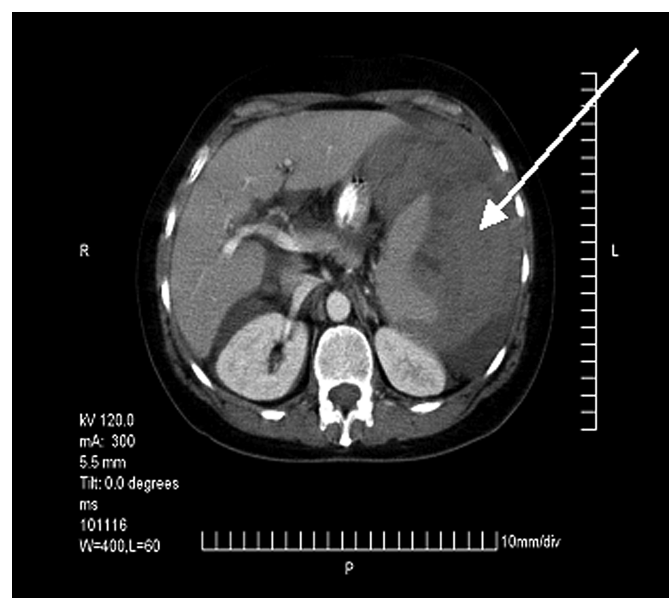


Figure 1. Transaxial computed tomographic scan image. The white arrow points to the 11 cm x 13 cm splenic hematoma.

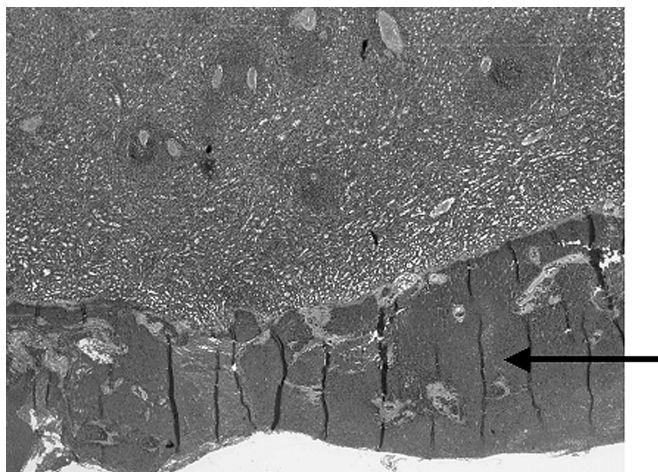


Figure 2. The section shows normal architectural splenic pulp with a black arrow pointing to the subcapsular hematoma.

literature on 2 previous occasions, and to our knowledge this case represents the first, in which the patient underwent an emergency splenectomy.

In our opinion, it is unlikely that the patient suffered direct trauma at the time of the laparoscopic cholecystectomy, either due to laparoscopic trocar insertion or inadvertent injury caused by the laparoscopic instruments as has previously been reported. Such an eventuality would have

led to profound bleeding at the time of surgery or indeed the development of hypovolemic shock in the early post-operative period. It is conceivable that this patient had some adhesions of the splenic capsule to the parietal peritoneum; either congenital or secondary to an episode of minor prior trauma, which may have gone unnoticed. In such a circumstance, establishing pneumoperitoneum at the start of the laparoscopic cholecystectomy may have caused the splenic capsule to stretch resulting in a small subcapsular hematoma, which continued to enlarge over the subsequent weeks ultimately causing a delayed rupture. This is consistent with the operative and histological findings. There was certainly no history of significant trauma in the intervening period to account for coincidental traumatic rupture. In fact, despite repeated questioning, the patient denied any postoperative trauma to the abdomen of any kind and stated, “I was too ill to even get out of bed.”

An alternative explanation is that this case represents a rare case of atraumatic spontaneous splenic rupture, the causes of which are summarized in **Table 1**. Spontaneous splenic rupture is a rare condition that is typically associated with either an infectious cause or as a result of hematological disease, or amyloidosis. The existence of spontaneous idiopathic rupture as an entity has been widely debated, ever since the first case was reported in 1874⁷ by English surgeon

Table 1.
Atraumatic Causes of Splenic Rupture^{11,12}

Spontaneous		Normal Size/Histology of the Spleen	
Pathological		Abnormal Size/Histology of the Spleen	
Infections	Neoplastic	Miscellaneous	Hematological
Infectious mononucleosis	Lymphoma	Sarcoidosis	Hemophilia
Viral Hepatitis	Leukemia	Amyloidosis	Hemolytic anaemia
Actinomycosis	Myeloid metaplasia	Gaucher's disease	Felty's syndrome
Malaria	Metastatic cancer	Crohn's disease	
Acute sepsis	Peliosis	Periarteritis nodosa	
Kalazar	Sarcoma	Splenic infarct	
Salmonella	Multiple myeloma	Splenic congestion	
Typhoid fever	Polycythemia	Splenic vein thrombosis	
Tuberculosis		Portal vein thrombosis	
Brucellosis		Systemic Lupus Erythematosus	
Syphilis		Pregnancy	
Echinococcus		Pancreatitis	
Yaws		Gastric ulcer	

Atkinson. Some authors conclude that spontaneous rupture only occurs in the diseased spleen.⁸ Orloff and Peskin⁹ reviewed all cases of spontaneous splenic rupture published in the English literature before 1958. Using specific criteria (**Table 2**), they were able to conclude that “a small number of cases which, when subjected to careful scrutiny, defy any conclusion other than that they represent instances of spontaneous rupture of the normal spleen.”⁹ A number of theories have been put forward to explain such idiopathic rupture, ranging from reflex spasms of the splenic vein producing congestion with subsequent rupture, to abnormal mobility of the spleen that undergoes repeated episodes of torsion.

The fact that both macroscopic and microscopic appearance of the spleen remains normal in such cases has led to a suggestions that isolated disease in the segment of rupture is to blame, and thus all pathological changes are destroyed.

Interestingly, there has been a reported case of spontaneous splenic rupture secondary to acute hepatitis A,¹⁰ but we were unable to find similar reports of such a presentation specifically associated with hepatitis C in the absence of advanced cirrhosis and portal hypertension. Histological examination of our patient’s spleen showed no intrinsic pathology, and we would tend to rule out similar pathological rupture as a cause in our patient. It is possible, though difficult to confirm, that the patient’s hepatic disease may have adversely affected the spleen and made it more prone to minor trauma, and this would certainly make spontaneous rupture as defined by Orloff and Peskin less likely.

Table 2.

Orloff and Peskin’s Criteria for Spontaneous Rupture of a Normal Spleen

On thorough questioning, either before operation or in retrospect after operation, there should be no history of trauma or unusual effort that could injure the spleen.

There should be no evidence of disease in organs other than the spleen that is known to affect the spleen adversely and thereby could cause it to rupture.

There should be no perisplenic adhesions or scarring of the spleen that suggests that it has been traumatized previously.

Other than the findings of hemorrhage and rupture, the spleen should be normal on both gross and histological examination.

CONCLUSION

Given the temporal proximity to the previous surgery and the fact that histological inspection revealed no intrinsic pathological abnormality of the spleen, it is most plausible that this represents a genuine complication of the laparoscopic cholecystectomy, and although rare, it could easily have cost the patient her life. We suggest that visualization of the spleen at the end of laparoscopic cholecystectomy might prove a worthwhile exercise to ensure early recognition and management of such cases.

References:

1. Hedican SP. Complications of hand-assisted laparoscopic urologic surgery. *J Endourol.* 2004;18(4):387–396.
2. Janes SE, Cowan IA, Dijkstra B. A life threatening complication after colonoscopy. *BMJ.* 2005;330(7496):889–890.
3. Zyromski NJ, Camp CM. Splenic injury: a rare complication of endoscopic retrograde cholangiopancreatography. *Am Surg.* 2004;70(8):737–739.
4. Kienzle HF. Malpractice in laparoscopic cholecystectomy. Results of cases recently considered by the Expert Commission [in German]. *Zentralbl Chir.* 1999;124(6):535–541.
5. Mrksic MB, Farkas E, Cabafi Z, Komlos A, Sarac M. Complications in laparoscopic cholecystectomy [in Croatian]. *Med Pregl.* 52(6–8):253–257, 1999.
6. Nathanson LK, Shimi S, Cuschieri A. Laparoscopic cholecystectomy: the Dundee technique. *Br J Surg.* 1991;78(2):155–159.
7. Atkinson E. Death from idiopathic rupture of the spleen. *BMJ.* 1874;2:403–404.
8. Wright LT, Prigot A. Traumatic subcutaneous rupture of the normal spleen. *Arch Surg.* 1939;39:551–576.
9. Orloff MJ, Peskin GW. Spontaneous rupture of the normal spleen; a surgical enigma. *Surg Gynecol Obstet.* 1958;106(1):1–11.
10. Van Landingham SB, Rawls DE, Roberts JW. Pathological rupture of the spleen associated with hepatitis A. *Arch Surg.* 1984;119(2):224–225.
11. Baert D, Burvenich P, Lagae J. Occult splenic rupture: a case report. *Acta Clin Belg.* 1999;54(3):169–171.
12. Lieberman ME, Levitt MA. Spontaneous rupture of the spleen: a case report and literature review. *Am J Emerg Med.* 1989;7(1):28–31.