



Contents lists available at ScienceDirect

International Journal of Surgery Case Reports

journal homepage: www.casereports.com

Osteosarcoma of the rib: A challenge of diagnosis and surgical intervention: A case report

Suprayitno Wardoyo^a, Achmad Fauzi Kamal^b, Muhammad Aris Furqon^{c,*}, Jonathan Grantomo^c, Witantra Dhamar Hutami^d

^a Division of Cardiothoracic and Vascular Surgery, Department of Surgery, Faculty of Medicine, Universitas Indonesia/Cipto Mangunkusumo General Hospital, Jakarta, Indonesia

^b Department of Orthopedics and Traumatology, Universitas Indonesia/Cipto Mangunkusumo General Hospital, Jakarta, Indonesia

^c Resident of Cardiothoracic and Vascular Surgery, Faculty of Medicine, Universitas Indonesia/Cipto Mangunkusumo General Hospital, Jakarta, Indonesia

^d Resident of Orthopaedic and Traumatology, Universitas Indonesia/Cipto Mangunkusumo General Hospital, Jakarta, Indonesia

ARTICLE INFO

Article history:

Received 21 February 2021

Received in revised form 13 March 2021

Accepted 14 March 2021

Available online 16 March 2021

Keywords:

Chest wall tumour

Osteosarcoma of the ribs

Chest wall reconstruction

ABSTRACT

INTRODUCTION AND IMPORTANCE: Chest wall tumour could grow from various tissues composing the chest wall. Diagnosis and treatment of patients with chest wall tumour pose several challenges.

CASE PRESENTATION: We present a case of 55 year old woman with chief complaint of a painfull mass on her chest wall. Patient was diagnosed with osteosarcoma of the ribs. Patient underwent surgery and was hospitalized for seven days before discharged.

CLINICAL DISCUSSION: Osteosarcoma of the ribs is a rare case with wide resection as the main treatment. In this case, chest wall reconstruction was needed to prevent impaired chest wall mechanical function in respiration.

CONCLUSION: Diagnosis and treatment of osteosarcoma of the ribs pose challenges. The main treatment of the osteosarcoma of the ribs is wide resection, followed by reconstruction of chest wall when needed. Reconstruction could be performed with autologous tissue, gore-tex, and mesh. The adjuvant chemotherapy was considered to give for better outcome.

© 2021 The Authors. Published by Elsevier Ltd on behalf of IJS Publishing Group Ltd. This is an open access article under the CC BY-NC-ND license (<http://creativecommons.org/licenses/by-nc-nd/4.0/>).

1. Introduction

Chest wall tumour could grow from various tissues composing the chest wall. Tissues such as bones, connective tissue, adipose tissue, blood vessels, nerve, cartilage, and muscles could be the origin of tumour cells. The incidence of malignancy of the bones and joints is 0.9 per 100,000 people per year [1]. Diagnosis and treatment of patients with chest wall tumour pose several challenges.

In this care report, we elaborate our experience in treating a 55 year old woman with chief complaint of a painful mass on her chest wall. Patient was diagnosed with osteosarcoma of the ribs. Patient underwent surgery and was hospitalized for seven days before discharged.

2. Presentation of case

A 55-year-old woman came to our clinic complaining of a mass on her left chest wall. Initially, the mass was small and unpainful,

but since six months before admission, she started to feel pain on her left chest. Patient had sought medical treatment and had been evaluated for heart disease, but no abnormalities was found. No history of smoking.

Upon physical examination, a 6 × 6 cm mass was found on left lateral chest wall. The mass was fixed to the chest wall with clear borders and hard consistency. There was no sign of inflammation on the lump.

Chest radiographs showed destruction of the fourth ribs and surrounding soft tissue. Bone lesion was suspected. No pleural effusion was seen (Fig. 1). Computed tomography (CT) scan showed 5.5 × 5.3 cm destruction of the fourth ribs and surrounding soft tissue with contrast enhancement and intralesional calcification (Fig. 2). Blood tests showed no significant abnormality beside increased phosphatase alkali (353 U/L).

Biopsy and preoperative histopathology examination result indicated that the tumour was consistent with osteosarcoma (Fig. 3). In our clinical and pathological conference, the team decided to do wide surgical resection and reconstruction of the chest wall, and followed by adjuvant chemotherapy.

Surgery was performed by an expert team of surgical orthopedic oncologists and thoracic surgeons. Patient was put in supine position and then aseptic and antiseptic procedures were performed on the surgical field. Tumour was identified and dissected from

* Corresponding author at: Division of Thoracic, Cardiac, and Vascular Surgery, Cipto Mangunkusumo Hospital, Faculty of Medicine, University of Indonesia, Jalan Diponegoro No. 71, Senen, Jakarta Pusat, DKI Jakarta, 10430, Indonesia.

E-mail address: muhammad.aris01@ui.ac.id (M.A. Furqon).

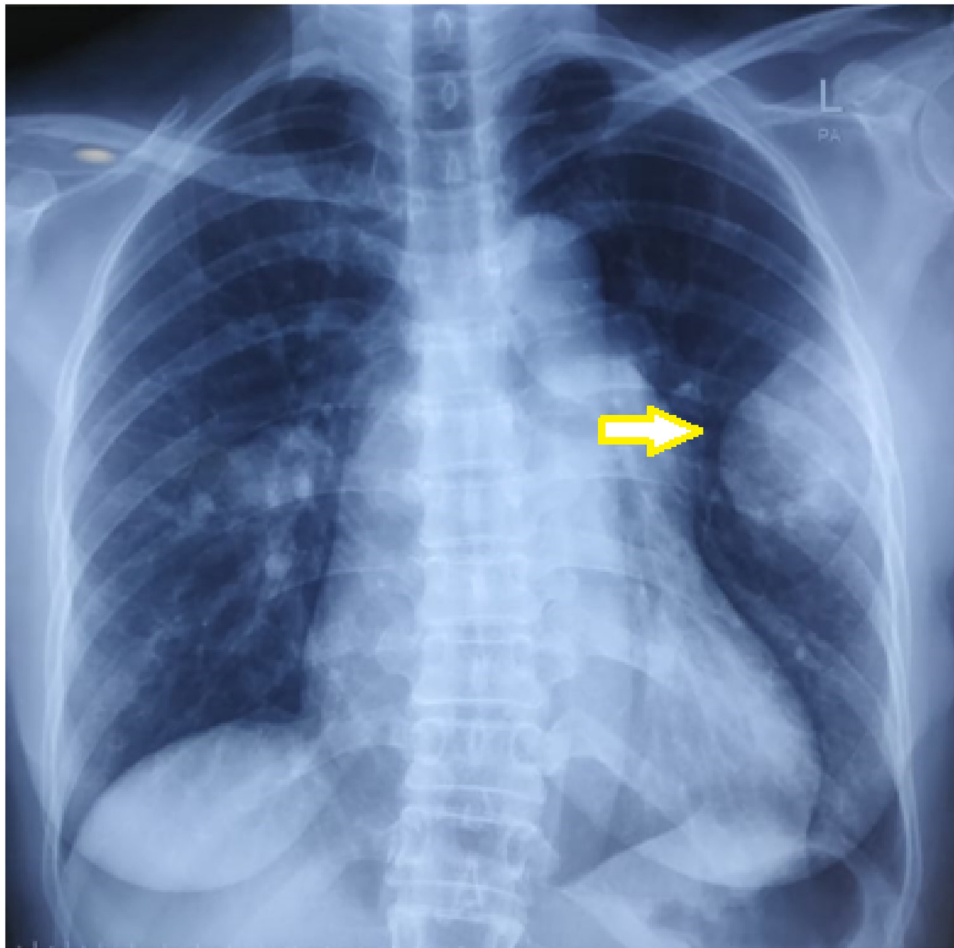


Fig. 1. Preoperative Chest X-ray of patient. Notice a round mass (pointed by yellow arrow) on left hemithorax and destruction of the fourth ribs.

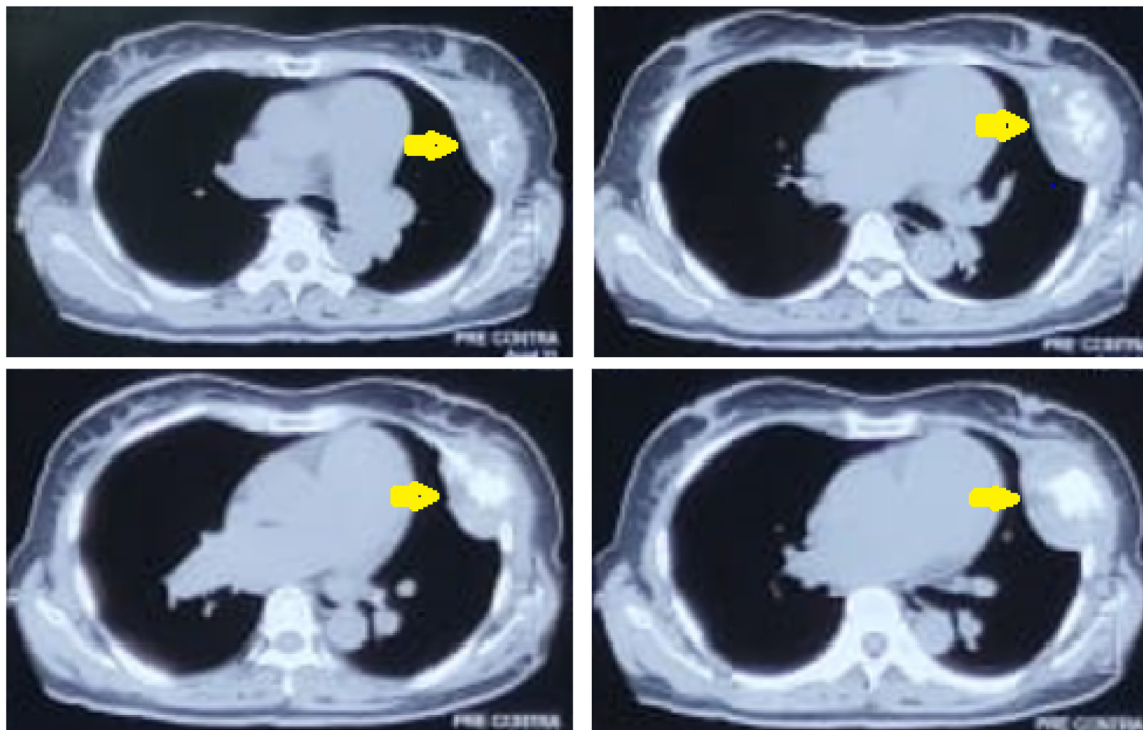


Fig. 2. Preoperative CT scan showing bone destruction of the fourth ribs and intralesional calcification.

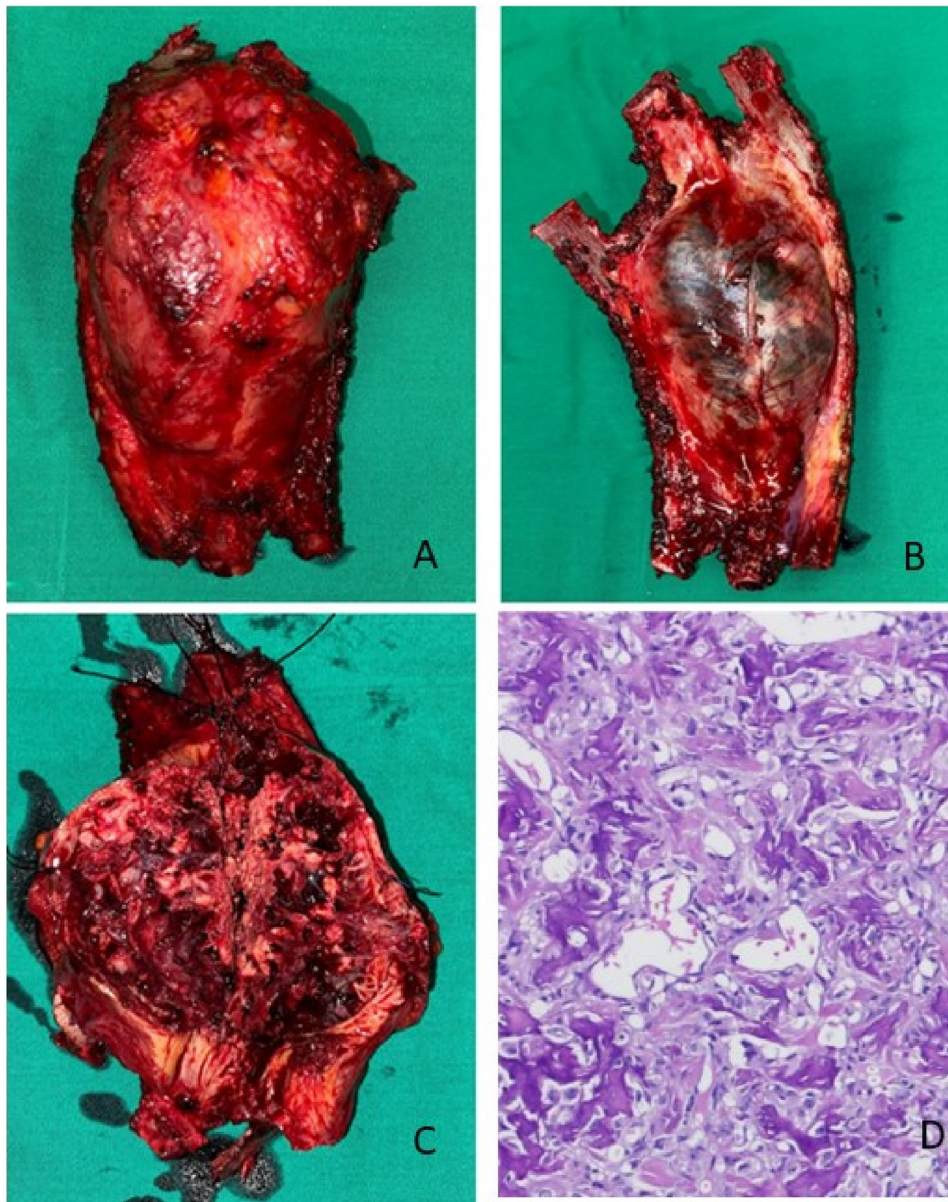


Fig. 3. (A, B, and C) Excised tumor mass. (D) Histopathological picture with Haematoxylin and eosin stain with 100x magnification.

surrounding tissues. The tumour was found on the fourth ribs, extending to the third and fifth ribs. Tumour resection was performed by excising the third, fourth, and fifth ribs. Tumour excision was performed as wide as possible and included the pleura. Chest cavity was left open. A drain was placed in pleural space and connected to WSD. Chest wall was reconstructed with biological mesh. Skin was then closed layer by layer (Fig. 4). There's no perioperative complication. Post-operative histopathological evaluation is consistent with, preoperative biopsy, osteosarcoma.

After surgery, patient was extubated and monitored in the ICU for twenty hours before moved to ward. Chest drain was removed on the fifth day and patient was discharged on the seventh day.

Upon routine clinical examination, there were no complications reported and the patient was satisfied with the surgery results.

3. Discussion

Chest wall tumour could be caused by both benign and malignant lesions. Benign lesions are more commonly found among

elderlies while lesions on younger patients are more likely to be benign [2].

Osteosarcoma is a noncommon type of chest wall malignancy. Epidemiology of chest wall malignancy is not well studied. Based on a publication by Andrianapolous EG et al., most chest wall tumours are benign (85%). The most common malignant lesions are metastases lesion and primary chondrosarcoma [2,3]. Based on a report by Sakellaridis T et al., from 15-year data, most rib tumours are benign (70.33%). They reported that 48.15% of the malignant lesions are metastases lesions, most commonly from renal cell carcinoma, followed by breast carcinoma. The most common primary malignant lesion of the ribs is chondrosarcoma, followed by osteosarcoma [4].

Even though epidemiological studies reported that osteosarcoma most commonly originates from long bones of the extremities (especially lower extremities), in this case, the chest wall tumour was osteosarcoma. Osteosarcoma is rarely found on flat bones such as the ribs. The most common origin of osteosarcoma are femur (42%), tibia (19%), and humerus (10%) [4]. Flat bones that are com-

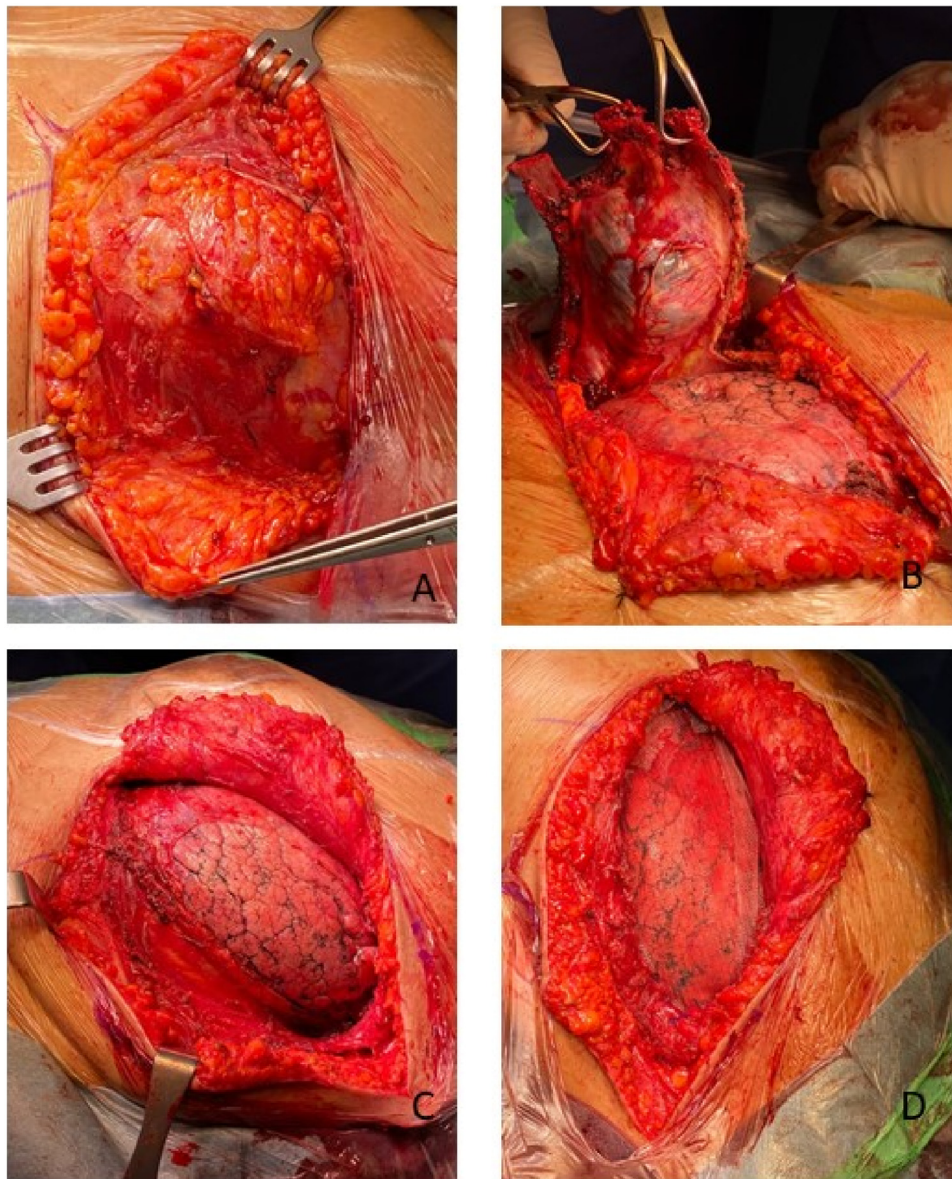


Fig. 4. (A) intraoperative mass identification; (B) wide excision of the mass; (C) chest wall defect after wide excision; (D) Chest wall defect reconstruction with mesh.

mon origin of osteosarcoma include skull and jaws (8%) as well as pelvic (8%) [1]. Meanwhile, ribs osteosarcoma accounts for only 1.25% of all osteosarcoma cases [1].

Kundu ZS suggested alkaline phosphatase (ALP) and lactate dehydrogenase (LDH) as biomarkers and prognosis predictors of osteosarcoma [5]. Meta-analysis by Hao H showed that high serum ALP is an indicator of poor prognosis while a meta-analysis by Fu Y showed that patients with high LDH have poor prognosis [6,7].

Radiographic examination is a standard examination for all patients with thoracic abnormalities. For more detailed assessment, CT scan or magnetic resonance imaging (MRI) could be performed. CT scan could provide a detailed enough image to evaluate almost all chest wall tumours. MRI outperforms CT scan in depicting soft tissues.

Chest wall resection is the main treatment for chest wall tumours [8]. Surgery with wide excision extending to tumour-free borders is a principle in surgical oncology aimed to reduce the risk of recurrence. In this case, considering the location of the chest wall tumour, chest wall reconstruction was needed to prevent impaired chest wall mechanical function in respiration.

Mesh is one of the modalities that could be used to reconstruct chest wall beside autologous tissue, gore-tex, and methyl methacrylate [8]. In this patient, we reconstructed the chest wall using mesh. In a case report by Lim W et al., they performed reconstruction using titanium mesh in a similar case [9]. Meanwhile, Tozum et al. treated a similar case with reconstruction using collagen mesh and metal plate [10,11].

4. Conclusion

Osteosarcoma of the ribs is a rare case, hence the diagnosis and treatment pose more challenges. The main treatment of the osteosarcoma of the ribs is wide resection, followed by reconstruction of chest wall when needed. Reconstruction could be performed with autologous tissue, gore-tex, and mesh. The adjuvant chemotherapy was considered to give for better outcome.

Declaration of Competing Interest

None declared.

Sources of funding

This research is funded by author's personal funding, no sponsors involved.

Ethical approval

This study is exempt from ethical approval in our institution.

Consent

Written informed consent was obtained from the patient for publication of this case report and accompanying images. A copy of the written consent is available for review by the Editor-in-Chief of this journal on request.

Author contribution

Suprayitno Wardoyo: study concept or design, data collection, data analysis or interpretation, writing the paper.

Achmad Fauzi Kamal: study concept or design, data collection, data analysis or interpretation, writing the paper.

Muhammad Aris Furqon: study concept or design, data collection, data analysis or interpretation, writing the paper.

Jonathan Grantomo: study concept or design, data collection, data analysis or interpretation, writing the paper.

Witantra Dhamar Hutami: study concept or design, data collection, data analysis or interpretation, writing the paper.

Registration of research studies

Not applicable.

Guarantor

Suprayitno Wardoyo.
Achmad Fauzi Kamal.

Provenance and peer review

Not commissioned, externally peer-reviewed.

References

- [1] G. Ottaviani, N. Jaffe, The epidemiology of osteosarcoma, in: N. Jaffe, O. Bruland, S. Bielack (Eds.), *Pediatric and Adolescent Osteosarcoma*, Springer, Boston, 2009.
- [2] A.A. Shah, T.A. D'Amico, Primary chest wall tumors, *J. Am. Coll. Surg.* 210 (3) (2010) 360–366.
- [3] E.G. Andrianopoulos, G. Lautidis, P. Kormas, A. Karameris, S. Lahanis, L. Papachristos, et al., Tumours of the ribs, *Eur. J. Cardiothorac. Surg.* 15 (5) (1999) 615–620.
- [4] T. Sakellariadis, S. Gaitanakis, A. Piyis, Rib tumors: a 15-year experience, *Gen. Thorac. Cardiovasc. Surg.* 62 (2014) 434–440.
- [5] Z.S. Kundu, Classification, imaging, biopsy and staging of osteosarcoma, *Indian J. Orthop.* 48 (3) (2014) 238–246.
- [6] H. Hao, L. Chen, D. Huang, J. Ge, Y. Qiu, L. Hao, Meta-analysis of alkaline phosphatase and prognosis for osteosarcoma, *Eur. J. Cancer Care* 26 (5) (2017), e12536.
- [7] Y. Fu, T. Lan, H. Cai, A. Lu, W. Yu, Meta-analysis of serum lactate dehydrogenase and prognosis for osteosarcoma, *Medicine (Baltimore)* 97 (19) (2018) e0741.
- [8] E.A. David, M.B. Marshall, Review of chest wall tumors: a diagnostic, therapeutic, and reconstructive challenge, *Semin. Plast. Surg.* 25 (1) (2011) 16–24.
- [9] W. Lim, S. Ahmad Sarji, Y. Yik, T. Ramanujam, Osteosarcoma of the rib, *Biomed. Imaging Interv. J.* 4 (1) (2008) e7.
- [10] H. Tozum, A.N. Aydemir, M. Demiroglu, K. Ozkan, A.B. Ceyran, B. Kilic, A rare rib lesion due to parosteal osteosarcoma: a case report, *J. Med. Case Rep.* 13 (1) (2019) 19.
- [11] R.A. Agha, T. Franchi, C. Sohrabi, G. Mathew, for the SCARE Group, The SCARE 2020 guideline: updating consensus surgical CAse REport (SCARE) guidelines, *Int. J. Surg.* 84 (2020) 226–230.

Open Access

This article is published Open Access at [sciencedirect.com](https://www.sciencedirect.com). It is distributed under the [IJSCR Supplemental terms and conditions](#), which permits unrestricted non commercial use, distribution, and reproduction in any medium, provided the original authors and source are credited.