

A New Technique for Seprafilm® That Can Be Practiced with a 5-mm Trocar

Rikiya Sano^{1*}, Yoshiaki Ota¹, Tamaki Tanaka², Soichiro Suzuki¹, Koichiro Shimoya², Mitsuru Shiota¹

Departments of ¹Gynecologic Oncology and ²Obstetrics and Gynecology, Kawasaki Medical School, Kurashiki, Okayama, Japan

Abstract

Seprafilm® is an adhesion barrier sheet. However, it is difficult to handle it through a 5-mm trocar. We have devised a method of applying Seprafilm® safely and reliably through a 5-mm trocar by using a holder that comes with the film. We practiced this method in three cases of total laparoscopic hysterectomy for uterine leiomyoma. The quarter-pack is cut into three pieces. The film placed on the holder sheet was rolled up with forceps (or wrapped around forceps) and inserted into a 5 mm trocar. After application, the center of the short axis of the holder was pinched with a grasping forceps, and the holder was drawn out of the body through the trocar. Of the 36 pieces placed, Seprafilm® broke only in once. Insertion was successful in 100%, and the holder was successfully retrieved through the trocar in 92% (33/36) of the cases. The holder may be easily retrieved after application. This technique represents an extremely simple versatile application method in operations in which only 5-mm trocars can be used.

Keywords: Adhesion, endoscopy, hysterectomy, laparoscopy

INTRODUCTION

Although fewer postoperative adhesions occur after laparoscopic surgery compared with those after open abdominal surgery,^[1] adhesion barriers are still proactively used with the aim of sparing fertility and avoiding complications such as postoperative ileus.

Seprafilm® is an adhesion barrier sheet that remains in the desired location, not only preventing postoperative adhesive intestinal obstructions but also reducing the risk of prolonged surgery and increased hemorrhage, should further surgery be required.^[2] It has also been found to help improve postoperative pain.^[3] It is already widely used, particularly in open abdominal gastrointestinal surgery. In gynecology, it is often used during cesarean sections.^[4] However, Seprafilm® is brittle and cracks easily. It is thus difficult to handle it in laparoscopic surgery,^[5,6] and special measures are required to enable its use through 5-mm trocars.

Article History:

Submitted: 28 July 2020

Revised: 16 October 2020

Accepted: 22 October 2020

Published: 3 August 2021

We have devised a method that enables the safe, reliable insertion and application of adhesion barrier sheets through a 5-mm trocar, which requires no special equipment other than the holder that comes with the film.

SUBJECTS AND METHODS

The study participants were three patients who underwent total laparoscopic hysterectomy (TLH) for uterine leiomyoma at our hospital between October and December 2019, and an adhesion barrier was applied by the method reported in the present study. We measured the rate of the breakage of Seprafilm®, the success rate of insertion, the rate of retrieving the holder through a trocar, and the time of placement. This study was approved by the appropriate research ethics committee (institutional review board no. 3831). An appropriate informed consent was obtained from each patient.

Address for correspondence: Dr. Rikiya Sano,
Department of Gynecologic Oncology, Kawasaki Medical School,
577 Matsushima, Kurashiki, Okayama 701-0192, Japan.
E-mail: sun102life@yahoo.co.jp

This is an open access journal, and articles are distributed under the terms of the Creative Commons Attribution-NonCommercial-ShareAlike 4.0 License, which allows others to remix, tweak, and build upon the work non-commercially, as long as appropriate credit is given and the new creations are licensed under the identical terms.

For reprints contact: WKHLRPMedknow_reprints@wolterskluwer.com

How to cite this article: Sano R, Ota Y, Tanaka T, Suzuki S, Shimoya K, Shiota M. A new technique for seprafilm® that can be practiced with a 5-mm trocar. *Gynecol Minim Invasive Ther* 2021;10:168-70.

Access this article online

Quick Response Code:



Website:
www.e-gmit.com

DOI:
10.4103/GMIT.GMIT_36_20

We conducted laparoscopic total hysterectomy using a 5-mm diameter ENDOPATH® XCEL bladeless trocar (Ethicon, Johnson & Johnson, NJ, USA). Prior to wound closure, we introduced Seprafilm® quarter-pack anti-adhesion barrier sheets (Sanofi, Paris, France) into the peritoneal cavity and applied them.

We first equally divided the quarter-pack into three pieces [Figure 1a]. Hence, 12 Seprafilm® insertion maneuvers are required for each patient. A piece of Seprafilm® was placed on the top of a holder sheet, the corner was pinched with a grasping forceps, and the Seprafilm® and the holder were then rolled up along the forceps with the Seprafilm® on the inside of the sleeve [Figure 1b]. The forceps were inserted into the 5-mm trocar with the Seprafilm® rolled around them [Figure 2a], and, having been introduced into the abdominal cavity, the film was applied to the desired site [Figure 2b]. Finally, the center of the short axis of the holder was pinched with the grasping forceps [Figure 2c], and

the holder was carefully guided into the same orientation as the trocar sleeve and drawn out of the body [Figure 2d]. The procedure was performed by the same surgeon in all cases.

RESULTS

We repeated this Seprafilm® placement method for a total of 36 times. The rate of breakage was 3% (1/36), where the film most commonly suffered partial breakage while it was being rolled up along the forceps with the holder. There was no breakage inside the trocar. The holder was successfully retrieved through the trocar in 92% (33/36) of the cases, and the median placement time was 615 s per patient. There were no complications caused by this surgical procedure.

DISCUSSION

We have devised a new method for the safe, reliable insertion and application of adhesion barrier sheets through 5-mm

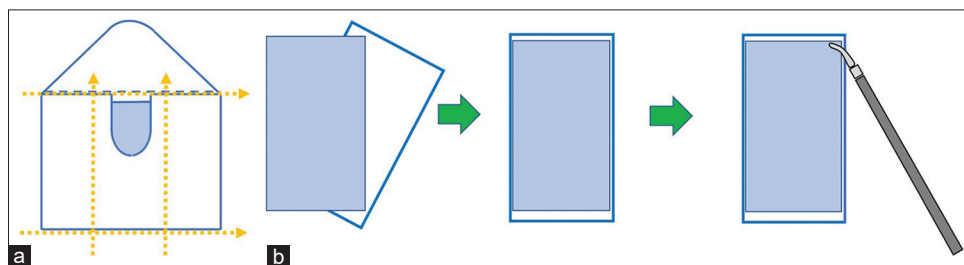


Figure 1: (a) The quarter-pack sheet is divided into three pieces along its short axis. (b) A piece of Seprafilm® is placed on a holder paper. The corner is pinched with a grasping forceps, and rolled up around the forceps with the Seprafilm® on the inside of the sleeve

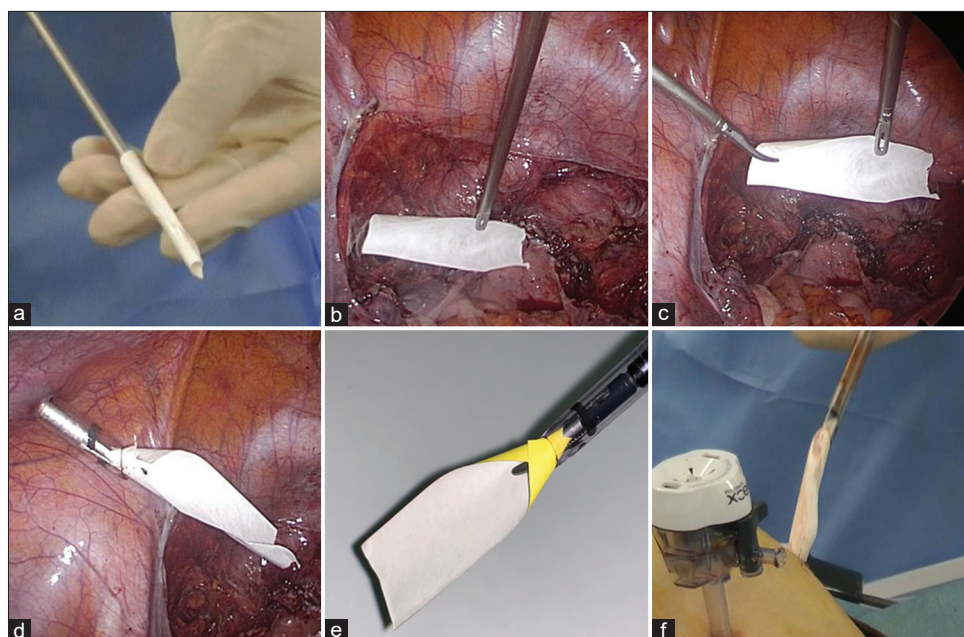


Figure 2: (a) The forceps are introduced with the Seprafilm® wrapped around them into the 5-mm trocar. (b) After its insertion into the peritoneal cavity, the Seprafilm® is applied to the desired site. The holder can also be used in the application process. (c) When retrieving the holder, it is pinched with the grasping forceps at the center of its short side. (d) The holder is guided so that it aligns with the direction of the sleeve. (e) Origami reproduction of the ideal positional relationship between the sleeve and the holder. (f) If the holder cannot be retrieved, pull it out with the trocar

trocars, which requires no special equipment other than the holder that comes with the film.

Our method is extremely simple, as it uses only the holder that comes with the film to introduce and apply Seprafilm® within the peritoneal cavity by the same method used in open surgery. Seprafilm®, an adhesion barrier sheet, is a translucent film made from sodium hyaluronate and carboxymethyl cellulose that works as a physical barrier to prevent adhesions. However, because of its nature as a film, it may crack when inserted through a trocar.^[5] It may also stick to wet trocars or forceps or to the surrounding organs before it can be applied to the desired site, and it cannot be reapplied. Given these characteristics, different hospitals take different measures when inserting and applying Seprafilm® in laparoscopic surgery. Useful methods that have previously been described include the use of a catheter tip syringe.^[7] However, the current package insert does not recommend the use of any devices other than the holder that comes with the film during its introduction, as the safety of such methods is controversial. Our method clearly avoids this issue.

Another noteworthy point about our technique is that it can be reliably implemented through a 5-mm trocar. Most previously reported methods of Seprafilm® application in laparoscopic surgery, either with or without an introducer, envisage its introduction through a 10–12-mm trocar.^[8,9] As we use only 5-mm trocars when conducting TLH, we had to devise a technique that could be performed safely and reliably through trocars of this size. As direct methods entail the issue of Seprafilm® adhesion to the inside of the sleeve when a 5-mm trocar is used, we explored methods involving the use of a holder. In the method we describe here, the Seprafilm® is rolled around the forceps 2–3 times, making it comparatively easy to perform. The use of a holder also eliminates the risk of the Seprafilm® sticking to the inside of the sleeve. Our next problem was how to retrieve the holder after application. After attempting a range of different cutting techniques in a dry box, we identified the easiest method of retrieving the holder through the 5-mm trocar. The key points are the orientation of the shade of the trocar tip and the degree of curvature of the short axis of the holder [Figure 2e]. If the holder can be curved in this way, it can easily be drawn out with a grasping forceps. If the holder cannot be curved in the ideal way, the trocar can be rotated slightly and used to shape the holder so that it can be smoothly guided into the sleeve. If for some reason the holder cannot be retrieved through the trocar, it is possible to retrieve it by pulling a corner of the holder into the sleeve and withdrawing it together with the forceps and the trocar [Figure 2f].

In our method, we cut a single quarter-pack sheet into three pieces, meaning that at least 12 Seprafilm® insertion

maneuvers are required for each patient. The prolongation of surgery duration because of the greater number of applications is a cause of concern.^[10] In our operations, the actual time required for the procedure is around 10 min. We regard this time as acceptable from the standpoint of adhesion prevention, but the longer time required compared with the use of anti-adhesive sprays and coatings may be solved by stacking multiple films at once.

We have devised a new method of application for adhesion barrier sheets focusing on holder retrieval. This method can be implemented without the use of any special equipment. Using the holder in this way represents a versatile technique that enables the safe, reliable insertion and application of adhesion barrier sheets through a 5-mm trocar.

Financial support and sponsorship

Nil.

Conflicts of interest

Prof. Mitsuru Shiota, an editorial board member at *Gynecology and Minimally Invasive Therapy*, had no role in the peer review process of or decision to publish this article. The other authors declared no conflicts of interest in writing this paper.

REFERENCES

- Ahmad G, O'Flynn H, Hindocha A, Watson A. Barrier agents for adhesion prevention after gynaecological surgery. *Cochrane Database Syst Rev* 2015(4);CD000475.
- Zeng Q, Yu Z, You J, Zhang Q. Efficacy and safety of Seprafilm for preventing postoperative abdominal adhesion: Systematic review and meta-analysis. *World J Surg* 2007;31:2125-31.
- Khaitan L, Scholz S, Houston HL, Richards WO. Results after laparoscopic lysis of adhesions and placement of Seprafilm for intractable abdominal pain. *Surg Endosc* 2003;17:247-53.
- Bates GW Jr, Shomento S. Adhesion prevention in patients with multiple cesarean deliveries. *Am J Obstet Gynecol* 2011;205:S19-24.
- Takeuchi H, Kitade M, Kikuchi I, Shimanuki H, Kinoshita K. A novel instrument and technique for using Seprafilm hyaluronic acid/carboxymethylcellulose membrane during laparoscopic myomectomy. *J Laparoendosc Adv Surg Tech A* 2006;16:497-502.
- Kusuki I, Suganuma I, Ito F, Akiyama M, Sasaki A, Yamanaka K, *et al.* Usefulness of moistening Seprafilm before use in laparoscopic surgery. *Surg Laparosc Endosc Percutan Tech* 2014;24:e13-5.
- Ortiz MV, Awad ZT. An easy technique for laparoscopic placement of Seprafilm. *Surg Laparosc Endosc Percutan Tech* 2009;19:e181-3.
- Tsuruta A, Itoh T, Hirai T, Nakamura M. Multi-layered intra-abdominal adhesion prophylaxis following laparoscopic colorectal surgery. *Surg Endosc* 2015;29:1400-5.
- Chuang YC, Lu HF, Peng FS, Ting WH, Tu FC, Chen MJ, *et al.* Modified novel technique for improving the success rate of applying Seprafilm by using laparoscopy. *J Minim Invasive Gynecol* 2014;21:787-90.
- Raimondo D, Raffone A, Saccone G, Travaglio A, Degli Esposti E, Mastronardi M, *et al.* Cellulose absorbable barrier for prevention of de-novo adhesion formation at the time of laparoscopic myomectomy: A systematic review and meta-analysis of randomized controlled trials. *Eur J Obstet Gynecol Reprod Biol* 2020;245:107-13.