

Salvage endoscopic resection in patients with esophageal adenocarcinoma after chemoradiotherapy



Authors

Irma C. Noordzij¹, Wouter L. Curvers¹, Clément J. Huysentruyt², Grard A.P. Nieuwenhuijzen³, Geert-Jan Creemers⁴, Maurice J.C. van der Sangen⁵, Erik J. Schoon¹

Institutions

- 1 Department of Gastroenterology and Hepatology, Catharina Hospital, Eindhoven, the Netherlands
- 2 PAMM (laboratory of Pathology and Medical Microbiology), Eindhoven, the Netherlands
- 3 Department of Surgery, Catharina Hospital, Eindhoven, the Netherlands
- 4 Department of Oncology, Catharina Hospital, Eindhoven, the Netherlands
- 5 Department of Radiation Oncology, Catharina Hospital, Eindhoven, the Netherlands

submitted 19.9.2017

accepted after revision 2.2.2018

Bibliography

DOI <https://doi.org/10.1055/a-0599-6008> |
Endoscopy International Open 2018; 06: E1126–E1129
© Georg Thieme Verlag KG Stuttgart · New York
ISSN 2364-3722

Corresponding author

E.J. Schoon, MD, PhD, Gastroenterologist, Department of Gastroenterology and Hepatology, Catharina Hospital,

Michelangelolaan 2, 5623 EJ, Eindhoven, The Netherlands
Fax: +3140-239 97 51
erik.schoon@catharinaziekenhuis.nl

ABSTRACT

Background and study aims For early esophageal adenocarcinoma, endoscopic resection is an accepted curative treatment with an excellent long-term prognosis. Case series from Japan have reported endoscopic resection of residual esophageal squamous cell carcinoma after chemoradiotherapy. This is the first report describing endoscopic resection of residual esophageal adenocarcinoma after chemoradiotherapy. Two patients with advanced esophageal adenocarcinoma had been treated with chemoradiotherapy because comorbidity precluded esophageal resection. When residual tumor was observed endoscopically, complete remission was achieved by salvage endoscopic therapy alone or in combination with argon plasma coagulation (APC). Both patients achieved long-term sustained remission and died of non-tumor-related causes.

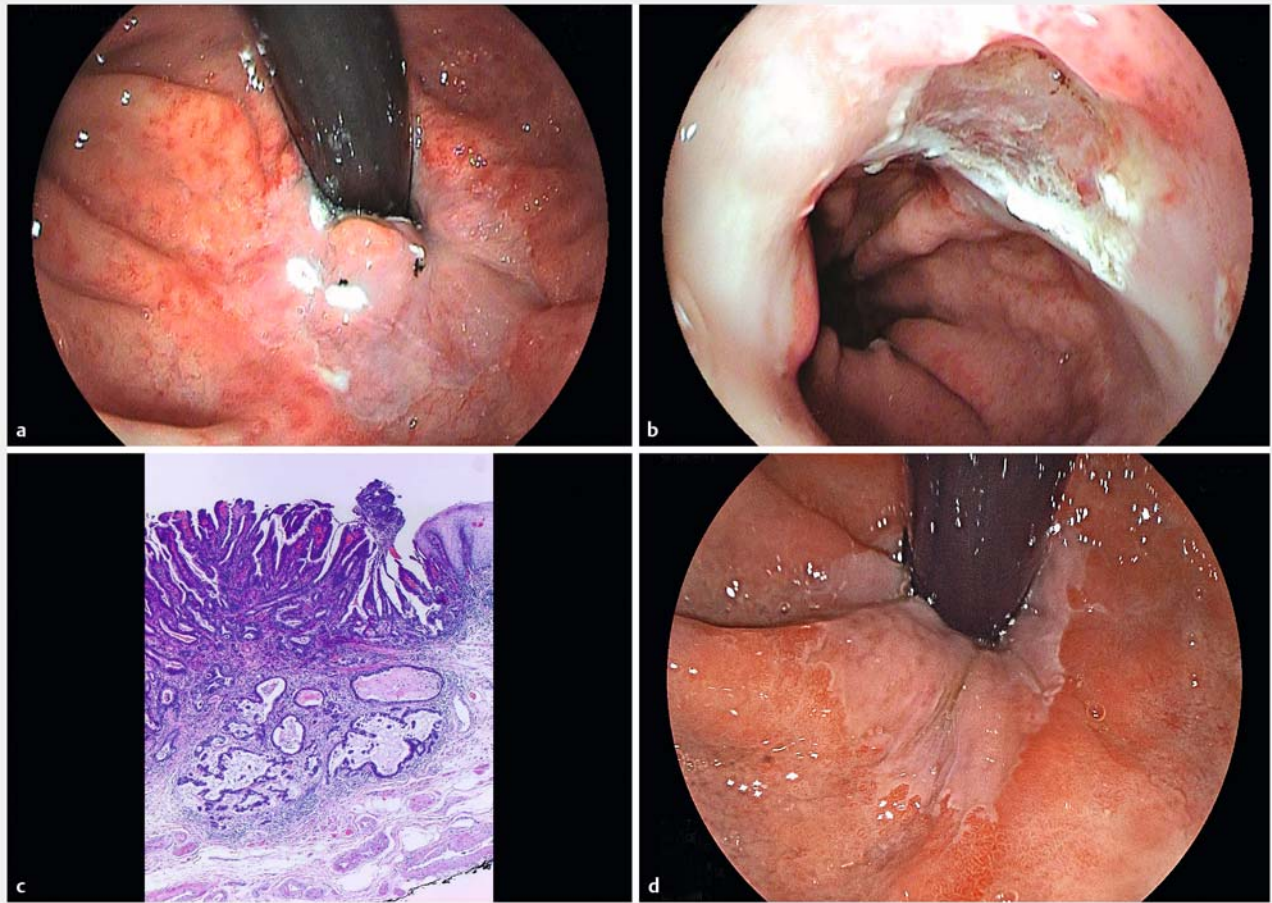
Introduction

Esophageal adenocarcinoma is the fastest increasing type of cancer in the western world [1]. Endoscopic resection is an effective treatment for early esophageal adenocarcinoma with an excellent long-term prognosis [2]. For advanced cases, the preferred curative treatment is neoadjuvant chemoradiotherapy (CRT) followed by esophageal resection. In patients who are unfit for surgery, definitive CRT is an alternative, but local failure after definitive CRT at the primary site remains a significant problem [3].

In case series from Japan, salvage endoscopic resection of residual cancer after definitive CRT has been reported in esophageal squamous cell carcinoma [3–5]. Yano et al reported a local failure rate of 34% in patients treated with definitive CRT after diagnosis of squamous cell carcinoma of the esophagus. Because of the high local recurrence rate for squamous cell car-

cinomas, curative local control is crucial and salvage endoscopic resection provides a therapeutic option with curative intent [3,5]. Reports of curative treatment with salvage endoscopic resection of recurrent or residual squamous cell carcinoma after definitive CRT have been described, however to date, curative treatment with salvage endoscopic resection in cases of residual adenocarcinoma after CRT has not been reported. The only reported case of endoscopic resection after neoadjuvant chemotherapy was described with a submucosal invasive adenocarcinoma with concomitant distant metastases [6].

This is the first report describing salvage endoscopic resection of esophageal adenocarcinoma after CRT in two patients with residual tumour.



► **Fig. 1** Endoscopic images of salvage ER for residual adenocarcinoma after definitive CRT in a 68-year-old male. **a** Delineation of the residual Paris type IIA lesion by coagulation markers. **b** Wound resection after salvage ER. **c** Histopathological evaluation of the specimen showed a radically resected adenocarcinoma infiltrating the muscularis mucosae (ypT1m3), R0 resection. **d** At long-term follow-up, the neosquamocolumnar junction in the same area looked normal 3 years after salvage ER.

Case reports

We present two patients with an advanced esophageal adenocarcinoma who had been treated with CRT because they were considered “not fit for surgery” due to comorbidity and/or complications during treatment.

Patient 1

A 68-year-old male patient with obstructive pulmonary disease GOLD III (Global initiative for chronic obstructive lung disease, stage III [$30\% \leq FEV_1 < 50\%$ predicted]) presented with dysphagia. At endoscopy active reflux esophagitis was observed in the presence of a lesion suspicious for malignancy. Pathology showed a moderately differentiated adenocarcinoma. Endoscopic ultrasonography (EUS) revealed a tumor invading the muscularis propria with no signs of lymph node metastases. Subsequent computed tomography (CT) showed no distant metastases (cT2N0M0). Our multidisciplinary team proposed treating the patient with neoadjuvant CRT followed by esophageal resection and reconstruction. Chemoradiation consisted of radiotherapy with a total dose of 41.4 Gy in 23 fractions of

1.8 Gy, 5 fractions per week and concurrent chemotherapy of 5 weekly administrations of carboplatin (AUC [area under the curve] 2 and paclitaxel 50 mg/m²).

Shortly after finishing the neoadjuvant CRT, the patient developed massive pulmonary embolism and a pneumothorax. Due to these complications after neoadjuvant CRT and his pre-existing comorbidity, he was no longer considered suitable for esophageal resection.

Four months after the neoadjuvant CRT treatment, endoscopy revealed a minimal residual Paris type IIA lesion of about 5 mm in a short Barrett segment (► **Fig. 1a**). We did not perform EUS, but the tumor invasion and lateral margins were very well judged endoscopically, based on extensive clinical experience. Biopsies confirmed residual adenocarcinoma. Subsequently, the lesion was removed by salvage endoscopic resection in one single resection using the multi-band mucosectomy device (MBM, Cook, Ireland) (► **Fig. 1b**). The resected specimen showed a moderately differentiated adenocarcinoma invading the muscularis mucosa without lymphovascular invasion and a free vertical resection margin (R0 resection) (► **Fig. 1c**). During

follow-up, a second endoscopic resection was performed on residual Barrett mucosa at the level of the Z-line containing high-grade dysplasia. During subsequent endoscopy, the residual Barrett mucosa was treated with radiofrequency ablation (Halo 90, Barrx, Sunnyvale, California, United States).

Endoscopic and radiologic follow-up by means of a CT scan was performed once every 3 months in the first year after endoscopic resection, once every 6 months in the second year, and once a year in the subsequent years. During this subsequent follow-up there were no signs of metastases, and complete remission of cancer and intestinal type dysplasia sustained for 35 months (► Fig. 1d).

The patient died 3 years and 10 months after achieving complete remission due to respiratory failure, which was unrelated to the primary esophageal carcinoma.

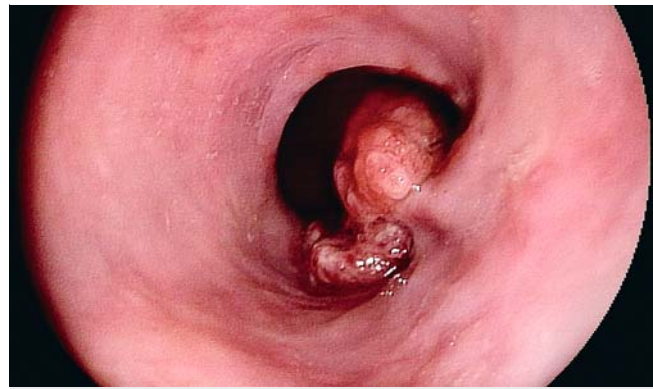Patient 2

A 78-year-old male patient with a history of myocardial infarction presented with pain in the epigastric region and weight loss. Endoscopy showed a suspicious lesion with a length of 3 cm at the gastroesophageal junction (GEJ) (► Fig. 2), and subsequent biopsies revealed a moderately differentiated adenocarcinoma. EUS and CT scan demonstrated a tumor invading the muscularis propria with no signs of lymph node metastases or distant metastases (cT2N0M0).

Our multidisciplinary team decided to treat the patient with definitive CRT because of frailty. In case of incomplete response to restaging, a subsequent esophageal resection could be considered.

The treatment consisted of a total radiation dose of 50.4 Gy in 28 fractions of 1.8 Gy, 5 fractions per week and concurrent chemotherapy with 6 weekly intravenous administrations of carboplatin (AUC and paclitaxel 50 mg/m²). Due to grade 3 thrombopenia, only four of six intended chemotherapy cycles were given. Furthermore, definitive CRT was complicated by post-irradiation pneumonitis. Five months after the end of definitive CRT, endoscopic response evaluation revealed a histologically proven residual adenocarcinoma Paris IIa type lesion at the GEJ without signs of distant metastases. The residual tumor was removed by means of salvage endoscopic resection using the multiband mucosectomy technique (MBM, Cook, Ireland) combined with argon plasma coagulation (APC) in the center of the lesion due to local non-lifting. Pathology showed a poorly differentiated adenocarcinoma invading the muscularis mucosa without lymphovascular invasion and doubtful vertical resection margins (R1). In three consecutive endoscopies, histological remnants of adenocarcinoma were found in biopsies of the scar and treated with APC, which eventually resulted in a complete endoscopic remission.

Subsequently, the follow-up was similar to that in Patient 1. Complete endoscopic and histological remission of cancer sustained for 37 months. CT scan 1 year after endoscopic resection presented no signs of metastases. Three years and 8 months after achieving complete remission, the patient died of massive intracerebral hemorrhage, a non-tumor-related cause.



► Fig. 2 Endoscopic image of primary lesion before definitive CRT in a 78-year-old male.

Discussion

This is the first report describing endoscopic resection salvage treatment of residual adenocarcinoma after CRT. Two patients with an initial cT2N0M0 adenocarcinoma of the distal esophagus were treated with CRT. After CRT, both patients were considered “unfit for surgery” due to comorbidity or persistent physical impairment after CRT. In both cases, complete remission could be achieved by means of salvage endoscopic resection of the residual tumor alone or in combination with APC. Sustained clinical remission was achieved in both patients. Endoscopic treatment was uncomplicated.

State-of-the-art treatment in the Netherlands for surgically resectable locally advanced esophageal or GEJ carcinoma is neoadjuvant CRT followed by a subsequent esophagectomy [7]. Definitive CRT is regarded as first-choice treatment with curative intent for unresectable esophageal cancer or for patients unfit for surgery. Although CRT has shown a high response rate, local failure with recurrence or residual tumor is common [3, 8]. Shapiro et al showed that 76% (56/74) of patients with esophageal adenocarcinoma had residual tumor cells after neoadjuvant CRT [8], however, definitive CRT is more intensive treatment.

This report demonstrates that curative treatment with salvage endoscopic resection after CRT in patients with esophageal carcinoma is feasible. Salvage endoscopic resection could be considered in patients with limited residual superficial cancer in the esophagus and no signs of systemic dissemination. Furthermore, the lesion should be suitable for endoscopic resection, and an R0 resection should be pursued. Esophageal adenocarcinomas are mostly associated with Barrett’s metaplasia or dysplasia. Neoadjuvant or definitive CRT, however, does not eradicate Barrett’s epithelium esophagus. In addition, patients with persisting (dysplastic) Barrett’s epithelium are at potential risk for developing metachronous neoplastic lesions. Therefore, most esophageal adenocarcinoma recurrences arise in the persisting (dysplastic) Barrett’s epithelium [9] and are not visible on CT scan. Additional endoscopic surveillance and treatment of residual Barrett’s dysplasia after CRT, therefore, should be considered.

Systematic endoscopic follow-up after treatment with definitive CRT in patients unfit for surgery is unusual in the Netherlands. The ongoing preSANO (Surgery As Needed for Oesophageal cancer) study evaluates the accuracy of detecting the presence or absence of residual disease after neoadjuvant CRT [10]. Shapiro et al. showed that neoadjuvant CRT induces non-random and concentric regression of esophageal cancer within the esophageal wall towards the lumen. In patients (63/71) with residual disease, the tumor lesions were most commonly present in the mucosa, the submucosa or both. This suggests a possible preferential persistence of malignant cells in the mucosa or submucosa after neoadjuvant CRT [8], which could therefore potentially be suitable for endoscopic therapy.

For patients who are unfit for surgery but fit enough for systematic sedated endoscopy, long-term follow-up after CRT could be considered since local control could be achieved by means of salvage endoscopic resection of small remnant or recurrent tumours in the absence of lymph node metastases. However, salvage endoscopic resection may be hampered by development of submucosal fibrosis and destruction of the esophageal wall layers after CRT [11]. In the future, an alternative endoscopic treatment for residual or recurrent esophageal carcinoma could be endoscopic submucosal dissection (ESD). In addition, ESD could facilitate R0 resection in larger lesions.

Conclusion

In conclusion, this report suggests that salvage endoscopic resection after CRT could potentially be a curative treatment for residual adenocarcinoma after CRT in selected patients who are unfit for surgery.

Competing interests

None

References

- [1] Pohl H, Sirovich B, Welch HG. Esophageal adenocarcinoma incidence: are we reaching the peak? *Cancer Epidemiol Biomarkers Prev* 2010; 19: 1468–1470
- [2] Ell C, May A, Pech O et al. Curative endoscopic resection of early esophageal adenocarcinomas (Barrett's cancer). *Gastrointest Endosc* 2007; 65: 3–10
- [3] Yano T, Muto M, Hattori S et al. Long-term results of salvage endoscopic mucosal resection in patients with local failure after definitive chemoradiotherapy for esophageal squamous cell carcinoma. *Endoscopy* 2008; 40: 717–721
- [4] Takeuchi M, Kobayashi M, Hashimoto S et al. Salvage endoscopic submucosal dissection in patients with local failure after chemoradiotherapy for esophageal squamous cell carcinoma. *Scand J Gastroenterol* 2013; 48: 1095–1101
- [5] Hatogai K, Yano T, Kojima T et al. Local efficacy and survival outcome of salvage endoscopic therapy for local recurrent lesions after definitive chemoradiotherapy for esophageal cancer. *Radiat Oncol* 2016; 11: 31
- [6] Nakatani K, Tanabe S, Koizumi W et al. Successful treatment of S-1 + CDDP followed by salvage EMR for a case with metastatic Barrett's esophageal cancer. *Dis Esophagus* 2007; 20: 173–177
- [7] Shapiro J, van Lanschot JJ, Hulshof MC et al. Neoadjuvant chemoradiotherapy plus surgery versus surgery alone for oesophageal or junctional cancer (CROSS): long-term results of a randomised controlled trial. *Lancet Oncol* 2015; 16: 1090–1098
- [8] Shapiro J, ten Kate FJ, van Hagen P et al. Residual esophageal cancer after neoadjuvant chemoradiotherapy frequently involves the mucosa and submucosa. *Ann Surg* 2013; 258: 678–688
- [9] Theisen J, Stein HJ, Dittler HJ et al. Preoperative chemotherapy unmasks underlying Barrett's mucosa in patients with adenocarcinoma of the distal esophagus. *Surg Endosc* 2002; 16: 671–673
- [10] Noordman BJ, Shapiro J, Spaander MC et al. Accuracy of Detecting Residual Disease After Cross Neoadjuvant Chemoradiotherapy for Esophageal Cancer (preSANO Trial): Rationale and Protocol. *JMIR Res Protoc* 2015; 4: e79
- [11] Shapiro J, Wijnhoven BP, van Lanschot JJ. Reply to Letter: "Residual esophageal cancer after neoadjuvant chemoradiotherapy frequently involves the mucosa and submucosa". *Ann Surg* 2015; 262: e84–e85