



Contents lists available at ScienceDirect

International Journal of Surgery Case Reports

journal homepage: www.casereports.com

Calvarial ectopic meningothelial meningioma



Roberto Bezerra Vital^{a,*}, Pedro Tadao Hamamoto Filho^d, Renan Luiz Lapate^d,
Vinícius Zanin Martins^b, Flávio de Oliveira Lima^c, Flávio Ramalho Romero^d,
Marco Antônio Zanini^d

^a Resident of Neurosurgery at Hospital das Clínicas, UNESP, Botucatu, Brazil

^b Resident of Pathology at Hospital das Clínicas, UNESP, Botucatu, Brazil

^c Pathologist at Hospital das Clínicas, UNESP, Botucatu, Brazil

^d Neurosurgeon at Hospital das Clínicas, UNESP, Botucatu, Brazil

ARTICLE INFO

Article history:

Received 3 January 2015

Received in revised form 17 March 2015

Accepted 17 March 2015

Available online 18 March 2015

Keywords:

Meningioma

Brain tumor

Benign

ABSTRACT

BACKGROUND: Meningiomas are the most common benign neoplasm of the brain whereas ectopic presentation, although reported, is rare. Among these ectopic tumors, there are a group of purely intraosseous meningiomas, which usually are diagnosed differentially from common primary osseous tumor such as fibrous dysplasia and osteoid osteoma.

CASE DESCRIPTION: We report a 62-year-old female with a history of headaches and 6 months of progressive right parietal bulging, with no neurological signs. Parietal craniotomy was performed with immediate titanium cranioplasty of the parietal convexity. Histopathology exams revealed an ectopic intradiploic meningioma without invasion of cortical layers, with positive staining for progesterone receptors and epithelial membrane antigen.

CONCLUSIONS: Ectopic intraosseous meningiomas remain a rare neoplasm with only a few cases reported. The main theories to justify the unusual topography appear to be embryological remains of neuroectodermal tissue or cellular dedifferentiation. Surgical treatment seems the best curative option.

© 2015 The Authors. Published by Elsevier Ltd. on behalf of Surgical Associates Ltd. This is an open access article under the CC BY-NC-SA license (<http://creativecommons.org/licenses/by-nc-sa/4.0/>).

1. Introduction

Meningioma is the most common type of benign brain tumor [1], whereas ectopic meningioma, although reported, is rare. The head and neck region is the most common ectopic site whereas the scalp, skin, orbit, paranasal sinuses, salivary glands, and intraosseous or intradiploic regions can also be affected [2–5].

In view of their rarity, ectopic meningiomas of the skull are usually not the first preoperative suspicion. The main differential diagnoses are fibrous dysplasia and osteoid osteoma, the most common being benign primary tumors [6]. We report herein the case of a 62-year-old female patient with a pure ectopic intraosseous meningioma without dural invasion.

2. Presentation of case

A 62-year-old female patient presented with a history of classical migraine for the last 30 years. Six months before the diagnosis, her headaches had changed their characteristics to a continuous unilateral (right side) pain of increasing intensity. The patient reported no nausea or vomiting, which usually followed her typical migraines. Also, the patient noted a growing lump on the right parietal side and was referred to our service by her primary care physician. On neurological examination, the patient was alert and oriented, complaining of moderate headache. A hard, slightly painful, elliptical prominence without clearly defined margins was detected on her right parietal bone, which measured approximately 7 × 8 cm.

MRI images showed an osteoblastic lesion in the right parietal bone diploe, with possible involvement of both cortical layers and without dural extension (Fig. 1). The patient was scheduled for elective surgery in the following week. The surgical procedure consisted of a right parietal incision and craniotomy and was completed without interferences. The lesion was visible on the outer surface due to bone protrusion. Craniotomy was performed with a clear 1-cm margin and skull convexity was reconstructed with a titanium mesh (Fig. 2).

Histopathological examination revealed an ectopic intraosseous meningothelial meningioma, WHO grade 1. Immunohistochemi-

* Corresponding author at: Univ Estadual Paulista – UNESP; Department of Neurology, Psychology and Psychiatry, Distrito de Rubião Júnior s/n – Botucatu – SP, Zip code: 18.618-970, Brazil. Tel.: +55 14 3815 6000.

E-mail addresses: Roberto.vital@hotmail.com (R.B. Vital), pthagamotof@hotmail.com (P.T. Hamamoto Filho), relapate@gmail.com (R.L. Lapate), viniciuszanin@gmail.com (V.Z. Martins), Flavioolima@fmb.unesp.br (F. de Oliveira Lima), [ffromero@ig.com.br](mailto:fromero@ig.com.br) (F.R. Romero), mzanini@fmb.unesp.br (M.A. Zanini).

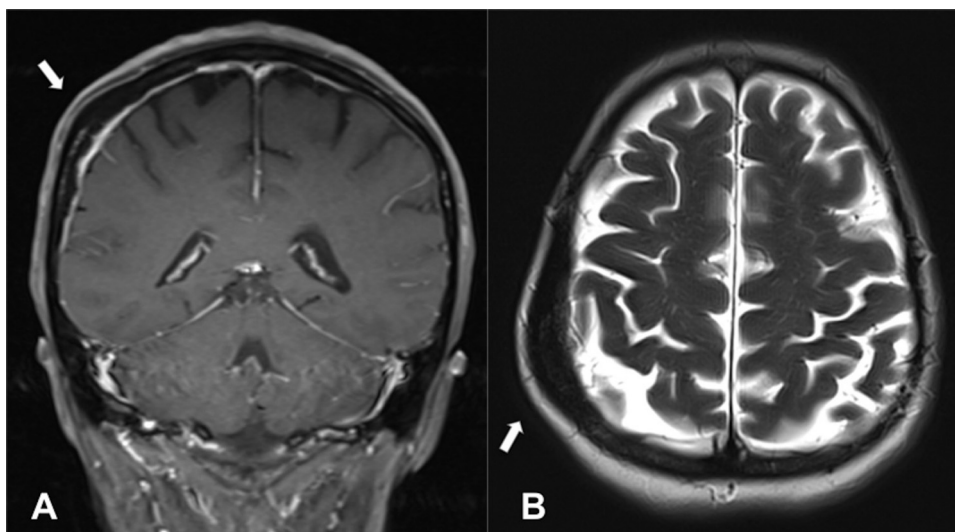


Fig. 1. (A) T1-weighted coronal gadolinium-enhanced MRI scan showing an expansive diploic lesion (white arrow) without enhancement or dural invasion. (B) T2-weighted axial scan showing the expansive non-lytic tumor.

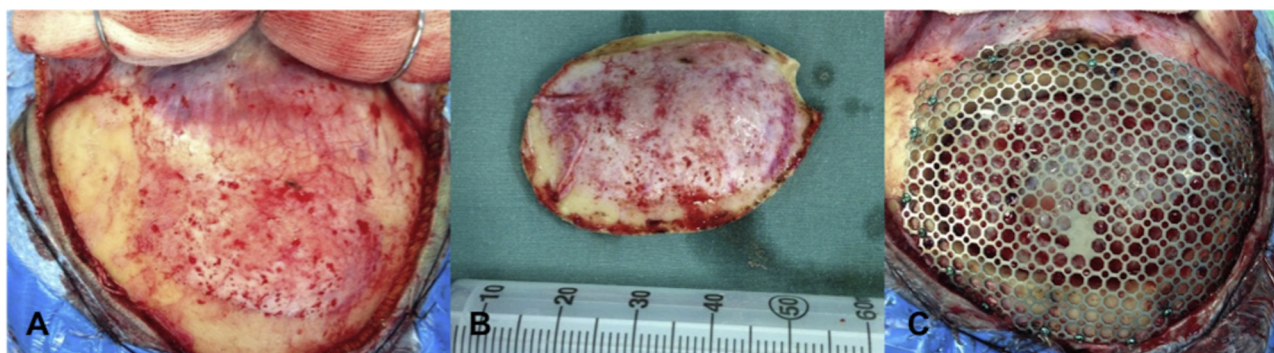


Fig. 2. Intraoperative images. (A) Right parietal arciform incision showing the prominent bone in the center. (B) Bone flap after craniotomy. (C) Cranioplasty with a titanium mesh.

cal staining was positive for progesterone receptor and epithelial membrane antigen (Fig. 3). There was no involvement of the cortical layers or pericranium.

The patient was discharged two days after surgery without headaches or other symptoms. Ten months after surgery, the patient remains asymptomatic and shows no signs of recurrence (Fig. 4).

3. Discussion

A small number of meningiomas without any dural connection has been described. Consequently, any lesions occurring outside the central nervous system are very rare [7]. Ectopic intraosseous meningiomas can also be described as intradiploic or calvarial [8] and may appear as osteoblastic [5,9], osteolytic lesions [4,10–14] or mixed lesions [8] on plain X-rays and computed tomography scans. The present case was a rare intradiploic meningioma. Further investigation by MRI can identify ectopic meningiomas, which do not exhibit the usual paramagnetic contrast enhancement.

The clinical presentation of the present case is similar to that found in previously reported cases of skull tumors, usually headaches and an often painless, palpable mass on the scalp or skull [2,4,10,11,12,15]. Involvement of other ectopic sites such as the paranasal sinuses and orbit usually manifests as pain and proptosis [16], whereas pain and a palpable mass are common when the tumor affects more distant sites. Histologic examination

usually presents meningotheial meningiomas, but the microcystic [8] or lipomatous [14] variations are also reported. Immunohistochemical staining is usually positive for progesterone receptor, epithelial membrane antigen as in our described case, and S100 [8,14].

In 1960, Hoyer et al. [17] reviewed the latest case reports and proposed the classification of ectopic meningiomas into four types: (1) intracranial tumors with extracranial extension; (2) meningiomas originating in cranial nerve sheaths; (3) extracranial tumors without any connection to cranial nerve foramina; (4) intracranial benign lesions with extracranial metastases. In 2000, Lang et al. [18] described a similar, but simpler classification: type 1, purely extracalvarial tumors; type 2, purely calvarial tumors, and type 3, calvarial tumors with extracalvarial extension. Each type is further divided according to location into skull base (S) or calvarial (C) lesions. Our case is classified as type 3 in Hoyer's classification and type 2 in Lang's classification, since the lesion was restricted to the skull (inner and outer tables), showing no dural invasion on histopathological examination, supporting the hypothesis that the tumor originated in the diploic layer.

Some theories have been offered to explain how a meningioma can appear distant from the usual arachnoid cap cells (meningocytes) [19,20]. One theory suggests that embryological remains of neuroectodermal tissue, which should develop into cap cells, can expand [21] or erroneously migrate to other tissues [4,20]. Other theories that could account for some cases are the spreading of

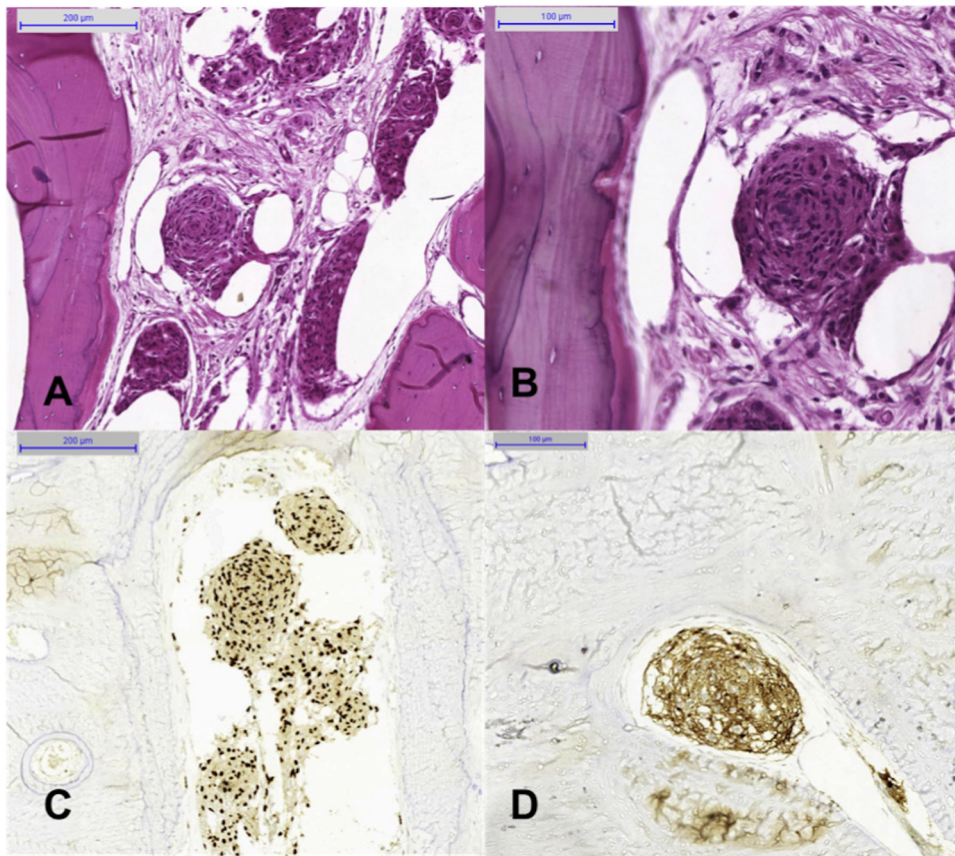


Fig. 3. Photomicrographs showing islands of eosinophilic cells arranged in clusters and whorls in the bone fragment. Note the absence of nuclear pleomorphism. H&E, 100× (A) and 200× (B). Positive immunohistochemical staining for progesterone receptor (C, 100×) and epithelial membrane antigen (D, 200×).

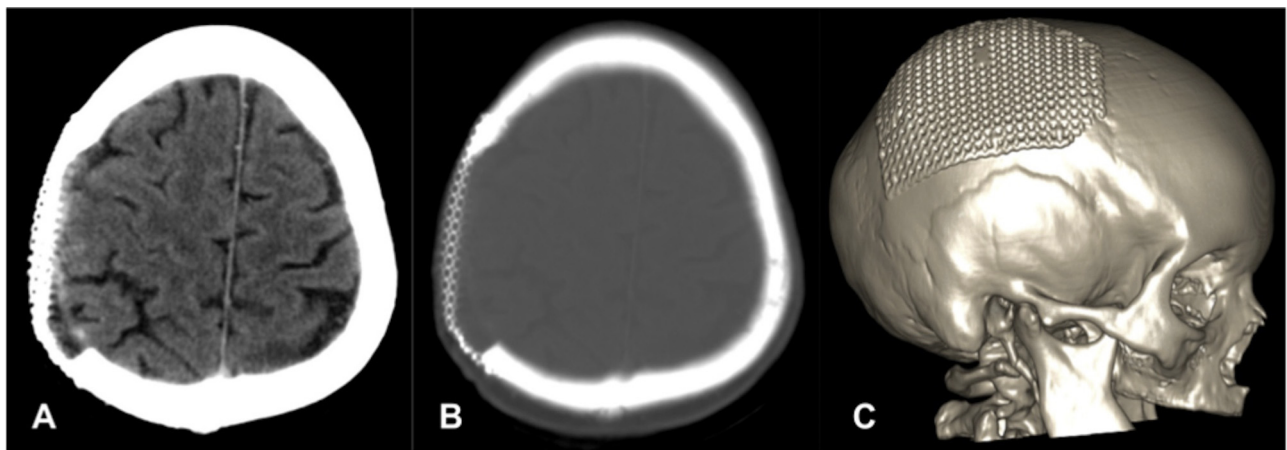


Fig. 4. A 10-month postoperative head CT scan showing the right parietal craniotomy with the reconstructive titanium mesh and absence of residual lesions. A: brain window; B: bone window; C: 3D reconstruction.

these remnant cells due to trauma, dural lesions, or cells entrapped in cranial sutures and cranial nerve sheaths [22,23]. Some authors proposed the occurrence of dedifferentiation of cells in extracranial tissues, which develop into neoplastic meningocytes [2,24]. None of these theories could be confirmed in the present case, but a probable intradiploic origin is suggested.

Overall, most meningiomas, including ectopic tumors, are benign; therefore, their complete surgical excision should be the rule [2,8,9,21]. Partial resection of residual lesions can be monitored radiologically, while adjuvant therapies such as radiation may provide an alternative for symptomatic and surgically difficult cases [5].

4. Conclusions

Ectopic meningiomas are uncommon, whereas intraosseous meningiomas are even rarer. These tumors are usually benign, without a fully elucidated natural history. Surgical resection remains the only curative option.

Conflict of interest

None declared.

Funding

None.

Ethical approval

Written informed consent was obtained from the patient for publication of this case report and accompanying images. A copy of the written consent is available for review by the Editor-in-Chief of this Journal.

Consent

Written informed consent was obtained from the patient for publication of this case report and accompanying images.

Author's contributions

RBV: drafted and designed the manuscript and participated in surgery; PTHF: drafted and coordinated the manuscript; RLL: participated in surgery and reviewed the Literature for previous cases; VZM and FOL: analyzed the pathological and histological materials; FRR: coordinated surgery and grammatical review. MAZ: performed the final review. All authors read and approved the final manuscript.

References

- [1] R.H. Wong, A.K. Wong, N. Vick, et al., Natural history of multiple meningiomas, *Surg. Neurol. Int.* 4 (2013) 71.
- [2] B. Cirak, M.B. Guven, S. Ugras, et al., Fronto-orbitonasal intradiploic meningioma in a child, *Pediatr. Neurosurg.* 32 (1) (2000) 48–51.
- [3] S. Kobayashi, K. Kyoshima, F. Nakagawa, et al., Diploic meningioma of the orbital roof, *Surg. Neurol.* 13 (4) (1980) 277–281.
- [4] K. Kuzeyli, S. Duru, S. Baykal, et al., Primary intraosseous meningioma of the temporal bone in an infant. A case report, *Neurosurg. Rev.* 19 (3) (1996) 197–199.
- [5] T.S. Crawford, B.K. Kleinschmidt-DeMasters, K.O. Lillehei, Primary intraosseous meningioma. Case report, *J. Neurosurg.* 83 (5) (1995) 912–915.
- [6] D. Selva, V.A. White, J.X. O'Connell, et al., Primary bone tumors of the orbit, *Surv. Ophthalmol.* 49 (3) (2004) 328–342.
- [7] H.W. Farr, G.F. Gray Jr., M. Vrana, et al., Extracranial meningioma, *J. Surg. Oncol.* 5 (5) (1973) 411–420.
- [8] J.E. Velazquez Vega, A.E. Rosenberg, Microcystic meningioma of the calvarium: a series of 9 cases and review of the Literature, *Am. J. Surg. Pathol.* (2014).
- [9] S. Budhdeo, R.A. Ibrahim, M. Hofer, et al., Primary intraosseous osteoblastic meningioma, *JRSM Short Rep.* 2 (6) (2011) 52.
- [10] N. Muthukumar, Primary calvarial meningiomas, *Br. J. Neurosurg.* 11 (5) (1997) 388–392.
- [11] N. Tokgoz, Y.A. Oner, M. Kaymaz, et al., Primary intraosseous meningioma: CT and MRI appearance, *AJNR Am. J. Neuroradiol.* 26 (8) (2005) 2053–2056.
- [12] V. Agrawal, N. Ludwig, A. Agrawal, et al., Intraosseous intracranial meningioma, *AJNR Am. J. Neuroradiol.* 28 (2) (2007) 314–315.
- [13] V. Tang, M. Lam, A. Lai, Intraosseous meningioma mimicking a metastasis, *BMJ Case Rep.* 2014 (2014), <http://dx.doi.org/10.1155/2015/482140>, <http://www.hindawi.com/journals/crinm/2015/482140/>
- [14] L. Kim, C. Huang, A.L. Morey, et al., Intraosseous lipomatous meningioma, *Case Rep. Neurol. Med.* 2015 (2015) 482140.
- [15] A. Akhaddar, H. Ennouali, Intraosseous extradural meningioma of the frontal bone, *Pan Afr. Med. J.* 17 (2014) 69.
- [16] R.H. Daffner, R. Yakulis, J.C. Maroon, Intraosseous meningioma, *Skeletal Radiol.* 27 (2) (1998) 108–111.
- [17] S.J. Hoye, C.S. Hoar Jr., J.E. Murray, Extracranial meningioma presenting as a tumor of the neck, *Am. J. Surg.* 100 (1960) 486–489.
- [18] F.F. Lang, O.K. Macdonald, G.N. Fuller, et al., Primary extradural meningiomas: a report on nine cases and review of the literature from the era of computerized tomography scanning, *J. Neurosurg.* 93 (6) (2000) 940–950.
- [19] G.N. Marta, S.F. Correa, Teixeira M.J. Meningioma, review of the literature with emphasis on the approach to radiotherapy, *Expert Rev. Anticancer Ther.* 11 (11) (2011) 1749–1758.
- [20] N. Altinors, A. Cetin, I. Pak, Scalp meningioma: case report, *Neurosurgery* 16 (3) (1985) 379–380.
- [21] J.B. Elder, R. Atkinson, C.S. Zee, et al., Primary intraosseous meningioma, *Neurosurg. Focus* 23 (4) (2007) E13.
- [22] F. Kaneko, K. Takase, K. Nishiyama, et al., Report of a case of intraosseous meningioma, *No Shinkei Geka* 16 (2) (1988) 197–202.
- [23] B. Azar Kia, M. Sarwar, J.A. Marc, et al., Intraosseous meningioma, *Neuroradiology* 6 (5) (1974) 246–253.
- [24] S. Shuangshoti, M.G. Netsky, G.S. Fitz-Hugh, Parapharyngeal meningioma with special reference to cell of origin, *Ann. Otol. Rhinol. Laryngol.* 80 (3) (1971) 464–473.

Open Access

This article is published Open Access at sciedirect.com. It is distributed under the [IJSCR Supplemental terms and conditions](#), which permits unrestricted non commercial use, distribution, and reproduction in any medium, provided the original authors and source are credited.