



Case report

Echinococcus granulosus hydatid cyst in rural Manitoba, Canada: Case report and review of the literature



Steven Grocholski^a, Salem Agabawi^{a,b,*}, Kamran Kadkhoda^d, Gregory Hammond^{b,c}

^a Department of Internal Medicine, Rady Faculty of Health Sciences, University of Manitoba, Winnipeg, MB, Canada

^b Section of Infectious Diseases, Rady Faculty of Health Sciences, University of Manitoba, Winnipeg, MB, Canada

^c Department of of Medical Microbiology & Infectious Diseases, Rady Faculty of Health Sciences, University of Manitoba, Winnipeg, MB, Canada

^d Immunopathology Laboratory, Main Campus, Cleveland Clinic, Cleveland, OH, USA

ARTICLE INFO

Article history:

Received 19 June 2019

Accepted 4 September 2019

Keywords:

Echinococcal granulosus

Echinococcal disease

Hydatid cyst

Parasitic infection

Hepatic cyst

ABSTRACT

Echinococcal infections are a rare but important disease in Canada. The parasite's traditional endemic area includes rural, northern communities with wild canines and ungulates. There is evidence that the endemic area is enlarging. *Echinococcus* can cause significant morbidity, and rarely death. An 18-year-old female presented with right upper quadrant abdominal pain. Computed Tomography (CT) of the abdomen showed a 5.4 × 4 cm cyst with the presence of "water lily sign". She showed signs of cyst leak including eosinophilia and fever. Therefore, she underwent surgical resection of her cyst with Albendazole cover and was continued post-operatively for three months. CT head, chest, and pelvis failed to identify further sites of cyst formation. She has recovered well from surgery and is no longer followed by Infectious Diseases. The annual incidence and prevalence of *Echinococcus* disease are very low among the Canadian population. Therefore, there is a paucity of experience with new interventional techniques. Traditional management with surgery and anti-helminthic drugs is a reasonable alternative to percutaneous drainage. Screening communities has previously been determined not to be cost effective. Screening family members with similar risk factors has not been previously documented, and treatment has historically been reserved for symptomatic individuals with the disease.

© 2019 Published by Elsevier Ltd. This is an open access article under the CC BY-NC-ND license (<http://creativecommons.org/licenses/by-nc-nd/4.0/>).

Introduction

Echinococcus is a rare parasitic infection in Canada, with a defined incidence of 0.14 infections/100,000 [1]. It is a helminth with a complex life cycle. Canines, including wolves, foxes, and dogs are definitive hosts. Ungulates such as moose, deer, and elk are intermediate [2,3]. Intermediate hosts ingest Echinococcal eggs, which then develop into cysts. Cysts can form in any organ system but have a preponderance for the liver and GI tract. Intermediate hosts are consumed by the definitive host, with the transfer of the cyst. Cysts then develop into the adult worm in the GI tract of the definitive host, producing eggs. The life cycle then repeats. There is evidence that the endemic area of echinococcosis is enlarging, with the recent spread of the parasites to southwestern Ontario [1]. Climate change has the potential to change the endemic area for both species of *Echinococcus* in Canada through changing ungulate

migration patterns, and effects on Echinococcal eggs by humidity and temperature [4]. *E. canadensis*, a type of *E. granulosus*, is the major endemic *Echinococcus* in Canada and found throughout much of the country [5]. *Echinococcus multilocularis* is also found in Canada. Distribution of *E. multilocularis* is dependant on haplotype [6]. There are currently no cost-effective screening or treatment programs in Canada [1]. In this article, we present the investigation and treatment decisions of a single patient in Manitoba.

Case presentation

An 18-year-old Caucasian female presented to a rural nursing station with a two-month history of right upper quadrant abdominal pain. The pain increased in severity over 48 h. She was transferred to Winnipeg with suspected cholecystitis. Upon arrival, she was febrile and tachycardic. She was fluid resuscitated and prescribed Piperacillin-Tazobactam for treatment of suspected biliary sepsis. She received two infusions of Vancomycin while her syndrome remained undifferentiated. A CT of her abdomen showed cyst formation in segments 2 and 3 of her liver measuring 5.4 × 4 cm in maximal diameter (Fig. 1). Water lily sign was present within the cyst. Sludge was present in the biliary tree.

* Corresponding author at: Max Rady College of Medicine, University of Manitoba, 807K John Buhler Research Centre, 727 McDermot Avenue, Winnipeg, MB, R3E 3P5, Canada.

E-mail address: salem.agabawi@gmail.com (S. Agabawi).

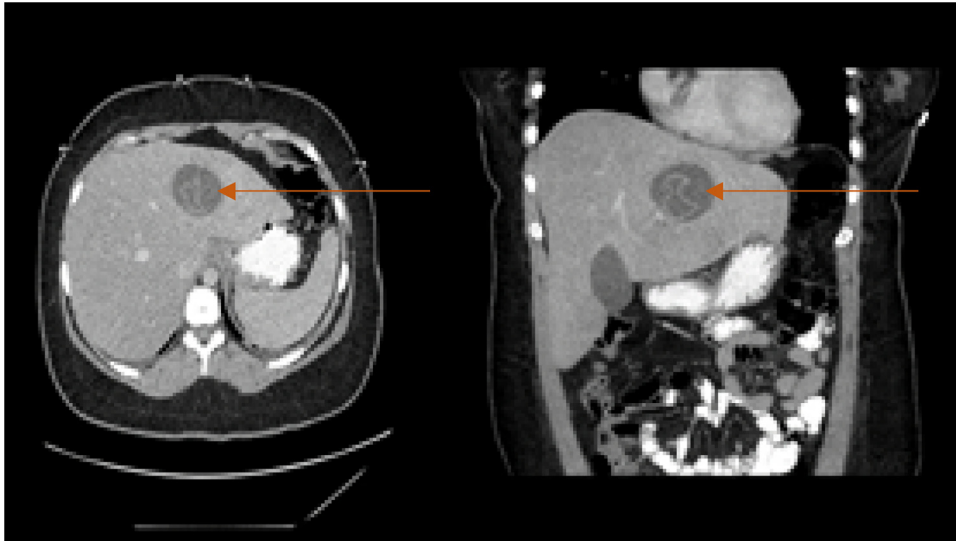


Fig. 1. CT Abdomen showing a cyst in the left lobe of the liver with the presence of a “water-lily sign”.

Infectious Diseases was consulted, and further history was obtained. The patient lived in a rural community with her family. She enjoyed hunting. Her family butchered and consumed meat obtained through hunting; including moose, elk, deer, and bear. They did not consume the liver and owned one dog, adopted within the last two years. She had one prior dog which died ten years before her presentation. Her family owned a large vegetable garden, and the patient consumed raw vegetables throughout her life. Fox and wolves were frequently seen in the patient’s yard.

The patient was empirically started on Albendazole 400 mg twice a day by mouth for the suspected Echinococcal cyst. Anti-echinococcal serology was ordered. Serology is processed at the National Reference Center for Parasitology in Montreal, Quebec, and results were not immediately available. The patient remained intermittently febrile over the next 48 h. Total blood eosinophil count peaked at 0.95×10^9 cells/L; accounting for 10.3% of the total white blood cell count. MRI was performed to determine if a cyst leak was present (Fig. 2). Images again showed a suspected echinococcal cyst with “water lily sign”. No definitive comments could be made on vascularization.

The patient’s case was discussed with both Interventional Radiology and General Surgery. As there was no in-house experience in PAIR (Percutaneous Aspiration, Irrigation with scolicide, and Re-aspiration), the patient underwent definitive management of her cyst through General Surgery. This included open laparotomy with complete left hepatic lobe resection and cholecystectomy.

Surgery was unremarkable. Intra-operative cyst aspiration was completed. Specimens were submitted to parasitology and pathology laboratory. Microscopic examination confirmed echinococcal infection with hooklets and protoscoloces seen (Fig. 3). Liver tissue showed infiltration with eosinophils. Gallbladder pathology showed cholecystitis, but no parasite infiltration. A residual specimen was also sent to the National Reference Centre for Parasitology (NRCP) in Montreal, Canada, for Echinococcal polymerase chain reaction and subsequently tested positive for *E. granulosus* using species-specific primers. A serum sample also tested highly positive for *Echinococcus* at NRCP.

The patient’s postoperative course was uneventful. Cessation of fevers and resolution of her eosinophilia occurred immediately post-operatively. Piperacillin-Tazobactam was discontinued on the first postoperative day. She received Ceftriaxone 2 g IV daily and Metronidazole 500 mg IV three-times daily to complete a total of 12 days of antibiotic therapy for cholecystitis. She was successfully discharged home on postoperative day five.

Albendazole treatment was prescribed for a further three months. She was followed by Infectious Diseases as an outpatient. She underwent CT head, chest, and pelvis to screen for cyst formation in other organ systems. None were found. At three months post-operative she remained well with no eosinophilia on CBC. Serology to *Echinococcus* was reviewed, confirming infection with *E. granulosus*. She was discharged from the Infectious Disease clinic.

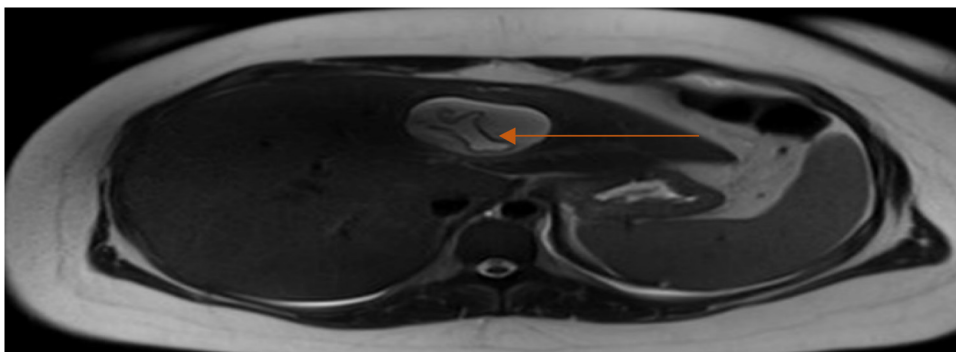


Fig. 2. MRI Liver showing water lily sign in the left lobe of the liver.

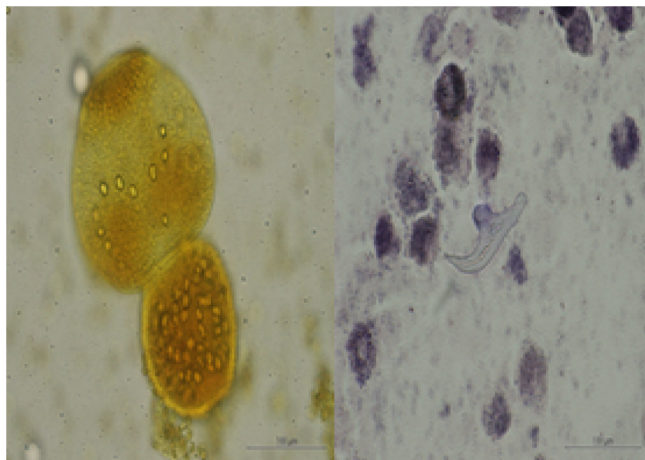


Fig. 3. Light microscopy of aspirated contents of the resected hepatic cyst. The image on left (wet mount stained with iodine solution) shows a typical scolex. The image on the right (iron hematoxylin/modified acid-fast combination stain) shows a hooklet (pictures taken at Cadham Provincial Laboratory by K Kadkhoda).

Discussion

Echinococcus is a helminth with a complex life cycle. In Canada, the most common form of *Echinococcus* is *E. granulosus*, specifically, *E. canadensis* [5]. Three canine infections in South-western Ontario have recently been identified, a place previously thought to be free of *Echinococcus*. With changing animal migration patterns, and changing patterns of human movement, it is thought that the endemic regions of *Echinococcus* are expanding. It is an important, but rare disease, as infection can lead to significant morbidity, and rarely, death. The recent serosurveillance study showed an exposure rate of Cystic *Echinococcosis* (CE) among indigenous population varied from less than 10% in Quebec and eastern Saskatchewan to 48% in Northwestern Saskatchewan [7]. The largest case series of Canadian-acquired echinococcal hepatic hydatid cyst was reported in Manitoba [8]. Additional case series reported from Alberta identified a total of 42 cases [9]. Despite this, it is considered an uncommon infectious disease in Canada.

Echinococcal infections can be definitively diagnosed through a combination of imaging and serology [10]. Imaging can aid in the diagnosis pre-operatively, with CT or MR of the cyst showing a typical “water lily sign”. “The water lily sign” is formed by the cyst membrane surrounded by peri-cyst fluid. The membrane moves with position, giving the appearance of a water-lily floating in a pond. Serology can aid the diagnosis of *Echinococcus*, however, the advanced Parasitology reference center for Canada is located in Montreal, and results may not be available prior to definitive management. Direct light microscopy can identify *Echinococcus* by its distinct features [11]. Typical morphologic features include hooklets and a proboscis.

Several options for management of echinococcal cysts are detailed in the literature. Echinococcal cysts can be approached medically or through direct intervention with aspiration or surgery [10,12]. A large treatment cohort was documented in a Turkish population with a much higher incidence of disease than Canada [13]. This case series documents 101 patients with combined medical and surgical treatment, with a significant decrease in cyst recurrence compared to surgical resection alone. The optimal post-surgical duration of anthelmintic drugs remains controversial but may be up to 3 months, through a randomized control trial of 77 patients has shown no difference in recurrence rate when treated with one month of Albendazole compared to three months of

treatment [12,14]. Several cohorts have documented successful treatment with PAIR (Percutaneous Aspiration, Injection of scolicide, and re-aspiration). This is a reasonable alternative to surgery in a setting with procedural expertise.

There is no population screening program for *echinococcal* cysts in Canada. Surveillance in a northern Saskatchewan community of human exposure to *E. granulosus* using serology showed that up to 11% of people may be exposed [15]. Using a quality-adjusted life year analysis of 20 000 dollars per case discovered, it was found that empirically treating dogs for *Echinococcus* would not be financially viable even in the highest prevalence regions of Canada [1]. Treatment of echinococcal cysts has previously been focused on symptomatic patients, as the parasite is slow growing, and may not cause morbidity during an individual’s lifespan. There is no evidence for screening even close relatives of incident cases, as it is unclear if they should undergo treatment.

Echinococcus may be an emerging disease in Canada. To date, the Canadian experience with investigation and treatment decisions has not been widely published. We present a case of the cystic echinococcal disease in an 18-year-old Caucasian female. In regions with low incidence, traditional approaches to management including surgery and prolonged anti-helminthic therapy are a reasonable course of action. A cost-effective management plan for close contacts with similar risk factors is to maintain a high level of suspicion for disease if these family members come to medical attention in the future.

Funding

There was no financial support received for this case.

Consent

Written informed consent was obtained from the patient for publication of this case report and accompanying images. A copy of the written consent is available for review by the Editor-in-Chief of this journal on request”.

Declaration of Competing Interest

There are no conflicts of interest with the report’s authors.

References

- [1] Schurer JM, Rafferty E, Farag M, Zeng W, Jenkins EJ. Echinococcosis: an economic evaluation of a veterinary public health intervention in rural Canada. *PLoS Negl Trop Dis* 2015;9(7):1–15.
- [2] Webster GA, Cameron TW. Epidemiology and diagnosis of echinococcosis in Canada. *Can Med Assoc J* 1967;96(10):600–7.
- [3] Poole JB. Echinococcus disease in Northern North America. *Am J Trop Med Hyg* 1957;6(3):424–9.
- [4] Jenkins EJ, Schurer JM, Gesy KM. Old problems on a new playing field: helminth zoonoses transmitted among dogs, wildlife, and people in a changing northern climate. *Vet Parasitol* 2011;182(1):54–69.
- [5] Cerda J, Buttke D, Ballweber L. *Echinococcus* spp. tapeworms in North America. *Emerg Infect Dis* 2018;24(2):230–5.
- [6] Schurer JM, Ndao M, Quewezance H, Elmore SA, Jenkins EJ. People, pets, and parasites: one health surveillance in Southeastern Saskatchewan. *Am J Trop Med Hyg* 2014;90(6):1184–90.
- [7] Al Saghier M, Taylor MC, Greenberg HM. Canadian-acquired hydatid disease: a case report. *Can J Infect Dis* 2001;12(3):178–82.
- [8] Somily A, Robinson JL, Miedzinski LJ, Bhargava R, Marrie TJ. Echinococcal disease in Alberta, Canada: more than a calcified opacity. *BMC Infect Dis* 2005;5:34.
- [9] Gesy KM, Schurer JM, Massolo A, Liccioli S, Elkin BT, Alisaukas R, et al. Unexpected diversity of the cestode *Echinococcus multilocularis* in wildlife in Canada. *Int J Parasitol Wildl* 2014;3(2):81–7.
- [10] Mihmanli M, Idiz UO, Kaya C, Demir U, Bostanci O, Omeroglu S, et al. Current status of diagnosis and treatment of hepatic echinococcosis. *World J Hepatol* 2016;8(28):1169.
- [11] Saenz-Santamaria J, Moreno-Casado J, Nuñez C. Role of fine-needle biopsy in the diagnosis of hydatid cyst. *Diagn Cytopathol* 1995;13(3):229–32.

- [12] Keong B, Wilkie B, Sutherland T, Fox A. Hepatic cystic echinococcosis in Australia: an update on diagnosis and management. *ANZ J Surg* 2018;88(1–2):26–31.
- [13] Karabulut K, Ozbalci GS, Kesicioglu T, Tarim IA, Kamalli Polat A, Karabickak I, et al. Long-term outcomes of intraoperative and perioperative albendazole treatment in hepatic hydatidosis: single center experience. *Ann Surg Treat Res* 2014;87(2):61–5.
- [14] Akhan O, Yildiz AE, Akinci D, Yildiz BD, Ciftci T. Is the adjuvant albendazole treatment really needed with PAIR in the management of liver hydatid cysts? A prospective, randomized trial with short-term follow-up results. *Cardiovasc Intervent Radiol* 2014;37(6):1568–74.
- [15] Himsworth CG, et al. Emergence of sylvatic *Echinococcus granulosus* as a parasitic zoonosis of public health concern in an indigenous community in Canada. *Am J Trop Med Hyg* 2010;82(4):643–5.