



Case Report

Duodenal perforation after gastrostomy tube replacement: Case report and literature review

Hsiao-Hui Yang^a, Chia-Jung Ke^a, Ting-Han Shih^{b*}

^aDivision of General Surgery, Department of Surgery, Hualien Tzu Chi Hospital, Buddhist Tzu Chi Medical Foundation, Hualien, Taiwan, ^bDivision of Colorectal Surgery, Department of Surgery, Hualien Tzu Chi Hospital, Buddhist Tzu Chi Medical Foundation, Hualien, Taiwan

Received : 11-Jul-2018
Revised : 07-Aug-2018
Accepted : 26-Sep-2018

ABSTRACT

Gastrostomy is commonly used to provide long-term enteral access for patients with feeding impairment. Routine replacement is a safe procedure, but it has various complications. We present a case of nasopharyngeal cancer, who visited the emergency department for gastrostomy tube dislodgement. Diffuse abdominal pain developed 3 days after replacement of the gastrostomy tube with a temporary silicone Foley tube. Emergency diagnostic laparoscopy was performed and found tip migration and causing duodenal perforation. Tip migration and compression necrosis of mucosa were the possible mechanisms. The condition was successfully treated by emergency laparoscopic duodenorrhaphy.

KEYWORDS: Duodenal perforation, Gastrostomy, Replacement

INTRODUCTION

Gastrostomy is commonly used to provide long-term enteral nutrition to patients with feeding impairment, such as dysphagia, or in whom insertion of nasogastric tube is impossible. Several conduits are available: with or without a balloon or an external bumper. Regular replacement is needed for long-term access. Some complications associated with gastrostomy tube replacement were reported, such as fistula tract disruption, gastric outlet obstruction, gastric ulcer, cholangitis, and pancreatitis [1]. Duodenal perforation due to tube migration or erosion is rare, and we herein present a case with a short literature review.

CASE REPORT

A 33-year-old female patient with nasopharyngeal carcinoma, who was receiving chemoradiotherapy and gastrostomy feeding because of dysphagia, visited the emergency department for gastrostomy tube dislodgement. A temporary 20 Fr silicone Foley tube was re-inserted without fixation on the skin. After insertion, kidney, ureter, and bladder radiography showed contrast medium passing through the small intestines [Figure 1a]. However, the patient developed vomiting and diffuse abdominal pain 3 days later, which were aggravated by gastrostomy feeding. Physical examination revealed diffuse abdominal tenderness without peritoneal signs. Supine abdomen radiography showed the advancement of the balloon of the Foley tube. Abdominal computed tomography (CT) revealed malposition of the Foley tube with free air around the third portion of the duodenum [Figure 1b]. Emergency diagnostic laparoscopy was performed for duodenal perforation.

Two working ports were inserted via the right and left upper quadrants. During the operation, we found intact gastrostomy fistula tract, but the tissue near the third portion of the duodenum was necrotic. The mesocolon was opened between the ileocolic artery and the duodenum. A 5 mm perforated hole and the tip of the Foley tube were found outside the duodenum [Figure 2]. Laparoscopic duodenorrhaphy was done without the available omental patch. A 24 Fr gastrostomy tube was re-inserted for future feeding, and jejunostomy for temporary feeding was performed as well. She recovered well and started gastrostomy feeding on day 5 after the operation without evidence of leakage and was discharged on that day. The jejunostomy tube was removed 1 month later, and she is currently undergoing chemotherapy.

DISCUSSION

Gastrostomy feeding is the usual choice for long-term enteral nutrition in patients who cannot tolerate oral feeding. The gastrostomy tube can be placed percutaneously, laparoscopically or using the open method. Each technique has its advantages and disadvantages, but they all share similar complications, with rates of 73% for minor complications and 5% for major ones [2]. Minor complications include wound infection, tube leakage, and tube dislodgement, whereas major


*Address for correspondence:

Dr. Ting-Han Shih,
Division of Colorectal Surgery, Department of Surgery, Hualien Tzu Chi General Hospital, Buddhist Tzu Chi Medical Foundation, 707, Section 3, Chung-Yang Road, Hualien, Taiwan.
E-mail: atpsam@gmail.com

This is an open access journal, and articles are distributed under the terms of the Creative Commons Attribution-NonCommercial-ShareAlike 4.0 License, which allows others to remix, tweak, and build upon the work non-commercially, as long as appropriate credit is given and the new creations are licensed under the identical terms.

For reprints contact: reprints@medknow.com

How to cite this article: Yang HH, Ke CJ, Shih TH. Duodenal perforation after gastrostomy tube replacement: Case report and literature review. Tzu Chi Med J 2019;31(4):280-2.

Access this article online	
Quick Response Code: 	Website: www.tcmjmed.com
	DOI: 10.4103/tcmj.tcmj_122_18

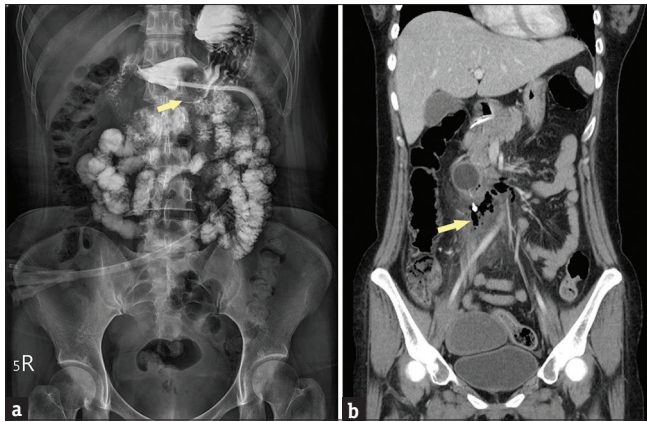


Figure 1: (a) Abdominal radiography showing the contrast medium from gastrostomy passing through the small intestines. The balloon of the Foley tube was found in the antrum of the stomach (arrow). (b) Computed tomography showing the balloon of the Foley tube that advanced to second portion of the duodenum. Free air and fat stranding were noted around the tip of the Foley tube (arrow), leading to suspicion of duodenal perforation

complications include gastric outlet obstruction, gastrocolic fistula, and peritonitis due to leakage of gastric content or food into the peritoneal cavity. Scheduled replacements are usually safe and are done nonsurgically by the bedside. The reported complication rate for replacement is 1.3%; the most common complication is fistula tract disruption, which can be critical if peritonitis occurs [3]. Other complications, such as gastric outlet obstruction, colocutaneous fistula, cholangitis, pancreatitis, and esophageal or intestinal perforation, had been reported as well [1].

The types of gastrostomy tube are percutaneous endoscopic gastrostomy (PEG) and low-profile balloon gastrostomy [4]. PEG uses devices with internal retention disc and external fixation plate. Low-profile balloon gastrostomy is used for well-established stomas (4–6 weeks after open gastrostomy) owing to the button devices. The button devices can be divided into two types: obturated (with a mushroom-shaped tip as the internal retention device) and nonobturated (with a balloon tip as the internal retention device and an external stabilizer to prevent migration). The nonobturated type is most commonly used for routine replacement. A Foley catheter may also be used as a temporary replacement gastrostomy tube when the gastrostomy tube is not available. However, migration due to inadequate anchoring to the skin, gastrointestinal peristalsis [5] and absence of interval markings on the shaft to recognize is a problem.

Moriwaki *et al.* [6] first reported duodenal perforation due to compression necrosis by the tip of the PEG tube. A similar mechanism, such as ball bulb syndrome, was proposed, which is gastroduodenal obstruction by incarceration of the gastric submucosal tumor. Kim *et al.* [1] reported a pediatric case of intussusception of the duodenum into the stomach and duodenal perforation after gastrostomy replacement. The appropriate gastrostomy tube, balloon volume, and catheter length, bearing in mind the small size of the stomach of children, should be taken into consideration. Rossidis *et al.* [7] reported a case of distal duodenal perforation after Stamm gastrostomy creation using a 20-Fr silicone Foley catheter. The patient recovered

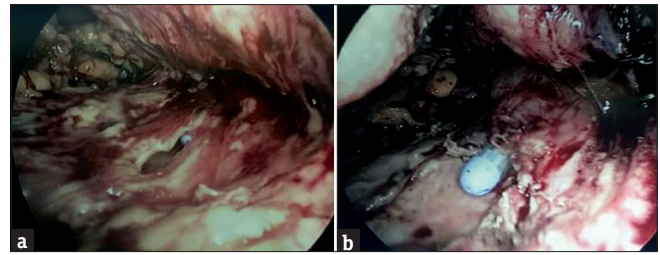


Figure 2: Kocher's maneuver was performed, entering the retroperitoneal cavity. (a) Necrotic tissue and a perforated hole on the third portion of the duodenum were noted during blunt dissection. (b) The tip of the Foley tube was found penetrating the duodenal wall

well after emergency suture repair with the omental patch. Migration of silicone Foley catheter due to the absence of bumper and compression necrosis due to the relatively rigid tip was the likely mechanisms. In our case, a 20 Fr silicone Foley tube was used for temporary gastrostomy without external anchoring. Duodenal perforation developed 3 days later, with balloon migration and tip compression as the possible causes.

Mucosal ulceration due to traumatic injury from the protruding tip of balloon-type gastrostomy tube has been reported by Seidner and Ghanta [8]. Overinflation of the balloon also played a role. Relocating or replacing the tube with a low-profile internal bumper, instead of proton pump inhibitor or acid-suppression agents, resolved the ulceration and bleeding in their case. The use of histamine H₂-receptor antagonists had no significant impact on and may not prevent gastric ulcers [9]. Appropriate placement and gastrostomy tube are the ways to prevent ulcerations.

In our case, the duodenal perforation was confirmed by CT and needed emergency operation due to peritonitis. We chose diagnostic laparoscopy first, and the whole procedure was completed by laparoscopy. The postoperative course was uneventful. This is the first report on gastrostomy complicated by duodenal perforation that was managed by laparoscopy. The advantages of laparoscopy are decreased postoperative pain, early recovery, and early ambulation, which are associated with improved safety and effectiveness.

CONCLUSION

Based on our experience, replacement of the gastrostomy tube with a temporary Foley catheter can cause duodenal perforation due to tip migration and compression necrosis of mucosa by balloon. External anchoring should be performed and replaced as soon as possible with a button device, even surgically if needed. For duodenal perforation, emergency management by laparoscopic repair is safe but should be thoroughly explained to the patient and performed with great caution.

IRB Approval

The report had been approved by the Research Ethics Committee of Hualien Tzu Chi Hospital, Buddhist Tzu Chi Medical Foundation, for case report publication. (CR 107-06) IRB agrees to waive the patient consent.

Financial support and sponsorship

Nil.

Conflicts of interest

There are no conflicts of interest.

REFERENCES

1. Kim SH, Min SH, Kim HY, Jung SE. Duodenal perforation: Unusual complication of gastrostomy tube replacement. *Pediatr Gastroenterol Hepatol Nutr* 2014;17:112-5.
2. Friedman JN, Ahmed S, Connolly B, Chait P, Mahant S. Complications associated with image-guided gastrostomy and gastrojejunostomy tubes in children. *Pediatrics* 2004;114:458-61.
3. Nishiwaki S, Araki H, Fang JC, Hayashi M, Takada J, Iwashita M, et al. Retrospective analyses of complications associated with transcutaneous replacement of percutaneous gastrostomy and jejunostomy feeding devices. *Gastrointest Endosc* 2011;74:784-91.
4. The Agency for Clinical Innovation and the Gastroenterological Nurses College of Australia. A clinician's guide: Caring for people with gastrostomy tubes and devices from pre-insertion to ongoing care and removal. Version 1.2. Chatswood (NSW): The Agency for Clinical Innovation and the Gastroenterological Nurses College of Australia; 2015.
5. Soscia J, Friedman JN. A guide to the management of common gastrostomy and gastrojejunostomy tube problems. *Paediatr Child Health* 2011;16:281-7.
6. Moriwaki Y, Arata S, Tahara Y, Toyoda H, Kosuge T, Suzuki N, et al. Duodenal perforation due to compression necrosis by the tip of percutaneous endoscopic gastrostomy tube. *Nutrition* 2011;27:979-81.
7. Rossidis AC, Raper SE, Dumon KR. Duodenal perforation as a complication of gastrostomy tube migration. *JRSM Open* 2017;8:2054270417692709.
8. Seidner DL, Ghanta RK. Management of a traumatic gastric ulcer with a low-profile gastrostomy tube. *Nutr Clin Pract* 2005;20:88-92.
9. Kanie J, Akatsu H, Suzuki Y, Shimokata H, Iguchi A. Mechanism of the development of gastric ulcer after percutaneous endoscopic gastrostomy. *Endoscopy* 2002;34:480-2.