

# INDUCTION OF ACUTE CHOLECYSTITIS BY ACTIVATION OF FACTOR XII\*

By CARL G. BECKER, THEODORE DUBIN, AND FRANK GLENN

*From the Departments of Pathology and Surgery, The New York Hospital-Cornell University Medical Center, New York 10021*

Acute, acalculous cholecystitis is a serious, often fatal disease that is seen among patients suffering with bacterial sepsis, burns, or trauma, including surgical trauma, and cancer (1). In 1921, F. C. Mann (2) of the Mayo Clinic induced acute inflammation and hemorrhage in the gall bladder of dogs by intravenous injection of solutions of sodium hypochloride. Mann's experiments (2) indicated that the gall bladder could be injured by intravenous injection of a known chemical substance and/or a chain of events set in motion by such an injection.

Factor XII (Hageman factor) can be activated by bacterial endotoxin and by exposure of plasma to collagen (3, 4). It is possible in the clinical settings mentioned above that induction of acute cholecystitis results from the activation of the intrinsic pathway of coagulation leading to generation of mediators of inflammation.

To test this hypothesis we injected dogs and monkeys intravenously with chemically defined polyphenol activators of factor XII, with *Escherichia coli* endotoxin, or with buffered saline and observed the effects of systemic activation of factor XII-dependent pathways on the gall bladder and other tissues. The results of these experiments are described below.

## Materials and Methods

*Experimental Protocol.* 12 mongrel male dogs that weighed between 8 and 15 kg, and 3 male African Green Monkeys (*Cercopithecus aethiops*) that weighed between 4 and 6 kg, were used. The animals were anesthetized by intravenous injection of pentobarbital, and under surgical conditions the abdomen was opened and the gall bladder visualized. Besides the gall bladder, the stomach, duodenum, small bowel, colon, mesentery, liver, and spleen were clearly visible in the operative field.

Animals were injected in the femoral vein with  $10^{-4}$  M solutions of ellagic acid (K and K Laboratories, Inc., Plainview, N. Y.), rutin (Sigma Chemical Co., St. Louis, Mo.), or with lipopolysaccharide W *E. coli* O128:B12 (Difco Laboratories, Detroit, Mich.), all dissolved in phosphate-buffered physiologic saline (PBS),<sup>1</sup> or with PBS in comparable volume as control according to the plan in Table I.

Blood samples were obtained before injection of solutions of ellagic acid, rutin, *E. coli* endotoxin, or PBS, at intervals thereafter either by venopuncture with plastic syringes or through a polyethylene catheter implanted in the femoral vein, and anticoagulated with Na citrate in chilled plastic tubes for studies described below.

The gall bladder and other viscera were observed for 1 h after injection of activator substance or control PBS, and photographs taken at different intervals during this period. At the end of

---

\* This work was supported by National Institutes of Health grants HL 18828 and HL 01803, a grant from The Cross Foundation, and a grant from the Paley Foundation.

<sup>1</sup> Abbreviations used in this paper: PBS, phosphate-buffered physiologic saline; PTT, partial thromboplastin time.

TABLE I

Activator substance	Dose	Animals	
		Dogs	Monkeys
	<i>mg/kg body wt</i>		
Ellagic acid	0.5	3	3
Rutin	0.5	3	—
<i>E. coli</i> endotoxin	1.0	3	—
PBS (control)		3	—

this period the animals were sacrificed by injection of a lethal dose of pentobarbital. They were subjected to complete post-mortem examination, and specimens of gall bladder, liver, stomach, duodenum, small bowel, colon, mesentery, kidney, skeletal muscle, diaphragm, skin, heart, lung, and brain were fixed in Zenker's solution made 5% in acetic acid, washed, embedded in paraffin, sectioned, and stained with hematoxylin and eosin for light microscopic examination. Photomicrographs were taken on a Leitz photomicroscope (E. Leitz, Inc., Rockleigh, N. J.) with Kodachrome II film (Eastman Kodak Co., Rochester, N. Y.).

*Plasma Samples.* Platelets and other formed elements were removed by centrifugation in plastic tubes at 4°C, and plasma was pipetted with plastic pipette tips into plastic tubes and stored at -70°C.

*Determination of Partial Thromboplastin Time (PTT).* A fibrometer (Baltimore Biological Laboratories, Baltimore, Md.), plastic pipette tips, plastic tubes, and the following reagents were used: Celite (Filter Aid, Fisher Scientific Co., Pittsburgh, Pa.) in PBS in a concentration of 5 mg/ml, 0.05 M CaCl<sub>2</sub> in glyoxaline buffer, and rabbit brain cephalin (Sigma Chemical Co.) in PBS. For measurement of activated PTT, 0.1 ml of plasma was pipetted in a plastic reaction vessel and warmed at 37°C for 60 s. 0.1 ml of Celite suspension was then added, and the mixture was warmed for 60 s. 0.05 ml of cephalin suspension and 0.05 ml of CaCl<sub>2</sub> solution were then added, and the timer and probes were started. For the measurement of unactivated PTT, 0.1 ml of PBS was used instead of 0.1 ml of Celite suspension; the assay was otherwise performed identically. All values presented represent the mean of duplicate determinations. The coefficient of variation in activated or unactivated PTT was <6%.

*Determination of Fibrinolytic Activity.* The euglobulin clot lysis time of plasma samples was measured using the technique of Ogston et al. (5). All determinations were performed in duplicate, and the values shown represent the mean of duplicate determinations. Plasmin activity was also measured according to the technique of Friberger et al. (6) using chromogenic substrate S-2251 (H-D-Val-Leu-Lys-pNA) (Ortho Diagnostics Inc., Raritan, N. J.). Plasmin activity according to this method is expressed in nkat/ml. The titer of fibrinogen clottable with thrombin was measured according to the technique described by Biggs (7).

*Measurement of Serum Complement.* Plasma samples were clotted by addition of CaCl<sub>2</sub> and centrifuged. CH<sub>50</sub> was measured in the serum supernate according to the method described by Rapp and Borsos (8).

## Results

*Morphologic Observations.* Within 3-5 min of intravenous injection in dogs and monkeys of ellagic acid, rutin, or *E. coli* endotoxin, spasm of small arteries in the body and fundus of the gall bladder occurred in association with segmental spasm of larger branches of the cystic artery. The blue color of the gall bladder turned gray, then white. These changes progressed until only the major branches of the cystic artery were visible to the naked eye; the smaller vessels having so greatly contracted. In general, these changes and ensuing changes described below were confined to the body and fundus of the gall bladder and spared the ampulla. Approximately 15-20 min after injection of activator substances, serosal veins and lymphatics appeared engorged and the gall bladder wall began to appear edematous. This change pro-

gressed until the serosa developed a reticulated or striated appearance as a result of spreading apart of connective tissue bundles by edema fluid. Approximately 30 min after injection of activator substances, petechial hemorrhages were apparent in the serosa of the gall bladder (Figs. 1 and 2).

The petechial hemorrhages sometimes enlarged with the cessation of vasospasm and the reappearance to the naked eye of small serosal arteries, which occurred between 30 and 60 min after the injection of activator.

In both dogs and monkeys the changes described above were confined to the gall bladder and were not observed in other abdominal viscera visible through the abdominal incision. The severity of changes in the gall bladder varied somewhat from animal to animal in both dogs and monkeys, but occurred in every animal. No changes occurred grossly in the gall bladders or other organs of sham-operated dogs injected intravenously with comparable volumes of PBS.

On microscopic examination of the gall bladders from dogs injected intravenously with rutin or ellagic acid, marked edema of the serosa and muscularis with focal hemorrhage was observed (Fig. 3). Focal necrosis of arteries and veins was present and the walls of both were often markedly infiltrated by polymorphonuclear neutrophils (Fig. 4). Small veins were engorged with polymorphonuclear neutrophils that were adherent to endothelium, between endothelial cells and extravasated (Fig. 5). The lumina of some vessels in the wall of the gall bladder were occluded by thrombi (Fig. 6). These changes were confined to the muscularis and serosa, although hemorrhage was sometimes observed just below the mucosa (Fig. 3). The mucosa itself appeared normal (Fig. 2). Gall bladders of monkeys injected intravenously with ellagic acid showed the same histologic changes, though of lesser severity. In dogs and monkeys, no microscopic changes were observed in other abdominal viscera (Fig. 7), including those supplied by other branches of the celiac artery, the kidneys, skeletal muscle, heart, or skin. Margination of polymorphonuclear neutrophils was seen in pulmonary blood vessels, and alveolar capillaries contained an increased number of polymorphonuclear neutrophils (Figs. 8 and 9). In some animals pulmonary edema was present and in others focal extravasation of erythrocytes from alveolar capillaries had occurred.

Microscopic examination of tissue sections from dogs injected with endotoxin revealed vascular thrombosis and necrosis, edema, and hemorrhage in the serosa and muscularis of the gall bladder. This was not accompanied by infiltration of these vascular structures by polymorphonuclear neutrophils. In addition, microthrombi were present in small pulmonary vessels, including alveolar capillaries, myocardial vessels, and in the kidney.

No changes were observed in the gall bladder, lungs, or other viscera of sham-operated dogs that were injected intravenously with comparable volumes of PBS.

*Studies on Plasma.* Intravenous injection of dogs with ellagic acid, rutin, or *E. coli* endotoxin resulted in shortening of the unactivated PTT but not of the Celite-activated PTT. Intravenous injection of monkeys with ellagic acid resulted in marked prolongation of both the activated and unactivated PTT. The euglobulin clot lysis time of dogs injected with ellagic acid, rutin, or *E. coli* endotoxin was greatly shortened. This change was associated with a fall in fibrinogen titer and, in the case of dogs injected with ellagic acid or *E. coli* endotoxin, activated capacity of plasma to digest chromogenic substrate S-2251. It was not possible to measure the euglobulin clot lysis

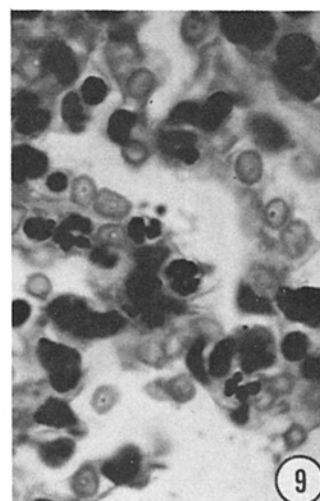
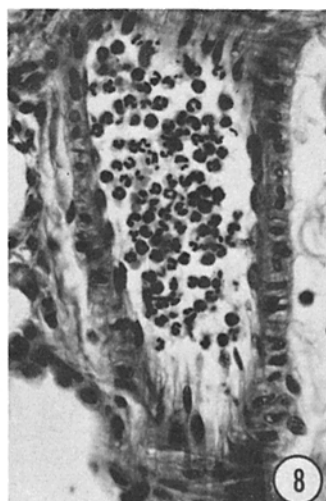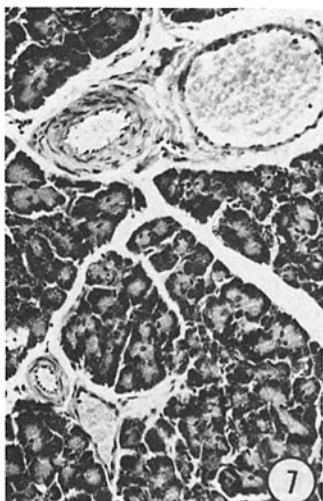
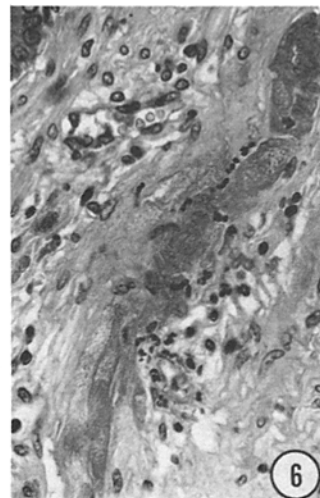
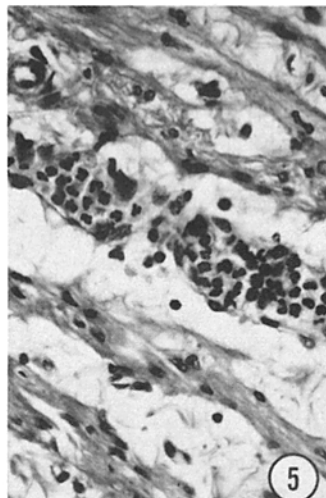
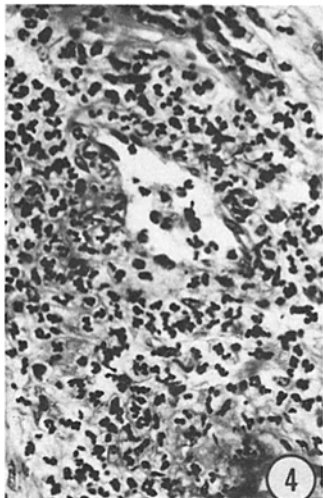
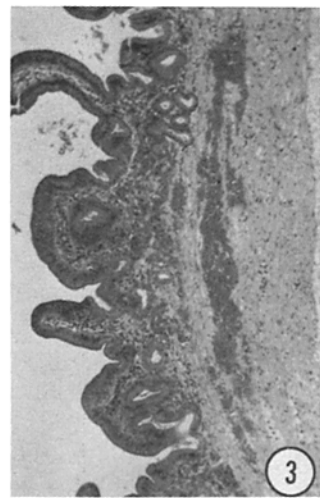
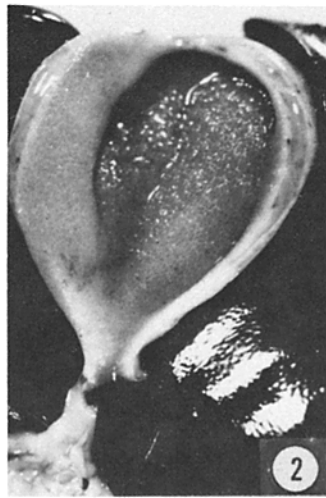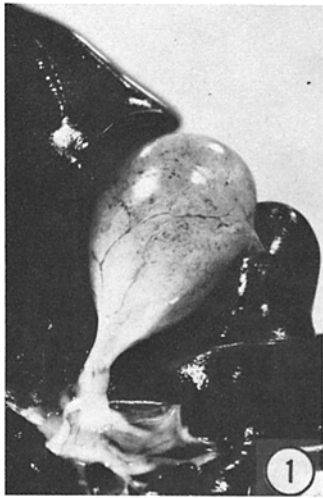


TABLE II  
*Effect of Injection of Ellagic Acid, Rutin, and Endotoxin on PTT and Fibrinolytic Activity*

Subject	Substance injected	Unactivated PTT		Euglobulin clot lysis time		Plasmin activity		Fibrinogen titer	
		0 min	15 min	0 min	15 min	0 min	15 min	0 min	15 min
		<i>s</i>		<i>min</i>		<i>nkat/ml</i>			
Dog 21	Ellagic acid	185.2	119.7	68	8	0	0.08	1:64	1:32
Dog 31	Rutin	147.4	110.2	133	33	0	0	1:64	1:8
Dog 30	Endotoxin	350.2	238.2	96	21	0	0.24	1:64	1:16
Dog 20	PBS	168.2	168.3	64	63	0	0	1:64	1:64
Monkey 2	Ellagic acid	333.7	>1,200.0	198	*	0	0.32	1:64	<1:1

\* Not clottable with thrombin.

time in monkey plasma after intravenous injection of ellagic acid because the fibrinogen titer fell to a dilution of <1:1; however, plasmin activity was demonstrable in these samples by using chromogenic substrate S-2251. The effects on plasma of the animals whose tissues are illustrated in Figs. 1-9 are seen in Table II.

The use of coagulation assays to demonstrate consumption of factor XII or of prekallikrein in dog or in monkey plasma after intravenous injection of activator substances was precluded by the presence of either activated clotting proteins and/or residual activating substances.

No significant changes were observed in  $CH_{50}$  in these studies.

### Discussion

In experiments described above it has been demonstrated that intravenous injection in dogs and monkeys of ellagic acid or of rutin, which are known polyphenol activators of factor XII, induces acute inflammation in blood vessels of the serosa and muscularis of the gall bladder. Margination of polymorphonuclear neutrophils was also seen to a lesser extent in the lung, sometimes with pulmonary edema and focal necrosis of

FIG. 1. Petechial hemorrhages are present in the serosa of the body and fundus of the gall bladder of dog No. 21, sacrificed 1 h after injection of ellagic acid in the femoral vein.

FIG. 2. The muscularis and serosa of the body and fundus of the gall bladder described above are greatly thickened by edema. The mucosa is grossly normal.

FIG. 3. Hemorrhage is present in the muscularis and in the submucosa of the gall bladder of dog No. 31, injected intravenously with rutin. Hematoxylin and eosin.  $\times 80$ .

FIG. 4. The walls of veins and an artery are necrotic and infiltrated by polymorphonuclear neutrophils in the muscularis of the gall bladder of dog No. 21, injected intravenously with ellagic acid. Hematoxylin and eosin.  $\times 500$ .

FIG. 5. A small vein in the muscularis of the gall bladder described in Fig. 4 is choked with polymorphonuclear neutrophils, many of which are marginated and some of which are emigrating. Edema spreads smooth muscle fibers apart. Hematoxylin and eosin.  $\times 500$ .

FIG. 6. Necrosis and thrombosis of a small artery deep to the gall bladder mucosa is shown in a microscopic section of dog No. 31, injected intravenously with rutin. Hematoxylin and eosin.  $\times 500$ .

FIG. 7. The pancreatic parenchyma of dog No. 21, injected intravenously with ellagic acid, and its blood vessels are histologically normal. Hematoxylin and eosin.  $\times 200$ .

FIG. 8. Polymorphonuclear neutrophils fill the lumen and appear to be adherent to the endothelium of a branch of the pulmonary artery in dog No. 21. Hematoxylin and eosin.  $\times 500$ .

FIG. 9. In the lungs of monkey No. 2, injected intravenously with ellagic acid, increased numbers of polymorphonuclear neutrophils are present in alveolar capillaries that are focally injured, allowing extravasation of erythrocytes. Hematoxylin and eosin.  $\times 1,250$ .

alveolar capillaries. Blood vessels in other organs were not affected. Intravenous injection of *E. coli* endotoxin in dogs also resulted in necrosis and thrombosis of blood vessels that was especially severe in the gall bladder, but which occurred in other organs also.

These morphologic changes are associated with, and presumably the result of, activation of factor XII-dependent pathways and generation of kinin activity because it could be demonstrated that coagulation and fibrinolytic pathways had been activated in the dog and monkey. Activated factor XII converts prekallikrein to kallikrein, and several laboratories have presented evidence indicating that kallikrein converts plasminogen to plasmin (9, 10). Ellagic acid and *E. coli* endotoxin are known to activate factor XII-dependent pathways in vitro and in vivo, and it has been demonstrated in this laboratory that rutin can activate factor XII-dependent pathways in human plasma in vitro (11–14). It is of interest that intravenous injection of dogs with ellagic acid, rutin, or *E. coli* endotoxin resulted in shortening of the unactivated PTT but not of the Celite-activated PTT. These results reconcile the observations of Botti and Ratnoff (12) and of Girolami et al. (15) and indicate that in the dog, shortening of the unactivated PTT is a more sensitive indicator of activation of the intrinsic pathway. Intravenous injection of monkeys with ellagic acid induced marked increases in both the unactivated and Celite-activated PTT, which suggests consumption of coagulation factors. The marked consumption of fibrinogen observed in monkey plasma supports this explanation.

Plasma samples from dogs injected intravenously with rutin were unable to hydrolyze chromogenic substrate S-2251, even though the euglobulin clot lysis times and fibrinogen titers of these samples were decreased. In contrast, plasma from dogs injected with ellagic acid or *E. coli* endotoxin, or from monkeys injected with ellagic acid were able to digest S-2251. We have no explanation for this discrepancy.

Botti and Ratnoff (12) have demonstrated that intravenous injection of ellagic acid in dogs in similar doses led to activation of factor XII. However, these investigators did not describe changes in the gall bladder or the lung consequent to injection of ellagic acid.

The observation that injury to blood vessels was limited to the gall bladder and lung suggests that the blood vessels in these organs are especially responsive to bradykinin. Because it has been shown that bradykinin stimulates contraction of endothelial cells of postcapillary venules resulting in increased permeability (16), it is reasonable to assume that endothelium of venules in the gall bladder and lung are especially sensitive to bradykinin. However, vasospasm of arteries in the gall bladder, but not those of adjacent organs, was the earliest change that we observed, which suggests that smooth muscle of branches of the cystic artery are also sensitive to bradykinin and respond by constricting. In this connection it is known that umbilical cord vessels and the ductus arteriosus constrict in response to bradykinin, whereas many other vessels dilate (17, 18).

It should be pointed out that some controversy exists concerning the presence of kininogenase in dog plasma. Saito et al. (19) were unable to correct the PTT of human plasma deficient in prekallikrein with dog plasma, nor were they able to precipitate kallikrein from dog plasma using rabbit antiserum to human kallikrein. In contrast, Nakahara (20) was able to generate bradykinin activity measured by bioassay on exposure of dog plasma to glass. He suggested that dog plasma also

contained potent inhibitors of kininogenase, which may explain the difficulty in demonstrating kininogenase activity.

The vasospasm and edema that we observed in the wall of the gall bladder certainly indicated kinin-like activity. This may have been generated as the result of kininogenase activity in plasma. It is also conceivable that it might have been generated as the result of activity of kininogenases associated with blood vessels in the wall of the gall bladder. The latter hypothesis might explain the localization of the inflammatory response to vessels of the gall bladder and of the lung.

It was also observed that 1 h after intravenous injection of ellagic acid or rutin, margination and emigration of polymorphonuclear neutrophils had occurred in venules of the gall bladder and that the walls of some veins and arteries were extensively infiltrated with polymorphonuclear neutrophils. The nature of the chemotactic stimulus is unknown, but it is conceivable that it is kallikrein generated as a consequence to activation of factor XII (21). According to this hypothesis, activation of factor XII-dependent pathways led to the production of bradykinin, which enhanced vascular permeability to larger molecules, including kallikrein, which in turn stimulated the migration of polymorphonuclear neutrophils into the walls of blood vessels. Alternatively, activation of the fibrinolytic pathway with the formation of plasmin may have led indirectly to the generation of chemotactic factors from the complement system (22, 23). The fact that  $CH_{50}$  did not fall does not exclude limited and/or local activation of C5.

Margination and emigration of polymorphonuclear neutrophils was present to a much greater degree in the gall bladders of dogs treated with ellagic acid or rutin than in dogs treated with endotoxin. All these substances are known to activate factor XII, but endotoxin can also activate both the classical and alternative pathways of the complement system (13), possibly leading to a rapid sequestering of polymorphonuclear neutrophils and preventing their accumulation in the gall bladder.

It is of interest that margination of polymorphonuclear neutrophils was also observed in vessels of the lung, sometimes with the development of pulmonary edema after injection with ellagic acid or rutin. This observation also suggests that certain vascular beds are more sensitive than others to products generated as a consequence of activation of factor XII. Desai et al. (24) have demonstrated that the fifth component of complement is chemotactic in the lung of hamsters, but to our knowledge the chemotactic activity of kallikrein in the lung has not been measured. However, exposure of hamsters to a dust of quercetin, the aglucone of rutin, results in recruitment of polymorphonuclear leukocytes through intrapulmonary airway walls (25).

Margination and emigration of polymorphonuclear neutrophils was observed in ear chambers in rabbits by Graham et al. (26) after local application of factor XII and ellagic acid. We did not observe these changes in the skin or any organs other than the gall bladder or lung when ellagic acid or rutin were injected intravenously. There is no ready explanation for these differences, but it is conceivable that vessels of the ear became more responsive to products of factor XII activation after implantation of the ear chamber. It might be similarly argued that surgical exposure of the gall bladder also made its vasculature more responsive to products of factor XII activation. This seems unlikely because: (a) we did not observe these changes in other organs in the field of operation that were equally subject to minor surgical trauma;

(b) inflammatory changes were equally marked in the portion of the gall bladder wall attached to the liver and not subject to manipulation; and (c) inflammation was observed in the gall bladder after intravenous injection of activators of factor XII when even touching the gall bladder was scrupulously avoided.

The observations described above support the hypothesis that activation of factor XII-dependent pathways can lead to development of acute, acalculous cholecystitis. When this syndrome occurs in patients with bacterial sepsis, bacterial endotoxin might serve as the substance activating the intrinsic pathway of coagulation. Activation of factor XII by exposure of plasma to collagen or the release of tissue factor and activation of factor VII might lead to the development of acute cholecystitis in patients with burns or other trauma. The latter explanations might apply to patients with widespread metastases and foci of necrotic tumor. In addition, plasminogen activator from tumor cells might initiate the chain of events leading to acalculous cholecystitis (27).

The fact that intravenous injection of known polyphenol activators of the intrinsic coagulation pathway can lead to the development of acute vasculitis in the gall bladders of dogs and monkeys may provide an important insight into both the epidemiology of cholecystitis in man and into the mechanisms underlying the segmental nature of vascular injury. Polyphenols are common constituents of plants and are commonly ingested. Furthermore, it has been demonstrated in this laboratory that constituents of tobacco smoke contain rutin or rutin-like moieties capable of activating factor XII (14). It is conceivable that repetitive inhalation of such material might lead to the development of inflammation in the gall bladder and that cigarette smoking contributes to the development of cholecystitis in man.

### Summary

Acute, acalculous cholecystitis is seen among patients suffering with bacterial sepsis, burns, trauma, or cancer; clinical conditions that could lead to activation of factor XII-dependent pathways and result in inflammation of the gall bladder. To test this hypothesis, dogs were injected intravenously with ellagic acid or rutin, known polyphenol activators of factor XII, or with *Escherichia coli* endotoxin, also known to activate factor XII, and monkeys were injected intravenously with ellagic acid. In both species, in vivo activation of factor XII-dependent pathways with polyphenol activator resulted in rapid and selective development of acute vasculitis in the serosa and muscularis of the gall bladder and margination of polymorphonuclear neutrophils in pulmonary blood vessels. Intravenous injection of *E. coli* endotoxin in dogs resulted in necrosis and thrombosis of vessels that were especially severe in the serosa and muscularis of the gall bladder but also present in vessels of many other organs. These observations indicate that blood vessels of the gall bladder and, to a lesser degree, the lung are especially sensitive to injury consequent to in vivo activation of factor XII-dependent pathways and, in view of the common ingestion of plant polyphenols, may provide important insight into the pathogenesis of cholecystitis in man.

We gratefully acknowledge the technical assistance of Mr. Richard Terek, Mr. Clarence Johnson, Mrs. Mariane Matheas, and Miss Teresia Laube, and the help of Miss Gioconda Carrozza in preparation of the manuscript. We are also grateful to Dr. Ralph Nachman for suggestions and criticism of the manuscript.

*Received for publication 29 August 1979.*



## References

1. Glenn, F. 1979. Acute acalculous cholecystitis. *Ann. Surg.* **189**:458.
2. Mann, F. C. 1921. The production by chemical means of a specific cholecystitis. *Ann. Surg.* **73**:54.
3. Morrison, D. C., and C. C. Cochrane. 1974. Direct evidence for Hageman factor (factor XII) activation by bacterial lipopolysaccharides (endotoxins). *J. Exp. Med.* **140**:797.
4. Wilner, G. D., H. L. Nossel, and E. C. Le Roy. 1968. Activation of Hageman factor by collagen. *J. Clin. Invest.* **47**:2608.
5. Ogston, D., N. B. Bennett, C. M. Ogston, and O. D. Ratnoff. 1971. The assay of a plasma component necessary for the generation of a plasminogen activator in the presence of Hageman factor (Hageman co-factor). *Br. J. Haematol.* **20**:209.
6. Friberger, P., M. Knös, S. Gustavsson, L. Aurell, and G. Claesson. 1978. Methods for determination of plasmin, antiplasmin, and plasminogen by means of substrate S-2251. *Haemostasis.* **7**:138.
7. Biggs, R. 1976. Human Blood Coagulation, Haemostasis and Thrombosis. Blackwell Scientific Publications Ltd., Oxford. 2nd edition. 722-724.
8. Rapp, H. J., and T. Borsos. 1970. Molecular Basis of Complement Action. Appleton-Century-Crofts, New York. 78-83.
9. Colman, R. W. 1969. Activation of plasminogen by human plasma kallikrein. *Biochem. Biophys. Res. Commun.* **35**:273.
10. Mandle, R., and A. P. Kaplan. 1977. Hageman factor substrates. Human plasma prekallikrein: mechanism of activation by Hageman factor and participation in Hageman factor-dependent fibrinolysis. *J. Biol. Chem.* **252**:6097.
11. Ratnoff, O. D., and J. D. Crum. 1964. Activation of Hageman factor by solutions of ellagic acid. *J. Lab. Clin. Med.* **63**:359.
12. Botti, R. E., and O. D. Ratnoff. 1964. Studies on the pathogenesis of thrombosis: an experimental "hypercoagulable" state induced by the intravenous injection of ellagic acid. *J. Lab. Clin. Med.* **64**:385.
13. Morrison, D. C., and R. J. Ulevitch. 1978. The effects of bacterial endotoxins on host mediation systems. *Am. J. Pathol.* **93**:527.
14. Becker, C. G., and T. Dubin. 1977. Activation of factor XII by tobacco glycoprotein. *J. Exp. Med.* **146**:457.
15. Girolami, A., D. Agostino, and E. E. Clifton. 1966. The effect of ellagic acid on coagulation in vivo. *Blood.* **27**:93.
16. Majno, G., S. M. Shea, and M. Levantahl. 1969. Endothelial contraction induced by histamine type mediators. An electron microscopic study. *J. Cell Biol.* **42**:647.
17. Davignon, J., R. R. Lorenz, and J. T. Shepherd. 1965. Response of human umbilical artery to changes in transmural pressure. *Am. J. Physiol.* **209**:51.
18. Kovalcik, V. 1963. The response of the isolated ductus arteriosus to oxygen and anoxia. *J. Physiol. (Lond.)* **169**:185.
19. Saito, H., G. Goldsmith, and O. D. Ratnoff. 1974. Fletcher factor activity in plasmas of various species. *Proc. Soc. Exp. Biol. Med.* **147**:519.
20. Nakahara, M. 1974. Activation of dog plasma kininogenase with glass. *Biochem. Pharmacol.* **23**:3009.
21. Kaplan, A. P., A. B. Kay, and K. F. Austen. 1972. A prealbumin activator of prekallikrein. III. Appearance of chemotactic activity for human neutrophils by the conversion of human prekallikrein to kallikrein. *J. Exp. Med.* **135**:81.
22. Ratnoff, O. D., and G. B. Naff. 1967. The conversion of C'1S to C'1 esterase by plasmin and trypsin. *J. Exp. Med.* **125**:337.
23. Bokisch, V. A., H. J. Muller-Eberhard, and C. C. Cochrane. 1969. Isolation of a fragment (C3a) of the third component of human complement containing anaphylatoxin and

- chemotactic activity and description of an anaphylatoxin inactivator of human serum. *J. Exp. Med.* **129**:1109.
24. Desai, U., D. L. Kreutzer, H. Showell, C. V. Arroyave, and P. A. Ward. 1979. Acute inflammatory pulmonary reactions induced by chemotactic factors. *Am. J. Pathol.* **96**:71.
  25. Kilburn, K. H., W. S. Lynn, L. L. Tres, and W. N. McKenzie. 1973. Leukocyte recruitment through airway walls by condensed vegetable tannins and quercetin. *Lab. Invest.* **28**:55.
  26. Graham, R. C., R. H. Ebert, O. D. Ratnoff, and J. M. Moses. 1965. Pathogenesis of inflammation. II. In vivo observations of the inflammatory effects of activated Hageman factor and bradykinin. *J. Exp. Med.* **121**:807.
  27. Reich, E. 1975. Plasminogen activator: secretion by neoplastic cells and macrophages. In *Proteases and Biological Control*. E. Reich, D. B. Rifkin, and D. Shaw, editors. Cold Spring Harbor Laboratory, Cold Spring Harbor, N. Y. 333-341.