

**ORCID**

Javier Gil-Lianes  <https://orcid.org/0000-0001-7235-528X>

**REFERENCES**

1. Wagner G, Sachse MM. Acquired reactive perforating dermatosis. *J Dtsch Dermatol Ges J Ger Soc Dermatol JDDG*. 2013;11(723–9):723–30. <https://doi.org/10.1111/ddg.12131>
2. Kawakami T, Akiyama M, Ishida-Yamamoto A, Nakano H, Mitoma C, Yoneda K, et al. Clinical practice guide for the treatment of perforating dermatosis. *J Dermatol*. 2020;47:1374–82. <https://doi.org/10.1111/1346-8138.15647>
3. Husein-ElAhmed H, Steinhoff M. Dupilumab in prurigo nodularis: a systematic review of current evidence and analysis of predictive factors to response. *J Dermatol Treat*. 2020;1–7. [Online ahead of print]. <https://doi.org/10.1080/09546634.2020.1853024>
4. Holm JG, Agner T, Sand C, Thomsen SF. Dupilumab for prurigo nodularis: case series and review of the literature. *Dermatol Ther*. 2020;33:e13222. <https://doi.org/10.1111/dth.13222>
5. Ying Y, Shuang C, Zhen-Ying Z. Dupilumab may be an alternative option in the treatment of acquired reactive perforating collagenosis combined with AD. *Immun Inflamm Dis*. 2021;10:e574. <https://doi.org/10.1002/iid3.574>

Received: 6 February 2022 | Revised: 1 April 2022 | Accepted: 10 May 2022

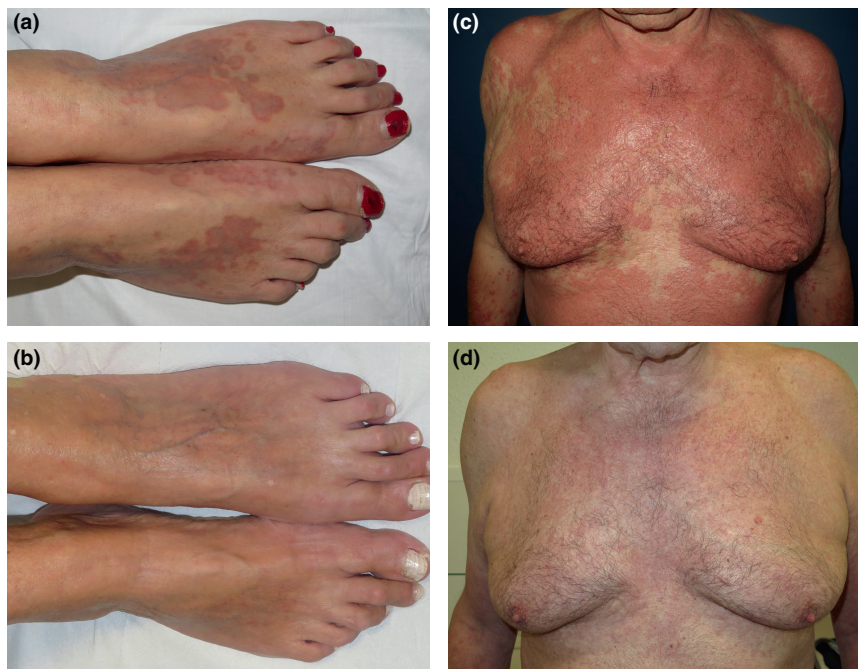DOI: 10.1111/ajd.13875

## Treatment of granuloma annulare with tofacitinib

Dear Editor,

Granuloma annulare (GA) is a granulomatous, idiopathic, inflammatory skin disorder characterized by

the formation of papules and plaques with annular and acral distribution.<sup>1</sup> GA is often limited and self-resolving, but in some cases, it can be generalized and refractory to



**FIGURE 1** Generalized granuloma annulare. Baseline and after tofacitinib treatment. (a) and (b) (patient 12). Granuloma annulare lesions on the dorsal aspect of both feet before and 8 months after initiating treatment. (c) and (d) (patient 13). Granuloma annulare lesions on anterior chest before and 6 months after initiating treatment

This is an open access article under the terms of the [Creative Commons Attribution](https://creativecommons.org/licenses/by/4.0/) License, which permits use, distribution and reproduction in any medium, provided the original work is properly cited.

© 2022 The Authors. *Australasian Journal of Dermatology* published by John Wiley & Sons Australia, Ltd on behalf of Australasian College of Dermatologists.

TABLE 1 Patients with granuloma annulare treated with tofacitinib

Patient	Author/year	Gender/age	Clinic type	GA type	Basal involved BSA (%)	Disease duration	Previous systemic therapies	Tofacitinib treatment	Adverse effects	Outcome and follow-up
1	Damsky/2020 <sup>2</sup>	F/66	Generalized	NR	NR	6 years	Hydroxychloroquine, SC, UV, doxycycline, cyclosporine, isotretinoin	5 mg twice daily	None	CR at month 6. Response sustained with tofacitinib until the writing of the case
2	Damsky/2020 <sup>5</sup>	M/69	Localized	NR	NR	1 year	None	Topical 2% ointment twice daily	None	Near resolution of treated lesions at week 15. No improvement in untreated lesions. No follow-up described
3	Durgin/2020 <sup>6</sup>	F/46	Generalized	10	10	2 years	Hydroxychloroquine, dapsone	Topical 2% ointment twice daily	None	PR (BSA improvement of 90% from baseline) at week 12 applying only the treatment to the lesions of the right arm. Without relapses in 2 month of follow-up
4	Wang/2021 <sup>1</sup>	F/60	Generalized	7	7	6 years	SC, pentoxifylline	5 mg twice daily	None	PR (BSA improvement of 71.4% from baseline) at month 6. No follow-up described
5	Wang/2021 <sup>1</sup>	F/68	Generalized	30	30	6 years	Hydroxychloroquine, SC, cyclosporine, antibiotics, UV	5 mg twice daily	None	CR at month 6. No follow-up described
6	Wang/2021 <sup>1</sup>	F/64	Generalized	10	10	6 years	Pentoxifylline	5 mg twice daily	None	PR (BSA improvement of 60% from baseline) at month 6. No follow-up described
7	Wang/2021 <sup>1</sup>	M/53	Generalized	18	18	10 years	Hydroxychloroquine, antibiotics, UV	5 mg twice daily	None	CR at month 6. No follow-up described
8	Wang/2021 <sup>1</sup>	F/65	Generalized	8	8	15 years	None	5 mg twice daily	None	CR at month 6. No follow-up described
9	McPhie/2021 <sup>4</sup>	F/78	Generalized	NR	NR	6 years	UV, methotrexate, ustekinumab	5 mg twice daily	None	Almost CR at month 9. No follow-up described
10	McPhie/2021 <sup>4</sup>	F/59	Generalized	NR	NR	10 years	UV, ustekinumab	5 mg twice daily	None	PR (degree of improved NR) at week 4. No follow-up described
11	New case reported in this manuscript	F/69	Generalized	12	12	5 years	Hydroxychloroquine, SC, retinoic acid, tranexamic acid, indomethacin, methotrexate	5 mg twice daily	None	CR at month 4. Response sustained 4 months after suspension and 11 months after starting dose tapering
12	New case reported in this manuscript	F/73	Generalized	10	10	5 years	Hydroxychloroquine, SC, pentoxifylline, dapsone	5 mg twice daily	None	CR at month 8. Response sustained 6 months after suspension and 17 months after starting dose tapering
13	New case reported in this manuscript	M/64	Generalized	45	45	3 years	Hydroxychloroquine, SC, UV, methotrexate, adalimumab	5 mg twice daily	None	CR at month 6. Response sustained 10 month after suspension

Abbreviations: BSA—body surface area; CR—complete response; F—female; M—male; GA—granuloma annulare; NR—not reported; PR—partial response; SC—systemic corticosteroids; UV—narrowband ultraviolet B phototherapy.

treatments.<sup>1</sup> New advances in the pathophysiology of GA have favoured Janus kinase (JAK) inhibitors as a promising therapeutic option.<sup>1,2</sup> Here, we report three cases of resistant generalized GA successfully treated with tofacitinib.

The first was a 69-year-old woman with a 6-year history of generalized GA who had been treated with oral corticosteroids, retinoic and tranexamic acid, indomethacin, hydroxychloroquine and methotrexate without improvement or intolerance, and the second a 73-year-old woman with a history of dyslipidemia receiving simvastatin treatment who was diagnosed with generalized GA in 2016. She had received oral corticosteroids, hydroxychloroquine, pentoxifylline and dapsone, without improvement (Figure 1a). The third patient was a 64-year-old man with a 3-year evolution of a generalized GA who had received oral corticosteroids, phototherapy, methotrexate, hydroxychloroquine and adalimumab with partial response. Furthermore, he had begun experiencing flares of bilateral uveitis in the context of skin outbreaks (Figure 1c).

In all three cases, the diagnosis was confirmed histologically and due to difficulties in management, treatment with off-label oral tofacitinib was requested and approved by the therapeutic committee. After the three patients gave written informed consent, tofacitinib was initiated at a dose of 5 mg twice daily. The three patients showed complete response after 4, 8 and 6 months, respectively (Figure 1b and d), without relapses after dose tapering or suspension of the treatment. The characteristics of all the reported GA patients treated with tofacitinib are summarized in Table 1.

JAK inhibitors represent a promising approach for cutaneous granulomatous disorders.<sup>2</sup> Damsky et al demonstrated that JAK–STAT signalling was constitutively activated in GA lesional macrophages, and that tofacitinib treatment induced histologic clearance of granulomas and downregulation of the JAK–STAT pathway.<sup>2</sup> Further, Wang et al recently found that IFN- $\gamma$ , oncostatin M, IL-21 and IL-15, four important cytokines that signal via the JAK–STAT pathway, are upregulated in GA skin lesions.<sup>1</sup> Further, Min et al identified a significant upregulation of inflammatory T-helper cell types 1 and 2, and Janus kinase immune pathways in GA patients.<sup>3</sup>

Tofacitinib is a potent inhibitor of JAK 1 and 3 in human cells. Currently, it is approved for the treatment of rheumatoid arthritis, psoriatic arthritis, juvenile idiopathic arthritis and ulcerative colitis with a recommended dose of 5 mg twice daily. Recent data from post-marketing surveillance have shown an increased risk of death, major adverse cardiovascular events, malignancies and thrombosis related to tofacitinib prompting the FDA to issue a safety communication. We found eight previous reports in the literature of patients treated with oral tofacitinib for GA<sup>1,2,4</sup>

and two reports of treatment with topical tofacitinib.<sup>5,6</sup> All patients improved ranging from a partial response of 60% to complete remission. Topical treatment showed improvement between weeks 12 and 15, while oral treatment took about 6 months. None of the cases described have reported any adverse effects. In addition, other JAK inhibitors such as baricitinib and upadacitinib have recently been used in two generalized GA patients with good results.<sup>7,8</sup>

In conclusion, advances in GA pathophysiology have allowed the introduction of JAK inhibitors as a new treatment option. To our knowledge, there are only about a dozen reports of GA patients treated with tofacitinib. So far, it has shown an excellent response rate, with both oral and topical administration. Further studies are necessary to assess the safety and the long-term remission of GA patients treated with tofacitinib, and to study the efficacy of other JAK inhibitors in these patients.

#### FUNDING INFORMATION

None.

#### CONFLICT OF INTEREST

The authors declare that there is no conflict of interest.

Xavier Bosch-Amate MD 


Laura Serra-García MD 

Francesc Alamon-Reig MD 

Ignasi Marti-Marti MD 

Javier Gil-Lianes MD 

Priscila Giavedoni MD 

José M. Mascaró Jr MD 

*Department of Dermatology, Hospital Clinic of Barcelona, University of Barcelona, Barcelona, Spain*

#### Correspondence

José M. Mascaró Jr, Villarroel 170. 08036, Barcelona, Spain.

Email: [jmmascaro\\_galy@ub.edu](mailto:jmmascaro_galy@ub.edu)

#### ORCID

Xavier Bosch-Amate  <https://orcid.org/0000-0002-4809-8866>

Laura Serra-García  <https://orcid.org/0000-0002-1231-4651>

Francesc Alamon-Reig  <https://orcid.org/0000-0002-6018-9680>

[org/0000-0002-6018-9680](https://orcid.org/0000-0002-6018-9680)

Ignasi Marti-Marti  <https://orcid.org/0000-0002-6838-6160>

Javier Gil-Lianes  <https://orcid.org/0000-0001-7235-528X>

Priscila Giavedoni  <https://orcid.org/0000-0002-1474-9261>

José M. Mascaró Jr  <https://orcid.org/0000-0001-9327-2555>

#### REFERENCES

- Wang A, Rahman N-T, McGeary MK, Murphy M, McHenry A, Peterson D, et al. Treatment of granuloma annulare and

- suppression of proinflammatory cytokine activity with tofacitinib. *J Allergy Clin Immunol*. 2021;147:1795–809.
- Damsky W, Thakral D, McGeary MK, Leventhal J, Galan A, King B. Janus kinase inhibition induces disease remission in cutaneous sarcoidosis and granuloma annulare. *J Am Acad Dermatol*. 2020;82:612–21.
  - Min MS, Wu J, He H, Sanz-Cabanillas JL, del Duca E, Zhang N, et al. Granuloma annulare skin profile shows activation of T-helper cell type 1, T-helper cell type 2, and Janus kinase pathways. *J Am Acad Dermatol*. 2020;83:63–70.
  - McPhie ML, Swales WC, Gooderham MJ. Improvement of granulomatous skin conditions with tofacitinib in three patients: a case report. *SAGE Open Med Case Rep*. 2021;9:2050313X2110394.
  - Damsky W, King BA. Treatment of granuloma annulare with tofacitinib 2% ointment. *JAAD Case Rep*. 2020;6:69–71.
  - Durgin JS, Shields BE, Rosenbach M. Generalized granuloma annulare: a widespread response to limited application of compounded 2% topical tofacitinib. *JAAD Case Rep*. 2020;6:1113–5.
  - Yan TM, Zhang H, Wu XY, Zhang ZY. Successful treatment of generalized granuloma annulare with baricitinib. *J Eur Acad Dermatol Venereol*. 2022. <https://doi.org/10.1111/jdv.18031>
  - Sondermann W, Hadaschik E, Specker C. Successful therapy of disseminated patch-type granuloma annulare with upadacitinib in a patient with rheumatoid arthritis. *Dermatol Ther*. 2022;35:e15211.

Received: 15 March 2022 | Accepted: 21 April 2022

DOI: 10.1111/ajd.13864

## Mental health, insomnia and suicidal ideation during treatment with apremilast

The efficacy of apremilast, a phosphodiesterase-4 inhibitor, in the treatment of psoriasis has been established.<sup>1–3</sup> We report on two patients who developed psychiatric symptoms since the commencement of apremilast.

Patient A, a 38-year-old man with whole-body psoriasis, was commenced on apremilast. He had previously completed treatment for latent tuberculosis 1 year prior to apremilast. Over a two-week period, he titrated to a dose of 30 mg twice daily. Upon reaching this dose, he developed insomnia and, subsequently, suicidal ideation. He continued apremilast despite these symptoms with the 6 month supply provided to him in accordance with the Australia Medicare allowance and did not contact the prescriber or seek medical attention. He had nocturnal suicidal ideation for 3 weeks, and this was then resolved without treatment. He did not have any suicide attempts or plans and did not inform his partner of these thoughts. He continued to take his apremilast during this period. Despite resolution of suicidal ideation, he continued to have insomnia with functional impairment during the daytime and self-ceased apremilast 4 months after commencement. Resolution of insomnia occurred within 2 weeks of cessation. He reported improvement of his psoriasis while on apremilast however had relapsed at the time of review due to self-cessation.

Patient B, a 45-year-old woman with whole-body psoriasis, was commenced on apremilast. She had a history of mild depression managed on a stable dose of paroxetine for 7 months prior to apremilast. She otherwise had a history of osteopenia and insulin resistance with no medication changes within a year. Within 2 weeks of commencement on apremilast, she developed insomnia and subsequent nausea and headaches. She self-ceased treatment due to these side effects and had complete resolution within a week of cessation.

Apremilast is an effective and relatively safe option for the treatment of mild-to-moderate psoriasis.<sup>1–3</sup> Insomnia or suicidal ideation was not reported as an adverse event in two pivotal randomized controlled trials,<sup>2,3</sup> however, patients with a history of depression are excluded from all clinical trials. Insomnia has been reported in 11% of 40 patients in a small observational study.<sup>4</sup> Reports of suicidal ideation due to apremilast are rare,<sup>5</sup> and no difference was reported against placebo in the randomized-controlled trials.<sup>2,3</sup> The significance of this symptom, in addition to the knowledge that depression, is a known comorbidity of psoriasis, justifies close monitoring of patients on apremilast.<sup>1</sup>

Due to the emergence of these psychiatric symptoms in patients with no history of mental illness or other