



Potential intravenous immunoglobulin-induced optic disc edema

Anna K. Britton^a, Anagha Vaze^b, Sam Milliken^{c,d}, Clare L. Fraser^{a,b,*}

^a Sydney Eye Hospital, 8 Macquarie St, Sydney, NSW, 2000, Australia

^b Save Sight Institute, Faculty of Health and Medicine, The University of Sydney, 8 Macquarie St, Sydney, NSW, 2000, Australia

^c St Vincent's Hospital, 390 Victoria Street, Darlinghurst, 2010, Australia

^d University of New South Wales, Kensington, 2052, Australia

ARTICLE INFO

Keywords:

IVIG (Intravenous immunoglobulin)
Optic disc edema
Papilledema

ABSTRACT

Purpose: To report a case of recurrent and bilateral optic disc edema following intravenous immunoglobulin (IVIG) administration.

Observations: A 46 year-old woman received IVIG on 3 separate occasions over 7 years for Non-Hodgkin's Lymphoma (NHL) and each time developed headaches and transient visual disturbance, and was subsequently found to have bilateral optic disc swelling. Lumbar puncture confirmed raised cerebrospinal fluid (CSF) opening pressure and there was resolution following treatment with oral acetazolamide (Diamox).

Conclusions and importance: To our knowledge there is no literature on papilledema following administration of IVIG. This case is pertinent for physicians treating patients with IVIG who develop headache, transient visual disturbance and optic disc edema.

1. Introduction

Papilledema is the swelling and blurring of bilateral optic disc margins due to raised intracranial pressure (ICP)^{1,2} secondary to blockage of axoplasmic flow in the neurons. A syndrome of raised ICP has been reported after certain medications including minocycline and Vitamin A, among others.³

Immunoglobulin is derived from donor plasma and consists of immunoglobulin G (IgG) and small amounts of immunoglobulin A (IgA).^{2,4} Immunoglobulin (IG) can be given via various routes (intravenous: IVIG, subcutaneous and intramuscular) and is given for immune deficiencies, autoimmune and inflammatory disorders.⁴ The role of immunoglobulin is to protect against infection by providing antibodies in immunodeficiency states and also to suppress inflammatory and autoimmune processes.² Adverse reactions to IVIG are reported to occur in 5–15% of all IVIG infusions and the majority are transient, reversible and include headache, chills or flushing.^{2,4,5} In the current literature on the adverse effects of IVIG, there are no reports of papilledema or raised ICP following administration. We report a case of a 46-year-old patient with Non-Hodgkin's Lymphoma (NHL) who received IVIG on 3 separate occasions and subsequently developed postural headaches and bilateral optic disc edema following each administration.

2. Case report

In mid-2013, a 46 year-old woman was referred into a tertiary ophthalmic emergency department by her optometrist with bilateral swollen optic discs. She had a two-week history of visual disturbance with black spots appearing when changing posture. She had a medical history of Stage 4 follicular B cell NHL, which had been treated with chemotherapy previously (2006 CVP-R (Cyclophosphamide, Vincristine, Prednisolone + Rituximab) chemotherapy, radiotherapy and maintenance rituximab for two years, 2012 'R-CHOP' (Rituximab plus CHOP (Cyclophosphamide, doxorubicin Hydrochloride, vincristine/Oncovin, Prednisone) medications) with further maintenance rituximab, and was treated with Rituximab and IVIG (Intragram P) at the time of presentation (Fig. 1). She had been commenced on IVIG following a chest infection two months earlier. Her NHL never involved the central nervous system (CNS). She also gave a history of migraines, sinusitis and recent bronchitis. Her weight was 97.5kg and height 165.5cm (BMI 35.6) in 2013.

On examination, right visual acuity (RVA) was 6/6, left visual acuity (LVA) was 6/6 + 1. Intraocular pressure (IOP) was 11 mm of Hg in both eyes. The eye movements were normal and there was no relative afferent pupillary defect (RAPD). Anterior segment examination was unremarkable. Dilated fundus examination revealed bilateral swollen optic

* Corresponding author. Save Sight Institute, 8 Macquarie St, Sydney, NSW, 2000, Australia.

E-mail address: clare.fraser@sydney.edu.au (C.L. Fraser).

<https://doi.org/10.1016/j.ajoc.2022.101617>

Received 4 July 2021; Received in revised form 25 May 2022; Accepted 10 June 2022

Available online 16 June 2022

2451-9936/© 2022 The Authors. Published by Elsevier Inc. This is an open access article under the CC BY-NC-ND license (<http://creativecommons.org/licenses/by-nc-nd/4.0/>).

discs (Frisen grade 3–4) with a peripapillary haemorrhage on the right disc. Differential diagnoses at this point included papilledema from raised intracranial pressure, optic nerve infiltrate or less likely optic neuritis secondary to Rituximab. Preliminary work-up included routine bloods (FBC WCC 7.99, Hb 146, Plt 198, ESR 12 mm/hr, EUC: Na 142, K 3.8, Cl 100, Bicarb 26, Urea 3.2, Cr 59, eGFR >90), which were normal, except for a mildly raised CRP of 8. A CT brain with CT venogram (CTV) was performed which excluded a space occupying lesion, thrombosis or haemorrhage. The lumbar puncture opening pressure was 29cm H2O with normal constituents. Given these results and raised BMI, the patient was diagnosed with idiopathic intracranial hypertension (IIH) and bilateral papilledema. She was commenced on Diamox 250mg TDS and IVIG was subsequently ceased (Fig. 1). It was recommended that she lose weight, but she was the same weight at each subsequent visit. She was reviewed every few months until disc edema had resolved, which was about eight months after initial disc swelling and Diamox was tapered (Fig. 2).

In 2016 the patient had a chest infection requiring admission to hospital for IV antibiotics (IV 1.2g Benzylpenicillin QID and PO 100mg doxycycline BD for management of community acquired pneumonia (CAP)). No prednisone was administered. Given a reduction in immune markers (hypogammaglobulinaemia) her haematologist recommenced IVIG (Intragram P), initiating treatment with a double dose to get levels up, and planned for monthly dosing thereafter (Fig. 1). Since recommencing IVIG she began experiencing headaches, without a clear pattern. She denied transient visual obscurations or pulsatile tinnitus. She had an ophthalmology review at 2 and 4 weeks following commencement of IVIG. Her weight was 102.7kg and height 165.5cm (BMI 37.50) in 2015 prior to presentation.

On examination, RVA and LVA was 6/5, with full colour vision. Dilated fundus examination revealed a recurrence of diffuse disc edema on the right and nasal edema on the left. Optical coherence tomography (OCT) confirmed disc swelling: global peripapillary retinal nerve fiber layer (RNFL) right 129µm, left 103µm with nasal elevation on sector analysis. A CT/CTV brain was again normal. She refused repeat lumbar puncture. The patient was commenced on acetazolamide 250mg three

times daily for a total of seven months, with resolution of the headaches. When reviewed 6 months later, examination findings had returned to previous baseline, with no further disc edema. She had not lost any weight. The baseline was her RNFL measurements after resolution of the first episode of optic disc edema (Exam 3 and 4 in Fig. 2). Given recurrence of optic disc edema following a single dose of IVIG, no further monthly IVIG was administered.

In early-2020, the patient again had a chest infection and given comorbidities, her haematologist felt that a trial of new IVIG (Privigen) was required (Fig. 1). Prior to respiratory PCR results, the patient was commenced on IV ceftriaxone and azithromycin. Subsequently, respiratory PCR demonstrated parainfluenza 4 and antibiotics were ceased. Two rounds of IVIG were given 5 weeks apart. She again developed a headache associated with posture change, vomiting, ‘fuzzy’ vision and tinnitus. Her weight was 106.5kg and height 165.5cm (BMI 38.88) in 2019, prior to presentation. RVA and LVA was 6/12 improving with pinhole to 6/7.5 in both eyes. Fundus examination revealed a swollen disc in the right eye only. Visual field testing was normal, with no peripheral constriction or enlargement of the blind spot. OCT of the disc showed right RNFL of 136µm, compared to the left RNFL of 96µm. Lumbar puncture was again declined, and the patient was given a trial of acetazolamide 250mg three times daily. IVIG was ceased. After 5 weeks of acetazolamide the headaches had improved. With another 6 weeks of treatment the disc edema resolved (OCT showed RNFL: 101 right, 90 left). Acetazolamide was again tapered. Symptoms and clinical findings remained normal at a three-month follow-up, despite no weight loss.

3. Discussion

Raised intracranial pressure has many causes, however IVIG has not been documented as one of these. We report a case of a woman with papilledema and symptoms of raised ICP following IVIG infusion for NHL, with two further recurrences after re-challenge with IVIG.

Headache following IVIG administration is a very common adverse effect, reported in more than half patients receiving IVIG.^{4,5} A risk factor for the development of headache includes a high dose of

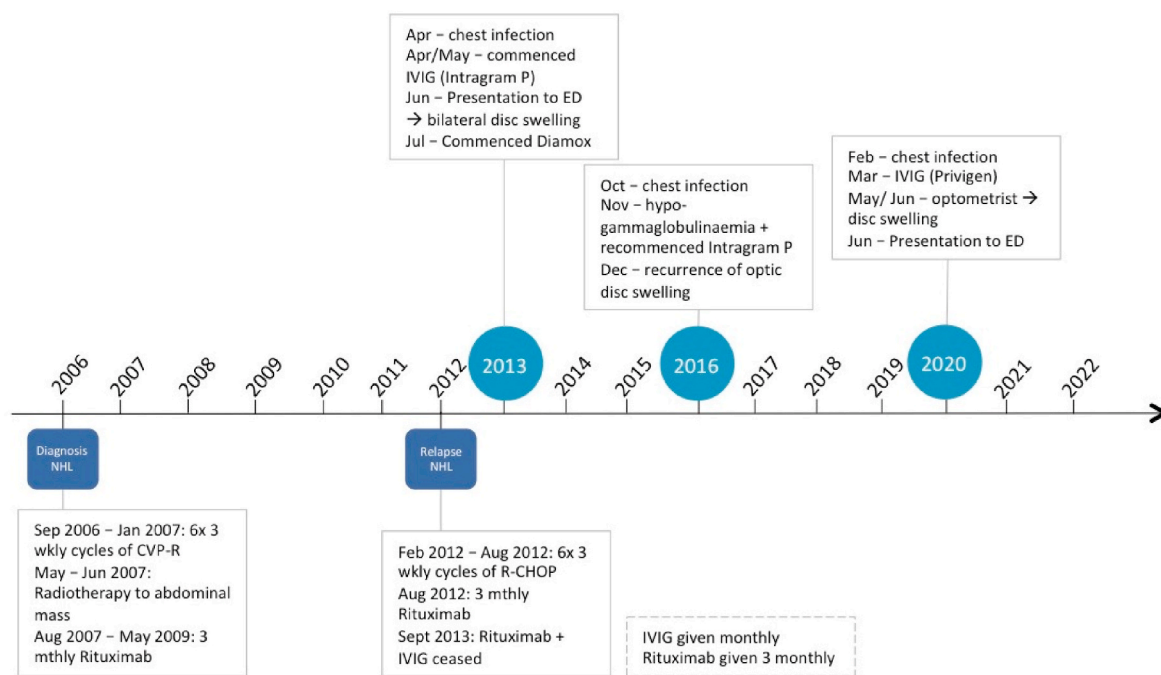


Fig. 1. Timeline of treatment for NHL and development of optic disc swelling.

Key: NHL (Non-Hodgkin’s Lymphoma), CVP-R (cyclophosphamide, vincristine and prednisone + rituximab), R-CHOP (CVP plus doxorubicin and Rituximab), IVIG (Intravenous immunoglobulin), ED (emergency department).

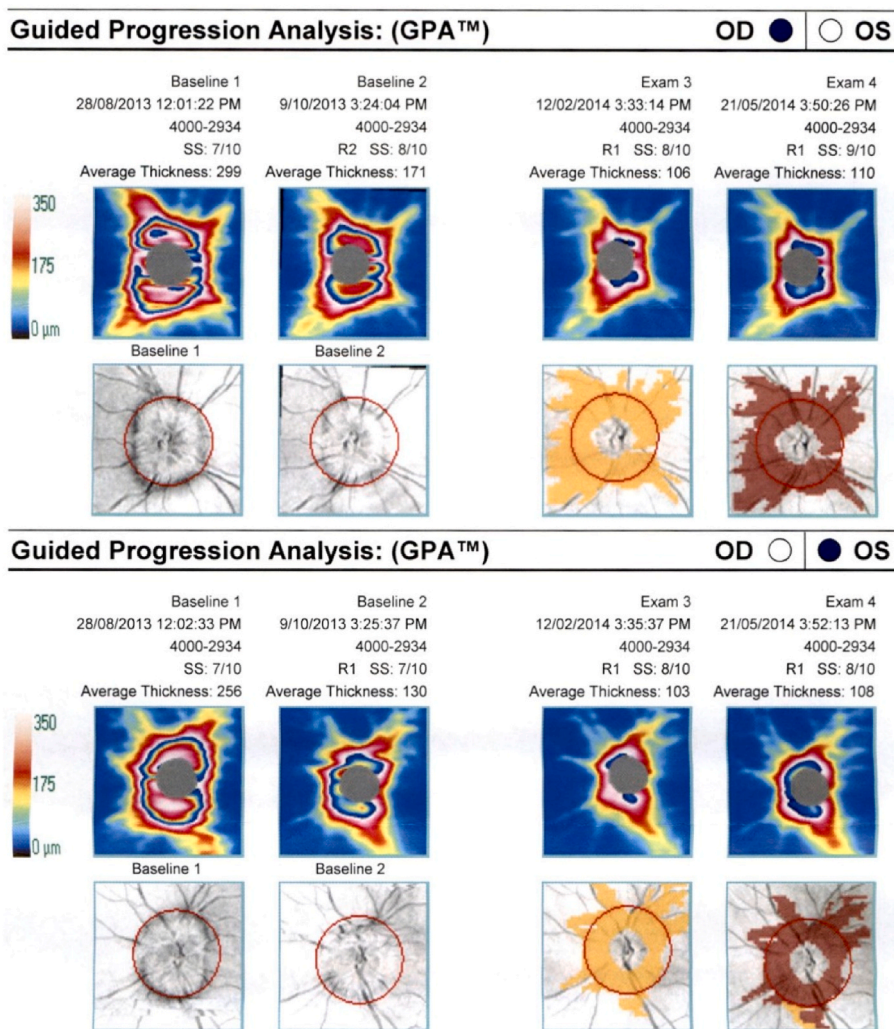


Fig. 2. OCT RNFL at the time of the first episode of optic disc swelling, after commencement of Diamox and progression until resolution of disc swelling (Exam 3 and 4).
Key: OD (right eye), OS (left eye).

immunoglobulin.^{4,5} In review papers on the adverse effects of immunoglobulin, authors suggested that if a headache post-infusion of IVIG is long-lasting and poorly responsive to analgesia, the possibility of aseptic meningitis or posterior reversible encephalopathy syndrome (PRES) should be considered.^{4,5} In a few papers cited in these reviews, authors detail cases of aseptic meningitis induced by IVIG, and while a lumbar puncture (LP) was performed, opening pressure is only recorded for one case and neither of these papers record examination of the optic nerve.^{6,7} In the context of our case, an ophthalmic examination to exclude optic disc swelling in the setting of headache post-IVIG infusion should be considered. Perhaps fundus examination in the cases discussed^{6,7} would have revealed disc edema. Aseptic meningitis has been known to slow CSF resorption and cause intracranial hypertension.⁸

The pathogenesis for IVIG contributing to raised ICP, headache and optic disc swelling is unclear, particularly given that this observation hasn't been reported elsewhere. One possible mechanism is a transient hyperviscosity following IVIG infusion. A couple of features in this case suggest that the optic disc edema was indeed papilledema. Firstly, lumbar puncture confirmed an elevated ICP on the first episode. Secondly, the headache and optic disc edema resolved following a course of acetazolamide, a medication given in the treatment of raised ICP.⁹ Finally, no other cause for the symptoms was found or became apparent on re-challenge. While the patient had a high BMI, which is a risk factor for IIH, she did not have any significant weight loss or weight gain

during these three episodes.

There are a few limitations in this case report. One of which is the fact that there was no repeat LP for further occurrences of optic disc swelling at the patient's request. However despite not having an opening pressure on LP for the second and third instances of disc swelling, clinically the patient presented with features consistent with raised ICP. In the 2016 and 2020 episodes of optic disc swelling, there was a preceding viral respiratory tract infection prompting IVIG infusion for reductions in immune markers. In both of these episodes, no steroid treatment was given. No NHL medications were given at this time. Blood tests in 2013 and 2016 confirm normal urea, kidney function and haemoglobin, thus no other IIH systemic confounders such as anemia or uremia were present.

Although not directly related, there has been one case report of a 12-year-old girl with optic disc swelling in the context of Kawasaki disease treated with IVIG.¹⁰ Interestingly in this case, the patient began to complain of visual change on day 5, which was also the first day IVIG was administered.¹⁰ The patient complained of photophobia, eye pain and reduced vision, and was found to have bilateral, asymmetric optic disc swelling.¹⁰ On the subsequent days the patient suffered a severe worsening of visual acuity and a corresponding worsening of bilateral optic disc swelling.¹⁰ The authors maintain that the ocular inflammatory symptoms appeared prior to IVIG infusions, but nevertheless were significantly worse following these.¹⁰ Whether this worsening of vision

and optic nerve swelling can be solely attributed to Kawasaki disease or was worsened by the IVIG is impossible to tell. In any case, the IVIG may have had some part to play in the worsening of the optic disc edema.

4. Conclusion

We present a case of recurrent papilledema with three separate courses of IVIG over a 7-year period, treated with oral acetazolamide. To our knowledge, no other cases like this have been reported. This is pertinent both for physicians prescribing IVIG and reviewing the adverse effect of headache following infusion, and for ophthalmologists treating patients in a similar situation. This case highlights the need for ophthalmic examination in the work-up of persistent headache post IVIG.

Patient consent

Patient consent was obtained for publication of this report.

Funding

No funding or grant support for this manuscript.

Conflicts of interest disclosure statement

All authors have no conflicts of interest to declare.

Author contributions

AB – collected background information, wrote the manuscript, made Fig. 1.

AV, SM, CF – managed the patient, provided clinical advice, and edited the manuscript.

All authors read and approved the final manuscript.

All authors attest that they meet the current ICMJE criteria for authorship.

Acknowledgements

The authors would like to thank the patient for her consent for publication of this report.

References

1. Dennis M, Bowen WT, Cho L. *Mechanisms of Clinical Signs*. Australia: Elsevier; 2012.
2. Bienfang DC, Brazis PW, Wilterdink JL. Overview and differential diagnosis of papilledema. 2021. Available from: https://www.uptodate.com.acs.hcn.com.au/contents/overview-and-differential-diagnosis-of-papilledema?search=papilledema&source=search_result&selectedTitle=1~150&usage.type=default&display_rank=1;20/04/2021.
3. Mollan SP, Davies B, Silver NC, et al. Idiopathic intracranial hypertension: consensus guidelines on management. *J Neurol Neurosurg Psychiatry*. 2018;1–13.
4. Guo Y, Tian X, Wang X, Xiao Z. Adverse effects of immunoglobulin therapy. *Front Immunol*. 2018;9(1299).
5. Stiehm E. Adverse effects of human immunoglobulin therapy. *Transfus Med Rev*. 2013;27(3):171–178.
6. Kemmotsu Y, Nakayama T, Matsuura H, Saji T. Clinical characteristics of aseptic meningitis induced by intravenous immunoglobulin in patients with Kawasaki disease. *Pediatr Rheumatol*. 2011;9(28).
7. Sekul EA, Cupler EJ, Dalakas MC. Aseptic meningitis associated with high-dose intravenous immunoglobulin therapy: frequency and risk factors. *Ann Intern Med*. 1994;121:259–262.
8. Wolf ME, Eisele P, Schweizer Y, et al. Intracranial hypertension as an acute complication of aseptic meningitis with leptomeningeal contrast enhancement on FLAIR MRI. *Case Reports in Neurology*. 2016;8:10–15.
9. Lee AG, Wall M, Brazis PW, Wilterdink JL. Idiopathic intracranial hypertension (pseudotumor cerebri): prognosis and treatment 2021 28/04/21. Available from: https://www.uptodate.com.acs.hcn.com.au/contents/idiopathic-intracranial-hypertension-pseudotumor-cerebri-prognosis-and-treatment?search=IIH&source=search_result&selectedTitle=2~150&usage.type=default&display_rank=2.
10. Grouteau E, Debusson Cc, Brochard K, et al. Severe global inflammatory involvement of ocular segments and optic disc swelling in a 12-year-old girl with Kawasaki disease. *Eur J Ophthalmol*. 2011;21(1):112–114.