

Received: 2011.08.16  
Accepted: 2011.10.27

## Tuberculous spondylodiscitis in a patient with a sickle-cell disease: CT findings

Leszek Krupniewski<sup>1</sup>, Piotr Palczewski<sup>1</sup>, Marek Gołębiowski<sup>1</sup>,  
Katarzyna Kosińska-Kaczyńska<sup>2</sup>

<sup>1</sup> 1<sup>st</sup> Department of Clinical Radiology of the Medical University of Warsaw, Warsaw, Poland

<sup>2</sup> 1<sup>st</sup> Chair and Clinic of Obstetrics and Gynecology of the Medical University of Warsaw, Warsaw, Poland

**Author's address:** Leszek Krupniewski, 1<sup>st</sup> Department of Clinical Radiology, Chałubińskiego 5 St., 02-004 Warsaw, Poland,  
e-mail: leiu@poczta.onet.pl

### Summary

**Background:**

Although sickle-cell anemia (SCA) is common in black Americans, Sub-Saharan Africa and in the Mediterranean area, the disease is rare in the temperate climate zone. The manifestations of the disease are related mainly to the production of abnormal hemoglobin that leads to organ ischemia and increased susceptibility to infection caused by functional asplenia.

**Case Report:**

The authors present CT findings in a 39-year-old black woman diagnosed due to abdominal pain, lymphadenopathy and fever. CT of the thorax and abdomen demonstrated changes in the liver, spleen, and skeletal system suggestive of SCA complicated with spondylodiscitis in the thoracic spine.

**Discussion:**

Hepatomegaly and small calcified spleen are typical findings in older homozygotic patients with SCA. The lesions in the skeleton may be related either to intramedullary hematopoiesis or osteonecrosis and osteomyelitis. In the latter case, diffuse osteosclerosis and H-shaped vertebrae are most typical. Tuberculous spondylodiscitis is characterized by the location in the thoracic region, preferential involvement of anterior elements, relative sparing of intervertebral discs, and cold abscesses.

**Key words:**

sickle-cell disease • tuberculous spondylodiscitis • computed tomography

**PDF file:**

<http://www.polradiol.com/fulltxt.php?ICID=882586>

### Background

Sickle-cell anemia is a common genetic disease found in 20–40% of black inhabitants of tropical Africa and 5–10% of those living in South and North America [1]. It rarely occurs in Europe, mainly in the Mediterranean area [1,2]. The purpose of this study was to present changes found in a CT examination of the chest and abdomen of a homozygotic patient with sickle-cell anemia and to discuss the pathophysiology of this disease in relation to the lesions observed in imaging studies.

### Case Report

A 39-year-old black woman was admitted to the 1<sup>st</sup> Chair and Clinic of Obstetrics and Gynecology of the Medical University of Warsaw (Head: Prof. Leszek Bablok) due to diffuse abdominal pain, cahexia and fever. Findings on

admission included severe anemia (RBC  $2.19 \times 10^6/\mu\text{l}$ , HGB 4.9 g/dl, HCT 17.2%), leukocytosis of  $12.6 \times 10^3/\mu\text{l}$ , thrombocytosis  $572 \times 10^3/\mu\text{l}$  and a significantly raised level of C-reactive protein (107 mg/l). Gynecological examination and performed ultrasound did not reveal any pathologies of the reproductive organs. In February 2007, the patient underwent surgery in the same Clinic for an inflammatory tumor of the lesser pelvis and pyonephrosis. Presence of oviduct tissue was determined in histopathological examination of the removed tumor.

Fever of up to 39.6°C persisted in the course of hospitalization despite the application of broad-spectrum antibiotics (ciprofloxacin, metronidazole and ampicillin with clavulanic acid followed by vancomycin and gentamicin) and pain became more intense. Findings in computed tomography examination of the chest and abdomen indicated a systemic disease: hepatomegaly, small, calcified spleen

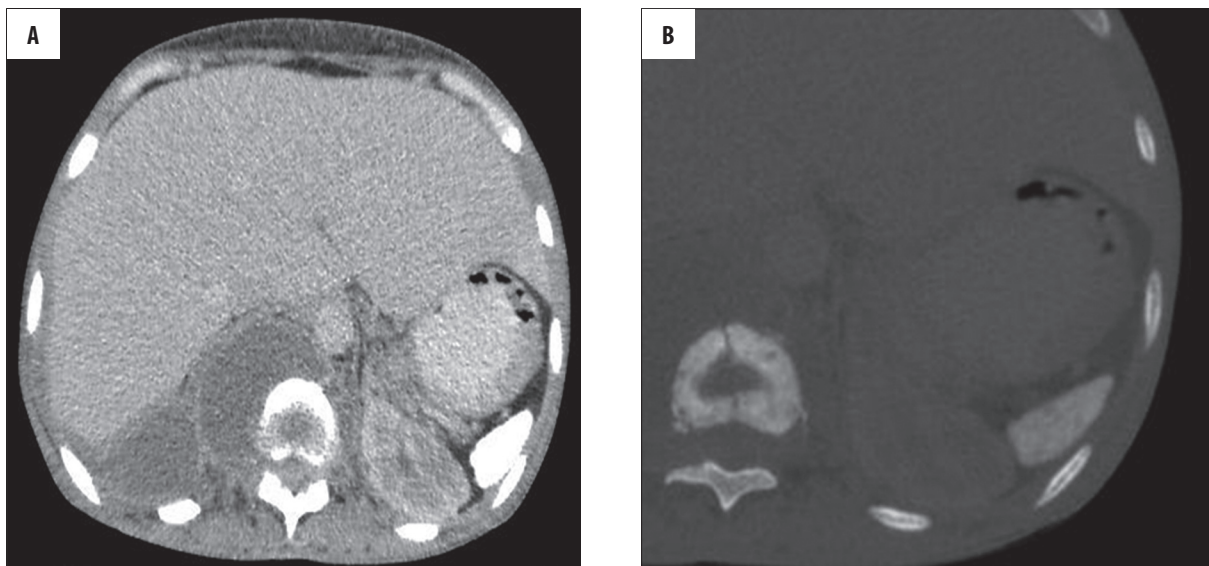


Figure 1. Hepatomegaly (A) associated with a shrunken, completely calcified spleen (B).

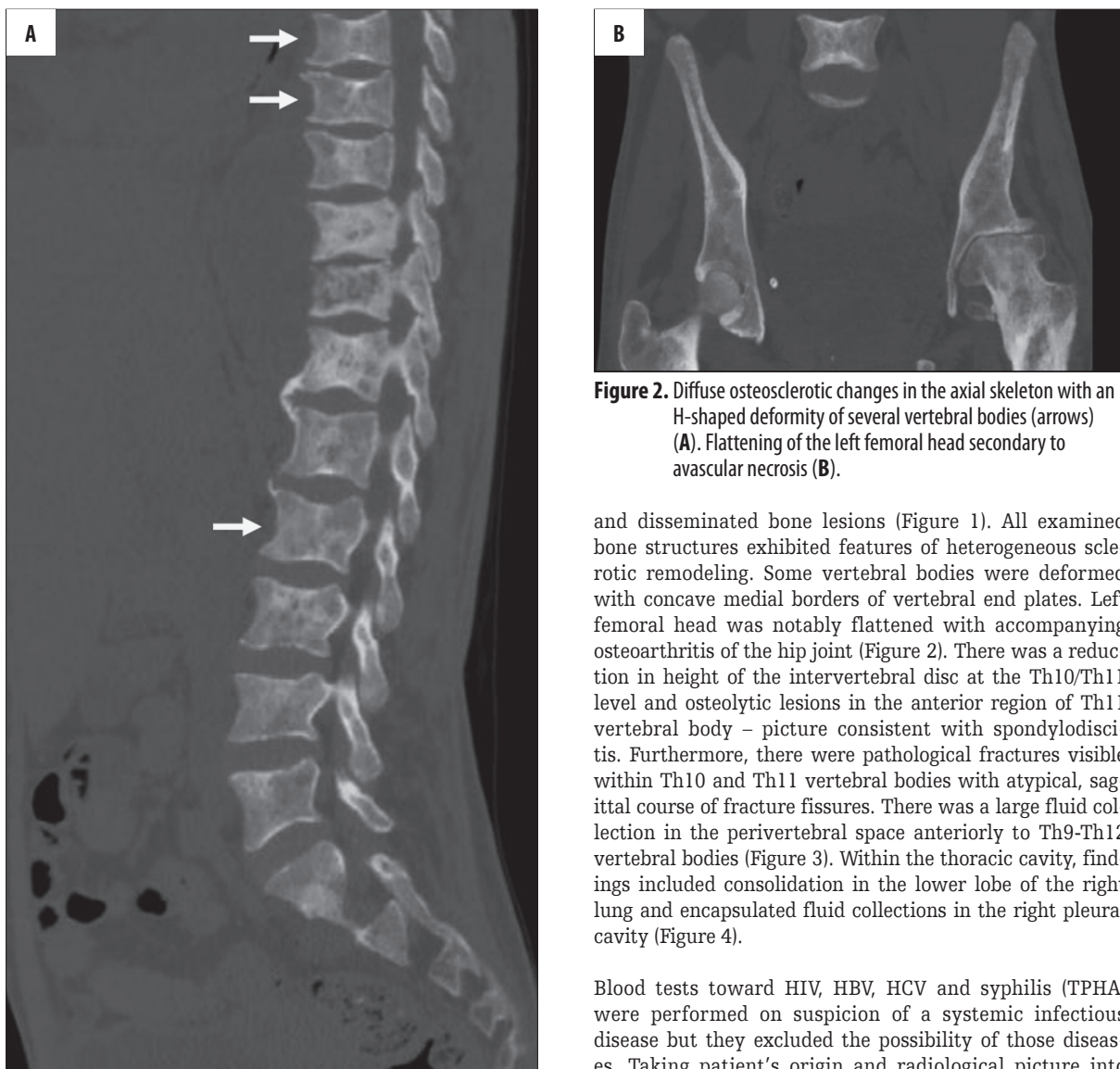
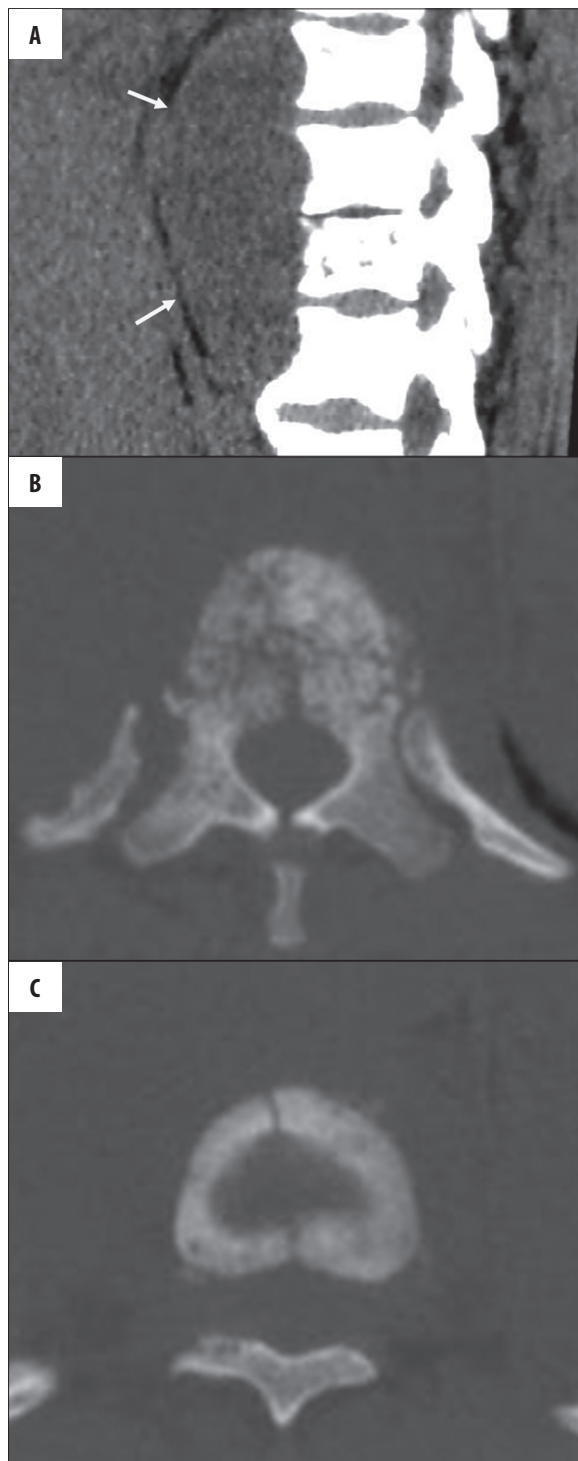

Figure 2. Diffuse osteosclerotic changes in the axial skeleton with an H-shaped deformity of several vertebral bodies (arrows) (A). Flattening of the left femoral head secondary to avascular necrosis (B).

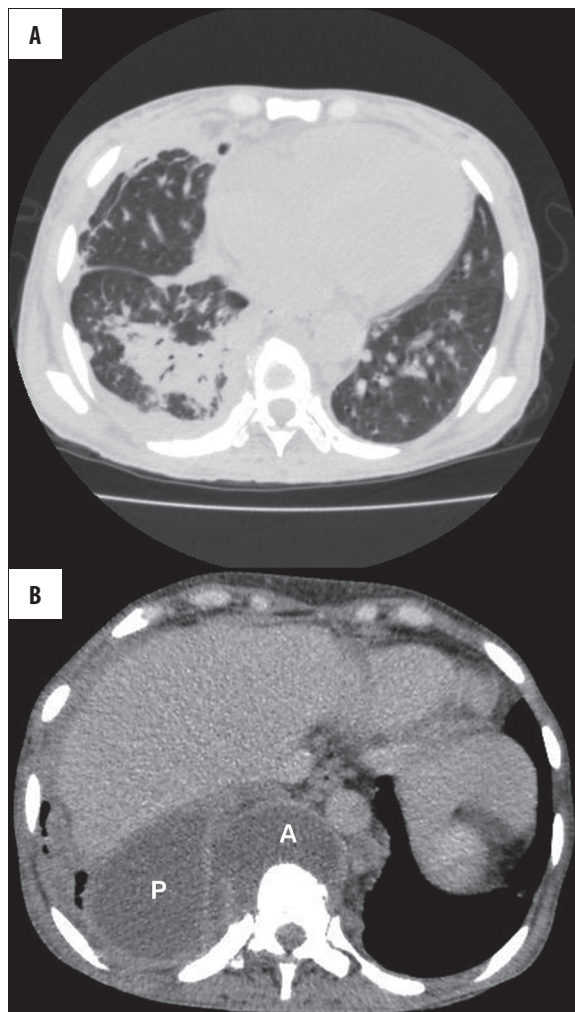
and disseminated bone lesions (Figure 1). All examined bone structures exhibited features of heterogeneous sclerotic remodeling. Some vertebral bodies were deformed with concave medial borders of vertebral end plates. Left femoral head was notably flattened with accompanying osteoarthritis of the hip joint (Figure 2). There was a reduction in height of the intervertebral disc at the Th10/Th11 level and osteolytic lesions in the anterior region of Th11 vertebral body – picture consistent with spondylodiscitis. Furthermore, there were pathological fractures visible within Th10 and Th11 vertebral bodies with atypical, sagittal course of fracture fissures. There was a large fluid collection in the perivertebral space anteriorly to Th9-Th12 vertebral bodies (Figure 3). Within the thoracic cavity, findings included consolidation in the lower lobe of the right lung and encapsulated fluid collections in the right pleural cavity (Figure 4).

Blood tests toward HIV, HBV, HCV and syphilis (TPHA) were performed on suspicion of a systemic infectious disease but they excluded the possibility of those diseases. Taking patient's origin and radiological picture into



**Figure 3.** Spondylodiscitis: reduction of the intervertebral space at the level of Th9-Th10, destructive changes in the anterior part of the Th10 vertebral body and a paraspinal abscess anteriorly (arrows) (A). Inflammatory changes are complicated with pathologic fractures of the Th9 and Th10 vertebral bodies (B,C).

consideration, we suspected sickle-cell disease complicated by tuberculosis. Further diagnostics at the Institute of Hematology confirmed the diagnosis of sickle-cell anemia. A tuberculin test was also performed. Its positive result as



**Figure 4.** Pulmonary complications. Right lower lobe consolidation (A). Right-sided pyothorax (P) and paraspinal abscess (A) (B).

well as clinical and radiological picture allowed for stating a diagnosis of organ tuberculosis. The patient was transferred to the Institute for Infectious Diseases for further treatment.

**Discussion**

Sickle-cell anemia is a hemolytic anemia associated with occurrence of pathological red blood cells, which undergo faster turnover in the bloodstream. Sickle-cell anemia is inherited in an autosomal dominant pattern [1]. Genetic background for sickle-cell anemia was described in 1949, which makes it the first disease with its etiopathology defined at a molecular level [3]. A point mutation within a gene encoding globin on chromosome 11 lays at the origin of sickle-cell anemia, leading to a substitution of valine by glutamic acid at position 6 of the globin chain [3]. The described substitution results in pathological hemoglobin HbS. After deoxygenation, it becomes poorly soluble and forms conglomerates with other hemoglobin particles in the red cell (process known as polymerization) [4]. Appearance of HbS gene quantitatively increases the resistance against infection by malaria parasite (to a greater degree in homozygotic than in heterozygotic carriers), but



it carries a number of undesirable consequences for one's health – more pronounced in people with two defective globin genes. Erythrocytes packed with HbS polymers take an elongated, falciform shape and are less flexible. Pathological blood cells are also more adhesive and attach easily to the endothelium. Thickening of the intima of large vessels is also observed [4]. The most serious consequences for the patient are associated with thromboembolic complications and increased susceptibility to infections. Hemolytic anemia influences patient's well-being to a lesser degree [5].

Pathological changes in the course of sickle-cell anemia involve many organs and develop gradually after birth. In homozygotic individuals, they appear within first few months of life [6]. Splenic enlargement occurs within the first year of life after disappearance of fetal haemoglobin (HbF), which plays a protective role [6]. Enlarged spleen becomes repeatedly infarcted, which may lead to superinfections with formation of abscesses. As a result, functional asplenia develops by the age of 5 with a typical picture of a small calcified spleen in homozygotic individuals (Figure 1B) [7,8]. From that moment, the frequency of infectious complications increases [9]. Another serious complication is sequestration, which involves trapping of significant volumes of circulating blood in the spleen, and may lead to a hypovolemic shock [10]. Contrary to the spleen, the liver becomes gradually enlarged due to the increased levels of erythrocyte degradation products and stimulation of the reticulo-endothelial system secondary to the loss of splenic function (Figure 1A) [8]. Increased degradation of red blood cells leads to hemosiderosis. Cholelithiasis and cholangitis are also commonly occurring complications [8].

Lesions in the skeletal system may result from erythropoietic bone marrow hyperplasia or ischemic and inflammatory complications [11–13]. When symptoms of increased erythropoiesis predominate, x-ray pictures show widening of bone marrow cavities of the long bones with reduction of the cortical layer and general osteoporosis with disappearance of some bone trabeculae and secondary thickening of the remaining ones [14]. Skull x-ray images reveal widening of the diploe with vertical radiolucent areas giving a hair-on-end appearance [15]. A "fish vertebrae" sign is present, which is typical for osteoporosis [16]. Hematopoietic bone marrow expansion is best visualized with an MRI [17]. Presence of red marrow is a factor predisposing to bone infarctions as well as osteitis because it slows down the blood flow leading to local hypoxia and hemoglobin polymerization. It also facilitates deposition of microorganisms [18,19]. Numerous bone infarctions are visible in the entire skeletal system, most commonly in the long bones (mainly femur and humerus), vertebral column, bones of hands and feet and, less often, in the skull [20]. Typical evolution of avascular necrosis may be observed in the epiphyses of the long bones. Its last stage involves epiphyseal collapse with destruction of articular surface and development of secondary osteoarthritis (Figure 2B) [21,22]. Evolution of bone infarctions in the metaphyses of long bones and vertebral column leads to formation of sclerotic lesions with dystrophic calcifications [23]. Typical picture of vertebral osteonecrosis includes H-shaped vertebral bodies formed as a result of collapsing of the ischemic central end plate regions and hypertrophy of anterior and posterior parts of

the vertebrae (indicated by arrows on Figure 2A) [24]. This deformation occurs in about 10% of patients with sickle-cell anemia and is a pathognomonic feature of the disease [24]. Early phase of bone infarction resembles an osteolytic lesion and is difficult to differentiate from osteitis [11]. Osteitis occurs even 100 times more often in a population of patients with sickle-cell anemia than in healthy individuals [25]. Etiological factors are usually bacteria such as *Salmonella* and *Staphylococcus* [18,26]. Frequent infections caused by *Salmonella species* and Gram-negative bacilli are associated with intestinal microinfarctions that lead to periodic bacteriemia [18]. In addition to the foci of bone destruction, computed tomography may demonstrate periosteal reaction and fluid collections located subperiosteally as well as in neighboring soft tissues. However, these kinds of lesions may also appear in the course of bone infarction [27]. MRI examination allows for a more accurate differentiation between the red marrow, acute bone infarction and osteomyelitis. Hematopoietic bone marrow is characterized by low signal in T1-weighted images and low to intermediate signal in T2-weighted images [17]. Both acute bone marrow infarction as well as osteomyelitis will exhibit high signal in T2-weighted images [28,29]. Contrast enhancement is helpful in the differential diagnosis between those two pathologies: thin, linear peripheral changes present in infarction vs. geographic, irregular changes characteristic for inflammation [29,30].

Inflammatory vertebral lesions in the course of tuberculosis have been thoroughly described in numerous publications [31–35]. Vertebral column is the most common site of tuberculous process in the skeletal system [36]. In contrast to staphylococcal infections, which usually locate in the lumbar region of the vertebra, tuberculosis shows predilection for the thoracic region [36]. Inflammation involves an intervertebral disc and vertebral bodies [31,32]. Features indicating the likelihood of tuberculous infection include involvement of anterior parts of vertebral bodies with relative sparing of intervertebral discs, spreading of the inflammation along the anterior longitudinal ligament (i.e. anterior spondylitis) and presence of diffuse gravitation abscesses (Figure 3) [31–35]. MRI is a method of choice for detection and evaluation of the extent of inflammatory changes in the vertebral column and perivertebral soft tissues [33,34]. As mentioned before, osteolytic foci in vertebral bodies should be differentiated from an acute phase of bone infarction. However, reduction of intervertebral disc height at the level of involved vertebral bodies (on the remaining levels the disc height was normal) and extensive fluid collection in the perivertebral soft tissues present in the described case pointed directly to an inflammatory condition (Figures 2A, 3A).

It is important to consider thalassemia, which may give a similar radiological picture, and Gaucher's disease in the differential diagnosis of sickle-cell anemia. Hepatomegaly is a nonspecific sign, which may be present in: hepatosteatosis, acute hepatitis, venous congestion in the course of right-sided heart failure, lymphoma, amyloidosis or primary biliary cirrhosis. Presence of a small, calcified spleen may be helpful for the diagnosis of homozygotic sickle-cell disease, as this sign is rarely present in heterozygotic SCA patients or in the course of thalassemia [37].

---

**References:**

---

1. Szczeklik A: Choroby wewnętrzne. Stan wiedzy na rok 2010. Medycyna Praktyczna, Kraków, 2010, 1507 [in Polish]
2. Bowman JE, Murray RFJ: Genetic variation in peoples of African origin. Baltimore, Md: Johns Hopkins University Press, 1990, 196-201
3. Pauling L, Itano HA, Singer SJ et al: Sickle cell anemia: a molecular disease. Science, 1949; 110: 543-49
4. Bookchin RM, Lew VL: Pathophysiology of sickle cell anemia. Hematol Oncol Clin North Am, 1996; 10: 1241-53
5. Ballas SK: Sickle cell disease: clinical management. Baillieres Clin Haematol, 1998; 11: 185-214
6. Powers DR: Natural history of sickle cell disease-the first ten years. Semin Hematol, 1975; 12: 267-85
7. Magid D, Fishman EK, Siegelman SS: Computed Tomography of Spleen and Liver in Sickle Cell Disease. AJR, 1984; 143: 245-49
8. McCall IW, Vaidya S, Serjeant GR: Splenic opacification in homozygous sickle cell disease. Clin Radiol, 1981; 32: 611-15
9. Barrett-Connor E: Bacterial infection and sickle cell anemia. Medicine, 1971; 50: 97-112
10. Roshkow JE, Sanders LM: Acute splenic sequestration crisis in two adults with sickle cell disease: US, CT, and MR imaging findings. Radiology, 1990; 177: 723-25
11. Lonergan GJ, Cline DB, Abbondanzo SL: Sickle cell anemia. Radiographics, 2001, 21: 971-94
12. States LJ: Imaging of metabolic bone disease and marrow disorders in children. Radiol Clin North Am, 2001; 39: 749-72
13. Jean-Baptiste G et al: Osteoarticular disorders of haematological origin. Baillieres Best Pract Res Clin Rheumatol, 2000, 14: 307-23
14. Carroll DS: Roentgen manifestations of sickle cell disease. South Med J, 1957; 50: 1486-90
15. Sebes JI, Diggs LW: Radiographic changes of the skull in sickle cell anemia. AJR, 1979;123: 373-77
16. Reynolds J: A re-evaluation of the „fish vertebra” sign in sickle cell hemoglobinopathy. AJR, 1966; 97: 693-707
17. Deely DM, Schweitzer ME: MR imaging of bone marrow disorders. Radiol Clin North Am, 1997; 35: 193-212
18. Smith JA: Bone disorders in sickle cell disease. Hematol Oncol Clin North Am, 1996; 10: 1345-56
19. Anand AJ, Glatt AE: *Salmonella osteomyelitis* and arthritis in sickle cell disease. Semin Arthritis Rheum, 1994; 24: 211-21
20. Carache S, Page DL: Infarctions of bone marrow in sickle cell disorders. Ann Intern Med, 1967; 67: 1195-200
21. Ware HE, Brooks AP, Toye R et al: Sickle cell disease and silent avascular necrosis of the hip. J Bone Joint Surg Br, 1991; 73: 947-49
22. Herningou P et al: Abnormalities of the adult shoulder due to sickle cell osteonecrosis during childhood. Rev Rhum Engl Ed, 1998, 65: 27-32
23. Weinberg S: Severe sclerosis of the long bones in sickle cell anemia. Radiology, 1982;145: 41-43
24. Leong CS, Stark P: Thoracic manifestations of sickle cell disease. J Thorac Imaging, 1998; 13: 128-34
25. Engh CA, Hughes JL, Abrams RC et al: Osteomyelitis in the patient with sickle cell disease. Diagnosis and management. J Bone Joint Surg (Am), 1971; 53: 1-15
26. Burnett MW, Bass JW, Cook BA: Etiology of osteomyelitis complicating sickle cell disease. Pediatrics, 1998; 101: 296-97
27. Stark JE, Glasier CM, Blasler RD et al: Osteomyelitis in children with sickle cell disease: early diagnosis with contrast-enhanced CT. Radiology, 1991; 179: 731-33
28. Frush DP, Heyneman LE, Ware RE et al: MR features of soft-tissue abnormalities due to acute marrow infarction in five children with sickle cell disease. AJR, 1999; 173: 989-93
29. Umans H, Haramati N, Flusser G: The diagnostic role of gadolinium enhanced MRI in distinguishing between acute medullary bone infarct and osteomyelitis. Magn Reson Imaging, 2000; 18: 255-62
30. Bonnerot V, Sebag G, de Montalembert M et al: Gadolinium-DOTA enhanced MRI of painful osseous crises in children with sickle cell anemia. Pediatr Radiol, 1994; 24: 92-95
31. Boxer DI, Pratt C, Hine AL et al: Radiological features during and following treatment of spinal tuberculosis. Br J Radiol, 1992; 65: 476-79
32. Shanley DJ: Tuberculosis of the spine: imaging features. AJR Am J Roentgenol, 1995; 164: 659-64
33. al-Mulhim FA, Ibrahim EM, el-Hassan AY et al: Magnetic resonance imaging of tuberculous spondylitis. Spine, 1995; 20: 2287-92
34. Desai SS: Early diagnosis of spinal tuberculosis by MRI. J Bone Joint Surg Br, 1994;76: 863-69
35. Całka K, Plucińska I, Jaźwiec P et al: Gruźlica kręgosłupa – obraz radiologiczny, opis przypadku. Pol J Radiol, 2006; 71(4): 77-81 [in Polish]
36. Martini M, Quaehes M: Bone and joint tuberculosis: a review of 652 cases. Orthopedics, 1988; 2: 861-66
37. Özgen A, Akata D, Arat A et al: Splenic calcifications in heterozygote sickle cell patients. Abdom Imaging, 1999; 24: 188-190