

Oncology

Metachronous ureteral metastasis of clear cell renal cell carcinoma in a duplex collecting system 1 year after nephrectomy

Sankara Varun Bhoopathy^{a,*}, Yilu He^a, Steve McCombie^a, Shannon Fadaee^b, Stuart Adams^b, Mohan Arianayagam^a

^a Nepean Urology Research Group, Nepean Hospital, PO Box 63, Penrith, NSW, 2751, Australia

^b NSW Health Pathology, Nepean Hospital, Penrith, NSW, 2751, Australia



ABSTRACT

While renal cell carcinoma is known to metastasise in an unpredictable pattern, even after resection of a primary tumour, delayed ureteric metastasis is a very rarely reported phenomenon. In this case report, we describe a case of ipsilateral metachronous ureteric metastasis in a patient with a complete duplex collecting system. This case demonstrates some useful strategies in the diagnosis and treatment of renal cell carcinoma in this context. To our knowledge, this is the first case report of delayed ureteric metastasis of a renal clear cell carcinoma in a patient with a duplex collecting system.

Introduction

Renal cell carcinoma (RCC) is known to present with metastases even after resection of the primary tumour. Although the introduction of immunotherapy has revolutionised the treatment of metastatic RCC, surgical resection of metastatic lesions is still indicated in certain situations if technically feasible. This is particularly relevant for metastases with favourable disease characteristics, and causing local symptoms.¹ Sites of metastasis of RCC are characteristically unpredictable, with the most frequent being to the lymph nodes, lung, liver, brain and skin. Delayed ureteric metastasis is very rare and, to our knowledge, has never been reported in a patient with a duplex collecting system. We describe below an ipsilateral ureteral stump metastasis of clear cell RCC in a complete duplex kidney that occurred one year following right nephrectomy.

Case presentation

A 49-year-old man initially presented with a one-month history of frank haematuria and intermittent right flank pain. He is a plumber with no significant past medical, surgical or family history. He is an ex-smoker with a 20-pack year history. Physical examination was unremarkable. A CT IVP revealed a duplex right sided collecting system, with a mass in the lower pole of the right kidney appearing to extend into the lower pole calyx. The CTIVP, and staging CT chest did not show any

evidence of metastatic disease or renal vein involvement.

Given that an upper tract Urothelial Cancer (UC) could not be excluded, he subsequently underwent a right ureteroscopy and pyeloscopy to ascertain the lesion's origin. This confirmed a complete duplex collecting system with a normal upper pole moiety system but evidence of irregular urothelium with an overlying blood clot in a lower pole moiety system. This was biopsied during pyeloscopy, however unfortunately the biopsy results were indeterminate. A repeat pyeloscopy showed similar findings and, although the biopsies again returned indeterminate, washings from the lower pole calyx demonstrated atypical cells. After discussion with the patient and a multidisciplinary team review, a decision was made to proceed to a laparoscopic right nephrectomy. Intraoperative frozen section was planned to be utilised to differentiate RCC from UC, and hence the need for concurrent removal of the duplex ureters.

At the time of his laparoscopic right nephrectomy the intraoperative frozen sections were indicative of a clear cell RCC and therefore concurrent ureterectomies were not performed. Formal histopathology confirmed the excision of an ISUP 2 clear cell RCC with invasion of the collecting system and renal vein, and negative surgical margins. The patient recovered well and an ultrasound at six months did not demonstrate any evidence of recurrence.

The patient subsequently re-presented with macroscopic haematuria 12 months after his nephrectomy, with a contrast computed tomography (CT) scan showing a thickened distal right ureter (Fig. 1). Ureteroscopy

Abbreviations: CT, Computed tomography; CTIVP, Computed Tomography Intravenous Pyelogram; PET, Positron Emission Tomography; RCC, Renal cell carcinoma; UC, Urothelial Cancer.

* Corresponding author.

E-mail address: mail@vaboo.org (S.V. Bhoopathy).

<https://doi.org/10.1016/j.eucr.2020.101214>

Received 21 March 2020; Accepted 15 April 2020

Available online 16 April 2020

2214-4420/Crown Copyright © 2020 Published by Elsevier Inc.

This is an open access article under the CC BY-NC-ND license

(<http://creativecommons.org/licenses/by-nc-nd/4.0/>).

demonstrated a mass within the lower pole moiety ureter, and biopsy demonstrated a clear cell RCC, presumed to have metastasized from the original tumour. Repeat staging excluded any other evidence of metastatic disease.

Following re-discussion at a multidisciplinary meeting, the patient underwent a robotic-assisted laparoscopic excision of both residual right ureters. Cystoscopic placement of ureteric catheters aided this resection, wherein an extensive inflammatory mass encompassing both right distal ureters was found and removed en-bloc (Fig. 2). Histology confirmed the excision of a clear cell RCC, with invasion into the muscularis propria of the ureter, and negative surgical margins (Fig. 3). The tumour had a similar immunohistochemical profile to the original tumour (PAX8, CD10 and Vimentin positive; Cytokeratin 7 and Gata 3 negative).

Discussion

RCC is well known for its propensity to metastasise early. Metastases are present in one third of patients at presentation, and one fifth of patients who have a nephrectomy for localised disease subsequently progress to metastatic disease.² However, the development of metachronous ureteral metastasis is very rare,³ and our case is the first in a patient with a duplex collecting system. In the majority of other reported cases the metastasis occurred to the ipsilateral ureteral stump, however reports of metastases to the contralateral ureter and bladder do exist.⁴

The mechanisms of the underlying spread of RCC to the ureter is debateable. Numerous possible mechanisms are proposed, including endoluminal or “drop metastasis” and implantation down the ureter, retrograde venous or lymphatic spread, and haematogenous spread. In the reported cases of ureteric metastasis, haematuria is the most common presentation.⁴ The time to metastasis in reported cases varied from 4 months to 12 years.³ European Association of Urology guidelines recommend performing metastasectomy when lesions are resectable, particularly in the presence of favourable disease characteristics, such as metachronous solitary metastases.¹ This has the highest effect on overall survival, as current immunotherapy and targeted therapies are not yet as effective.¹ As such, we performed a distal ureterectomy for this patient, as was the management for most of the previously reported cases.

This unusual case highlights some other useful strategies for the management of RCC. Firstly, in patients with a renal mass wherein UC is not excluded after multiple diagnostic procedures, intraoperative frozen section during nephrectomy can be used to guide decisions regarding concurrent ureterectomy. Secondly, the authors found the placement of ureteric catheters very helpful in performing the distal ureterectomy in this patient. Having ureteric catheters within both remnant ureters helped to define the extent of excision required, including removal of an adequate bladder cuff for a complete duplex system. Equally, having a ureteric catheter in the contralateral ureter helped with its protection during the procedure.

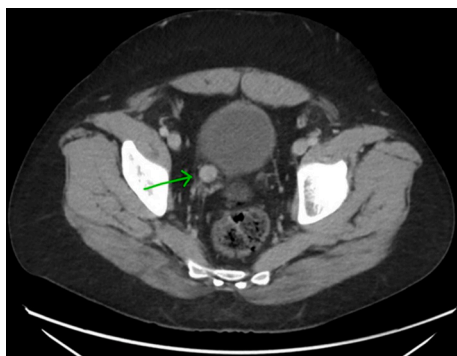

Fig. 1. Axial CT - Ovoid enhancing lesion in the distal right ureter.

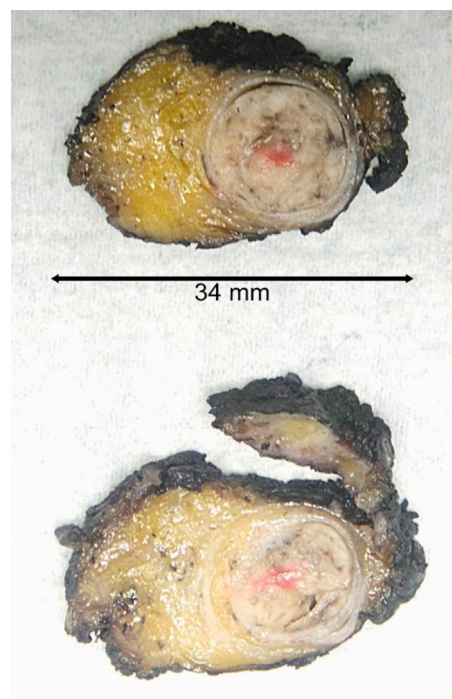


Fig. 2. Macroscopic photos of the involved right distal ureter.

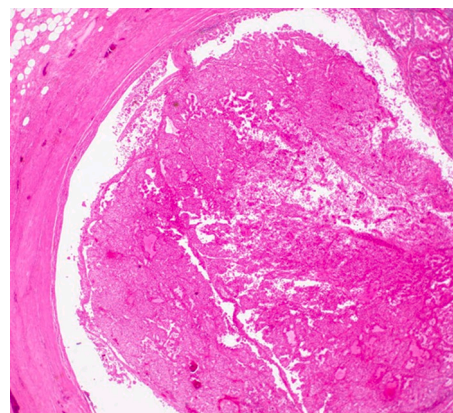


Fig. 3. Microscopic photo of the ureter tumour at x20 magnification.

Conclusion

Our case demonstrates a rare metastasis of RCC to the residual ureter. This unusual diagnosis should be considered in any patient that presents with haematuria following treatment for RCC. In the case of previous nephrectomy, a high index of suspicion may be required given the lack of delayed phase opacification of the ureter in this scenario. If this diagnosis is confirmed then, in the absence of other metastatic disease, proceeding to distal ureterectomy is a reasonable treatment option.

Consent

Consent has been obtained from the patient to use their deidentified clinical history, pathology and imaging findings.

Author contributions

Dr Sankara Varun Bhoopathy, Dr Yilu He, Dr Steve McCombie, Dr Shannon Fadaee, Dr Stuart Adams, and Dr Mohan Arianayagam

contributed to the conception and design of the paper, acquisition and interpretation of the data. All authors were involved in drafting and revising it critically and approve of the final version for publication. All authors agree to be accountable for all aspects of the work in ensuring that questions related to accuracy or integrity of any part of the work are appropriately investigated and resolved.

References

1. Ljungberg B, Bensalah K, Canfield S, et al. EAU guidelines on renal cell carcinoma: 2014 update. *Eur Urol*. 2015;67(5):913–924.
2. Tosco L, Van Poppel H, Freja B, Gregoraci G, Joniau S. Survival and impact of clinical prognostic factors in surgically treated metastatic renal cell carcinoma. *Eur Urol*. 2013;63(4):646–652.
3. Cheng K-C, Cho C-L, Chau LH, Lam K-M, So H-S. Solitary metachronous metastasis of renal cell carcinoma to the ureter. *Int J Case Rep Med*. 2013;2013.
4. Zorn KC, Orvieto MA, Mikhail AA, et al. Solitary ureteral metastases of renal cell carcinoma. *Urology*. 2006;68(2):428. e5-.e7.