

# Diagnostic Value of Extraoral Periapical Radiograph in Comparison to Intraoral Periapical Radiograph: A Cross-sectional, Institutional Study

## Abstract

**Background:** Radiographs form an invaluable adjunct in diagnosis, treatment planning, and postoperative evaluation during patient management in the dental office where intraoral periapical (IOPA) radiographs are the ones most commonly used. However, certain conditions render the placement of film difficult. In such cases, a panoramic radiograph may be taken, but it has the disadvantage of higher radiation exposure and cost. Extraoral periapical (EOPA) technique allows radiographs to be taken on an IOPA film by placing it extraorally. We aimed to evaluate its diagnostic accuracy compared to intraoral bisecting angle technique. **Materials and Methods:** Forty-five patients were randomly selected. Ninety radiographs were taken; two for each patient. First image was obtained by intraoral bisecting angle technique and second by EOPA technique. A scale was devised for the comparison of radiographs taken by the two techniques. Two experienced oral radiologists rated them based on the scale followed by statistical analysis. **Results:** Patients reported increased compliance with the EOPA technique. 84.40% of the EOPA radiographs (EOPARs) were diagnostically acceptable; sensitivity and specificity was 84% and 55%, respectively. **Conclusion:** EOPAR is beneficial in cases where intraoral film placement is difficult, and a radiograph is necessary for patient management, even though it demonstrates comparatively lesser diagnostic accuracy.

**Keywords:** Dental radiology, diagnostic value, extraoral, intraoral, periapical

## Introduction

General dental practitioners rely heavily on intraoral periapical radiographs (IOPARs) during day-to-day clinical practice. A good-quality IOPAR allows better assessment of the tooth morphology, periodontal structures, and periapical pathosis along with the prediction of prognosis, and posttreatment evaluation. Taking an IOPAR becomes difficult in situations where the patient is unable to tolerate the placement of an IOPA film/sensor due to anatomical difficulties, gag reflex, trauma, extensive ulceration, or a pediatric age group. A panoramic radiograph may be taken, but it has the disadvantage of higher radiation dose, lack of availability in dental clinics, patient cooperation (pediatric), and higher cost.

Extraoral periapical radiography (EOPAR) is a technique which was introduced in 2003 by Newman and Friedman.<sup>[1]</sup> In this technique, the IOPA film/sensor is placed

extraorally, directly overlying the area of interest, and the X-ray beam is directed from the contralateral side. In addition to patients who are intolerant to conventional IOPAR, it can also be used to determine working length while the rubber dam is in place.

Very limited literature is available on this technique. Therefore, we conducted a study to assess the diagnostic value of EOPA technique in adults and to compare it with the conventional IOPA technique.

## Materials and Methods

Institutional ethical clearance was obtained, and informed consent was taken from the patients. Given an alpha error of 0.05, abeta error of 0.2, the sample size was calculated as 45. Both male and female patients were consecutively selected between the age group of 18 and 70 years for this clinical, cross-sectional, single-center study. Patients reporting to the Department of Oral Medicine and Radiology seeking IOPAR for the treatment of any nature were included.

**How to cite this article:** Mishra I, Karjodkar FR, Sansare K, Dora AC, Tambawala SS, Kapoor R, *et al.* Diagnostic value of extraoral periapical radiograph in comparison to intraoral periapical radiograph: A cross-sectional, institutional study. *Contemp Clin Dent* 2018;9:406-9.

Isha Mishra,  
Freny R. Karjodkar<sup>1</sup>,  
Kaustubh Sansare<sup>1</sup>,  
Amaresh Chandra  
Dora<sup>1</sup>,  
Shahnaz S.  
Tambawala<sup>1</sup>,  
Ruchika Kapoor<sup>1</sup>,  
Sneha R. Sharma<sup>1</sup>

*Department of Oral Medicine and Radiology, Government Dental College and Hospital, <sup>1</sup>Department Oral Medicine and Radiology, Nair Hospital Dental College, Mumbai, Maharashtra, India*

**Address for correspondence:**  
Dr. Isha Dharendra Mishra,  
C-6/5, Neelkamal Building, Flat  
No. 3:2, Sector 5, CBD Belapur,  
Navi Mumbai - 400 614,  
Maharashtra, India.  
E-mail: eisha.mishra@gmail.com

### Access this article online

**Website:**  
www.contempclindent.org

**DOI:** 10.4103/ccd.ccd\_152\_18

### Quick Response Code:



This is an open access journal, and articles are distributed under the terms of the Creative Commons Attribution-NonCommercial-ShareAlike 4.0 License, which allows others to remix, tweak, and build upon the work non-commercially, as long as appropriate credit is given and the new creations are licensed under the identical terms.

For reprints contact: reprints@medknow.com

Pregnant patients, patients with a very large diffuse extraoral swelling, or those in immediate treatment needs (except when intolerant to IOPA technique and a repeat radiograph was already advised) were excluded.

A total of 90 radiographs were taken; two for each patient. First image was taken by intraoral bisecting angle technique and second by EOPA technique. Both radiographs were taken with optimal radiation exposure precautions (lead apron and thyroid collar). Care was taken to ensure that almost equal radiographs of the posterior teeth were taken from both the right and left sides and maxillary and mandibular arches. Dental X-ray Unit (IntraSkan DC, by Skanray Technologies Pvt. Ltd., manufactured in Mysore, India, 2015) was set at 65 kVp, 6 mA with exposure time of 0.8 s for IOPA technique (short-cone settings) and 0.9 s for EOPA technique (long-cone settings). Size 2 Kodak E-Speed film was used. Both films were processed identically using the manual time–temperature method. For the EOPA technique, the patient was asked to sit upright with his/her mouth as wide open as possible to prevent overlapping of the contralateral structures. X-ray tube was directed from the opposite side of the face and opposite arch. Exposing surface of the film was placed toward the cheek, overlying the tooth in question, facing the direction of X-rays. Occlusal clearance was kept approximately 1/8<sup>th</sup>-inch length of the film. A cotton roll was placed between the film and the cheek to achieve parallelism. A scale was devised for the comparison of IOPAR and corresponding EOPAR. Two experienced oral and maxillofacial radiologists assessed the radiographs and rated them based on the scale. The radiologists examined the IOPAR and corresponding EOPAR in succession but in a random order. Direct visual examination was performed under adequate illumination. All observations were immediately noted in a tabular format with parameters of the scale devised (given below). Examiners were blinded to the identity of the technique with which the radiographs were taken. The patient recruitment and data collection for the study were completed from November 2016 to December 2016.

#### Positioning of the patient for maxillary teeth

For the maxillary teeth, frankfurt horizontal plane was kept parallel to the floor and X-ray beam was directed with a negative angulation from the contralateral side (around 20°–30° to the horizontal plane such that it was perpendicular to the film) [Figure 1a].

#### Positioning of the patient for mandibular teeth

For the mandibular teeth, occlusal plane was kept parallel to the floor and the X-ray beam was directed with a positive angulation (around 20°–30° to the horizontal plane such that it was perpendicular to the film) [Figure 1b].

#### Scale

To the best of our knowledge, no scale was available in literature to assess the diagnostic value of a dental radiograph. To achieve objective assessment and comparison of the IOPAR and EOPAR, we devised a scale. The factors determining visual characteristics (adequate density and contrast), geometric characteristics (presence of sharpness and absence of magnification and distortion), anatomical accuracy (based on presence of superimposition of buccal and lingual cusp tips, cementoenamel junction and alveolar crests, open contacts and absence of zygoma superimposition), and radiographic coverage (visibility of the area of interest) were considered. Each of these seven parameters was awarded a score of 1 if acceptable and 0 if unacceptable as described in Table 1. With a maximum score of 7, radiographs with a score of  $\geq 3$  were considered diagnostically acceptable. Sample images of the diagnostically acceptable IOPAR and corresponding EOPAR are given in Figures 2 and 3].

#### Statistical analysis

The SPSS for Windows, Version 16.0. (SPSS Inc., 2007, Chicago, USA) analysis was used. Wilcoxon rank test was

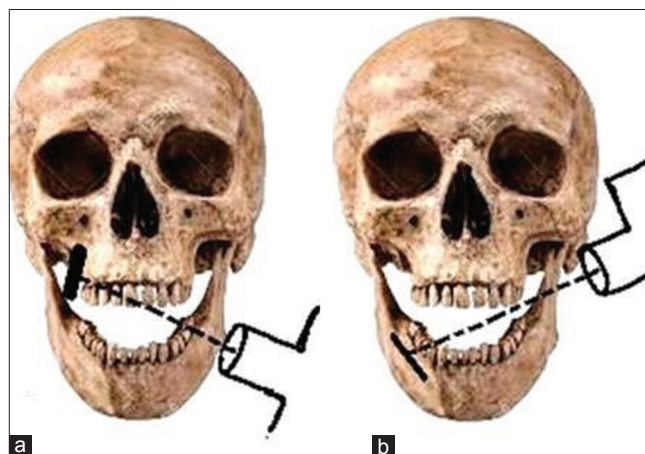


Figure 1: (a) Schematic representation of the placement of film/sensor and X-ray beam for taking maxillary radiograph using the extraoral periapical technique. (b) Schematic representation of the placement of film/sensor and X-ray beam for taking mandibular radiograph using the extraoral periapical technique

Table 1: Scale to determine the diagnostic value of radiograph and the method of scoring

Parameter	Acceptable/unacceptable score
Density	1/0
Contrast	1/0
Sharpness	1/0
Magnification	1/0
Distortion	1/0
Anatomical accuracy	1/0
Radiographic coverage	1/0
Total score	7/0
Diagnostically acceptable	$\geq 3$

used to evaluate the association between the parameters of IOPAR and EOPAR. Sensitivity and specificity along with positive and negative predictive value were estimated. Statistical significance was kept at  $P < 0.05$ . Interobserver agreeability was checked using the Cohen's kappa test.

### Results

In terms of density and contrast, EOPAR was *at par* with IOPAR ( $P$  value was not significant). For parameters of sharpness, magnification, distortion, anatomical accuracy, and radiographic coverage, EOPAR was inferior to IOPAR ( $P$  value was significant) [Graph 1 and Table 2]. 84.40% of the EOPARs, however, were diagnostically acceptable. Overall interobserver agreeability was moderate to substantial. The sensitivity and specificity of EOPA were 84% and 55%, respectively. Positive predictive value was 74% and negative predictive value was 49%.

### Discussion

EOPAR is a technique that can be employed in a wide spectrum of clinical conditions where the patient cannot tolerate the intraoral film placement. This includes patients with a severe gag reflex or a low pain threshold, shallow floor of the mouth or palate, dental phobia and anxiety, trismus, extensive ulceration or trauma, presence of tori, impacted third molars, and patients with communicable diseases. In addition, it can also be used to determine the working length when the rubber dam is in place.

The concept of extraoral radiography was introduced in 1974 by Fischer, who obtained images of the third molars using occlusal films. However, he used a kVp as high as 90 kV which had an obvious limitation.

In 2003, Newman and Freidman developed the technique of EOPAR and used it to obtain diagnostically acceptable radiographs while performing endodontic therapy.<sup>[1]</sup> They proposed placement of extraoral film/sensor externally with the angulation of  $-55^\circ$  for maxillary teeth and  $-35^\circ$  for mandibular teeth.

In 2007, Chen *et al.* described the design and testing of a film/sensor-beam alignment aiming device intended to

facilitate implementation of the technique proposed by Newman and Freidman.<sup>[2]</sup> They also advocated the usage of a lesser angulation, i.e., 20–25 for upper teeth and 10–15 for mandibular teeth.

In 2011 and 2013, Kumar *et al.*<sup>[3,4]</sup> demonstrated the usage of this technique in patients who were unable to tolerate the IOPA film/sensor in a variety of clinical conditions and found it to be effective in obtaining diagnostically acceptable radiographs.

In 2015, Babu and Patel<sup>[5]</sup> performed a comparative analysis of radiographs taken by the intraoral and extraoral technique in pediatric patients using a questionnaire and found EOPA to be a useful alternative to the conventional technique in pediatric patients.

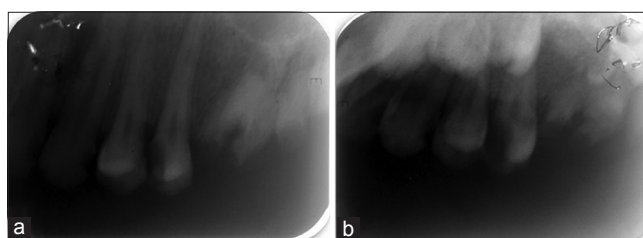


Figure 2: (a) Intraoral periapical radiograph of the maxillary first molar root piece. (b) Extraoral periapical radiograph of the maxillary first molar root piece

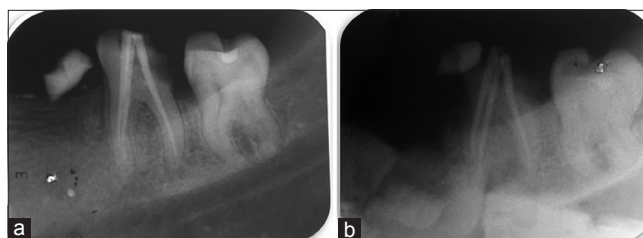
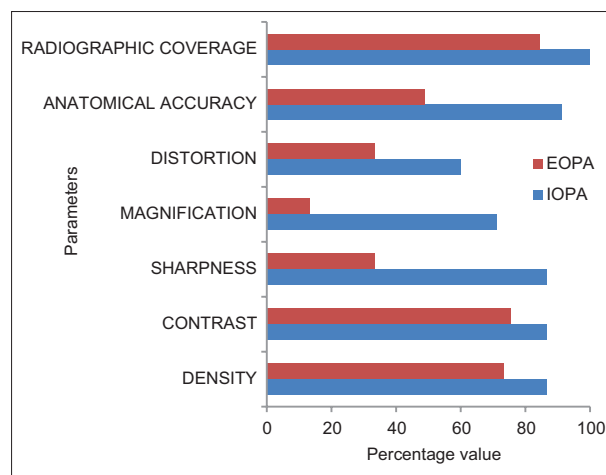


Figure 3: (a) Intraoral periapical master cone radiograph of the mandibular first molar. (b) Extraoral periapical master cone radiograph of the mandibular first molar

**Table 2: P value obtained using Wilcoxon rank test on comparison of the parameters in periapical radiographs taken by intraoral and extraoral technique**

Parameter	P (Wilcoxon rank test)
Density	0.11
Contrast	0.17
Sharpness	<0.001
Magnification	<0.001
Distortion	0.01
Anatomical accuracy	<0.001
Radiographic coverage	0.003
Diagnostic acceptability	0.006



Graph 1: Bar chart showing comparison of parameters in periapical radiographs taken by Intra-Oral & Extra-Oral technique

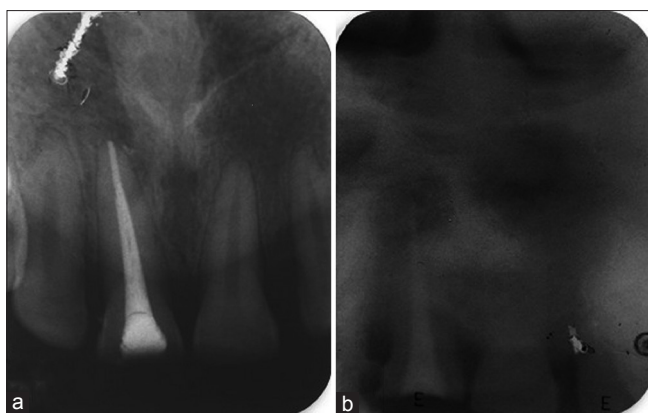


Figure 4: (a) Intraoral periapical postobturation radiograph of the maxillary central incisor. (b) Extraoral periapical postobturation radiograph of the maxillary central incisor

In this study, we compared the radiographs of the same region taken by the intraoral bisecting angle technique and by the EOPA technique. The results indicated that *P* value was not significant for the value of density and contrast but was significant for the values of sharpness, magnification, distortion, anatomical accuracy, and radiographic coverage. Thus, EOPA was inferior to IOPA in most parameters. However, diagnostic acceptability of EOPA was 84.40%.

Magnification and loss of sharpness were inherent faults because the EOPA film was placed externally. As per the rules of projection geometry, the increased film and object distance leads to magnification and consequently loss of sharpness. Distortion and lack of anatomical accuracy were noted probably because the direction of the beam is such that it does not fall perpendicular to the film/object.

As per the study by Babu and Patel,<sup>[5]</sup> pediatric dentist observed that 24 (80%) intraoral radiographs and 22 (73%) extraoral radiographs had a diagnostic value. However, the oral radiologist of this study concluded that 24 (80%) intraoral radiographs and 17 (57%) extraoral radiographs had diagnostic value. Moderate agreement with  $\kappa$ -value of 0.4872 (0.41–0.60) was found between the two observers. Our results were greater than both (84.40%). This could be because adult patients tend to be more compliant than pediatric patients.

The advantages of EOPA are lesser radiation exposure and cost in comparison to alternatives like panoramic radiograph. EOPA technique may be more consistent with the principle of optimization.<sup>[6]</sup>

In addition, it can be easily done with the intraoral X-ray machine within the clinic itself and has better patient compliance than IOPA. The drawbacks of this technique are that it is sensitive and takes some skill and patience to master. Overlapping and magnification are inherent faults. Our study had the limitations of a small sample size and subjective evaluation of parameters by the two examiners.

The inability to take radiographs of the anterior teeth is listed as a limitation in literature. In addition to our

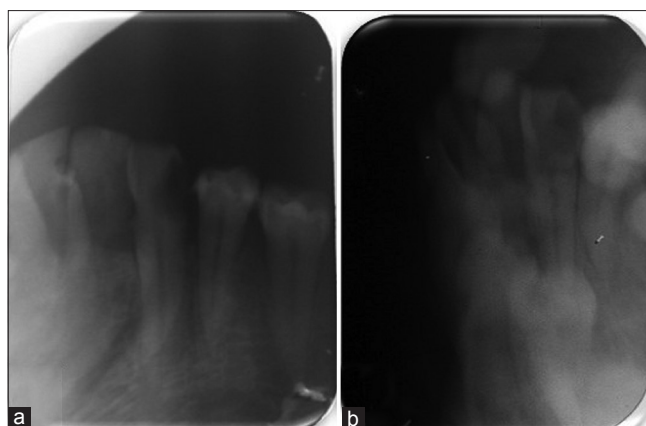


Figure 5: (a) Intraoral periapical radiograph of the mandibular canine. (b) Extraoral periapical radiograph of the mandibular canine

comparative study, we attempted to radiograph the maxillary central incisor as shown in Figure 4 by making the patient flex his neck forward and directing the X-ray beam from below the base of the skull and mandibular canine as shown in Figure 5 similar to anterior lateral oblique radiograph. Although the radiographs were not very clear, the basic pathology could be appreciated. Further refinement of the technique or usage of an F-speed film with increased kVp may help overcome this limitation.

## Conclusion

EOPAR, although inferior to the conventional technique, has a reasonably acceptable diagnostic value and may be used as an alternative when the placement of intraoral film/sensor is difficult. It has the advantage of a lesser radiation dose and cost-effectiveness in comparison to panoramic radiograph and the ease of being carried out within the clinic itself.

## Financial support and sponsorship

Nil.

## Conflicts of interest

There are no conflicts of interest.

## References

1. Newman ME, Friedman S. Extraoral radiographic technique: An alternative approach. *J Endod* 2003;29:419-21.
2. Chen CH, Lin SH, Chiu HL, Lin YJ, Chen YK, Lin LM, *et al.* An aiming device for an extraoral radiographic technique. *J Endod* 2007;33:758-60.
3. Kumar R, Khambete N, Priya E. Extraoral periapical radiography: An alternative approach to intraoral periapical radiography. *Imaging Sci Dent* 2011;41:161-5.
4. Kumar R, Khambete N. Use of extraoral periapical radiography in Indian population: Technique and case reports. *Indian J Dent Res* 2013;24:271-3.
5. Babu NS, Patel P. Comparative evaluation of extra-oral and intra-oral periapical radiographic technique in children. *Int J Sci Stud* 2015;2:7-12.
6. ICRP, Rehani MM, Gupta R, Bartling S, Sharp GC, Pauwels R, *et al.* Radiological protection in cone beam computed tomography (CBCT). ICRP publication 129. *Ann ICRP* 2015;44:9-127.