



Isolated Mesenteric Injury causing Ileal Devascularisation with Uterine Perforation following Termination of Pregnancy; A Case Report and Literature Review

Dileep Ramesh Hoysal^{1*}, Hemashree K²

¹Dileep Ramesh Hoysal, Assistant Professor, Department of Surgery, BGS GIMS, Bangalore

²Dr Hemashree K, House Surgeon, Department of Surgery, BGS GIMS, Bangalore

***Corresponding author:** Dileep Ramesh Hoysal

Address: Flat no 305, Chirag Residency, 7/2, Mysore road A cross, Opp. Byatarayanapura police station, Bangalore - 560026, Karnataka, India.
Tel: +91-990-1829377
e-mail:dileephoysal@gmail.com

Received: May 18, 2018

Revised: July 7, 2018

Accepted: July 15, 2018

ABSTRACT

Surgical abortion is one of the leading causes of maternal mortality, constituting up to 20% of maternal deaths. Uterine perforation is a rare complication, accounting for 4% of all the abortion related complications. Intestinal injury with uterine perforation following termination of pregnancy is even rare and is a potentially fatal complication with mortality of up to 10%. A 27-year-old G3P2L2 woman with 12 weeks of gestation referred to our hospital in hemorrhagic shock with a suspicion of uterine perforation following dilatation and curettage for termination of pregnancy. Patient underwent emergency laparotomy. She was found to have uterine perforation with mesenteric and ileal injuries intraoperatively. Perforation closure with ileoileal resection and anastomosis was done. Postoperatively the patient recovered completely. Prompt reporting/recognition of uterine perforation, preoperative resuscitation and early intervention are the most important steps in the management of patients with intestinal injury. Trauma surgeon should never hesitate or delay in considering an Emergency Laparotomy/laparoscopy in cases of suspected intestinal injury with uterine perforation. Emergency exploration decreases the morbidity and mortality to a great extent in patients with intestinal injury.

Keywords: Maternal mortality; Mesenteric injury; Unsafe abortion; Uterine perforation; Termination of pregnancy.

Please cite this paper as:

Hoysal DR, Hemashree K. Isolated Mesenteric Injury causing Ileal Devascularisation with Uterine Perforation following Termination of Pregnancy; A Case Report and Literature Review. *Bull Emerg Trauma*. 2018;6(4):376-378. doi: 10.29252/beat-060418.

Introduction

Surgical abortion is one of the commoner outpatient procedure performed in everyday practice [1, 2]. Though considered to be safe, it has a serious complication profile. Uterine perforations are rare

with an incidence of 4% in developing countries [2, 3]. However, studies suggest underestimation and underreporting of uterine perforations [4]. Uterine perforation associated with intestinal injuries, a potentially fatal complication has been reported in the literature in quite a few case reports and review

articles [2]. However, the importance of early intervention in these patients is hardly emphasized in the literature [1]. We herein report a case of isolated mesenteric injury causing ileal devascularisation with uterine perforation and discuss the importance of early surgery in patients with intestinal injury.

Case Report

A 27-year-old woman, gravid 3, para 2 and living 2 presented to our patient clinic with history of 3 months of amenorrhoea with no other significant past medical history, both the deliveries previously were normal vaginal deliveries (NVDs). Ultrasonography at the same visit revealed a single live intrauterine gestation of 12 weeks. About 10 days later, the patient presented to emergency room in hemorrhagic shock state with history of vaginal bleeding since 3 hours following dilatation and curettage at local hospital for termination of pregnancy. Uterine perforation and bowel injury was suspected following the procedure. Vaginal examination revealed bleeding with retained products of conception while abdominal

examination revealed lower abdominal guarding suggesting peritonitis. On presentation, Hemoglobin was 5.8 mg/dL indicating acute hemorrhage. Patient was resuscitated and was transferred to the operating room emergency. Laparotomy revealed isolated transverse mesenteric tear at the mesenteric border of the bowel causing distal ileal devascularisation for a length of 75cm about 50cm from the ileocaecal junction (Figure 1A). Perforation at the fundus (Figure 1B) of uterus measuring 6 cm with retained products of conception and 500mL of hemoperitoneum. After achieving haemostasis from bleeding mesentery, products of conception were evacuated (Figure 2A). Uterine perforation was closed followed by distal ileal resection and ileoileal two layered end to end anastomosis was performed (Figure 2B). Postoperative period was uneventful. The patient recovered well, started on oral diet after 48 hours. No complication was encountered post operatively and hence was discharged. Patient was followed up at first month and is on regular follow up once in three months. No complication was noted till date.

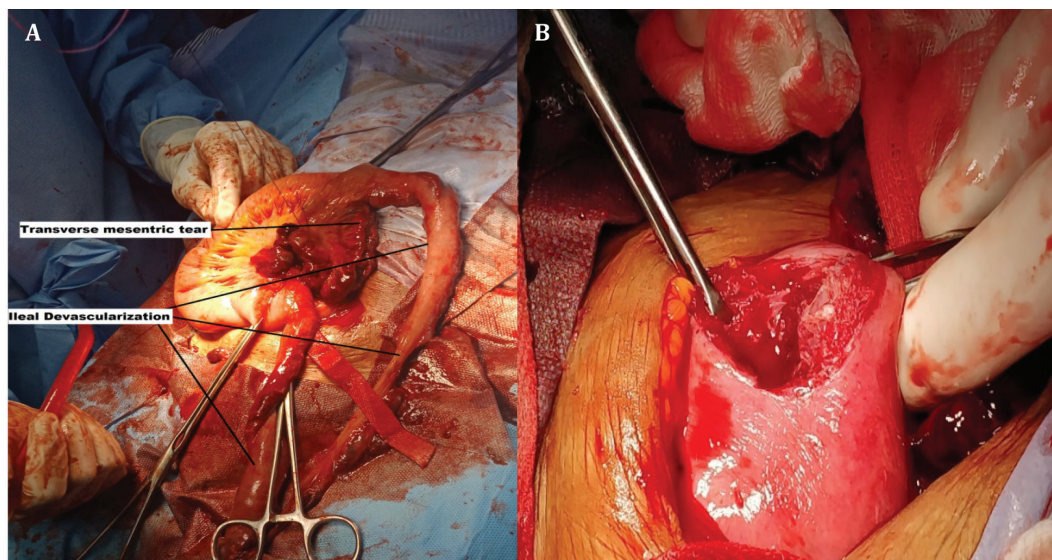


Fig. 1. Intraoperative image of the patient during laparotomy demonstrating mesenteric tear with ileal devascularisation (A); Uterine perforation at the fundus (B).

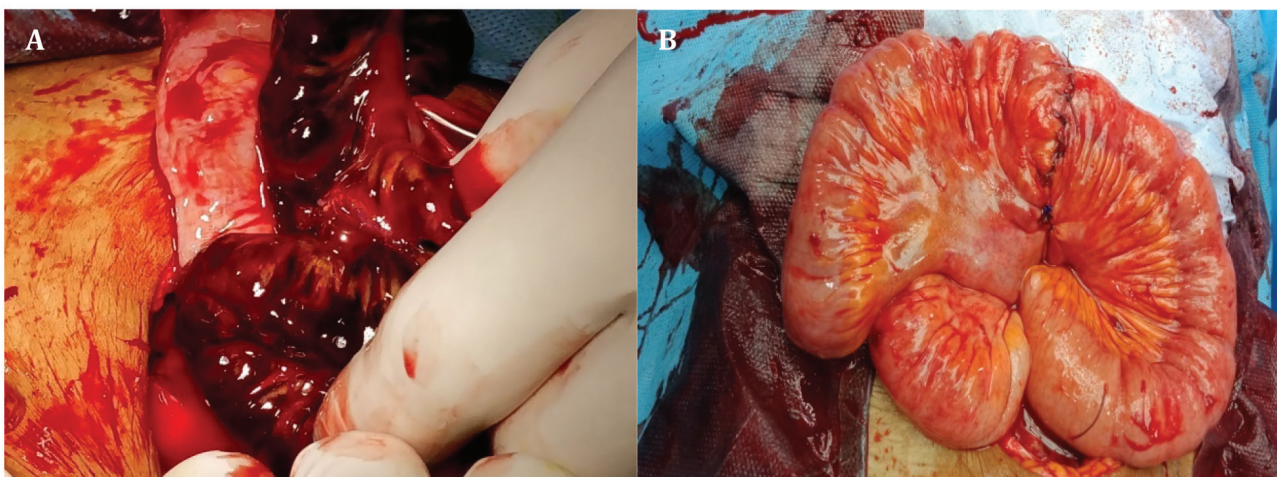


Fig. 2. Intraoperative image demonstrating the products of conception removed from uterus (A); the intraoperative view of the ileoileal end to end anastomosis (B).

Discussion

About 6 million abortions are performed every year in India. Surgical abortion is one of the leading causes of maternal mortality, constituting up to 20% of maternal deaths [5], reflecting the sizeable proportion of impact on the health indices of a developing country like ours. Though abortion is considered to be one of the safer procedures, the reason for higher mortality in majority of cases is because of the fact that a higher percentage of surgical abortions are unsafe abortions done in rural areas under unhygienic conditions because of the sensitivity of the issue due to socio-cultural stigmata and these cases usually present late to the medical establishments. Termination of pregnancy is safe but has serious complication profile and can be fatal. Perforation of uterus though rare, is one of the most frequent complications while performing dilatation and curettage, estimated to be around 0.4 % in developed countries and up to 3.6% in developing countries [2, 6]. Fundus being the most common site of perforation [7], the same was observed in our case.

Intestinal injuries with uterine perforation following abortion are very rarely encountered and are potentially fatal. Shunji Suzuki [8] in his observation estimated Intestinal injury to be around 60% of all the uterine perforations. Bowel injury following abortion can be a direct traumatic perforation, an indirect mesenteric injury leading to devascularisation and herniation and incarceration of intestine through

the uterine perforation [9, 10]. Isolated mesenteric injury without an intestinal injury is extremely rare in its occurrence. Suspicion/recognition of intestinal injury with uterine perforation during termination of pregnancy necessitates emergency exploration either by laparoscopy or laparotomy. Jhobtaet *al.*, [10] documented 82% morbidity in cases with intestinal injuries, most of the patients presented with sepsis (73%) at the time of admission and 82% of the patients underwent ileostomy/colostomy; no peri-operative complication was noted in our case. Early presentation and early intervention in the form of Laparotomy/laparoscopy decreases the morbidity and helps in avoiding bowel exteriorisation procedures and thereby hastening the recovery of the patient.

Intestinal injury with uterine perforation following termination of pregnancy is a rare yet a significant complication influencing the morbidity and mortality of child bearing women. Education and awareness among the people decreases the incidence of unsafe abortions and thereby maternal deaths. Emergency Laparotomy/laparoscopy should never be hesitated or delayed in cases of suspected intestinal injury with uterine perforation. Prompt recognition, preoperative resuscitation and early intervention are the most important steps in the management of patients with intestinal injury. Emergency exploration decreases the morbidity and mortality of such patients.

Conflicts of Interest: None declared.

References

1. Chang HM, Shen CJ, Lin CY, Tsai EM. Uterine perforation and bowel incarceration following surgical abortion during the first trimester. *Taiwan J Obstet Gynecol* 2008; **47**: 448–450.
2. Augustin G, Majerovic M, Luetic T. Uterine perforation as a complication of surgical abortion causing small bowel obstruction: a review. *Arch Gynecol Obstet*. 2013;**288**(2):311-23.
3. Obed SA, Wilson JB. Uterine perforation from induced abortion at Korle Bu Teaching Hospital, Accra, Ghana: a five year review. *West Afr J Med*. 1999;**18**:286–289.
4. Kaali SG, Szigetvari IA, Bartfai GS. The frequency and management of uterine perforations during first-trimester abortions. *Am J Obstet Gynecol*. 1989;**161**(2):406-8.
5. Indian Council of Medical Research. Illegal abortion in rural areas: a task force study. New Delhi, India: ICMR;1989.
6. Amarin ZO, Badria LF. A survey of uterine perforation following dilatation and curettage or evacuation of retained products of conception. *Arch Gynecol Obstet*. 2005;**271**(3):203-6.
7. Ghahramani L, Moslemi S, Tahamtan M, Hashemizadeh MH, Keshavarzi A. Antepartum Uterine Rupture Occurring at the Site of a Previously Repaired Dilatation and Curettage-Induced Perforation: A Case Report. *Bull Emerg Trauma*. 2013;**1**(2):96-8.
8. Suzuki S. Intestinal Injury Associated With Uterine Perforation due to Surgical Abortion in Japan. *Gastroenterology Res*. 2017;**10**(1):63.
9. Jhobta R, Attri A, Jhobta A. Bowel injury following induced abortion. *International Journal of Gynecology & Obstetrics*. 2007;**96**(1):24-7.
10. Kambiss SM, Hibbert ML, Macedonia C, Potter ME. Uterine perforation resulting in bowel infarction: sharp traumatic bowel and mesenteric injury at the time of pregnancy termination. *Mil Med*. 2000;**165**(1):81-2.

Open Access License

All articles published by Bulletin of Emergency And Trauma are fully open access: immediately freely available to read, download and share. Bulletin of Emergency And Trauma articles are published under a Creative Commons license. Mandated authors will be offered CC-BY; all other authors will choose between CC-BY, CC-BY-NC and CC-BY-NC-ND.