

Expert Opinion



Rethinking surgical concepts for early cervical cancer

Hyun-Joo Seol , Jong-Min Lee

Department of Obstetrics and Gynecology, Kyung Hee University Hospital at Gangdong, School of Medicine, Kyung Hee University, Seoul, Korea



Received: Mar 2, 2018

Accepted: Mar 27, 2018

Correspondence to

Jong-Min Lee

Department of Obstetrics and Gynecology,
Kyung Hee University Hospital at Gangdong,
School of Medicine, Kyung Hee University,
892 Dongnam-ro, Gangdong-gu, Seoul 05278,
Korea.

E-mail: kgo02@hanmail.net

Copyright © 2018. Asian Society of
Gynecologic Oncology, Korean Society of
Gynecologic Oncology

This is an Open Access article distributed
under the terms of the Creative Commons
Attribution Non-Commercial License (<https://creativecommons.org/licenses/by-nc/4.0/>)
which permits unrestricted non-commercial
use, distribution, and reproduction in any
medium, provided the original work is properly
cited.

ORCID iDs

Hyun-Joo Seol

<https://orcid.org/0000-0003-0303-7813>

Jong-Min Lee

<https://orcid.org/0000-0002-0562-5443>

Conflict of Interest

No potential conflict of interest relevant to this
article was reported.

Cervical cancer is the fourth most common malignant disease in women worldwide, and accounts for about one-tenth of all cancer deaths in women. Even though the incidence of cervical cancers has decreased as the result of the widespread use of effective screening tests for premalignant lesions, it remains the most common female genital tract malignancy in Korean women.

Radical hysterectomy and pelvic with/without para-aortic lymphadenectomy have been widely accepted as the preferred surgical treatments in patients with early-stage cervical cancers, including those with International Federation of Gynecology and Obstetrics (FIGO) stages IB–IIA. During this procedure, gynecologic oncologists aim to remove malignant lesions in the cervix, with a radial safety margin of 1–2 cm in the vagina and mesometrium. In cases of early cervical cancer where resection margins are very close to the bladder and rectum, most surgeons do not perform resections because of the lack of adequate safety margins. Furthermore, surgeons sometimes confront microscopic parametrial involvement in the final pathology report after radical surgery. Even in cases with histologically confirmed clear resection margins, adjuvant radiation therapy has usually been administered to improve loco-regional control of microscopic parametrial involvement. Unfortunately, this bimodal therapy strategy increases treatment-related morbidity and has uncertain effects on overall survival.

During the last decade, Höckel [1] has made important contributions to these issues based on ontogenetic compartment theory. He suggested that cervical cancer is locally confined to the Müllerian compartments derived from a common primordium during the natural course of embryonic development, over a relatively long phase. Furthermore, tumor progression is isotropic within the Müllerian compartment and suppressed at the compartment borders by the bladder and rectum. Thus, resection of the tumor-bearing compartment at its intact borders, irrespective of margin width, without adjuvant radiation therapy has improved local tumor control, reduced treatment-related morbidity, and enhanced overall survival [1–3]. Ungár et al. [4] also reported that complete excision of the connective tissue of the pelvis in the absence of adjuvant treatment showed excellent oncologic outcomes in patients with FIGO stage IB cervical cancers compared to those who received conventional radical surgery followed by tailored adjuvant treatment.

Author Contributions

Conceptualization: L.J.M.; Formal analysis: L.J.M.; Investigation: L.J.M.; Methodology: L.J.M.; Resources: L.J.M.; Supervision: L.J.M.; Visualization: S.H.J.; Writing - original draft: S.H.J.; Writing - review & editing: S.H.J., L.J.M.

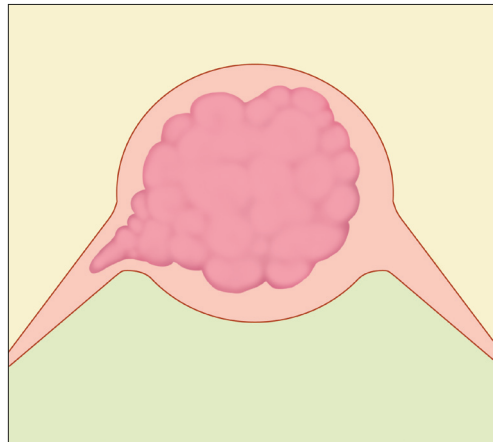


Fig. 1. Schematic diagram of microscopic parametrial involvement.

In order to maximize the therapeutic effect of radical surgery without adjuvant radiation therapy, we should also rethink the extent and assessment of lymph node dissection. Although there have been controversies surrounding the cardinal ligament (lateral parametrium), most gynecologic oncologists agree that it consists of lymph nodes and fatty lymphatic tissues, but not ligamentous tissues [1-3,5-7]. Whereas contiguous tumor invasion into the lateral parametrium is less frequent, tumor emboli in the lymphovascular spaces and lymph node metastases are the main metastatic pathway [5]. The nodes in the mesometrium drain into the presacral nodes [8,9]. To perform thorough lymph node dissection in the common iliac area, we should completely remove the deep common iliac nodes, as well as the superficial common iliac nodes up to the aortic bifurcation, between the lateral aspect of the common iliac vein and the psoas muscle by medializing the common iliac vessels and by exposing the iliolumbar vein and lumbosacral nerve trunk [8].

Recently, we reported the oncologic outcomes of 101 FIGO stage IB–IIA cervical cancer patients who presented with lymph node metastases or combinations of certain risk factors, including large tumor size, deep stromal invasion, and lymphovascular space invasion, after radical hysterectomy and systematic lymph node dissection without adjuvant radiation. Including 7 loco-regional recurrences, the estimated 3-year disease-free survival rate and 5-year overall survival rate were 90.7% and 90.6%, respectively [10]. Additionally, in 7 patients (not included in the analysis because of small number of cases) with microscopic parametrial involvement and close resection margins who did not receive adjuvant radiation, there were no pelvic recurrences and only one distant failure. **Fig. 1** shows the schematic diagram of microscopic parametrial involvement. Based on Höckel's ontogenetic compartment theory, we did not perform adjuvant radiation therapy for patients with microscopic parametrial involvement and close resection margins. In this situation, we hypothesize that narrow safety margins in the anterior and posterior directions of the dorsal parametrium remain in the Müllerian compartment and do not increase the risk of local failure.

Even though adjuvant radiation or chemoradiation therapies have usually been recommended for patients with high risk early cervical cancers after radical surgery, the ontogenetic compartment theory provides valuable new insight into surgical concepts and treatment strategies for gynecologic oncology.

REFERENCES

1. Höckel M. Cancer permeates locally within ontogenetic compartments: clinical evidence and implications for cancer surgery. *Future Oncol* 2012;8:29-36.
[PUBMED](#) | [CROSSREF](#)
2. Höckel M, Horn LC, Fritsch H. Association between the mesenchymal compartment of uterovaginal organogenesis and local tumor spread in stage IB-2B cervical carcinoma: a prospective study. *Lancet Oncol* 2005;6:751-6.
[PUBMED](#) | [CROSSREF](#)
3. Höckel M, Horn LC, Manthey N, Braumann UD, Wolf U, Teichmann G, et al. Resection of the embryologically defined uterovaginal (Müllerian) compartment and pelvic control in patients with cervical cancer: a prospective analysis. *Lancet Oncol* 2009;10:683-92.
[PUBMED](#) | [CROSSREF](#)
4. Ungár L, Pálfalvi L, Tarnai L, Nechushkina V, Lintner B, Novák Z, et al. Surgical treatment of stage IB cervical cancer. *Int J Gynecol Cancer* 2012;22:1597-603.
[PUBMED](#) | [CROSSREF](#)
5. Benedetti-Panici P, Maneschi F, D'Andrea G, Cutillo G, Rabitti C, Congiu M, et al. Early cervical carcinoma: the natural history of lymph node involvement redefined on the basis of thorough parametrectomy and giant section study. *Cancer* 2000;88:2267-74.
[PUBMED](#) | [CROSSREF](#)
6. Touboul C, Fauconnier A, Zareski E, Bouhanna P, Daraï E. The lateral infraureteral parametrium: myth or reality? *Am J Obstet Gynecol* 2008;199:242.e1-6.
[PUBMED](#) | [CROSSREF](#)
7. Querleu D, Cibula D, Abu-Rustum NR. 2017 update on the Querleu-Morrow classification of radical hysterectomy. *Ann Surg Oncol* 2017;24:3406-12.
[PUBMED](#) | [CROSSREF](#)
8. Cibula D, Abu-Rustum NR. Pelvic lymphadenectomy in cervical cancer--surgical anatomy and proposal for a new classification system. *Gynecol Oncol* 2010;116:33-7.
[PUBMED](#) | [CROSSREF](#)
9. Höckel M, Horn LC, Tetsch E, Eienkel J. Pattern analysis of regional spread and therapeutic lymph node dissection in cervical cancer based on ontogenetic anatomy. *Gynecol Oncol* 2012;125:168-74.
[PUBMED](#) | [CROSSREF](#)
10. Lee KB, Kim YS, Lee JM. Oncologic outcomes of adjuvant chemotherapy alone after radical surgery for stage IB-IIA cervical cancer patients. *J Gynecol Oncol* 2018;29:e5.
[PUBMED](#) | [CROSSREF](#)