

# Bidirectional ventricular tachycardia in ischemic cardiomyopathy during ablation



Colin Yeo, MBBS, Martin S. Green, MD, Girish M. Nair, MBBS, FHRS, David H. Birnie, MBChB, Pablo B. Nery, MD, Mouhannad M. Sadek, MD, FHRS

*From the Arrhythmia Service, Division of Cardiology, University of Ottawa Heart Institute, Ottawa, Ontario, Canada.*

## Introduction

Ventricular tachycardia (VT) with alternating morphology is usually associated with intracardiac channelopathies, such as digoxin toxicity and catecholergic polymorphic ventricular tachycardia (CPVT). We describe an unusual case of VT with alternating exits during VT ablation in a patient who is clinically known to have recurrent monomorphic VT.

## Case report

A 78-year-old man presented with recurrent appropriate shocks from his implantable cardioverter-defibrillator (ICD) for monomorphic VT. He was known to have ischemic cardiomyopathy and monomorphic VT for which he had received an ICD 12 years ago. Since then, he had infrequent episodes of VT while taking sotalol that were terminated with antitachycardia pacing. He presented with VT storm and appropriate ICD therapies refractory to intravenous amiodarone and was offered VT ablation. On arrival to the electrophysiology (EP) laboratory, he was in clinical and hemodynamically stable VT (Figure 1, VT1).

The EP procedure was performed using intracardiac echocardiography (SoundStar, Biosense Webster, Diamond Bar, CA) and CartoSound (Biosense Webster), creating an anatomic map of the left ventricle (LV). A bidirectional DF curve SmartTouch surround flow 3.5-mm irrigated ablation catheter (Biosense Webster) was used for mapping and ablation within the LV. A quadripolar diagnostic EP catheter (Response electrophysiology catheter, St. Jude Medical, St. Paul, MN) was placed in the right ventricular apex.

Figure 1 illustrates entrainment with near-concealed fusion (with slight electrocardiographic [ECG] morphological alteration) when pacing from the LV anterior-mid septum. The difference between the postpacing interval and the VT tachycardia cycle length (TCL) was 10 ms. The time from stimulus to surface QRS was 70 ms, equivalent to the time from the local elec-

trogram (EGM) to surface QRS. The stimulus to QRS interval was short, suggesting that the catheter was near the exit site of the VT or with dual capture of both the isthmus and outer loop tissue.<sup>1</sup>

The first radiofrequency (RF #1) application of 30 W was delivered at the site of entrainment (Figure 1). The clinical VT (VT1) terminated after 13 seconds of RF application. We continued for a total of 90 seconds of RF ablation at this site. Shortly after the termination of RF, there was a spontaneous occurrence of a second VT (VT2) of alternating morphology (Figure 2, VT2). We opted not to perform additional mapping of VT2 immediately at the time, but rather perform consolidation lesions at the site of successful ablation of VT1. Another RF application (RF #2) was applied adjacent to the first RF lesion, which resulted in termination of VT2 within 3 seconds of RF ablation.

We then proceeded to perform electroanatomic voltage mapping and ablation of the scar substrate in the LV. No further VTs were inducible on electrophysiologic testing after completion of substrate ablation. The subject had completed 6 months of follow-up without any recurrence of ventricular arrhythmias.

## Discussion

Bidirectional VT (BVT) is a form of VT with a beat-to-beat alteration in the QRS axis on the surface ECG. It is uncommon and usually associated with certain specific conditions, such as CPVT,<sup>2</sup> digoxin toxicity, and long QT syndrome type 7 (Anderesen-Tawil syndrome).<sup>3</sup> It had also been rarely reported in subjects with sarcoidosis<sup>4</sup> and acute coronary syndrome (ACS).<sup>5</sup> To our knowledge, it has never been described in subjects with ischemic cardiomyopathy in the absence of ACS.

In the context of channelopathies, the mechanism has been associated with mutations in the ryanodine receptor 2 of the sarcoplasmic reticulum, resulting in the voltage-dependent L-type Ca<sup>2+</sup> channel remaining open for a longer period of time extending into diastole of cardiac muscle cells. This causes delayed afterdepolarization in phase IV of the action potential, triggering polymorphic VT or BVT. Digoxin is postulated to cause polymorphic VT or BVT in a similar fashion by facilitating the opened state of ryanodine receptor 2. In

**KEYWORDS** Bidirectional ventricular tachycardia; Ablation; Ischemic cardiomyopathy; Entrainment; Multiple exit sites (Heart Rhythm Case Reports 2017;3:527–530)

**Address reprint requests and correspondence:** Dr Mouhannad M. Sadek, The Ottawa Hospital - General Campus, Box 703, 501 Smyth Rd, Ottawa, Ontario, Canada K1H 8L6. E-mail address: [msadek@ottawaheart.ca](mailto:msadek@ottawaheart.ca).

## KEY TEACHING POINTS

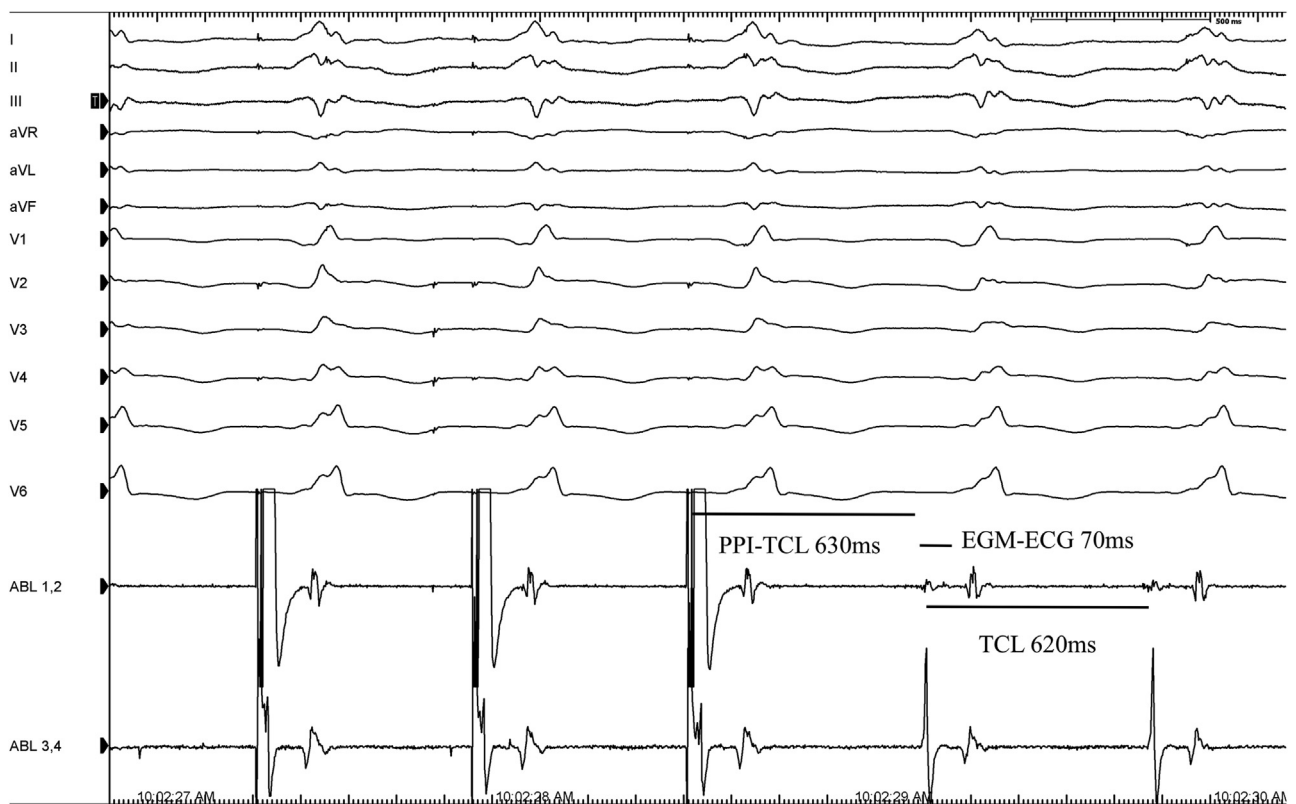
- Entrainment is an invaluable tool to localize the isthmus of scar-mediated reentry ventricular tachycardia (VT), which provides a significantly higher rate of success in termination of VT during ablation.
- Scar-mediated VT may present with VT of various morphologies on the surface electrocardiogram due to the presence of multiple exit sites.
- When a patient presents with de novo VT with alternating morphology on the surface electrocardiogram, scar-mediated reentry VT should be considered as a differential diagnosis and not just assume conditions more commonly associated with bidirectional VT, such as digoxin toxicity and catecholnergic polymorphic ventricular tachycardia.

ischemia, the mechanism is postulated to be a complex combination of neurohumoral and ionic imbalance coupled with an increase in electrical resistance between cardiac myocytes.<sup>6</sup>

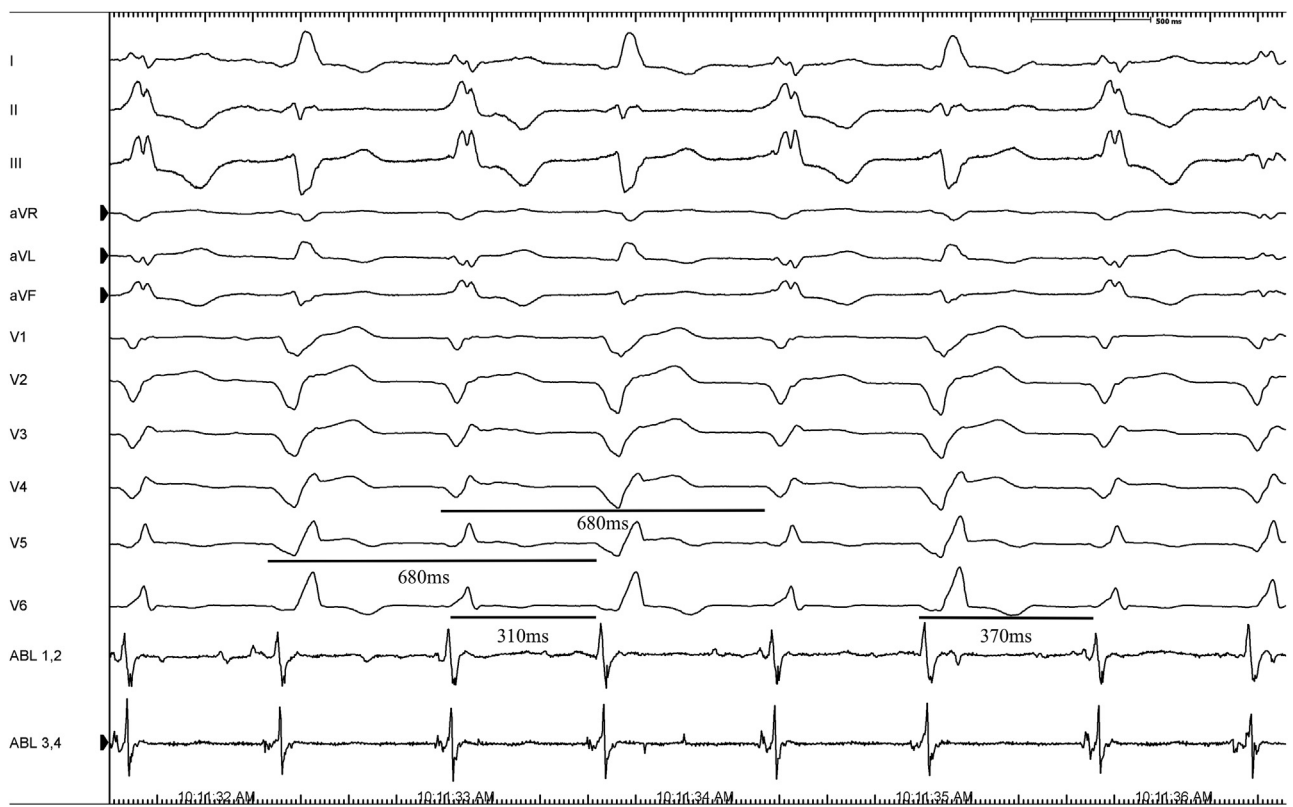In our subject, BVT occurred shortly after ablation was performed at the exit site of a reentrant circuit of a right bundle

branch block monomorphic VT. The exit site of the right bundle branch block morphology VT was localized to the anterior-mid aspect of the interventricular septum. The resultant BVT demonstrated left bundle branch block morphology with alternating superior and inferior axis. BVT exhibited a shorter but regular alternating cycle length (CL) associated with alternating surface morphology on the ECG and near-field EGM on the distal bipole of the ablation catheter (Figure 2, 310 and 370 ms, respectively, but a stable and consistent combined CL of 680 ms). One potential explanation is that BVT uses 2 exit sites in the LV (superior and inferior axis) that are closely related to the site of RF #1. The superior axis exit site having a faster conduction time or shorter circuit, resulting in a shorter TCL (310 ms) as compared with the inferior axis exit site (370 ms). However, both exit sites likely had a long effective refractory period; hence, the wavefront would block every other beat, leading to an exit in the alternative site. VT2 of “bidirectional” morphology must share a common protected isthmus, as there is a consistent combined CL of 680 ms and VT was noninducible post-ablation.

Although VT1 has a longer TCL than does VT2, we postulate that VT1 suppressed the wavefront exit of VT2 via concealed retrograde penetration and collision within the circuit or exit. As the VT1 wavefront exits, it collides with the exit sites of VT2, rendering these exit sites refractory (as illustrated in Figure 3). Hence, the VT1 exit site was preferentially



**Figure 1** Clinical ventricular tachycardia is shown with pacing from the mapping catheter during ventricular tachycardia demonstrating entrainment with near-concealed fusion and measurements demonstrating that the distal bipole of the ablation catheter was near the exit site of a protected isthmus. ECG = electrocardiogram; EGM = electrogram; PPI = postpacing interval; TCL = tachycardia cycle length.



**Figure 2** Second ventricular tachycardia (VT2) that occurred after the first radiofrequency application was delivered. VT2 exhibited a shorter but regular alternating cycle length associated with alternating morphology on the surface electrocardiogram and near-field electrogram.

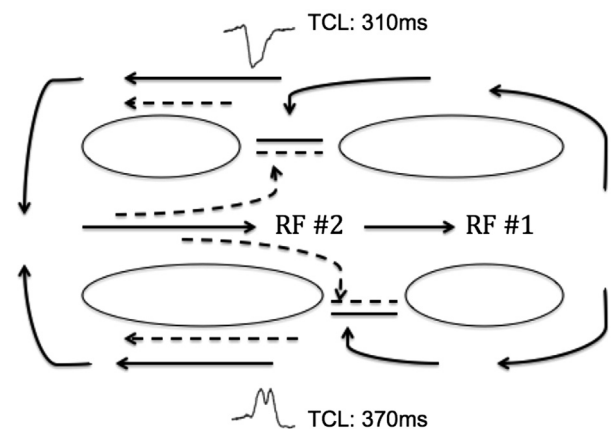
manifesting despite a longer TCL. However, with RF #1 applied in a protected area, the VT1 exit site was blocked and the VT circuit was left with the exit sites for VT2 with no colliding wavefront previously from VT1, leading to the manifestation of VT2. The local EGM of ablation 1–2 in **Figure 2** showed consistent alternating morphologies with each alternating ECG surface morphology during VT2, suggesting alternating wavefronts colliding at the ablation distal bipole, which would be in keeping with multiple exit sites.

As illustrated in **Figure 3**, RF #2 was applied to the common isthmus of VT2, just adjacent to the isthmus of VT1 where RF #1 was applied. This resulted in the block and termination of VT2.

The patient had previously never exhibited BVT until the first RF application was performed. A similar theory of multiple exit sites as the cause of BVT had been previously offered, but in the context of sarcoidosis and angina.<sup>4,7</sup> In the presence of scar-mediated reentry VT, it is common to find VT of multiple morphologies because of multiple exit sites. Ablation within areas of scar with an abnormal local EGM during pace mapping with multiple exit sites had been associated with greater success.<sup>8</sup> This could explain the success with single RF application at this site for VT2.

**Conclusion**

We present an unusual case of BVT in the midst of ablating ischemic VT. To our knowledge, this is the first reported case of this phenomenon in the absence of ACS. It is important to



**Legend:**  
 VT1: —————→  
 VT2: - - - - -→

**Figure 3** Proposed circuit: we postulate that the clinical ventricular tachycardia (VT1) suppressed the wavefront exit of second VT (VT2) via concealed retrograde penetration. By the time VT1 exits, its wavefront (represented by solid arrows) collides and blocks the exit sites for VT2, leading to preferential manifestation of VT1 despite having a longer tachycardia cycle length. When the first radiofrequency (RF #1) at the VT1 exit site resulted in termination, VT2 was able to exit from the superior and inferior exit sites without collision with the antidromic wavefront of VT1. This allowed the manifestation of “bidirectional” VT2 (represented by dashed arrows). Another RF application (RF #2) was applied to the adjacent site to RF #1, the common isthmus of both superior and inferior exit sites for VT2, resulting in the termination of VT2. TCL = tachycardia cycle length.

recognize that when a patient presents with de novo bidirectional VT, we should consider scar-mediated reentry VT and not assume conditions more commonly associated with BVT such as digoxin toxicity and CPVT.

## References

1. Stevenson WG, Khan H, Sager P, Saxon LA, Middlekauff HR, Natterson PD, Wiener I. Identification of reentry circuit sites during catheter mapping and radiofrequency ablation of ventricular tachycardia late after myocardial infarction. *Circulation* 1993;88:1647–1670.
2. Yeo C, Tan VH, Wong KC. Exercise-induced syncope in a 22-year-old man. *Heart* 2017;103:642.
3. Sumitomo N, Shimizu W, Taniguchi K, Hiraoka M. Calcium channel blocker and adenosine triphosphate terminate bidirectional ventricular tachycardia in a patient with Andersen-Tawil syndrome. *Heart Rhythm* 2008;5:498–499.
4. Benjamin MM, Hayes K, Field ME, Scheinman MM, Hoffmayer KS. Bidirectional ventricular tachycardia in cardiac sarcoidosis. *J Arrhythm* 2017;33:69–72.
5. Sonmez O, Gul EE, Duman C, Duzenli MA, Tokac M, Cooper J. Type II bidirectional ventricular tachycardia in a patient with myocardial infarction. *J Electrocardiol* 2009;42:631–632.
6. Wase A, Masood AM, Garikipati NV, Mufti O, Kabir A. Bidirectional ventricular tachycardia with myocardial infarction: a case report with insight on mechanism and treatment. *Indian Heart J* 2014;66:466–469.
7. Siegal D, Quinlan C, Parfrey B, Simpson CS, Redfeam DP, Baranchuk A. Type II bidirectional ventricular tachycardia as a mechanism of termination of sustained ventricular tachycardia. *J Cardiovasc Electrophysiol* 2009;20:345–346.
8. Tung R, Mathuria N, Michowitz Y, Yu R, Buch E, Bradfield J, Mandapati R, Wiener I, Boyle N, Shivkumar K. Functional pace-mapping responses for identification of targets for catheter ablation of scar-mediated ventricular tachycardia. *Circ Arrhythm Electrophysiol* 2012;5:264–272.