

CASE REPORT

OPEN ACCESS

Full open access to this and thousands of other papers at <http://www.la-press.com>.

Transfundal Uterine Incision Performed with Prophylactic Common Iliac Artery Balloon Occlusion for Patient with Placenta Previa Totalis

Yoshihiro Nishida, Tomoko Hirakawa, Yufuko Utsunomiya, Hatsumi Tsusue and Hisashi Narahara

Department of Obstetrics and Gynecology, Faculty of Medicine, Oita University, Oita, Japan.
Corresponding author email: ynishida@oita-u.ac.jp

Abstract: A 37-year-old primigravida at 35 weeks of gestation presented with known anterior wall dominant placenta previa totalis and suspected placenta accreta was successfully treated with transfundal uterine (transverse) incision performed with prophylactic common iliac artery balloon occlusion. This new surgical approach could be an alternative procedure for avoiding excessive blood loss during caesarean delivery.

Keywords: transfundal uterine incision, placenta previa, common iliac artery balloon occlusion

Clinical Medicine Insights: Case Reports 2012:5 93–97

doi: [10.4137/CCRep.S9777](https://doi.org/10.4137/CCRep.S9777)

This article is available from <http://www.la-press.com>.

© the author(s), publisher and licensee Libertas Academica Ltd.

This is an open access article. Unrestricted non-commercial use is permitted provided the original work is properly cited.

Introduction

Caesarean delivery is indicated in patients with placenta previa, especially those with placenta accrete; however, this procedure is occasionally associated with massive bleeding. Obstetricians may find it difficult to perform lower uterine segment transverse incision during caesarean delivery in such patients because it can pose a risk for the mother and fetus while cutting the placental tissue. The use of vertical incision and balloon catheter technique to obstruct blood vessels has been reported to avoid excessive blood loss in patients with placenta previa. However, every method has drawbacks, and a standard surgical consensus has not yet been obtained on these methods. Herein, we report a new method that involves the application of a transverse fundal uterine incision in order to avoid direct invasion of the placenta and subsequent application of a balloon occlusion of the common iliac artery to avoid massive bleeding during the operation. To our knowledge, this is the first report of successful procedure for a patient with placenta previa totalis.

Case

A 37-year-old primigravida, who was diagnosed with a placenta previa totalis, was referred and admitted to our hospital due to threatened premature labor at 33 weeks gestation. She married at 32-year-old and had a history of a hysteroscopic examination for fertility. An initial ultrasonography and MRI image showed that the placenta, which completely covered the internal os, was located mainly on the anterior uterine wall to the level of the maternal umbilicus and suspected placenta accrete located lower posterior uterine wall (Fig. 1). At 35 weeks and 2 days of gestation, because of continuous genital bleeding, cesarean section (transverse fundal uterine incision) assisted temporary balloon occlusion procedure was planned. Both the patient and her family agreed to the possible risk of hysterectomy and blood transfusion, if medically necessary. However, they did not desire subsequent pregnancy. In the operation room, at first, bilateral femoral arteries punctures were performed and 5-Fr vascular sheaths (Terumo Corporation, Tokyo, Japan) were inserted under local anesthesia with subcutaneous injection of lidocaine by radiologist and vascular specialist. Under fluoroscopy guidance, selective catheterization of the bilateral common iliac

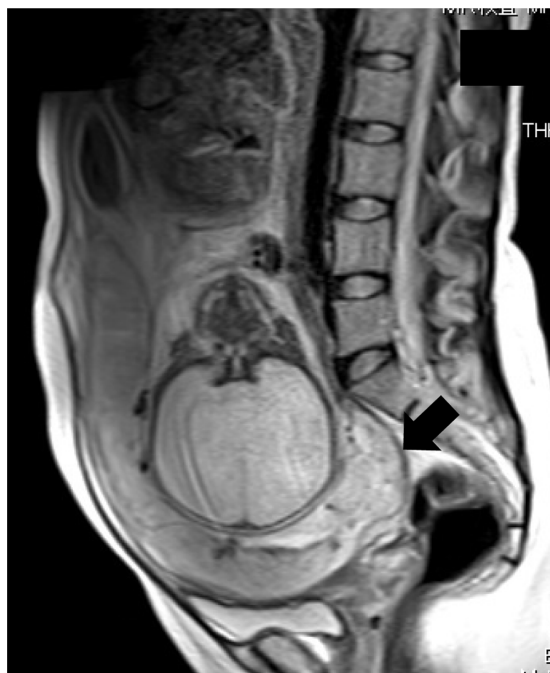

Figure 1. MRI image of the abdomen.

Note: Axial T2-weighted MRI image shows an anterior wall dominant placenta previa totalis and suspected placenta accrete of lower posterior wall (arrow).

arteries was performed using 5-Fr MOIYAN catheters (Miyano Medical, Co, Ltd, Kobe, Japan), with the tips positioned in the proximal parts of the common iliac arteries. This procedure was completed in about 15 minutes. After that, prior to marking incision line (Line A, Fig. 2) guided by ultrasonography, an emergency cesarean section was performed via a transverse fundal uterine incision (Line B, Fig. 2) under general anesthesia. A female infant weighing 3,138 g was born with Apgar scores of 7 and 8 at 1 and 5 min, respectively. Immediately after baby was delivered, bilateral common iliac arteries were occluded by inflation of the balloons through the catheters already in place (Fig. 3). Manual removal of the placenta revealed a moderate adhesion of a lower posterior part of the uterus. Fortunately, removal was performed almost completely without a large amount of blood loss. The operation wound at fundus of the uterus was single sutured almost 1 cm intervals in first layer. The one occluding balloon was deflated before closure of the wound and careful confirmation of hemostasis of bleeding. Interlocked suture was performed in second layer and the other occluding balloon was deflated finally without any abnormal uterine wound and genital bleeding. An adhesion

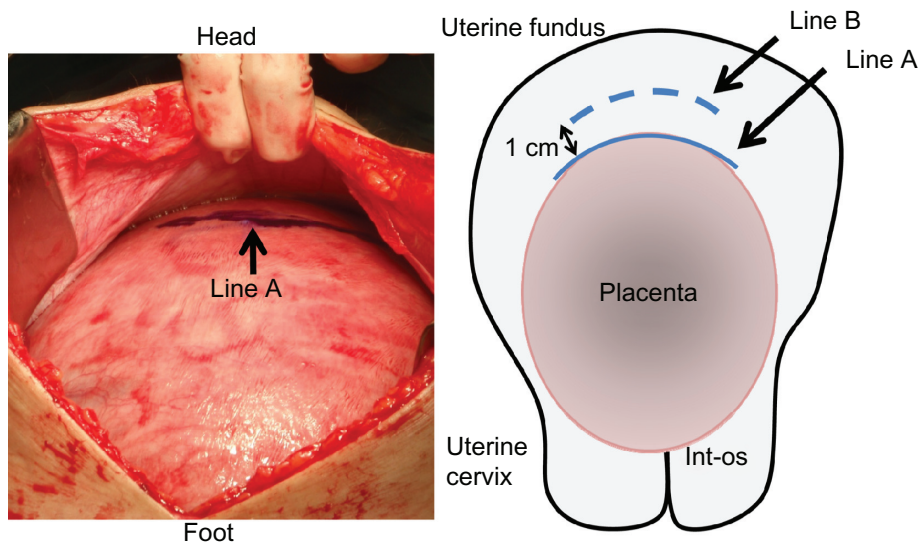


Figure 2. Figure of uterus during operation (left) and schematic model (right).

Notes: Line A shows a marking at edge of placenta guided by ultrasonography. Line B, short dashed line, shows a transverse uterine fundus incision line along line A which part approximately 1 cm.

barrier was used to cover the uterine incision site to reduce the likelihood of bowel adhesions. The total operative time was 67 minutes including preoperative preparing for catheter. The estimated blood loss was about 760-mL and returned 400-mL of autologous blood. The postoperative course was uneventful. The patient was discharged from the hospital on 7th postoperative day without any complication. The MRI

image, which was checked one month after operation, was confirmed almost normal uterus (Fig. 4).

Discussion

Cesarean section is required in all patients with placenta previa totalis. While performing a low-segmental transverse incision in most cases, unavoidable incision of the placenta is difficult, and as a result, massive

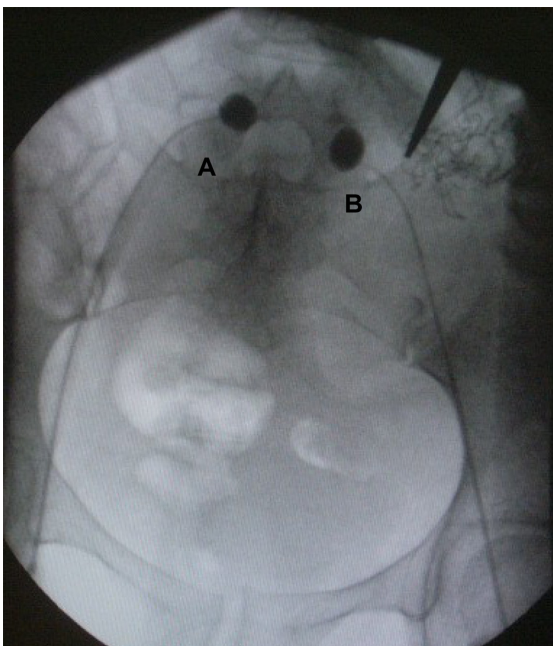


Figure 3. Fluoroscopic shows the endovascular balloons.

Note: Fluoroscopy shows the inflation of the balloons occluded in the common iliac arteries bilaterally (A: right and B: left).

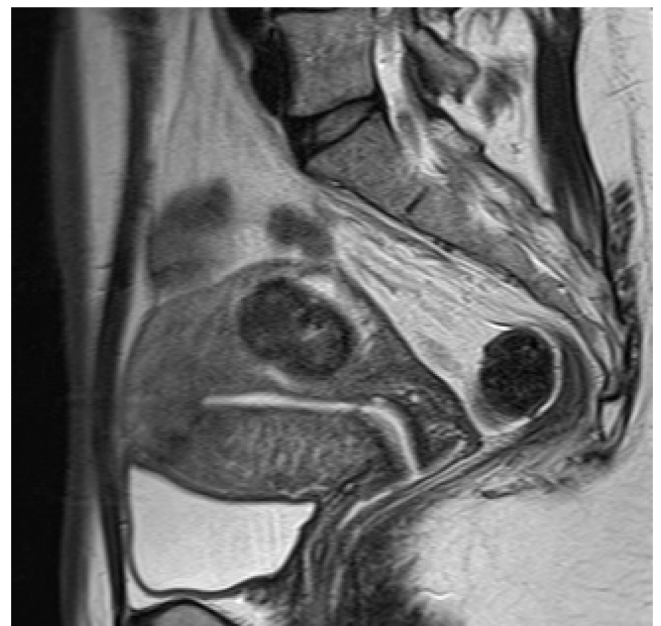

Figure 4. MRI image of the one month after operation.

Note: MRI shows almost normal uterine involution except small myoma located posterior wall.



bleeding would occur, and/or blood transfusion would be required. In case with some difficulty in delivering fetus, a vertical incision (isthmus-cornua) is performed, in addition to the low-segment transverse incision. When there are complications of placenta accrete and/or uncontrolled bleeding from the placental adhesion site would require other hemostatic techniques such as ligation of internal common iliac artery or uterine artery, B-lynch method, several interventional radiology (IVR) and cesarean hysterectomy finally.¹⁻⁴ Due to the development of hemostatics during cesarean section, cesarean hysterectomy in recent years has been reported to have declined.⁵ Recently, with the rising incidence of caesarean sections, the numbers of cases of placenta previa accreta and its complications is continuing to increase. Lone et al reported that hemostatic procedure past 10 years selected balloon tamponade (59%) and B-Lynch suture (48%), respectively.⁶ However, the technique of the uterine incision during cesarean section has rarely been reported. Shukunami et al. have reported a unique approach to a patient with placenta increta performing transverse fundal uterine incision, a large amount of blood transfusion was required.⁷

In this case, we performed new treatment procedures under the cooperation with anesthesiologist, interventional radiologist, pediatrician and para-medical staff. While it requires assessment of next pregnancy, our surgical technique and IVR would provide the patient for some benefits including avoidance of blood transfusion, safety of operation, security with controlled bleeding by IVR, and uterine preservation. Even if the placentation was just a previa not an accreta, IVR prior to a cesarean delivery can minimize the blood flow, consequently the amount of bleeding and subsequent maternal morbidity might be reduced.¹ Our procedure gave satisfactory results with no blood transfusion requirement under stable intraoperative conditions. In addition, a short operative time with early removal of the endovascular catheters also minimize the risk of vascular complications such as serious thrombosis. However, it is apparent that it would be hard to convince most practicing obstetricians to have balloon catheters placed in all cases of previa alone. Another problem is that there are reports that the transfundal incision is a risk for uterine rupture prior to labor in a subsequent pregnancy. Further investigation is necessary but for patients who do not desire another pregnancy it might be a useful

option that cesarean section is performed with transfundal uterine incision under the control of prophylactic common iliac artery balloon occlusion for patients with placenta previa and suspected placenta accreta strongly.

Author Contributions

Conceived and designed the experiments: YN. Analysed the data: YN. Wrote the first draft of the manuscript: YN. Contributed to the writing of the manuscript: YN, TH, YU, HT, HN. Agree with manuscript results and conclusions: YN, HN. Made critical revisions and approved final version: YN. All authors reviewed and approved of the final manuscript.

Funding

Author(s) disclose no funding sources.

Competing Interests

Author(s) disclose no potential conflicts of interest.

Disclosures and Ethics

As a requirement of publication author(s) have provided to the publisher signed confirmation of compliance with legal and ethical obligations including but not limited to the following: authorship and contribution, conflicts of interest, privacy and confidentiality and (where applicable) protection of human and animal research subjects. The authors have read and confirmed their agreement with the ICMJE authorship and conflict of interest criteria. The authors have also confirmed that this article is unique and not under consideration or published in any other publication, and that they have permission from rights holders to reproduce any copyrighted material. Any disclosures are made in this section. The external blind peer reviewers report no conflicts of interest.

References

1. Yi KW, Oh MJ, Seo TS, So KA, Paek YC, Kim HJ. Prophylactic hypogastric artery ballooning in a patient with complete placenta previa and increta. *J Korean Med Sci.* 2010;25(4):651–5.
2. Mallappa Saroja CS, Nankani A, El-Hamamy E. Uterine compression sutures, an update: review of efficacy, safety and complications of B-Lynch suture and other uterine compression techniques for postpartum haemorrhage. *Arch Gynecol Obstet.* 2010;281:581–8.
3. Porreco RP, Stettler RW. Surgical remedies for postpartum hemorrhage. *Clin Obstet Gynecol.* 2010;53:182–95.
4. Bonder LJ, Noshier JL, Gribbin C, Siegel RL, Beale S, Scorza W. Balloon-assisted occlusion of the internal iliac arteries in patients with placenta accreta/percreta. *Cardiovasc Intervent Radiol.* 2006;29:354–61.



5. Shellhaas CS, Gilbert S, Landon MB. The frequency and complication rates of hysterectomy accompanying cesarean delivery. *Obstet Gynecol.* 2009;114:224–9.
6. Lone F, Sultan AH, Thakar R, Beggs A. Risk factors and management patterns for emergency obstetrics hysterectomy over 2 decades. *Int J Gynecol Obstet.* 2010;109:12–5.
7. Shukunami K, Hattori K, Nishijima K, Kotsuji F. Transverse fundal uterine incision in a patient with placenta increta. *J Maternal-Fetal Neon Med.* 2004;16:335–6.