

# Management of cardiac involvement in muscular dystrophies: paediatric versus adult forms

ALBERTO PALLADINO<sup>1</sup>, PAOLA D'AMBROSIO<sup>1</sup>, ANDREA ANTONIO PAPA<sup>1,2</sup>, ROBERTA PETILLO<sup>1</sup>, CHIARA ORSINI<sup>1</sup>, MARIANNA SCUTIFERO<sup>1</sup>, GERARDO NIGRO<sup>2</sup> AND LUISA POLITANO<sup>1</sup>

<sup>1</sup> *Cardiomyology and Medical Genetics, Department of Experimental Medicine;*

<sup>2</sup> *Arrhythmologic Unit, Department of Cardiology, University of Campania "Luigi Vanvitelli", Naples, Italy*

**Muscular dystrophies are a group of genetic disorders characterized by muscle degeneration and consequent substitution by fat and fibrous tissue. Cardiac involvement is an almost constant feature in a great part of these diseases, as both primary myocardial involvement and secondary involvement due to respiratory insufficiency, pulmonary hypertension or reduced mobility. Primary myocardial involvement usually begins more precociously compared to the secondary involvement. In fact the first signs of cardiomyopathy can be observed in the first decade of life in muscular dystrophies with childhood onset and later in adult form of muscular dystrophies as myotonic dystrophy type 1.**

**At least an annual cardiac follow-up is recommended in these patients including clinical and instrumental examination (ECG, 24h Holter monitoring, ECHO), to detect cardiac involvement. A more frequent monitoring may be required according to the type of cardiomyopathy and the patient's needs.**

**In this short review practical guide-lines are shown for physicians routinely involved in the management of these patients.**

**Key words:** muscular dystrophies, cardiomyopathy, DMD, BMD, Steinert Disease, EDMD

## Introduction

Muscular dystrophies are a group of genetic disorders characterized by muscle degeneration and consequent substitution by fat and fibrous tissue. Several forms have been described on the basis of pattern of inheritance (autosomal dominant, autosomal recessive, X-linked), age of onset (childhood or adulthood), involvement of specific muscle groups and more recently on protein deficiency.

Cardiac involvement is an almost constant feature in

a great part of these diseases, as both primary myocardial involvement and secondary involvement due to respiratory insufficiency, pulmonary hypertension or reduced mobility.

In this short review, we will show few examples of cardiomyopathy occurring in infantile or adult forms of muscular dystrophies, underlying that usually the myocardial disease manifesting as cardiomyopathy and congestive heart failure is characteristic of dystrophinopathies and some types of sarcoglycanopathies - gamma and delta-sarcoglycanopathies in particular. Conversely, abnormalities in the conduction system causing heart blocks, arrhythmias, and sudden cardiac death are more commonly seen in Myotonic Dystrophy type 1 (DM1), Emery-Dreifuss muscular dystrophies (EDMD), Limb-Girdle Muscular Dystrophy 1B (LGMD1B) and less frequently in Facio-Scapulo-Humeral-dystrophy (FSHD).

## Heart involvement in infantile forms of muscular dystrophies

Cardiomyopathy in muscular dystrophies is generally the result of the same mutational event that leads to the onset of skeletal muscle involvement (1, 2). A paradigmatic example of this kind of myocardial involvement, is the cardiomyopathy observed in patients with dystrophinopathies, due to mutations in the dystrophin gene (3-10). It usually starts early in life, in an asymptomatic manner detectable by instrumental investigation (the presymptomatic stage) (11). The lack of dystrophin at the myocardium level causes the apoptosis and fibrotic changing of isolated cardiomyocytes (stage of focal fibrosis), often

inducing phenomena of compensatory hypertrophy of the surrounding cardiomyocytes or the onset of arrhythmias (12, 13). The confluence of these areas of fibrosis leads to a picture of diffuse fibrosis (diffuse fibrosis stage) that preludes to the dilation of the heart chambers (dilated cardiomyopathy stage), with a reduced ejection fraction (EF) (14). Dilated cardiomyopathy in turn evolves toward the stage of heart failure (HF) characterized by dyspnoea, peripheral edemas and liver enlargement (15). To be noted that the first episodes of HF are usually responsive to standard pharmacological treatment; however, recurrent episodes of HF lead to the stage of intractable or irreversible heart failure (16, 17).

In patients with Duchenne muscular dystrophy (DMD, OMIM 310200), the age of onset of cardiomyopathy is usually in the first decade of life, and it can be recognized in 25% of DMD patients aged 6 years through instrumental investigations (3, 7, 8, 14-18). With the age the cardiomyopathy progresses from the asymptomatic stage to the overt cardiac involvement involving about 80-85% of patients at the age of 18 (3).

Cardiomyopathy in Becker muscular dystrophy (BMD) is characterized by qualitative and/or quantitative anomalies of dystrophin at the myocardium level, similar to those found at the skeletal muscle level. BMD patients manifest signs and symptoms of cardiomyopathy in a late period of their life, usually in the third- fourth decade, but onset before 20 years is also observed (19). Cardiomyopathy may be the presenting symptom of dystrophinopathy (20). Interestingly patients with BMD seem to pay a more favorable evolution of myopathy with a more severe picture of cardiac involvement, likely due to the an increased request to a heart defective in dystrophin by a prolonged ambulation (4, 5).

## Diagnosis

The diagnosis of cardiomyopathy in dystrophinopathic patients is based on cardiological examination and the use of ECG, Holter monitoring and echocardiography (7, 8, 14, 15). The follow-up can benefit of periodical cardiac evaluations – at least once a year – starting from the age of the diagnosis of the underlying myopathy or from the time of the cardiac diagnosis. More frequent examinations and supplemental investigations such as cardiac magnetic resonance imaging (MRI) study, cardiac scintiscan, electrophysiological study (EPS) may be necessary according to the stage of cardiomyopathy and the patient's needs (21-28).

## Management

The pharmacological treatment of dystrophinopathic cardiomyopathy relies on the use of ACE-inhib-

itors (29-33), beta-blockers (34-37), combined with the steroid treatment (prednisone in the USA and deflazacort in Europe, Canada and Australia) currently considered as the gold standard for Duchenne muscular dystrophy (38-45). There is an almost unanimous consensus that the treatment with steroids is able to delay the onset of dystrophinopathic cardiomyopathy (17, 46, 47).

In case of dilated cardiomyopathy and/or heart failure, digitalis, diuretics (furosemide) and anticoagulants (48-50) are indicated without forgetting a careful monitoring of electrolytes (K<sup>+</sup>, Mg<sup>++</sup>, Na<sup>+</sup>) balance (Fig. 1).

A similar pattern and evolution of cardiomyopathy can be observed in other infantile forms of muscular dystrophy such as gamma (LGMD2C, OMIM 253700) and delta (LGMD2F, OMIM 601287) sarcoglycanopathies and merosinopathy (CMD1C, OMIM 601493); therefore these pathologies can benefit of the same cardiological protocol of diagnosis, follow-up and treatment (16).

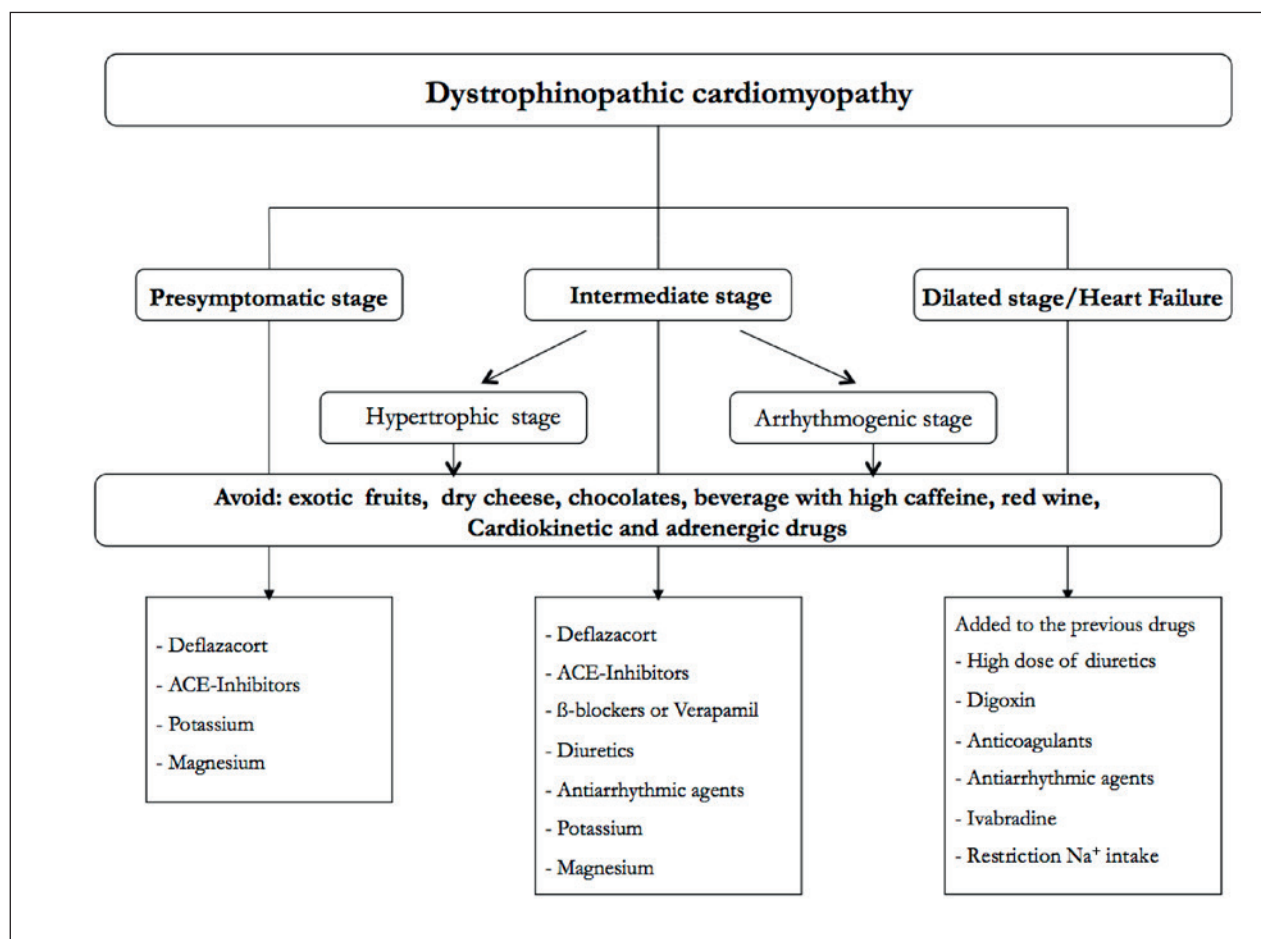
In the final stages of dystrophinopathic cardiomyopathy, where the refractory or intractable heart failure picture dominates, the use of ventricular devices such as Jarvic 2000 may ameliorate the clinical course of cardiomyopathy and prolong the life expectancy of these patients for which cardiac transplantation remains still unaccessible (51-54). Further information can be found in reference 17.

## Heart involvement in adult forms of muscular dystrophies

The most frequent forms of adult muscular dystrophies presenting heart involvement are Myotonic Dystrophy type 1 (DM1, OMIM 160900) or Steinert Disease, Emery-Dreifuss Muscular Dystrophies (EDMDs, OMIM 310300; 150330), Desminopathies (DES, OMIM 125660) and Facio-scapulo-humeral dystrophy (FSHD, OMIM 158900).

All these forms share a prevalent involvement of cardiac conduction tissue that leads to the onset of brady or tachy-arrhythmias. These dystrophies are characterized by the presence of increasing degrees of atrio-ventricular (A-V) blocks, ranging from the first degree in which a prolonged PR interval is observed to the complete A-V block and cardiac arrest, caused by the onset of atrial fibrillation/flutter or ventricular tachycardia/fibrillation.

DM1 is the most frequent muscular dystrophy in adults with a prevalence of 1:8000 individuals. Arrhythmias, often manifesting with the dramatic event of the sudden cardiac death (SCD), occur in about 40-60% of cases (55-60). The onset of arrhythmias is unrelated to the age of the patients and the size of the triplets expansion (61-63). Dilated cardiomyopathy is rare and usually limited to the final stages of the disease.



**Figure 1.** Pharmacological treatment of dystrophinopathic cardiomyopathy.

A dedicated cardiac protocol (64) has been developed to prevent the risk of SCD in these patients and includes periodical investigations such as the cardiological examination, ECG, ECG Holter monitoring and echocardiogram to be performed at least every six months (Fig. 2). If during the follow-up increasing degrees of A-V block or pauses > 2,5 sec on Holter monitoring are observed, an EPS is required to evaluate the needs of a device implantation. In our experience, the adoption of this protocol on 247 DM1 patients in the last 15 years resulted in only 2 cases (8 %) of SCD, at the beginning of the study. A family history positive for SCD is also a major criterion for a device implantation (65).

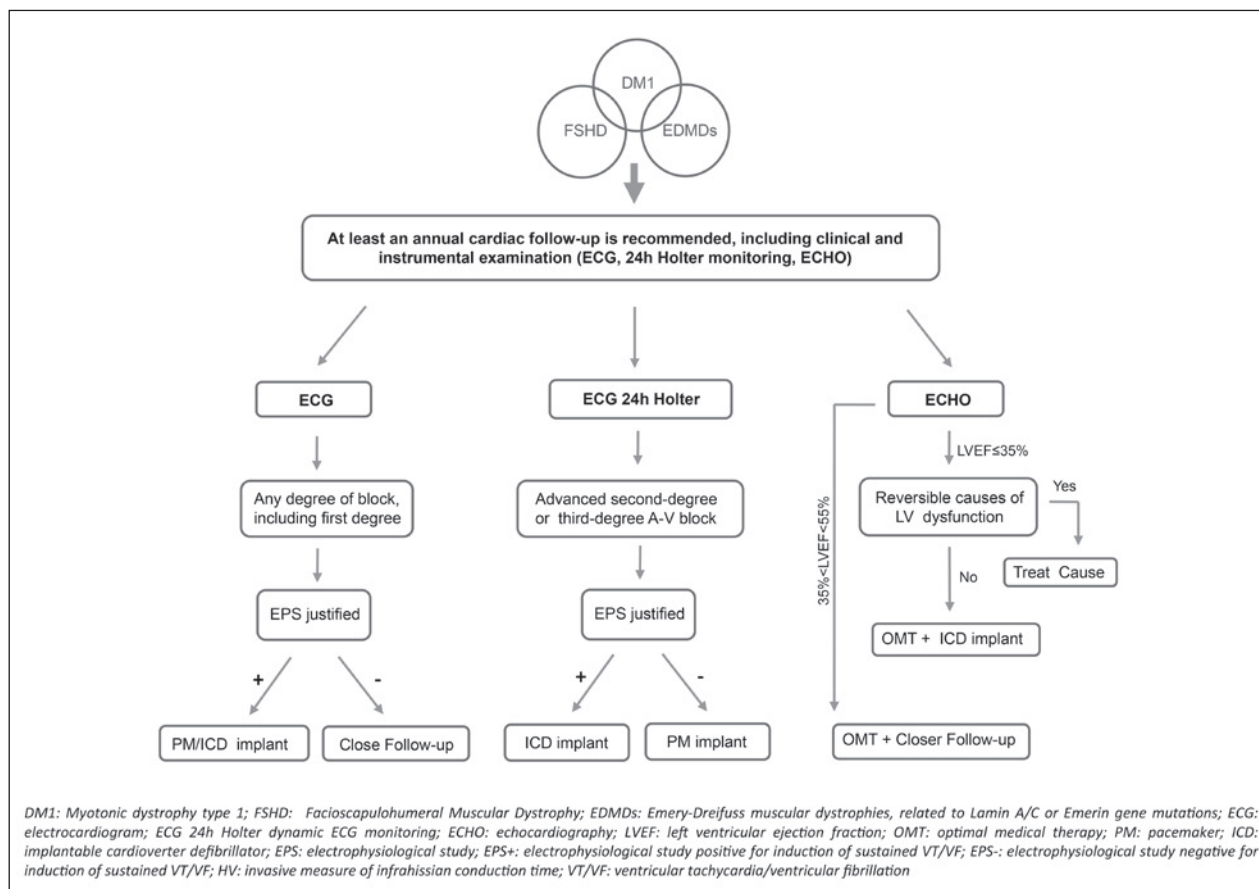
It is important to remember that a high number of SCD has been reported in the past in patients with DM1 despite a pacemaker implantation (66). As a consequence, there is an almost unanimous consensus that in these patients the implant of an ICD should be considered as the first choice (67).

A similar protocol can also be applied in patients with Emery-Dreifuss Muscular Dystrophies caused by

both emerin (X-linked form) or lamin A/C (Autosomal Dominant or Recessive forms) gene mutations (68-73). However, while in patients with emerinopathy the atrial fibrillation represents one of the triad elements characterizing the phenotype (74), in patients with laminopathy the device implantation may precede of many years the time of the diagnosis. Furthermore in these patients the muscle involvement can be minimal or even absent, further diverting attention from a proper diagnosis. Sudden cardiac death may frequently occur in laminopathic patients (75, 76).

There is no consensus concerning the optimal time to implant a device in these patients, as some clinicians suggest to be aggressive and implant at the time of the molecular diagnosis, while others prefer a periodical follow-up taking into account the criteria adopted for patients with DM1 (66, 76).

Facioscapulohumeral muscular dystrophy (FSHD) is one of the most prevalent inherited neuromuscular disorders (77), having significant intra- and interfamilial variability in disease presentation, progression and age



**Figure 2.** Cardiac follow-up and management of the most common adult forms of muscular dystrophies.

of onset, with most individuals becoming symptomatic in their second decade (78-81). Patients with childhood onset (i.e. infantile FSHD) have a more severe clinical presentation (78). Juvenile or adult onset male patients are more severely affected than females (80). The disease is characterized by progressive weakness and atrophy of muscles of the face and shoulder girdle, further extending to the proximal arms and legs (77). Non-muscular manifestations of the disease include sensorineural deafness and retinal vasculopathy (82, 83) as well as central nervous system alterations in some severely affected children (84).

Subjects with FSHD generally do not suffer from significant cardiac symptoms (85-87). Studies reported to date indicate that heart alterations unrelated to cardiomyopathy are possible in FSHD, especially in patients older than 45 years (88).

However in the last years some articles appeared showing that a few percentage of FSHD patients may present atrial involvement with episodes of atrial fibrillation/flutter (85, 89). The protocol adopted in these patients includes a cardiological examination, an ECG and

a echocardiogram to be performed once at year; more frequently checks – every six month or more – are recommended in the case of arrhythmias.

## Management

The pharmacological treatment of patients with a prevalent involvement of the cardiac tissue conduction relies on the use of ACE-inhibitors and appropriate anti-arrhythmic drugs.

In case of atrial arrhythmias it is indicated to prefer drugs as anti-arrhythmics (flecainide, propafenone) and beta-blockers. Amiodarone should be limited to patients not responders to the previous drugs, taking in mind that we are faced with young patients, a long-term therapy, and a high risk of negative effects on the thyroid and pulmonary function (90).

The anti-coagulant therapy – either with the classic warfarin or with the modern class of drugs – is indicated in patients who are implanted to avoid the onset of thrombo-embolic events. In all patients the monitoring of the electrolytes – sodium, potassium and magnesium –

is particularly recommended as the electrolyte imbalance can favor the onset of arrhythmias.

Invasive cardiac treatment should follow the guidelines shown in Figure 1.

## References

- Nigro G, Comi LI, Politano L, et al. Cardiomyopathies associated with muscular dystrophies. In: Engel AG and Franzini-Armstrong C (Eds.). *Myology*. New York: McGraw-Hill 2004:1239-56.
- Sano T, Wada M, Kagawa N. Pathology of the heart in muscular dystrophy. *Shinkei Naika (Neurological Medicine)* 2005;62:547-52.
- Nigro G, Comi LI, Politano L, Bain RJI. The incidence and evolution of cardiomyopathy in Duchenne muscular dystrophy. *Intern J Cardiol* 1990;26:271-7.
- Nigro G, Comi LI, Politano L, et al. Evaluation of the cardiomyopathy in Becker muscular dystrophy. *Muscle Nerve* 1995;18:283-91.
- Hoogerwaard EM, de Voogt WG, Wilde AA, et al. Evolution of cardiac abnormalities in Becker muscular dystrophy over a 13-year period. *J Neurol* 1997;244:657-63.
- Kaspar RW, Allen HD, Ray WC, et al. Analysis of dystrophin deletion mutations predicts age of cardiomyopathy onset in Becker muscular dystrophy. *Circ Cardiovasc Genet* 2009;2:544-51.
- Manning GW, Cropp GJ. The electrocardiogram in progressive muscular dystrophy. *Br Heart J* 1958; 3: 416-20.
- Perloff JK, Roberts WC, de Leon AC, et al. Distinctive electrocardiography of Duchenne's progressive muscular dystrophy: an electrocardiographic-pathologic correlative study. *Am J Med* 1967;42:179-88.
- Barp A, Bello L, Politano L, et al. Genetic modifiers of duchenne muscular dystrophy and dilated cardiomyopathy. *PLoS One* 2015;10:e0141240; doi:10.1371/journal.pone.0141240.
- Bello L, Piva L, Barp A, et al. Importance of SPP1 genotype as a covariate in clinical trials in Duchenne muscular dystrophy. *Neurology* 2012;79:159-62.
- Stearse SE, Dubowitz V, Benatar A. Subclinical cardiomyopathy in Becker muscular dystrophy. *Br Heart J* 1992;68:304-8.
- Miyoshi K. Echocardiographic evaluation of fibrous replacement in the myocardium of patients with Duchenne muscular dystrophy. *Br Heart J* 1991;66:452-5.
- Mertens L, Ganame J, Claus P, et al. Early regional myocardial dysfunction in young patients with Duchenne muscular dystrophy. *Am Soc Echocardiogr* 2008;21:1049-54.
- Kovick RB, Fogelman AM, Abbasi AD, et al. Echocardiographic evaluation of posterior left ventricular wall motion in muscular dystrophy. *Circulation* 1975;52:447-54.
- Ahmad M, Sanderson JE, Dubowitz V, et al. Echocardiographic assessment of left ventricular function in Duchenne's muscular dystrophy. *Br Heart J* 1978;40:734-40.
- Elliott P. Diagnosis and management of dilated cardiomyopathy. *Heart* 2000;84:106-12.
- Politano L, Nigro G. Managing dystrophinopathic cardiomyopathy. expert opinion in orphan drugs. 2016. Doi: 10.1080/21678707.2016.1234373.
- Nigro G, Comi LI, Politano L, et al. Electrocardiographic evaluation of P-type stage of dystrophic cardiomyopathy. *Cardiomyology* 1984;3:45-58.
- Melacini P, Fanin M, Danieli GA, et al. Cardiac involvement in Becker muscular dystrophy. *J Am Coll Cardiol* 1993;22:1927-34.
- Finsterer J, Stollberger C. Cardiac involvement in Becker muscular dystrophy. *Can J Cardiol* 2008;24:786-92.
- Chiang DY, Allen HD, Kim JJ, et al. Relation of cardiac dysfunction to rhythm abnormalities in patients with Duchenne or Becker muscular dystrophies. *Am J Cardiol* 2016;117:1349-54.
- Villa CR, Czosek RJ, Ahmed H, et al. Ambulatory monitoring and arrhythmic outcomes in pediatric and adolescent patients with duchenne muscular dystrophy. *J Am Heart Assoc* 2015;5; doi:10.1161/JAHA.115.002620.
- Fauchier L, Babuty D, Pellicieux S, et al. Conduction defects and arrhythmias in peripheral myopathies. *Arch Mal Coeur Vaiss* 2004; 97:25-33.
- Fayssol A, Nardi O, Orlikowski D, et al. Cardiac asynchrony in Duchenne muscular dystrophy. *J Clin Monit Comput* 2013; 27:587-9.
- Dittrich S, Tuerk M, Haaker G, et al. Cardiomyopathy in Duchenne muscular dystrophy: current value of clinical, electrophysiological and imaging findings in children and teenagers. *Klin Padiatr* 2015; 227:225-31.
- Ducceschi V, Nigro G, Sarubbi B, et al. Autonomic nervous system imbalance and left ventricular systolic dysfunction as potential candidates for arrhythmogenesis in Becker muscular dystrophy. *Int J Cardiol* 1997;59:275-9.
- Politano L, Palladino A, Nigro G, et al. Usefulness of heart rate variability as a predictor of sudden cardiac death in muscular dystrophies. *Acta Myol* 2008;27:114-22.
- Ammendola E, Russo V, Politano L, et al. Is heart rate variability a valid parameter to predict sudden death in patients with Becker's muscular dystrophy? *Heart* 2006 92:1686-7.
- Ramaciotti C, Heinstein LC, Coursey M, et al. Left ventricular function and response to enalapril in patients with Duchenne muscular dystrophy during the second decade of life. *Am J Cardiol* 2006;98:825-7.
- Duboc D, Meune C, Pierre B, et al. Perindopril preventive treatment on mortality in Duchenne muscular dystrophy: 10 years' follow-up. *Am Heart J* 2007;154:596-602.
- Goemans N, Buyse G. Current treatment and management of dystrophinopathies. *Curr Treat Options Neurol* 2014;16:287-99.
- Finsterer J, Cripe L. Treatment of dystrophin cardiomyopathies. *Nat Rev Cardiol* 2014;11:168-79.
- Viollet L, Thrush PT, Flanigan KM, et al. Effects of angiotensin-converting enzyme inhibitors and/or beta blocker on the cardiomyopathy in Duchenne muscular dystrophy. *Am J Cardiol* 2012;110: 98-102.
- Kajimoto H, Ishigaki K, Okumura K, et al. Beta-blocker therapy for cardiac dysfunction in patients with muscular dystrophy. *Cir J* 2006;70:991-4.
- Rhodes J, Margossian R, Darras BT, et al. Safety and efficacy of carvedilol therapy for patients with dilated cardiomyopathy secondary to muscular dystrophy. *Pediatr Cardiol* 2008;29:343-51.
- Frankenberger O, Steinberg JS. Beta blockers and amiodarone for the primary prevention of sudden cardiac death. *Curr Cardiol Rep* 1999;1:274-81.
- Viollet L, Ogata H, Ishikawa Y, et al. Beneficial effects of beta-blockers and angiotensin-converting enzyme inhibitors in Duchenne muscular dystrophy. *J Cardiol* 2009;53:72-8.
- Silversides CK, Webb GD, Harris VA, et al. Effects of deflazacort on left ventricular function in patients with Duchenne muscular dystrophy. *Am J Cardiol* 2003;91:769-72.

39. Markham LW, Spicer RL, Khoury PR, et al. Steroid therapy and cardiac function in Duchenne muscular dystrophy. *Pediatr Cardiol* 2005;26:768-71.
40. Markham LW, Kinnett K, Wong BL, et al. Corticosteroid treatment retards development of ventricular dysfunction in Duchenne muscular dystrophy. *Neuromuscul Disord* 2008;18:365-70.
41. Politano L, Nigro G. Treatment of dystrophinopathic cardiomyopathy: review of the literature and personal results. *Acta Myol* 2012;31:24-30.
42. Barber BJ, Andrews JG, Lu Z, et al. Oral corticosteroids and onset of cardiomyopathy in Duchenne muscular dystrophy. *J Pediatr* 2013;163: 1080-4.e1.
43. Schram G, Fournier A, Leduc H, et al. All-cause mortality and cardiovascular outcomes with prophylactic steroid therapy in Duchenne muscular dystrophy. *J Am Coll Cardiol* 2013;61:948-54.
44. Markham LW, Kinnett K, Wong BL, et al. Corticosteroid treatment retards development of ventricular dysfunction in Duchenne muscular dystrophy. *Neuromuscul Disord* 2008;18:365-70.
45. Dec GW. Steroid therapy effectively delays Duchenne's cardiomyopathy. *J Am Coll Cardiol* 2013;61:955-6.
46. Eagle M, Baudouin SV, Chandler C, et al. Survival in Duchenne muscular dystrophy: improvements in life expectancy since 1967 and the impact of home nocturnal ventilation. *Neuromuscul Disord* 2002;12:926-9.
47. Passamano L, Taglia A, Palladino A, et al. Improvement of survival in Duchenne muscular dystrophy: retrospective analysis of 835 patients. *Acta Myol* 2012;31:121-5.
48. Atsumi M, Tanaka A, Kawarabayashi T, et al. Cerebral embolism associated with Becker muscular dystrophy-related dilated cardiomyopathy. *No To Shinkei* 2004;56:163-7.
49. Ikeniwa C, Sakai M, Kimura S, et al. Two cases of Duchenne muscular dystrophy complicated with dilated cardiomyopathy and cerebral infarction. *No To Shinkei* 2006;58:250-5.
50. Baker DW, Wright RF. Management of heart failure. IV. Anticoagulation for patients with heart failure due to left ventricular systolic dysfunction. *JAMA* 1994;272:1614-8.
51. Ruiz-Cano MJ, Delgado JF, Jiménez C, et al. Successful heart transplantation in patients with inherited myopathies associated with end-stage cardiomyopathy. *Transplant Proc* 2003;35:1513-5.
52. Amodeo A, Adorisio R. Left ventricular assist device in Duchenne cardiomyopathy: can we change the natural history of cardiac disease? *Int J Cardiol* 2012;161:e43.
53. Iodice F, Testa G, Averardi M, et al. Implantation of a left ventricular assist device as a destination therapy in Duchenne muscular dystrophy patients with end stage cardiac failure: management and lessons learned. *Neuromuscul Disord* 2015;25:19-23.
54. Wu RS, Gupta S, Brown RN et al. Clinical outcomes after cardiac transplantation in muscular dystrophy patients. *J Heart Lung Transplant* 2010;29:432-8.
55. Nigro G, Papa AA, Politano L. The heart and cardiac pacing in Steinert disease. *Acta Myol*. 2012;31:110-6.
56. Petri H, Vissing J, Witting N, et al. Cardiac manifestations of Myotonic Dystrophy type 1. *Int J Cardiol* 2012;160:82-8.
57. Russo V, Rago A, Politano L, et al. The effect of atrial preference pacing on paroxysmal atrial fibrillation incidence in Myotonic Dystrophy type 1 patients: a prospective, randomized, single-blind cross over study. *Europace* 2012;14:486-9.
58. Nigro G, Russo V, Rago A, et al. Right atrial preference pacing algorithm in the prevention of paroxysmal atrial fibrillation in Myotonic Dystrophy type 1 patients: a long term follow-up study *Acta Myol*. 2012;31:139-43.
59. Russo V, Di Meo F, Rago A, et al. Paroxysmal atrial fibrillation in Myotonic Dystrophy type 1 patients: P wave duration and dispersion analysis. *Eur Rev Med Pharmacol Sci* 2015;19:1241-8.
60. Russo V, Papa AA, Rago A, et al. Which is the true epidemiology of atrial fibrillation in myotonic dystrophy type 1 patients? *Pacing Clin Electrophysiol* 2016;doi:10.1111/pace.12970.
61. Cudia P, Bernasconi P, Chioldelli R, et al. Risk of arrhythmia in type I myotonic dystrophy: the role of clinical and genetic variables. *J Neurol Neurosurg Psychiatry* 2009;80:790-3.
62. Nguyen HH, Wolfe JT III, Holmes DR Jr, et al. Pathology of the cardiac conduction system in myotonic dystrophy: a study of 12 cases. *J Am Coll Cardiol* 1988;11:662-71.
63. Brembilla-Perrot B, Schwartz J, Huttin O, et al. Atrial Flutter or Fibrillation is the Most Frequent and Life-Threatening Arrhythmia in Myotonic Dystrophy. *Pacing Clin Electrophysiol* 2014;37:329-35.
64. Dello Russo A, Mangiola F, Della Bella P, et al. Risk of arrhythmias in myotonic dystrophy: trial design of the RAMYD study. *J Cardiovasc Med (Hagerstown)* 2009;10:51-8.
65. Groh VJ, Groh MR, Saha C, et al. Electrocardiographic abnormalities and sudden death in myotonic dystrophy type 1. *N Engl J Med* 2008;358:2688-97.
66. Laurent V, Pellieux S, Corcia P, et al. Mortality in myotonic dystrophy patients in the area of prophylactic pacing devices. *Int J Cardiol* 2011;150:54-8.
67. Russo V, Rago A, Nigro G. Sudden cardiac death in neuromuscular disorders: Time to establish shared protocols for cardiac pacing. *Int J Cardiol* 2016;207:284-5.
68. Petillo R, D'Ambrosio P, Torella A, et al. Novel mutations in LMNA A/C gene and associated phenotypes. *Acta Myol* 2015;34:116-9.
69. Finsterer J, Stöllberger C, Sehnal E, et al. Dilated, arrhythmogenic cardiomyopathy in Emery-Dreifuss muscular dystrophy due to the emerin splice-site mutation c.449 + 1G>A. *Cardiology* 2015; 130:48-51.
70. Maggi L, D'Amico A, Pini A, et al. LMNA-associated myopathies: the Italian experience in a large cohort of patients. *Neurology* 2014;83:1634-44.
71. Parmar MS, Parmar KS. Emery-Dreifuss humeroperoneal muscular dystrophy: cardiac manifestations. *Can J Cardiol* 2012;28:516.e1-3.
72. Wessely R, Seidl S, Schömig A. Cardiac involvement in Emery-Dreifuss muscular dystrophy. *Clin Genet* 2005;67:220-3.
73. Boriani G, Gallina M, Merlini L, et al. Clinical relevance of atrial fibrillation/flutter, stroke, pacemaker implant, and heart failure in Emery-Dreifuss muscular dystrophy: a long-term longitudinal study. *Stroke* 2003;34:901-8.
74. Russo V, Rago A, Palladino A, et al. P wave duration and dispersion in Emery-Dreifuss Muscular Dystrophy. *J Investig Med* 2011;59:1151-4.
75. Nigro G, Russo V, Ventriglia VM, et al. Early onset of cardiomyopathy and primary prevention of sudden death in X-linked Emery-Dreifuss muscular dystrophy. *Neuromuscul Disord* 2010;20:174-7.
76. Russo V, Nigro G. ICD role in preventing sudden cardiac death in Emery-Dreifuss muscular dystrophy with preserved myocardial function: 2013 ESC Guidelines on Cardiac Pacing and Cardiac Resynchronization Therapy. *Europace* 2015;17:2:337; doi:10.1093/europace/euu146.
77. Deenen JC, Arnts H, van der Maarel SM, et al. Population-based incidence and prevalence of facioscapulohumeral dystrophy. *Neurology* 2014; 83:1056-9.
78. Brouwer OF, Padberg GW, Wijmenga C, et al. Facioscapulo-

- humeral muscular dystrophy in early childhood. *Arch Neurol* 1994; 51:387-94.
79. Nikolic A, Ricci G, Sera F, et al. Clinical expression of facioscapulohumeral muscular dystrophy in carriers of 1–3 D4Z4 reduced alleles: experience of the FSHD Italian National Registry. *BMJ Open* 2016; 6 e007798.
80. Zatz M, Marie SK, Cerqueira A, et al. The facioscapulohumeral muscular dystrophy (FSHD1) gene affects males more severely and more frequently than females. *Am J Med Genet* 1998;77:155-61.
81. Tonini MM, Passos-Bueno MR, Cerqueira A, et al. Asymptomatic carriers and gender differences in facioscapulohumeral muscular dystrophy (FSHD). *Neuromuscul Disord* 2004;14:33-8.
82. Padberg GW, Brouwer OF, de Keizer RJ, et al. On the significance of retinal vascular disease and hearing loss in facioscapulohumeral muscular dystrophy. *Muscle Nerve* 1995;2:S73-80.
83. Rosa N, Lanza M, de Bernardo M, et al. Intraocular pressure in patients with muscular dystrophies. *Ophthalmology* 2013;120:1306-7.
84. Saito Y, Miyashita S, Yokoyama A, et al. Facioscapulohumeral muscular dystrophy with severe mental retardation and epilepsy. *Brain Dev* 2007; 29:231-3.
85. Trevisan CP, Pastorello E, Armani M, et al. Facioscapulohumeral muscular dystrophy and occurrence of heart arrhythmia. *Eur Neurol* 2006;56:1-5.
86. Finsterer J, Stöllberger C. Clinical or subclinical cardiac involvement in facioscapulohumeral muscular dystrophy. *Neuromuscul Disord* 2006;16:61-2.
87. Galetta F, Franzoni F, Sposito R, et al. Subclinical cardiac involvement in patients with facioscapulohumeral muscular dystrophy. *Neuromuscul Disord* 2005;15:403-8.
88. Emmrich P, Ogunlade V, Gradistanac T, et al. Facioscapulohumeral muscle dystrophy and heart disease. *Z Kardiol* 2005;94:348-54.
89. Finsterer J, Stöllberger C, Meng G. Cardiac involvement in facioscapulohumeral muscular dystrophy. *Cardiology* 2005;103:81-3.
90. Czarnywojtek A, Plazinska MT, Zgorzalewicz-Stachowiak M, et al. Dysfunction of the thyroid gland during amiodarone therapy: a study of 297 cases. *Ther Clin Risk Manag* 2016;12:505-13.