

## Review Article

### COVID-19 ASSOCIATED HYPERCOAGULABILITY: MANIFESTATIONS, MECHANISMS, AND MANAGEMENT

Michael A. Mazzeffi, Jonathan H. Chow, and Kenichi Tanaka

Department of Anesthesiology, University of Maryland School of Medicine, Baltimore, Maryland

Received 26 Jun 2020; first review completed 17 Jul 2020; accepted in final form 24 Aug 2020

**ABSTRACT**—Patients with severe coronavirus disease-2019 (COVID-19) frequently have hypercoagulability caused by the immune response to the severe acute respiratory syndrome coronavirus-2 infection. The pathophysiology of COVID-19 associated hypercoagulability is not fully understood, but characteristic changes include: increased fibrinogen concentration, increased Factor VIII activity, increased circulating von Willebrand factor, and exhausted fibrinolysis. Anticoagulant therapy improves outcomes in mechanically ventilated patients with COVID-19 and viscoelastic coagulation testing offers an opportunity to tailor anticoagulant therapy based on an individual patient's coagulation status. In this narrative review, we summarize clinical manifestations of COVID-19, mechanisms, monitoring considerations, and anticoagulant therapy. We also review unique considerations for COVID-19 patients who are on extracorporeal membrane oxygenation.

**KEYWORDS**—Coagulation, coronavirus, COVID-19, embolism, thrombosis

**ABBREVIATIONS**—ADAMTS13—a disintegrin and metalloproteinase with thrombospondin type 1 motif member 13; CFT—clot formation time; COVID-19—coronavirus disease-2019; ECMO—extracorporeal membrane oxygenation; ICU—intensive care unit; IL—interleukin; JAK—janus kinase; k—kinetic time; MA—maximum amplitude; MAPK—mitogen-activated protein kinase; MCF—maximum clot firmness; PAI-1—plasminogen activator inhibitor-1; PGI<sub>2</sub>—prostacyclin; SARS-CoV-2—severe acute respiratory syndrome coronavirus-2; TEG—thromboelastography; TEM—thromboelastometry; TNF—tumor necrosis factor; ULVWF—ultra-large von Willebrand factor; VTE—venous thromboembolism

#### CLINICAL MANIFESTATIONS OF COVID-19 ASSOCIATED HYPERCOAGULABILITY

The immune response to severe acute respiratory syndrome coronavirus-2 (SARS-CoV-2) infection leads to coagulation system activation and hypercoagulability in many patients with coronavirus disease-2019 (COVID-19). Studies from France, the Netherlands, the United Kingdom, and the United States estimate a venous thromboembolism (VTE) incidence between 8% and 69% (Table 1) (1–10). Pulmonary embolism occurs in critically ill COVID-19 patients at twice the rate observed in influenza patients (10). Ninety percent of patients do not have evidence of deep venous thrombosis, suggesting that pulmonary embolism occurs *de novo* in most cases (10). Ischemic stroke, ST elevation myocardial infarction, and limb ischemia also occur and may be the heralding symptom (11–14).

Autopsies of COVID-19 patients have shown that SARS-CoV-2 causes endothelialitis and microvascular thrombosis (15). These changes result in hypoxemia if poorly ventilated lung regions become hyperperfused and intrapulmonary shunting occurs (16). Patient-specific risk factors for thrombosis have not been elucidated, but may include: total viral inoculum, magnitude of inflammation, and predisposing cardiovascular disease. Severity of illness is strongly associated with thrombotic risk and patients admitted to the intensive care unit (ICU) have a 5-fold higher incidence of VTE (8).

#### COVID-19 ENDOTHELIALITIS

Endothelial cells maintain normal vascular homeostasis and have been called the gatekeeper of vessel health (17). Endothelial cells modulate platelet activity, regulate inflammation, and maintain the physiologic barrier between intravascular and extravascular compartments (17). Endothelial cells normally express anticoagulant molecules including PGI<sub>2</sub> (prostacyclin), nitric oxide, tissue factor pathway inhibitor, and thrombomodulin (18). Under conditions of inflammation or stress, endothelial cells become altered and they express procoagulant molecules including thromboxane A<sub>2</sub>, tissue factor, plasminogen activator inhibitor-1 (PAI-1), and Factor VIII.

Varga et al. first described endothelialitis in three patients who died from COVID-19. All patients showed histological signs of endothelial cell infection in the kidneys, lungs, intestine, and heart. Histologic analyses further demonstrated perivascular inflammation with lymphocytes and mononuclear cells (19). These findings were confirmed by Ackermann et al. (15) who found evidence of endothelial cell infection in the lungs of COVID-19 patients with a profound T cell response, which differed from influenza patients who had more of a neutrophil response.

#### LINK BETWEEN INFLAMMATION AND COAGULATION

Coagulation is an integral part of host immunity, isolating pathogens and preventing their replication. Humans have evolved a complex crosstalk between inflammation and coagulation. Interleukin-6 (IL-6), which is produced by macrophages,

Address reprint requests to Michael A. Mazzeffi, MD, MPH, MSc, 22 South Greene Street, Baltimore, MD 21201. E-mail: mmazzeff@hotmail.com

The authors report no conflicts of interest.

DOI: 10.1097/SHK.0000000000001660

Copyright © 2020 by the Shock Society

TABLE 1. Select studies of venous thromboembolism in COVID-19

Author	Patient population	Thrombosis incidence	Notes
Artifoni et al. (1)	71 hospitalized patients France	22.5% incidence of any VTE 21% with DVT and 10% with PE	Strong association between D-dimer concentration and VTE Patients with D-dimer >3 ug/mL had over 60% incidence of VTE Higher incidence of mechanical ventilation and ICU admission in VTE patients All patients with VTE received prophylaxis with LMWH
Bompard et al. (2)	137 patients, 24 critically ill France	24% incidence of PE	All hospitalized patients received LMWH prophylaxis One-third of PEs proximal and two-third distal 20% of PE patients had associated right heart strain Median D-dimer concentration nine times higher in patients with PE
Desborough et al. (3)	66 critically ill patients United Kingdom	15% incidence of VTE 9% with DVT and 8% with PE	All thromboses were confirmed by ultrasound or CT Patients with VTE had longer ICU and hospital stay Major bleeding in 10.6% of patients, but five of seven patients with bleeding were on ECMO
Klok et al. (4)	184 critically ill patients the Netherlands	31% cumulative incidence of thrombosis over time PE was the most common type of thrombosis comprising 81%	Cohort was 76% male All patients received VTE prophylaxis, but regimen differed by hospital
Litjos et al. (5)	26 critically ill patients France	69% incidence of VTE	Incidence of VTE significantly higher in patients receiving prophylactic versus therapeutic anticoagulation
Lodigiani et al. (6)	388 patients, 61 critically ill Italy	8% incidence of VTE	Half of VTEs detected within 24 h of admission All critically ill patients received prophylaxis with LMWH
Maatman et al. (7)	109 critically ill patients United States	28% incidence of VTE	58% had hypercoagulability on thromboelastography Median D-dimer two times higher in patients with VTE Troponin concentration significantly higher in patients with VTE
Middeldorp et al. (8)	198 hospitalized patients, 75 critically ill Netherlands	42% cumulative incidence of VTE at day 21 59% cumulative incidence in ICU patients	VTE associated with increased hazard of death; HR = 2.4 (95% CI = 1.02, 5.5) Patients with VTE required ICU admission more frequently All patients received prophylaxis with LMWH
Nahum et al. (9)	34 critically ill patients France	65% of patients had DVT at admission 79% had DVT within 48 h of admission	All patients in the cohort had Duplex examinations of both lower limbs performed 53% of patients had bilateral DVTs
Poissy et al. (10)	107 critically ill patients France	21% incidence of PE	Incidence of PE was twice as high in COVID-19 patients when compared with historical cohort of influenza patients 20 of 22 patients who had PE were receiving VTE prophylaxis

CI indicates confidence interval; COVID-19, coronavirus disease-2019; CT, computed tomography; DVT, deep venous thrombosis; ECMO, extracorporeal membrane oxygenation; HR, hazard ratio; ICU, intensive care unit; LMWH, low molecular weight heparin; PE, pulmonary embolism; VTE, venous thromboembolism.

stimulates production of acute phase proteins including C-reactive protein and fibrinogen from the liver within 2 to 6 h (20). IL-6 and IL-1 $\beta$  increase PAI-1 expression through Janus kinase (JAK) signaling, and mitogen-activated protein kinase (MAPK) (21).

Inflammatory cytokines stimulate endothelial cells to release procoagulant molecules. Specifically, IL-8 and tumor necrosis factor- $\alpha$  (TNF- $\alpha$ ) trigger the release of ultra-large von Willebrand factor (ULVWF) multimers from endothelial cells in a concentration-dependent manner (22). IL-6 soluble IL-6 receptor (sIL-6R) complex triggers release of ULVWF multimers from endothelial cells, but to a lesser extent than

IL-8 or TNF- $\alpha$  (22). Conversely, IL-6, but not IL-8 or TNF- $\alpha$ , inhibits a disintegrin and metalloproteinase with thrombospondin type 1 motif member 13 (ADAMTS13), reducing ULVWF multimer cleavage and enhancing platelet adhesion and aggregation (22).

Neutrophils are a critical part of innate immunity and sIL-6R is shed from apoptotic neutrophils increasing the number of cells that can respond to IL-6 stimulation (23). Neutrophils trigger shedding of thrombomodulin in concert with TNF- $\alpha$ , which impairs activation of Protein C, an endogenous anticoagulant (24). Local TNF- $\alpha$ , IL-6, sIL-6R, and IL-8 levels are

TABLE 2. Comparison of coagulation parameters in sepsis-induced coagulopathy and COVID-19

Coagulation parameter	Sepsis-induced coagulopathy	COVID-19
Platelet count	Decreased in most patients	Normal in most patients
Factor VIII activity	Increased	Severely increased
Fibrinogen	Normal or decreased in most patients	Severely increased
Thrombin antithrombin complex	Increased	Increased
VWF antigen	Increased	Severely increased
Thromboelastometry (TEM)		
EXTEM clot formation time	Normal in most patients	Decreased in most patients
EXTEM maximum clot firmness	Normal or decreased in most patients	Increased in most patients
FIBTEM maximum clot firmness	Normal or decreased in most patients	Severely increased in most patients
Thromboelastography (TEG)		
Kinetic time	Normal in most patients	Decreased in most patients
Maximum amplitude	Normal or decreased in most patients	Increased in most patients

VWF indicates von Willebrand factor.

acutely elevated during inflammation, promoting coagulation and transmigration of immune cells.

**COAGULATION CHANGES IN COVID-19**

Some of the coagulation changes that occur in COVID-19 are similar to typical sepsis-induced coagulopathy, while others are distinct (Table 2) (25, 26). Figure 1 summarizes mechanisms contributing to hypercoagulability. Respiratory viral infection increases tissue factor expression on endothelial cells 4 to 5-fold, which activates the extrinsic pathway and enhances thrombin generation (27). Infected monocytes also express tissue factor, which synergistically drives thrombin generation (28). Coagulation is propagated through the intrinsic pathway and shutdown is overwhelmed because of high Factor VIII activity and depletion of endogenous anticoagulants including Protein C and antithrombin. The fibrinolytic system is activated by tissue plasminogen activator, urokinase plasminogen activator, Factor XIa, and Factor XIIa, but plasmin activity cannot keep pace with fibrin formation, as fibrinolysis inhibitors including plasminogen activator inhibitor-1 are increased during sepsis and appear to be unusually high with severe coronavirus infection (29).

Characteristic changes in coagulation that occur in critically ill COVID-19 patients include: severely elevated fibrinogen concentration (600 mg/dL–900 mg/dL), increased

Factor VIII activity (>300% in many patients), increased thrombin-antithrombin complexes, and low-normal antithrombin and Protein C activity (30–33). Thromboelastometry (TEM) and thromboelastography (34) show decreases in clot formation time and kinetic time, as well as increases in maximum clot firmness (MCF) and maximum amplitude (MA) (Fig. 2). These tests provide a good screening tool to identify hypercoagulable patients, particularly when D-dimer is elevated (30, 35).

**IMPLICATIONS OF ELEVATED D-dimer**

Fibrinogen concentration reaches 600 mg/dL to 900 mg/dL in critically ill COVID-19 patients, whereas a normal value is 200 mg/dL to 400 mg/dL (30, 36, 37). Increased D-dimer occurs in parallel with hyperfibrinogenemia in many patients. Desborough et al. (3) described a series of 10 COVID-19 patients in the United Kingdom who had ultrasound or computed tomography confirmed VTE. The median D-dimer concentration was higher in patients with VTE compared with controls (69.1 mg/L vs. 2.1 mg/L). Ranucci et al. (36) showed reductions in fibrinogen from 780 mg/dL to 580 mg/dL and in D-dimer from 3.5 mg/L to 2.5 mg/L in an Italian cohort of COVID-19 patients who were treated with low-molecular weight heparin and clopidogrel, suggesting that hyperfibrinogenemia and reactive fibrinolysis may be modifiable.

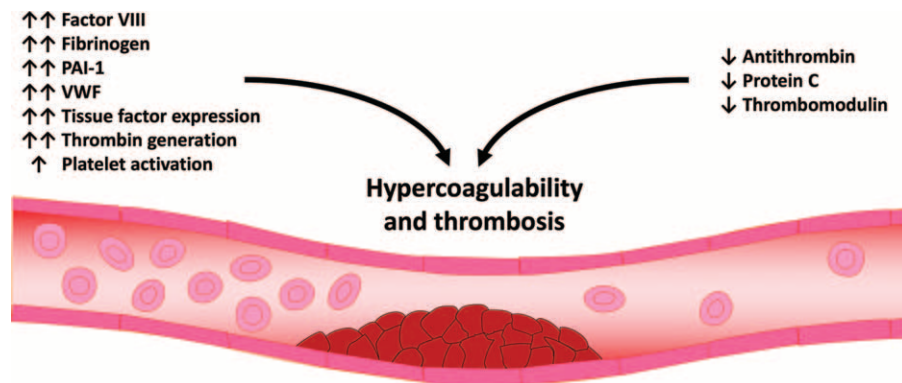


FIG. 1. Figure shows a summary of the coagulation changes that occur in COVID-19. Factor VIII activity, fibrinogen concentration, PAI-1, VWF, tissue factor expression, and thrombin generation are severely elevated in COVID-19. Platelet activation is also increased, while antithrombin, protein C, and thrombomodulin are decreased, leading to a hypercoagulable state and thrombosis in some patients. Figure created with Motifolio Toolkit (Motifolio Inc, Ellicott City, Md). PAI-1 indicates plasminogen activator inhibitor-1; VWF, von Willebrand factor; COVID-19, coronavirus disease-2019.

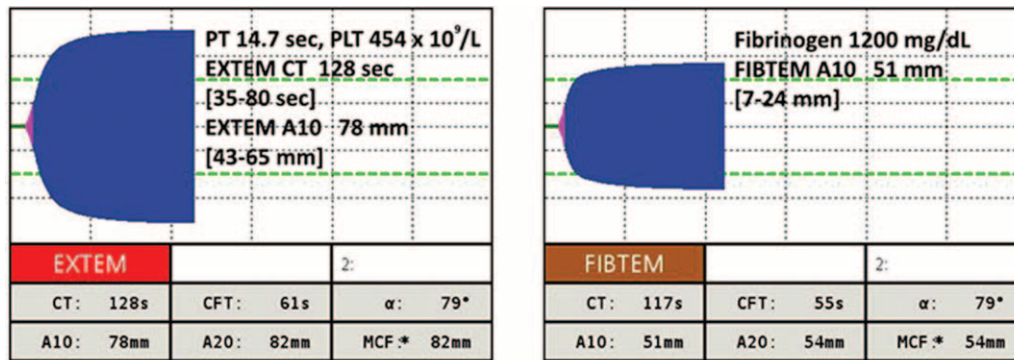


FIG. 2. Figure shows thromboelastometry tracings from a critically ill patient with severe acute respiratory distress syndrome related to SARS-CoV-2 infection who was on extracorporeal membrane oxygenation. The EXTEM and FIBTEM tracings show a slightly prolonged clotting time, but maximum clot formation on both EXTEM and FIBTEM is severely increased reflecting hypercoagulability. Normal ranges for tests are shown in brackets. SARS-CoV-2 indicates severe acute respiratory syndrome coronavirus-2.

D-dimer has become part of routine laboratory testing for critically ill COVID-19 patients and is considered a marker of disease severity. Zhang et al. reported that elevated D-dimer was a predictor of death in Chinese patients with COVID-19. In a study of 343 patients, there were 12 deaths in 67 patients who had an admission D-dimer  $\geq 2.0$  mg/L, and one death in 276 patients who had an admission D-dimer  $< 2.0$  mg/L, hazard ratio = 51.5 (95% CI = 12.9–206.7;  $P < 0.001$ ) (38). Notably, patients with elevated D-dimer were older and had more comorbidities including diabetes mellitus and cardiovascular disease, which were not controlled for adequately in the analysis. Similarly, Desborough et al. (3) found that patients who died were older (64 years vs. 55 years;  $P = 0.01$ ) and were more likely to have diabetes mellitus and cardiovascular disease. There was a non-significant trend toward higher D-dimer (7.8 mg/L vs. 2.1 mg/L;  $P = 0.28$ ) in patients who died, but the number of patients was relatively small limiting statistical power (3). Interestingly, COVID-19 patients do not consistently have signs of systemic fibrinolysis on viscoelastic coagulation testing (37, 39). Hence, D-dimer elevation is probably caused by both intravascular and extravascular fibrinolysis and impacted by the degree of lung injury, glomerular filtration rate, and baseline coagulation status.

### COAGULATION ASSESSMENT IN COVID-19 PATIENTS

Viscoelastic coagulation testing offers a useful tool to identify hypercoagulable COVID-19 patients. TEM and TEG offer an advantage over traditional plasma-based coagulation tests, such as prothrombin time and activated partial thromboplastin time, which are normal in most patients with COVID-19 (30, 35, 36). TEM shows a reduced clot formation time (CFT), increased angle, and increased MCF in COVID-19 patients with hypercoagulability (35), while TEG shows a reduced kinetic time (K), increased angle, and increased MA (30). The increased MCF in COVID-19 patients is mainly due to increased fibrinogen concentration, as is shown by a markedly increased FIBTEM MCF (Fig. 2).

Enhanced primary hemostasis related to increased VWF release from endothelial cells is difficult to demonstrate with

routine plasma-based coagulation tests, but is almost certainly a factor in COVID-19 associated hypercoagulability, as VWF antigen levels are increased five times above the upper limit of normal (30). One approach to monitor for hypercoagulability using commonly available laboratory tests is to measure fibrinogen concentration, Factor VIII activity, D-dimer, and viscoelastic coagulation parameters. In combination, these tests should demonstrate hypercoagulability in most COVID-19 patients, allowing for tailored anticoagulant therapy. Testing for antiphospholipid antibodies should also be considered for patients who demonstrate clinical signs of hypercoagulability (40).

### ANTICOAGULANT THERAPY FOR COVID-19 PATIENTS

Anticoagulant therapy is associated with improved survival in critically ill COVID-19 patients and the benefit of anticoagulation is greatest when there is more coagulation system activation (41, 42). Two cohort studies, one from China and one from the United States, demonstrated a mortality benefit when critically ill COVID-19 patients received either prophylactic or therapeutic anticoagulation. In the largest cohort study from New York City, 786 of 2,773 patients received intravenous unfractionated heparin and survival was improved in patients on mechanical ventilation ( $n = 395$ ) (41). In this study, a longer duration of anticoagulation was independently associated with a reduced risk of in-hospital death; hazard ratio = 0.86 per day, (95% CI = 0.82–0.89) and the incidence of serious bleeding was low at 3% (41).

The optimal degree of anticoagulation for critically ill COVID-19 patients is not known and it appears that VTE prophylaxis may not be adequate for a large proportion of patients. In one study of COVID-19 patients in the United States, up to 40% developed VTE, despite prophylaxis with unfractionated heparin or low molecular weight heparin (43). In a separate study of Italian patients, VTE prophylaxis with low molecular weight heparin was combined with antithrombin concentrate to keep antithrombin levels above 70% and clopidogrel when platelet count was above  $400 \times 10^9/L$  (44). This combination therapy leads to mitigation of hypercoagulability on viscoelastic coagulation testing (44). To our knowledge no

studies have compared the efficacy of prophylactic anticoagulation with therapeutic anticoagulation in critically ill COVID-19 patients.

Intravenous direct thrombin inhibitors may be beneficial in critically ill COVID-19 patients with hypercoagulability. Direct thrombin inhibitors bind to both circulating and clot-associated thrombin; whereas heparin–antithrombin complex binds only to circulating thrombin (45). Bivalirudin has a short half-life of approximately 25 min, which is prolonged when glomerular filtration rate is less than 30 mL/min and reaches 3 h when patients require renal replacement therapy (46). Argatroban has a half-life of approximately 45 min, but its half-life is prolonged in cases of acute hepatic dysfunction or cirrhosis (46). Novel oral anticoagulants are not typically used for treatment of critically ill COVID-19 patients because of their long half-lives, but they may be useful in the outpatient setting.

Other potential treatment options for COVID-19-associated hypercoagulability include: tissue plasminogen activator and recombinant thrombomodulin. In a case series of three critically ill COVID-19 patients with elevated D-dimer, tissue plasminogen activator treatment led to improved pulmonary gas exchange in all patients, with one patient having a durable response (47). A bolus of 25 mg was given over 2 h followed by a 22 h, 25 mg infusion (47). One patient had a 4-fold improvement in their P/F ratio after 11 h.

Thrombomodulin binds to activated thrombin and in concert with the endothelial protein C receptor converts Protein C to activated Protein C. Recombinant thrombomodulin (Asahi Kasei Pharma Corporation, Tokyo, Japan) has been approved for treatment of disseminated intravascular coagulation in Japan since 2008, but is not currently available in the United States or Europe. In a recent meta-analysis that included over 1,600 patients from three randomized controlled trials, it was found to reduce mortality in patients with sepsis-induced coagulopathy, relative risk = 0.80 (95% CI = 0.65–0.98) (48). To our knowledge, there are no published reports of recombinant thrombomodulin use in critically ill COVID-19 patients, but there is a strong physiologic rationale for its use and bleeding risk is probably low because its anticoagulant action is thrombin dependent.

Aspirin would seem to be a logical treatment for COVID-19 because of its irreversible antiplatelet effects and beneficial effects in patients with cardiovascular disease. Thrombocytopenia is uncommon in COVID-19 and aspirin reduces platelet neutrophil aggregates in the lung (30, 49). Aspirin also reduces IL-6 production, which may mitigate cytokine storm (50). At present, there are no studies to support aspirin's efficacy in COVID-19, but it is widely available, has a well-described risk profile, and is unlikely to cause major bleeding in patients without prior gastro-intestinal disease. Future studies will be needed to determine whether aspirin is a useful adjunctive treatment.

### **SPECIAL CONSIDERATIONS FOR EXTRACORPOREAL MEMBRANE OXYGENATION**

COVID-19 patients who require extracorporeal membrane oxygenation (ECMO) deserve special consideration in terms

of anticoagulation because many of the coagulation changes that occur with COVID-19 are exacerbated by ECMO. For example, patients on ECMO have increased Factor VIII activity and fibrinogen concentration, as well as supra-normal thrombin generation when they are not anticoagulated (51). COVID-19 patients who require ECMO have been noted to be hypercoagulable, requiring frequent circuit and oxygenator changes. In one report of 12 veno-venous ECMO patients, four patients had thrombotic complications during cannulation, two of which led to death (52). In addition, two other patients had cannula thrombosis, one of which required emergent cannula exchange (52). For this reason, many centers use high intensity heparin protocols for COVID-19 patients on veno-venous ECMO.

Exposure of blood to centrifugal pumps and high shear stress leads to loss of large VWF multimers and platelet GPIIb/IIIa receptor shedding, which causes abnormal primary hemostasis in ECMO patients and excessive bleeding during tissue injury (53–55). These changes, along with the use of higher anticoagulation targets in COVID-19 patients on ECMO, create a high risk for excessive bleeding during bedside procedures (e.g., chest drain insertion) or major surgical procedures. COVID-19 patients are at particularly high risk for airway bleeding and hemothorax given the severe tissue damage that occurs in the lungs. Given these complexities, we recommend an individualized, tailored approach to anticoagulation in COVID-19 patients on veno-venous ECMO. Hypercoagulability should be assessed using TEM or TEG, when available, and patients who are hypercoagulable should receive high intensity systemic anticoagulation with heparin or a direct thrombin inhibitor. Alternatively, patients with thrombocytopenia during ECMO and a low or normal MCF or MA might be better served with low intensity anticoagulation.

### **CONCLUSIONS**

Coagulation system activation is common in critically ill COVID-19 patients. Severity of illness is associated with the degree of coagulation system activation and patients with chronic cardiovascular diseases appear to have a predilection for hypercoagulability and organ failure. Some studies suggest that hypercoagulability during COVID-19 is modifiable offering an opportunity for intervention. Given the widespread availability of viscoelastic coagulation testing, anticoagulant therapy can be tailored for individual patients based on these tests. In critically ill COVID-19 patients, the risk for serious bleeding appears to be low; however, patients on ECMO represent an exception to this rule because of derangements in primary hemostasis. As greater experience is gained in caring for critically ill COVID-19 patients, there will be a better understanding of which patients are likely to benefit from high intensity anticoagulation and adjunctive therapies like low dose TPA, antiplatelet drugs, and perhaps recombinant thrombomodulin.

### **ACKNOWLEDGMENTS**

The authors acknowledge the courageous healthcare workers that work in the R Adams Cowley Shock Trauma Center Biocontainment unit.

## REFERENCES

- Artifoni M, Danic G, Gautier G, Gicquel P, Boutoille D, Raffi F, Neel A, Lecomte R: Systematic assessment of venous thromboembolism in COVID-19 patients receiving thromboprophylaxis: incidence and role of D-dimer as predictive factors. *J Thromb Thrombolysis* 50(1):211–216, 2020.
- Bompard F, Monnier H, Saab I, Tordjman M, Abdoul H, Fournier L, Sanchez O, Lorut C, Chassagnon G, Revel MP: Pulmonary embolism in patients with Covid-19 pneumonia. *Eur Respir J* 56:2001365, 2020.
- Desborough MJR, Doyle AJ, Griffiths A, Retter A, Breen KA, Hunt BJ: Image-proven thromboembolism in patients with severe COVID-19 in a tertiary critical care unit in the United Kingdom. *Thromb Res* 193:1–4, 2020.
- Klok FA, Kruijff M, van der Meer NJM, Arbous MS, Gommers D, Kant KM, Kaptein FHJ, van Paassen J, Stals MAM, Huisman MV, et al.: Incidence of thrombotic complications in critically ill ICU patients with COVID-19. *Thromb Res* 191:145–147, 2020.
- Litjens JF, Leclerc M, Chochois C, Monsallier JM, Ramakers M, Auvray M, Merouani K: High incidence of venous thromboembolic events in anticoagulated severe COVID-19 patients. *J Thromb Haemost* 18:1743–1746, 2020.
- Lodigiani C, Iapichino G, Carenzo L, Cecconi M, Ferrazzi P, Sebastian T, Kucher N, Studt JD, Sacco C, Alexia B, et al.: Venous and arterial thromboembolic complications in COVID-19 patients admitted to an academic hospital in Milan, Italy. *Thromb Res* 191:9–14, 2020.
- Maatman TK, Jalali F, Feizpour C, Douglas A 2nd, McGuire SP, Kinnaman G, Hartwell JL, Maatman BT, Kreutz RP, Kapoor R, et al.: Routine venous thromboembolism prophylaxis may be inadequate in the hypercoagulable state of severe coronavirus disease 2019. *Crit Care Med* 48:e783–e790, 2020.
- Middeldorp S, Coppens M, van Haaps TF, Foppen M, Vlaar AP, Muller MCA, Bouman CCS, Beenen LFM, Kootte RS, Heijmans J, et al.: Incidence of venous thromboembolism in hospitalized patients with COVID-19. *J Thromb Haemost* 18:1995–2002, 2020.
- Nahum J, Morichau-Beauchant T, Daviaud F, Echegut P, Fichet J, Maillet JM, Thierry S: Venous thrombosis among critically ill patients with coronavirus disease 2019 (COVID-19). *JAMA Netw Open* 3(5):e2010478, 2020.
- Poissy J, Goutay J, Caplan M, Parmentier E, Duburcq T, Lassalle F, Jeanpierre E, Rauch A, Labreuche J, Susen S, et al.: Pulmonary embolism in COVID-19 patients: awareness of an increased prevalence. *Circulation* 142:184–186, 2020.
- Oxley TJ, Mocco J, Majidi S, Kellner CP, Shoirah H, Singh IP, De Leacy RA, Shigematsu T, Ladner TR, Yaeger KA, et al.: Large-vessel stroke as a presenting feature of covid-19 in the young. *N Engl J Med* 382(20):e60, 2020.
- Harari R, Bangalore S, Chang E, Shah B: COVID-19 complicated by acute myocardial infarction with extensive thrombus burden and cardiogenic shock. *Catheter Cardiovasc Interv*; 2020. Online ahead of print.
- Bangalore S, Sharma A, Slotwiner A, Yatskar L, Harari R, Shah B, Ibrahim H, Friedman GH, Thompson C, Alviar CL, et al.: ST-segment elevation in patients with covid-19—a case series. *N Engl J Med* 382:2478–2480, 2020.
- Bellosta R, Luzzani L, Natalini G, Pegorer MA, Attisani L, Cossu LG, Ferrandina C, Fossati A, Conti E, Bush RL, et al.: Acute limb ischemia in patients with COVID-19 pneumonia. *J Vasc Surg*; 2020 [Epub ahead of print].
- Ackermann M, Verleden SE, Kuehnel M, Haverich A, Welte T, Laenger F, Vanstapel A, Werlein C, Stark H, Tzankov A, et al.: Pulmonary vascular endothelialitis, thrombosis, and angiogenesis in Covid-19. *N Engl J Med* 383:120–128, 2020.
- Gattinoni L, Coppola S, Cressoni M, Busana M, Rossi S, Chiumello D: COVID-19 does not lead to a “typical” acute respiratory distress syndrome. *Am J Respir Crit Care Med* 201(10):1299–1300, 2020.
- Cahill PA, Redmond EM: Vascular endothelium—gatekeeper of vessel health. *Atherosclerosis* 248:97–109, 2016.
- Pearson JD: Endothelial cell function and thrombosis. *Baillieres Best Pract Res Clin Haematol* 12(3):329–341, 1999.
- Varga Z, Flammer AJ, Steiger P, Haberecker M, Andermatt R, Zinkernagel AS, Mehra MR, Schuepbach RA, Ruschitzka F, Moch H: Endothelial cell infection and endotheliitis in COVID-19. *Lancet* 395:1417–1418, 2020.
- Banks RE, Forbes MA, Storr M, Higginson J, Thompson D, Raynes J, Illingworth JM, Perren TJ, Selby PJ, Whitcher JT: The acute phase protein response in patients receiving subcutaneous IL-6. *Clin Exp Immunol* 102(1):217–223, 1995.
- Dong J, Fujii S, Imagawa S, Matsumoto S, Matsushita M, Todo S, Tsutsui H, Sobel BE: IL-1 and IL-6 induce hepatocyte plasminogen activator inhibitor-1 expression through independent signaling pathways converging on C/EBPdelta. *Am J Physiol Cell Physiol* 292(1):C209–C215, 2007.
- Bernardo A, Ball C, Nolasco L, Moake JF, Dong JF: Effects of inflammatory cytokines on the release and cleavage of the endothelial cell-derived ultralarge von Willebrand factor multimers under flow. *Blood* 104(1):100–106, 2004.
- Scheller J, Chalaris A, Schmidt-Arras D, Rose-John S: The pro- and anti-inflammatory properties of the cytokine interleukin-6. *Biochim Biophys Acta* 1813(5):878–888, 2011.
- Boehme MW, Deng Y, Raeth U, Bierhaus A, Ziegler R, Stremmel W, Nawroth PP: Release of thrombomodulin from endothelial cells by concerted action of TNF-alpha and neutrophils: in vivo and in vitro studies. *Immunology* 87(1):134–140, 1996.
- Simmons J, Pittet JF: The coagulopathy of acute sepsis. *Curr Opin Anaesthesiol* 28(2):227–236, 2015.
- Wada H, Sase T, Matsumoto T, Kushiya F, Sakakura M, Mori Y, Nishikawa M, Ohnishi K, Nakatani K, Gabazza EC, et al.: Increased soluble fibrin in plasma of patients with disseminated intravascular coagulation. *Clin Appl Thromb Hemost* 9(3):233–240, 2003.
- Visseren FL, Bouwman JJ, Bouter KP, Diepersloot RJ, de Groot PH, Erkelens DW: Procoagulant activity of endothelial cells after infection with respiratory viruses. *Thromb Haemost* 84(2):319–324, 2000.
- Foley JH, Conway EM: Cross talk pathways between coagulation and inflammation. *Circ Res* 118(9):1392–1408, 2016.
- Mavrommatis AC, Theodoridis T, Economou M, Kotanidou A, El Ali M, Christopoulou-Kokkinou V, Zakyntinos SG: Activation of the fibrinolytic system and utilization of the coagulation inhibitors in sepsis: comparison with severe sepsis and septic shock. *Intensive Care Med* 27(12):1853–1859, 2001.
- Panigada M, Bottino N, Tagliabue P, Grasselli G, Novembrino C, Chantarangkul V, Pesenti A, Peyvandi F, Tripodi A: Hypercoagulability of COVID-19 patients in intensive care unit: a report of thromboelastography findings and other parameters of hemostasis. *J Thromb Haemost* 18:1738–1742, 2020.
- Helms J, Tacquard C, Severac F, Leonard-Lorant I, Ohana M, Delabranche X, Merdji H, Clere-Jehl R, Schenck M, Fagot Gandet F, et al.: High risk of thrombosis in patients with severe SARS-CoV-2 infection: a multicenter prospective cohort study. *Intensive Care Med* 46:1089–1098, 2020.
- Han H, Yang L, Liu R, Liu F, Wu KL, Li J, Liu XH, Zhu CL: Prominent changes in blood coagulation of patients with SARS-CoV-2 infection. *Clin Chem Lab Med* 58:1116–1120, 2020.
- Tabatabai A, Rabin J, Menaker J, Madathil R, Galvagno S, Menne A, Chow JH, Grazioli A, Herr D, Tanaka K, et al.: Factor VIII and functional protein C activity in critically ill patients with coronavirus disease 2019: a case series. *A A Pract* 14(7):e01236, 2020.
- Wallentin L, Becker RC, Budaj A, Cannon CP, Emanuelsson H, Held C, Horro J, Husted S, James S, Katus H, et al.: Ticagrelor versus clopidogrel in patients with acute coronary syndromes. *N Engl J Med* 361(11):1045–1057, 2009.
- Pavoni V, Giancesello L, Pazzi M, Stera C, Meconi T, Frigieri FC: Evaluation of coagulation function by rotation thromboelastometry in critically ill patients with severe COVID-19 pneumonia. *J Thromb Thrombolysis* 50:281–286, 2020.
- Ranucci M, Ballotta A, Di Dedda U, Bayshnikova E, Dei Poli M, Resta M, Falco M, Albano G, Menicanti L: The procoagulant pattern of patients with COVID-19 acute respiratory distress syndrome. *J Thromb Haemost* 18:1747–1751, 2020.
- Mortus JR, Manek SE, Brubaker LS, Loor M, Cruz MA, Trautner BW, Rose-ngart TK: Thromboelastographic results and hypercoagulability syndrome in patients with coronavirus disease 2019 who are critically ill. *JAMA Netw Open* 3(6):e2011192, 2020.
- Zhang L, Yan X, Fan Q, Liu H, Liu X, Liu Z, Zhang Z: D-dimer levels on admission to predict in-hospital mortality in patients with Covid-19. *J Thromb Haemost* 18(6):1324–1329, 2020.
- Madathil RJ, Tabatabai A, Rabin J, Menne AR, Henderson R, Mazzeffi M, Scalea TM, Tanaka K: Thromboelastometry and D-dimer elevation in Coronavirus-2019. *J Cardiothorac Vasc Anesth*; 2020 [Epub ahead of print].
- Zhang Y, Xiao M, Zhang S, Xia P, Cao W, Jiang W, Chen H, Ding X, Zhao H, Zhang H, et al.: Coagulopathy and antiphospholipid antibodies in patients with Covid-19. *N Engl J Med* 382:e38, 2020.
- Paranjpe I, Fuster V, Lala A, Ruskak A, Glicksberg BS, Levin MA, Charney AW, Narula J, Fayad ZA, Bagiella E, et al.: Association of treatment dose anticoagulation with in-hospital survival among hospitalized patients with COVID-19. *J Am Coll Cardiol* 76:122–124, 2020.
- Tang N, Bai H, Chen X, Gong J, Li D, Sun Z: Anticoagulant treatment is associated with decreased mortality in severe coronavirus disease 2019 patients with coagulopathy. *J Thromb Haemost* 18:1094–1099, 2020.
- Trigonis RA, Holt DB, Yuan R, Siddiqui AA, Craft MK, Khan BA, Kapoor R, Rahman O: Incidence of venous thromboembolism in critically ill coronavirus disease 2019 patients receiving prophylactic anticoagulation. *Crit Care Med* 48:e805–e808, 2020.
- Ranucci M, Ballotta A, Di Dedda U, Bayshnikova E, Dei Poli M, Resta M, Falco M, Albano G, Menicanti L: The procoagulant pattern of patients with COVID-19 acute respiratory distress syndrome. *J Thromb Haemost* 18(7):1747–1751, 2020.

45. White CM: Thrombin-directed inhibitors: pharmacology and clinical use. *Am Heart J* 149(1 suppl):S54–60, 2005.
46. Koster A, Faraoni D, Levy JH: Argatroban and bivalirudin for perioperative anticoagulation in cardiac surgery. *Anesthesiology* 128(2):390–400, 2018.
47. Wang J, Hajizadeh N, Moore EE, McIntyre RC, Moore PK, Veress LA, Yaffe MB, Moore HB, Barrett CD: Tissue plasminogen activator (tPA) treatment for COVID-19 associated acute respiratory distress syndrome (ARDS): a case series. *J Thromb Haemost* 18:1752–1755, 2020.
48. Valeriani E, Squizzato A, Gallo A, Porreca E, Vincent JL, Iba T, Hagiwara A, Di Nisio M: Efficacy and safety of recombinant human soluble thrombomodulin in patients with sepsis-associated coagulopathy: a systematic review and meta-analysis. *J Thromb Haemost* 18:1618–1625, 2020.
49. Ortiz-Munoz G, Mallavia B, Bins A, Headley M, Krummel MF, Looney MR: Aspirin-triggered 15-epi-lipoxin A4 regulates neutrophil-platelet aggregation and attenuates acute lung injury in mice. *Blood* 124(17):2625–2634, 2014.
50. Jenkins NP: Aspirin and plasma interleukin-6 acute coronary syndromes. *Cardiovasc Res* 42(3):824–825, 1999.
51. Mazzeffi M, Strauss E, Meyer M, Hasan S, Judd M, Abuelkasem E, Chow J, Nandwani V, McCarthy P, Tanaka K: Coagulation factor levels and underlying thrombin generation patterns in adult extracorporeal membrane oxygenation patients. *Anesth Analg* 129(3):659–666, 2019.
52. Beyls C, Huette P, Abou-Arab O, Berna P, Mahjoub Y: Extracorporeal membrane oxygenation for COVID-19-associated severe acute respiratory distress syndrome and risk of thrombosis. *Br J Anaesth* 125:e260–e262, 2020.
53. Chen Z, Mondal NK, Zheng S, Koenig SC, Slaughter MS, Griffith BP, Wu ZJ: High shear induces platelet dysfunction leading to enhanced thrombotic propensity and diminished hemostatic capacity. *Platelets* 30(1):112–119, 2019.
54. Kalbhenn J, Schlagenhaut A, Rosenfelder S, Schmutz A, Zieger B: Acquired von Willebrand syndrome and impaired platelet function during venovenous extracorporeal membrane oxygenation: rapid onset and fast recovery. *J Heart Lung Transplant* 37(8):985–991, 2018.
55. Mazzeffi M, Hasan S, Abuelkasem E, Meyer M, Deatrick K, Taylor B, Kon Z, Herr D, Tanaka K: Von Willebrand factor-GP1b interactions in venoarterial extracorporeal membrane oxygenation patients. *J Cardiothorac Vasc Anesth* 33(8):2125–2132, 2019.

