

OPEN

# Transient Monoplegia as a Result of Unilateral Femoral Artery Ischemia Detected by Multimodal Intraoperative Neuromonitoring in Posterior Scoliosis Surgery

## A Case Report

Rafal Pankowski, MD, PhD, Marek Roclawski, MD, PhD, Krzysztof Dziegiel, MD, PhD, Marcin Ceynowa, MD, PhD, Marcin Mikulicz, MD, Tomasz Mazurek, MD, PhD, and Wojciech Kloc, MD, PhD

**Abstract:** This is to report a case of 16-year-old girl with transient right lower limb monoplegia as a result of femoral artery ischemia detected by multimodal intraoperative spinal cord neuromonitoring (MISNM) during posterior correction surgery of adolescent idiopathic scoliosis.

A patient with a marfanoid body habitus and LENKE IA type scoliosis with the right thoracic curve of 48° of Cobb angle was admitted for posterior spinal fusion from Th6 to L2. After selective pedicle screws instrumentation and corrective maneuvers motor evoked potentials (MEP) began to decrease with no concomitant changes in somatosensory evoked potentials recordings.

The instrumentation was released first partially than completely with rod removal but the patient demonstrated constantly increasing serious neurological motor deficit of the whole right lower limb. Every technical cause of the MEP changes was eliminated and during the wake-up test the right foot was found to be pale and cold with no popliteal and dorsalis pedis pulses palpable. The patient was repositioned and the pelvic pad was placed more cranially. Instantly, the pulse and color returned to the patient's foot. Following MEP recordings showed gradual return of motor function up to the baseline at the end of the surgery, whereas somato-sensory evoked potentials were within normal range through the whole procedure.

This case emphasizes the importance of the proper pelvic pad positioning during the complex spine surgeries performed in prone position of the patient. A few cases of neurological complications have been described which were the result of vascular occlusion after prolonged pressure in the inguinal area during posterior scoliosis surgery when the patient was in prone position. If incorrectly interpreted, they would have a significant impact on the course of scoliosis surgery.

(*Medicine* 95(6):e2748)

**Abbreviations:** AIS = adolescent idiopathic scoliosis, DVR = direct vertebral rotation, ICT = intraoperative computed tomography, MEP = motor evoked potentials, MISNM = multimodal intraoperative spinal cord neuromonitoring, PSS = posterior scoliosis surgery, SCRR = single concave rod rotation, SSEP = somato-sensory evoked potentials, TC-MEP = transcranial motor evoked potentials.

## INTRODUCTION

The surgical correction of scoliosis bears the risk of one of the most catastrophic surgical complications such as neurological impairment.<sup>1</sup> The incidence of this complication is estimated to be 0.3% approximately.<sup>2</sup> The etiology of spinal cord lesion in scoliosis surgery is considered to be multifactorial with the dominance of mechanical and vascular ground.<sup>3,4</sup> Early detection of neurological compromise and immediate response during scoliosis surgery may reduce the risk of permanent spinal cord injury.<sup>4</sup> The first test used to detect and address problems before they become irreversible was Stagnara wake-up test, which was the “gold standard” for many years.<sup>5,6</sup> At present, a multimodal intraoperative spinal neuromonitoring (MISNM) is used routinely during spinal deformity surgery.<sup>5,7-11</sup> The earliest form of spinal cord neuromonitoring was somato-sensory evoked potentials (SSEP) recording, reserved only for the dorsal columns of the spinal cord and evaluated the integrity of the sensory pathways.<sup>4,12</sup> Many factors can influence the latency and amplitude of the recorded SSEP. The occurrence of misleading-evoked potentials can lead to false-negative outcomes.<sup>4,5,13-15</sup> It has led to the development of motor evoked potentials (MEP) that evaluate the descending lateral motor pathways of the spinal cord. MEP recording is much less variable than SSEP but on the other hand more sensitive to anesthetic drugs, particularly the neuromuscular blocking agents.<sup>16,17</sup> At present, SSEP along with MEP recordings are obligatory and provide the surgeon with a feedback on the neurological state of the patient. The most crucial point of the spinal deformity surgery is correction. If the signal of MISNM is altered after the corrective maneuvers, immediate release of the correction is mandatory for the potentials to recover to the regular neurologic state. In questionable cases the Stagnara wake-up test can be helpful. A few cases of neurological complications have been described which were the result of vascular occlusion after prolonged pressure in the inguinal area during posterior scoliosis surgery when the patient was in prone position.<sup>18-20</sup> These and similar situations may suggest that neurological impairment is associated with the operative

Editor: Perbinder Grewal.

Received: October 1, 2015; revised: January 5, 2016; accepted: January 7, 2016.

From the Department of Orthopedic Surgery, Medical University of Gdansk, Poland (RP, MR, MC, MM, TM); and Department of Neurology and Neurosurgery, Faculty of Medical Sciences, University of Warmia and Mazury, Olsztyn, Poland (KD, WK).

Correspondence: Marek Roclawski, ul. Pohulanka 6/53 80-807 Gdansk, Poland (e-mail: marekroclawski@op.pl).

All authors contributed equally to this work. RP, MR, MC, MM, and KD participated in the design of the study. RP and MR drafted the manuscript. TM and WK conceived of the study and participated in its coordination. All authors read and approved the final manuscript.

The authors have no funding and conflicts of interest to disclose.

Copyright © 2016 Wolters Kluwer Health, Inc. All rights reserved.

This is an open access article distributed under the Creative Commons Attribution-NonCommercial-NoDerivatives License 4.0, where it is permissible to download, share and reproduce the work in any medium, provided it is properly cited. The work cannot be changed in any way or used commercially.

ISSN: 0025-7974

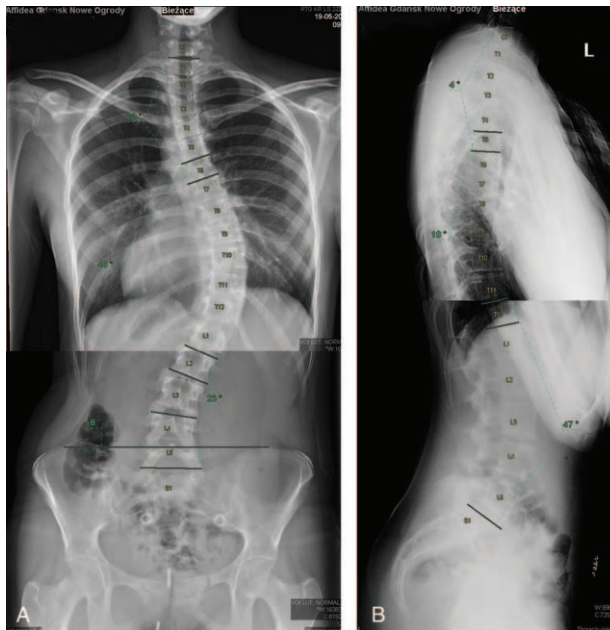
DOI: 10.1097/MD.0000000000002748

technique. If incorrectly interpreted, they would have a significant impact on the course of scoliosis surgery.

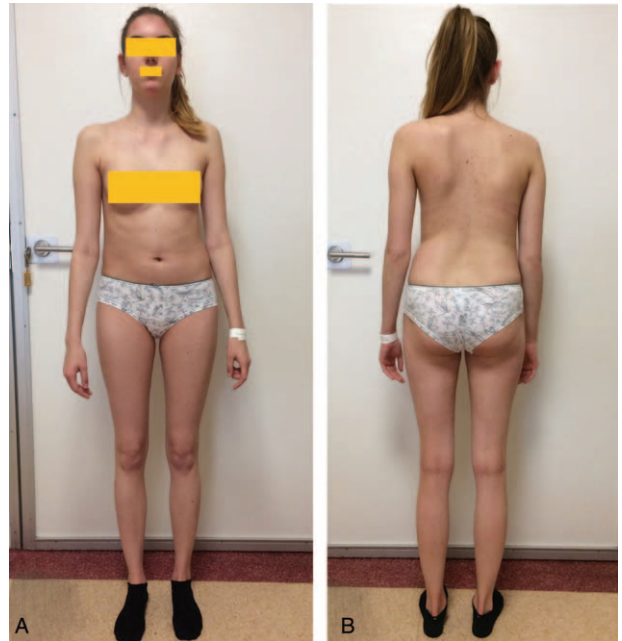
## CASE REPORT

### Methods

Written informed consent for publication of this case report and all images was obtained from the patient and the patient's mother. Because this is a case report ethical approval was not applicable. A 16-year-old girl with adolescent idiopathic scoliosis (AIS) was admitted to our Department for Posterior Scoliosis Surgery (PSS). Preoperative radiograph revealed LENKE IA type of the right thoracic curve of  $48^\circ$  of Cobb angle. The patient demonstrated a proper preoperative balance (Figure 1). Posterior spinal fusion was planned for Th6 to L2. She presented a marfanoid body habitus (weight 51 kg, height 174 cm, and BMI = 16.8) and typical AIS symptoms (Figure 2) without any abnormalities in genetic evaluation. Preoperative spinal MRI was within normal limits as well as preoperative neurological evaluation revealed no pathology except scoliosis. General anesthesia was performed with the standard scheme. Intravenous loading dose of Propofol 3 mg/kg and Remifentanyl 75  $\mu$ g/kg were used for the induction. For the anesthesia maintenance continuous infusion of Propofol 4 mg/kg/h and Remifentanyl 100  $\mu$ g/ml according to weight table was used. Concentrations of drugs infusion were customized to the patient's vital parameters. Because the multimodal spinal cord monitoring was used administration of neuromuscular blocking agents was avoided to prevent any deterioration in the MEP recordings.<sup>16,17</sup> After the induction patient was turned to the prone position on the operative radiolucent table carefully with cushions under the chest and pelvis considering the proper sagittal balance. Arms and legs were accurately positioned with slightly extended hips, minimally flexed knees, and feet in neutral position. Cushions were placed under knees, feet,



**FIGURE 1.** A, B, Posterior–anterior and lateral preoperative standing radiographs of the patient demonstrating the right thoracic scoliosis of  $48^\circ$  of Cobb angle.

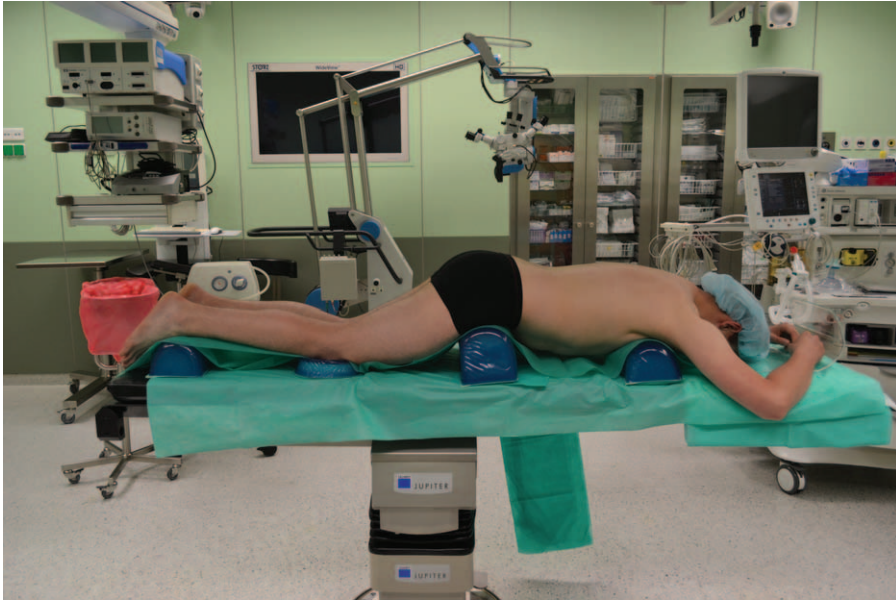


**FIGURE 2.** A, B, The patient's preoperative clinical views with a marfanoid body habitus and typical AIS symptoms.

elbows, and forehead (Figure 3). Multimodal Intraoperative spinal cord neuromonitoring (MISNM) with ISSIS software (Inomed, Medizintechnik GmbH, Germany) was used. Disposable subdermal electrodes were used for SSEP and MEP recordings. Posterior tibial nerve was stimulated bilaterally automatically and in the typical way for SSEP recording with 40-mA current at the rate of 4.7 Hz. A baseline was set from 300 trials with the use of signal averaging technique. A bandpass from 5 to 2500 Hz was used. Corkscrew electrodes were implanted over the cortical motor areas (C2 and C4) for transcranial motor evoked potentials (TC-MEP) induction. A stimulation protocol covered multiple pulse stimulation with 300 V and 155-mA current of 0.2 frequency with 5 stimuli-train. The intervals were set on 4 ms between stimuli that were monitored from tibialis anterior, triceps surae, and quadriceps muscle with a bandpass of 160 Hz. Warning criteria for TC-MEP were set typically as: 50% loss of amplitude and 10% loss of latency. SSEP recording was permanently generated through the whole surgery from the skin incision until the wound was closed (0–186 min) (Figure 4A). TC-MEP recording was performed 3 times before corrective maneuvers and 7 times after that (0, 2, 18, 89, 101, 114, 138, 145, 155, and 186 minutes).

## RESULTS

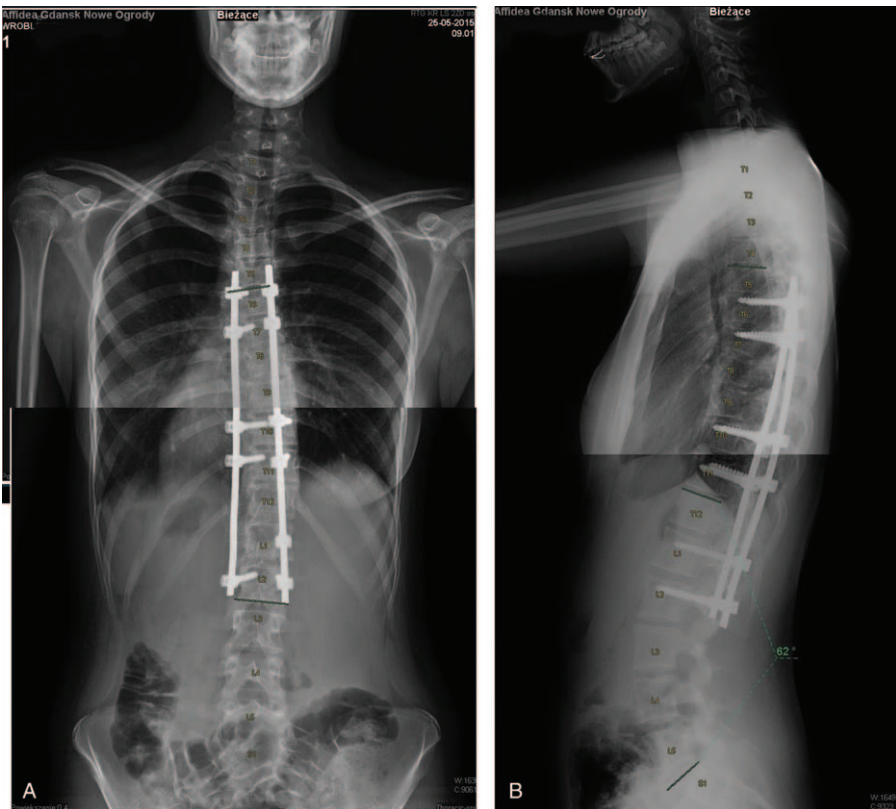
A posterior approach to the spine was performed and posterior spinal structures were exposed and released from Th6 to L2. Pedicle screws were instrumented selectively with AP fluoroscopic view guidance according to the preoperative plan (Figure 5). The proper screw placement was confirmed with intraoperative computed tomography (ICT) (Figure 6). Simultaneous correction was performed with single concave rod rotation (SCRR) and direct vertebral rotation (DVR) maneuvers (Figure 7). Before correction all 3 transcranial MEP recordings did not show any signs of spinal cord injury (Figure 4B). Immediately after corrective maneuvers (89 minutes) more than



**FIGURE 3.** The example of patient's prone positioning on the operative radiolucent table with cushions under the chest and pelvis. Arms and legs positioned with slightly extended hips, minimally flexed knees, and feet in neutral position.

80% loss of TC-MEPs was detected in all recording sites of the right lower extremity (Figure 4C). Simultaneously there were no changes in SSEP recordings. Therefore, the curve correction was released of 50% without rod removal immediately and after a few

minutes following MEP recording was performed. Simultaneously the patient was evaluated with ICT, which confirmed the unaltered position of screws and a lack of any impression to neural structures. During the next MEP evaluation (101 minutes)



**FIGURE 4.** A, B, Posterior–anterior and lateral postoperative standing radiographs of the patient. Selective pedicle screw instrumentation from Th6 to L2 was performed.

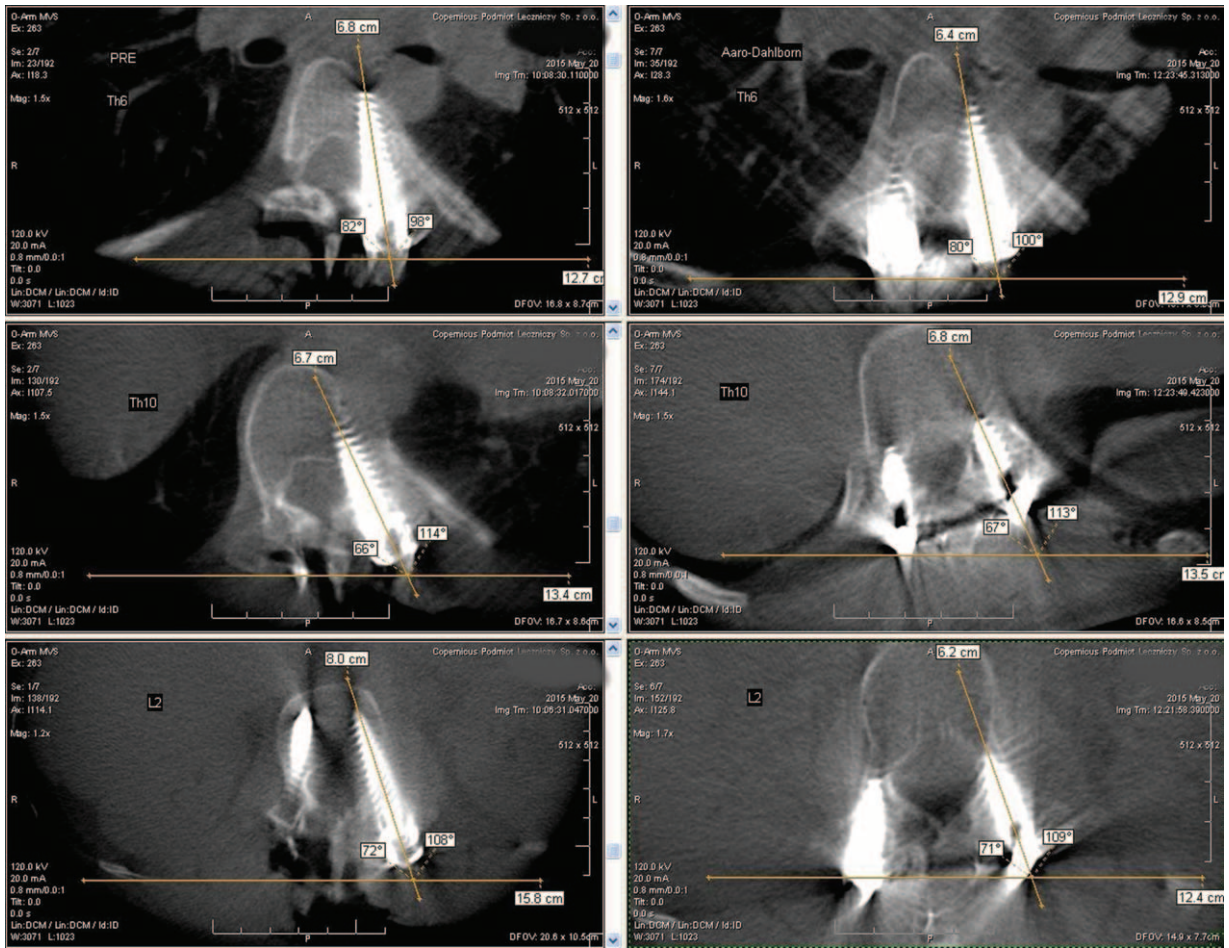


FIGURE 5. The proper screw placement confirmed by intraoperative computed tomography.

there was no improvement, but on contrary the SSEPs were unchanged from the baseline recordings (Figure 4D). Due to this fact the instrumentation was released completely with rod removal leaving only the pedicle screws in place. The next TC-MEPs (114 minutes) showed a serious neurological motor

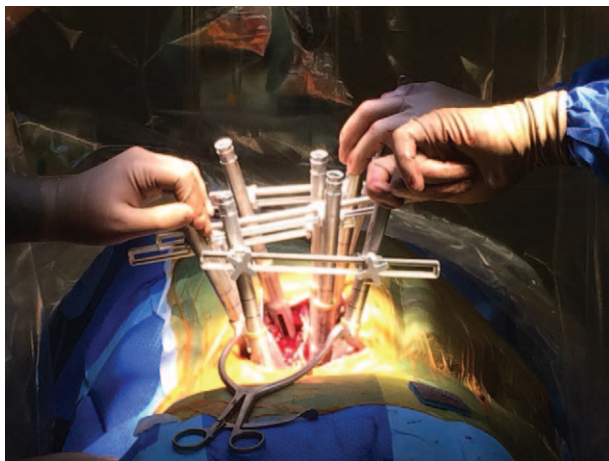
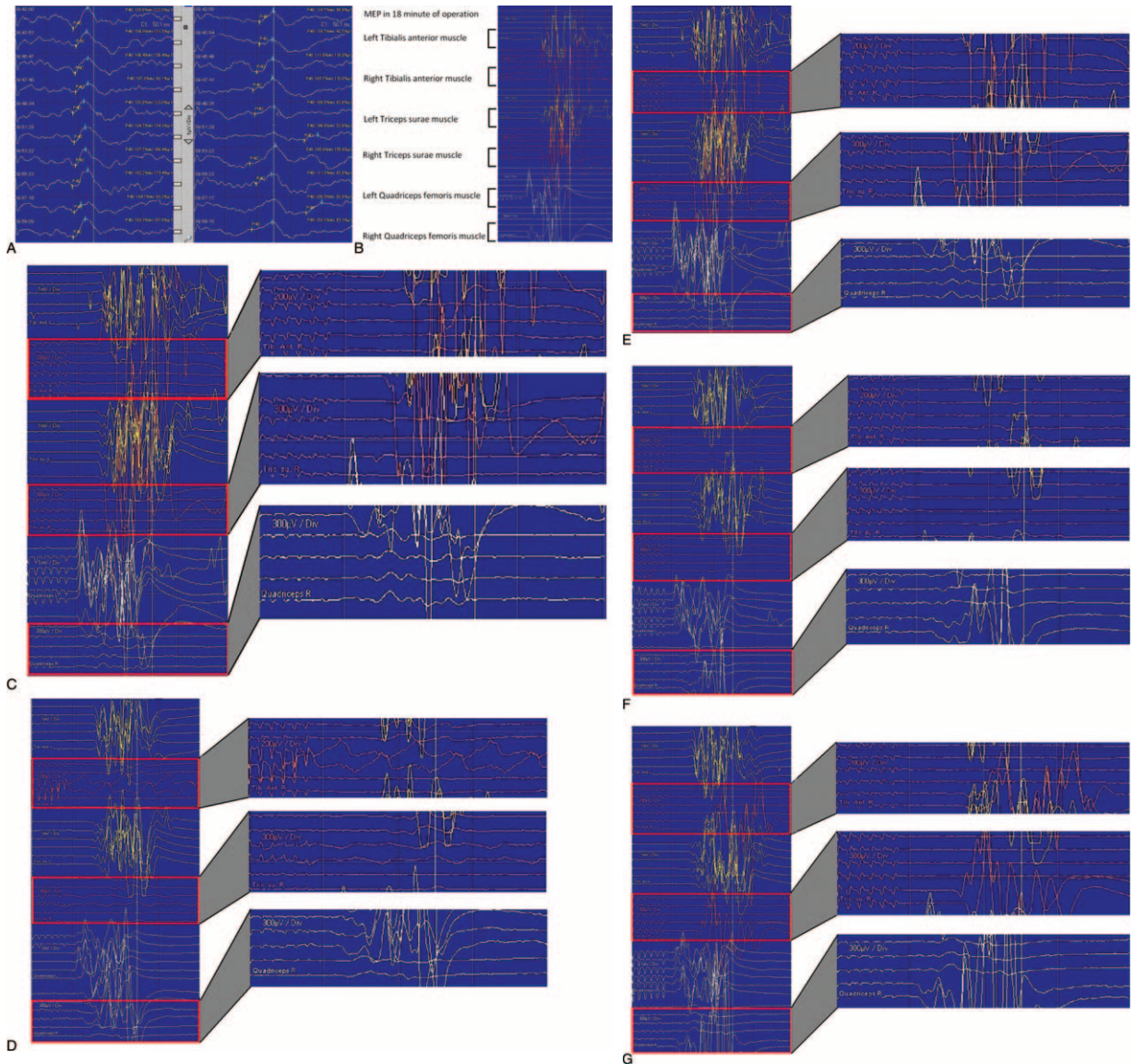


FIGURE 6. Simultaneous correction performed with single concave rod rotation and direct vertebral rotation.

deficit of the whole right lower limb (Figure 4E). Every possible technical error, which could be the cause of TC-MEPs decrease, was eliminated by neurophysiologist at that moment, so we decided that the wake-up test should be done. There was no voluntary movement possible for the right lower extremity with intact motor function on the contralateral side. On palpation the right foot was pale and cold and the left was normal. Dorsalis pedis and popliteal pulses were palpable only on the left unaffected side. An assumption was made that the possible cause for neurologic deficit of the right lower extremity would be the vascular occlusion of the right femoral artery through the cushion placed under the inguinal area. The cutaneous oxygen saturation on the right great toe was significantly lower than on the right side. The patient's position on the operative table was changed and the thigh cushion was positioned more cranially. Instantly, the pulse and color returned to the patient's foot. The cutaneous oxygen saturation on the right great toe increased and became equal with the left side. The next TC-MEP recording (138 minutes) showed the return of motor function mainly of the quadriceps femoris muscle, whereas SSEPs were within the normal range (Figure 4F). All following TC-MEP recordings monitored after the patients' positioning returned to the baseline (145, 155, and 186 minutes) (Figure 4G). After TC-MEP potentials became normal the rod was implanted again on the concave side and full correction (simultaneous SCRR and DVR maneuvers) and fusion of the deformity were completed without troubles. After



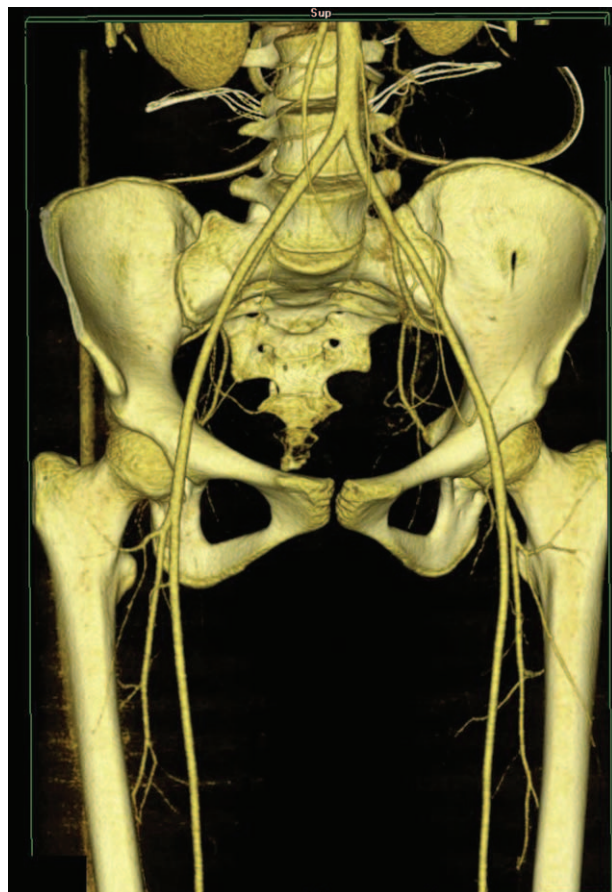
**FIGURE 7.** A, Somatosensory evoked potentials recorded from both posterior tibial nerves remained perfectly normal during the whole surgery (0–186 min). B, TC-MEP recording in 18 minutes of the surgery—unchanged from the baseline. C, Immediately after corrective maneuvers (89 min) more than 80% loss of TC-MEPs was detected in tibialis anterior, triceps surae, and quadriceps femoris recording sites of the right lower extremity. D, 101 minutes of the surgery—the curve correction was released of 50%—no improvement of TC-MEP recording. E, 114 minutes of the surgery—instrumentation released completely—TC-MEPs either did not improve but showed a serious neurological deficit of the whole right lower limb. F, 138 minutes of the surgery—the change of the thigh cushion position more cranially under the patient. The TC-MEP recording showed the return of motor function mainly of the quadriceps femoris muscle and partial return (10% of the baseline) of tibialis anterior and triceps surae. G, 145 minutes of the surgery—TC-MEP potentials returned to the baseline.

extubation the neurological state of the patient was within normal limits. Up till the second postoperative day an extensive diagnostic workup on the patient was performed. Both Doppler sonography and CT-angio did not show any abnormalities (Figure 8). Full neurological examination was performed without any pathological findings.

### DISCUSSION

Considering the patient’s welfare, intraoperative monitoring of the functional integrity of spinal cord is the

fundamental element of complex therapeutic planning in posterior corrective scoliosis surgery. The corrective maneuvers bear the risk of one of the most catastrophic complications such as neurological impairment. At present, multimodal intraoperative spinal cord neuromonitoring is used routinely during spinal deformity surgery for the early and accurate detection of impending spinal cord injury.<sup>21</sup> MISNM can be sensitive not only for the surgical maneuvers performed on spine but also for the other factors such as anesthetic drugs, neuromuscular blocking agents, hypotension, hypo perfusion, hypothermia, hypoxemia, blood rheology, and finally the



**FIGURE 8.** Postoperative angio-CT with no abnormalities.

patients positioning.<sup>4,5,13–15</sup> Even the proper positioning of the patient on the operative table can be associated with vascular occlusion of upper and lower limbs as well as the central retinal artery what leads to blindness.<sup>18–20</sup> To our knowledge, there are 2 case reports in the literature describing vascular occlusion of femoral artery in thin patients with marfanoid type of body habitus.<sup>18,20</sup> The presented patient had marfanoid phenotype but genetic evaluation did not show any abnormalities. Akagi et al<sup>19</sup> suggest some other risk factors for vascular occlusion of the femoral artery during posterior spinal surgery such as systemic lupus erythematosus, obesity, long time of the surgery, and thrombosis. It has been reported in the literature that the safe and reversible period of ischemia of the limb should not exceed 180 minutes.<sup>22</sup> Therefore in case of severe scoliosis posterior surgery with long operative time the presence of MISNM cannot be overemphasized and its lack can lead not only to neurological complications but also misdiagnosed limb ischemia and its permanent catastrophic sequelae for the patient. There have also been reports on SSEP sensitivity on limb ischemia.<sup>23</sup> Vossler et al have shown neurologic complication due to the lower limb vascular ischemia detected by SSEP decrease. What is worth to comment they used only SSEP recordings for spinal neuromonitoring. Tseng et al described the case of bilateral lower limb ischemia due to the femoral arteries vascular occlusion detected by multimodal spinal neuromonitoring with SSEPs and TC-MEPs decrease. The case was 15-year-old boy with idiopathic

scoliosis operated with PSS. The exact cause of ischemia similarly to our case was the inappropriately placed pad under the inguinal area what pressed directly on the femoral arteries.<sup>18</sup> In the present case, the diagnosis of right side monoplegia was based on TC-MEP recordings only with SSEPs unchanged. It should also be emphasized that the wake-up test that was performed to verify an unexpected neurological complication given the false-positive outcome of MISNM since the SSEP and TC-MEP recordings were unchanged from the baseline. The SSEP monitoring during PSS detects mainly intraoperative direct surgeon's maneuvers performed on the spine and it is reserved only for the dorsal columns of spinal cord with sensory pathways integrity evaluation. The SSEPs do not evaluate the descending lateral motor pathways of the spinal cord what can lead in consequence that this serious complication is undetected during surgery. It has been described in the literature as false negatives since the SSEP monitoring was unchanged in these cases.<sup>24</sup> TC-MEP intraoperative monitoring evaluates descending lateral motor pathways of the spinal cord and serves as a control for the SSEP recordings. Another advantage of TC-MEPs is that they can be updated multiple times during the particular part of the surgery. Our previous experience indicates much greater significance of TC-MEP potentials for the patient's clinical state prognosis than SSEP's.<sup>25</sup> The presented case proved it right because SSEP was constantly unchanged during the whole procedure. Because the decrease of TC-MEPs coincided with the critical portion of correction of the deformity, we supposed that the neurological impairment was due to the implant loosening with the possible spinal cord impression on the convex side. However, in ICT evaluation all pedicle screws had the proper and unchanged placement the same as before correction. The unilateral character of the ischemia in the presented case can be striking due to the fact that the pad is in a shape of a symmetrical rectangular cube. It possibly could be placed asymmetrically under the pelvis and it could be bolstered with the effect of the trunk deformity due to the right side thoracic curve. Although we think that MISNM is an essential method of the functional integrity of the spinal cord monitoring and should be used in every case of scoliosis surgery, it should be also taken into account that the MISNM outcome should be always analyzed individually with consideration to the different causes of the change of potentials. Moreover, Stagnara's wake-up test seems to be still up to date as an additional evaluation of the neurological state of the patient when MISNM is inconsistent as well as the patient's lower limb ischemia is possible to detect this way. If we misinterpret the neuromonitoring outcome and do not verify it with additional physical examination during wake-up test, it would lead in consequence to the wrong decision on postponement of scoliosis correction and spondylodesis delayed to the revision surgery in few weeks time. Furthermore, the following diagnostic workout would not detect the cause of neurological impairment during the surgery.

## CONCLUSIONS

This case emphasizes the importance of the proper pelvic pad positioning during complex spine surgeries performed in prone position of the patient. A few cases of neurological complications have been described which were the result of vascular occlusion after prolonged pressure in the inguinal area during posterior scoliosis surgery when the patient was in a prone position. If incorrectly interpreted, they would have a significant impact on the course of scoliosis surgery.

## REFERENCES

- MacEwen GD, Bunnell WP, Sriram K. Acute neurological complications in the treatment of scoliosis: a report of the Scoliosis Research Society. *J Bone Joint Surg Am.* 1975;57:404–408.
- Scoliosis Research Society. Morbidity and Mortality Report 1999 [unpublished].
- Machida M, Weinstein SL, Imamura Y, et al. Compound muscle action potentials and spinal evoked potentials in experimental spine maneuver. *Spine (Phila Pa 1976).* 1989;14:687–691.
- Mooney JF, Bernstein R, Hennrikus WL Jr et al. Neurologic risk management in scoliosis surgery. *J Pediatr Orthop.* 2002;22:683–689.
- Nash CL Jr, Brown RH. Spinal cord monitoring. *J Bone Joint Surg Am.* 1989;71:627–630.
- Vauzelle C, Stagnara P, Jouvinroux P. Functional monitoring of spinal cord activity during spinal surgery. *Clin Orthop.* 1973;93:173–178.
- Padberg AM, Bridwell KH. Spinal cord monitoring: current state of the art. *Orthop Clin North Am.* 1999;30:407–433.
- Padberg AM, Russo MH, Lenke LG, et al. Validity and reliability of spinal cord monitoring in neuromuscular spinal deformity surgery. *J Spinal Disord.* 1996;9:150–158.
- Wilson-Holden TJ, Padberg AM, Parkinson JD, et al. A prospective comparison of neurogenic mixed evoked potential stimulation methods: utility of epidural elicitation during posterior spinal surgery. *Spine (Phila Pa 1976).* 2000;25:2364–2371.
- Pereon Y, Nguyen The Tich S, Delecrin J, et al. Combined spinal cord monitoring using neurogenic mixed evoked potentials and collision techniques. *Spine (Phila Pa 1976).* 2002;27:1571–1576.
- Machida M, Weinstein SL, Yamada T, et al. Monitoring of motor action potentials after stimulation of the spinal cord. *J Bone Joint Surg Am.* 1988;70:911–918.
- Owen JH. The application of intraoperative monitoring during surgery for spinal deformity. *Spine (Phila Pa 1976).* 1999;24:2649–2662.
- Strahm C, Min K, Boos N, et al. Reliability of perioperative SSEP recordings in spine surgery. *Spinal Cord.* 2003;41:483–489.
- Ginsburg HH, Shetter AG, Raudzens PA. Postoperative paraplegia with preserved intraoperative somatosensory evoked potentials: case report. *J Neurosurg.* 1985;63:296–300.
- Lesser RP, Raudzens P, Luders H, et al. Postoperative neurological deficits may occur despite unchanged intraoperative somatosensory evoked potentials. *Ann Neurol.* 1986;19:22–25.
- Machida M, Weinstein SL, Yamada T, et al. Spinal cord monitoring: electrophysiological measures of sensory and motor function during spinal surgery. *Spine (Phila Pa 1976).* 1985;10:407–413.
- Dawson EG, Sherman JE, Kanim LE, et al. Spinal cord monitoring: results of the Scoliosis Research Society and the European Spinal Deformity Society survey. *Spine (Phila Pa 1976).* 1991;16(Suppl):361–364.
- Tseng MD, Cappelto L, Majid K, et al. Bilateral femoral artery ischemia detected by multimodality neuromonitoring during posterior scoliosis surgery. *Spine (Phila Pa 1976).* 2010;35:799–803.
- Akagi S, Yoshida Y, Kato I, et al. External iliac artery occlusion in posteriorspinal surgery. *Spine (Phila Pa 1976).* 1999;24:823–825.
- Vossler DG, Stonecipher T, Millen MD. Femoral artery ischemia during spinal scoliosis surgery detected by posterior tibial nerve somatosensory evoked potential monitoring. *Spine (Phila Pa 1976).* 2000;25:1457–1459.
- Schwartz DM, Auerbach JD, Dormans JP, et al. Neurophysiological detection of impending spinal cord injury during scoliosis surgery. *J Bone Joint Surg Am.* 2007;89:2440–2449.
- Trammell TR, Friedlander JK, Reed DB. The effect of lower limb ischemia on somatosensory evoked potential during spinal surgery. Report of two cases and review of literature. *Spine (Phila Pa 1976).* 1993;18:413–415.
- Sloan TB. Monitoring the brain and spinal cord. *Int Anesthesiol Clin.* 2004;42:1–23.
- Wiedemayer H, Sandalcioğlu IE, Armbruster W, et al. False negative findings in intraoperative SEP monitoring: analysis of 658 consecutive neurosurgical cases and review of published reports. *J Neurol Neurosurg Psychiatry.* 2004;75:280–286.
- Pankowski R, Dziegiel K, Roclawski M, et al. Intraoperative neurophysiologic monitoring (INM) in scoliosis surgery. *Stud Health Technol Inform.* 2012;176:319–321.