

# Rare craniofacial cleft in a dark-skinned African population

O. Olalekan Adeosun, Stephen Agbomhekhe Ogah<sup>1</sup>

Department of Dental and Maxillofacial Surgery, Federal Medical Centre, <sup>1</sup>Department of Surgery, Ear, Nose and Throat Division, Federal Medical Centre, Lokoja, Nigeria

## ABSTRACT

**Background:** Craniofacial clefts are congenital anomalies which pose a management challenge to cleft surgeons, especially in developing countries. The aim of this study is to share our experience regarding the management of these atypical facial clefts. **Patients and Methods:** This prospective study was carried out from May 2009 to May 2014 at Federal Medical Centre, Nguru, Nigeria. Diagnosis was based on clinical examination and Tessier classification was used to describe these clefts. **Results:** A total of seven patients with rare facial clefts were seen. There were four cases of midline clefts, two cases of bilateral clefts, and one case of multiple facial clefts. All cases were surgically treated, except one case of premaxillary agenesis type holoprosencephaly. **Conclusion:** To achieve an optimal management of patients with rare facial cleft, a well-equipped craniofacial center must be established which is still lacking in low-resource centers

**Key words:** Africans, cleft, craniofacial, dark-skinned, rare, reconstruction

### Address for correspondence:

Dr. Stephen Agbomhekhe Ogah,  
Department of Surgery, Ear, Nose  
and Throat Division, Federal  
Medical Centre, Lokoja, Nigeria.  
E-mail: stephenogah@yahoo.com

## INTRODUCTION

Congenital craniofacial clefts are disfiguring anomalies causing distortion of the face and cranium with either deficiencies or excesses of tissue that cleave anatomical planes in a linear fashion.<sup>1</sup> They exist in varying degrees of severity, ranging from a mere notch on the lip, nose, or scar-like structure on the cheek to a complete separation of all layers of facial structures.<sup>1</sup> In certain instances, one cleft type can manifest on one side of the face while a different type is present on the other side.<sup>2</sup> Their pathogenesis is not well understood, but they are likely to be the result of complex interrelated series of events such as incorrect genetic translation, cell deposition, cell differentiation, cell proliferation, and tissue remodeling.<sup>3</sup>

The exact incidence of craniofacial clefts is not known because of the rarity and series tend to be small; however, Kawamoto<sup>4</sup> estimated the incidence of these clefts to vary from 1.43 to 4.84 per 1000 live births. Furthermore, in a large series of common cleft lip and/or palate, the

incidence of these atypical facial clefts when compared with common cleft lip palate ranges from 9.5 to 34 per 1000.<sup>2</sup> The Tessier<sup>5</sup> classification is the most popular one currently being used for craniofacial clefts. The central point of reference is the orbit.<sup>5</sup> The orbits divide the face into upper and lower hemispheres and separate the cranial clefts from facial clefts. The clefts are numbered 0–14 depending on their location. Careful clinical examination and modern imaging techniques such as computed tomography (CT) scan, magnetic resonance imaging, and three-dimensional CT scan are necessary for proper diagnosis, evaluation of skeletal involvement in cleft formation, and accurate planning of surgical procedures. The management of craniofacial clefts poses a surgical challenge because of the complex bone and soft-tissue defects which may require a multistage reconstructive procedure and in a multidisciplinary approach. We present a case series of patients that presented to our rural-based hospital and highlight the challenges encountered in their management.

### Access this article online

#### Quick Response Code:



#### Website:

www.nigeriamedj.com

#### DOI:

10.4103/0300-1652.218415

This is an open access article distributed under the terms of the Creative Commons Attribution-NonCommercial-ShareAlike 3.0 License, which allows others to remix, tweak, and build upon the work non-commercially, as long as the author is credited and the new creations are licensed under the identical terms.

For reprints contact: reprints@medknow.com

**How to cite this article:** Adeosun OO, Ogah SA. Rare craniofacial cleft in a dark-skinned African population. Niger Med J 2017;58:21-5.

## PATIENTS AND METHODS

This is a prospective study of patients seen by the cleft team in Federal Medical Centre, Nguru, Northeastern Nigeria, from May 2009 to May 2014. Diagnosis was based on clinical examination of the patients and Tessier classification was used to describe the craniofacial clefts.

## RESULTS

Seven patients presented with rare facial clefts out of 327 orofacial clefts that were seen during the 4 years study period. There were four males and three females. There were four cases of midline cleft (Tessier no 0), two cases of bilateral cleft (Tessier no 7), one case of multiple clefts (Tessier no 5, 7, 30). In absolute term, the most common cleft was Tessier no 0, followed by Tessier no 7.

### Case reports

#### Case 1

A 35-year-old man presented to the clinic with a facial disfiguring anomaly. Physical examination revealed a median cleft of upper lip and nose (Tessier no 0). Nasal cartilage and bones were widened resulting in a lateral displacement of the ala nasi and deep midline depression [Figure 1a]. A broad nasal root and duplicated nasal septum were found. The external nares of the two halves were patent and wider than normal in horizontal dimension. In addition, a true orbital hypertelorism was also noticed at the orbital region. A diagnosis of median cleft face syndrome was made. Median cleft of the upper lip was repaired successfully by an inverted V-shape technique with special emphasis on muscular layer and vertical length of the lip [Figure 1b]; however, correction of bifid nose and hypertelorism are yet to be carried out because of challenges to be encountered in their reconstruction.

#### Case 2

A 30-year-old female had a midline cleft of the nose and upper lip (Tessier no 0). She was a street beggar by occupation and married to a deaf and dumb man with five children. Clinical examination revealed midline cleft of the nose apex, absence of cartilaginous part of nasal septum and columella [Figure 2a]. There was also an incomplete midline cleft of the upper lip with associated lip incompetence [Figure 2b]. An inverted V-shaped technique was used to repair the lip defect which resulted in an improved lip competence [Figure 2c].

#### Case 3

A 14-year-old male had a cleft nose (Tessier no 0) and an incomplete median cleft of the upper lip (Tessier no 0). There were both agenesis of cartilaginous part of nasal septum and columella [Figure 3a]. No history of difficulty in breathing was given and both nares were patent. The upper lip showed a furrow at midline and underdeveloped when compared with the thicker lower lip. There was

well-pronounced lip incompetence. The palate appeared clinically normal, except for the presence of a rudimentary premaxilla. Median cleft lip was repaired in layers by inverted V-shaped technique. Reconstruction of columella attempted with an internally nasal dorsal flap supported by conchal cartilage harvested from the left ear. A rubber nasal stent was placed to further improve the nasal patency [Figure 3c].

#### Case 4

A female child cleft patient of 9 years presented to the hospital with a severe hideous deformity.

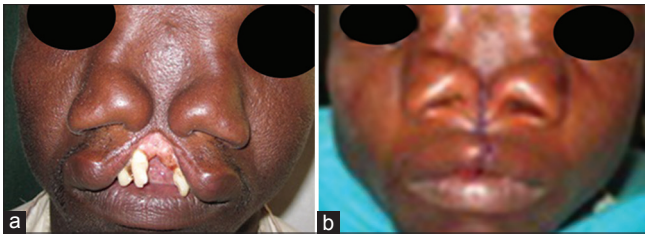
On clinical examination, a depressed scar about 2 cm in diameter extending from the apex of the V-shaped cleft of the lower lip (Tessier no. 30) to the tragus of the right dysmorphic ear was found [Figure 4a]. Superiorly, the scar traversed the root of the right zygoma and terminated at the posterior end of the right temporal region. There was also a right-sided commissural cleft (Tessier no. 7) of about 3 cm in length that was associated with a band that extended from its base. The left facial region revealed a retropositioned eye with cryptophthalmos; transmitted movement of the eye behind this covering tissue was also observed. Furthermore, there was an oblique facial cleft (Tessier no. 5) that extended from the lateral end of the upper lip to a coloboma at the junction of the middle and lateral third of the left lower eyelid [Figure 4b]. There was a deformity of the lower lacrimal canaliculus, with the lid retracted inferiorly. The underlying anterior wall of the maxilla was hypoplastic. The cleft of the lower lip was repaired by the V-plasty and the right-sided commissural defect was repaired by the linear suturing technique. Six months later, the patient was recalled for the repair of the oblique facial cleft. The lower eyelid part of the cleft was repaired with Z-plasty, while the closure of the labiomaxillary cleft was achieved by direct apposition of adjoining soft tissues in layers [Figure 4c]. The surgical correction of the retropositioned left eye and the lateral canthus are yet to be carried out.

#### Cases 5 and 6

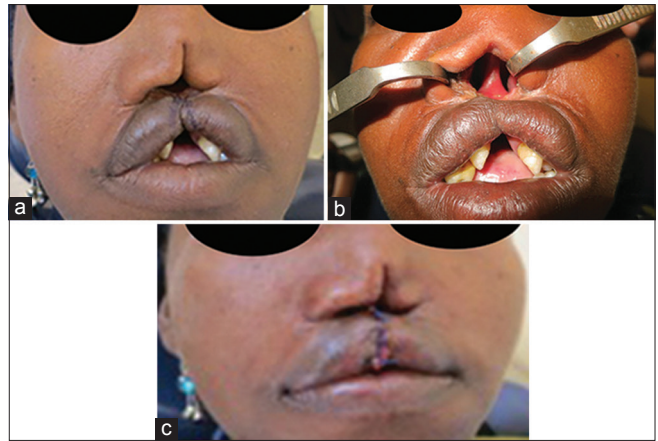
Two patients aged 9 years (female) and 17 years (male) had bilateral commissural clefts (Tessier no 7), with accompanied macrostomia [Figure 5a]. On clinical examination, there was neither hemifacial microsomia nor malformed external ear. On both patients, lateral clefts were repaired by linear suturing technique and there was marked improvement of their facial appearance [Figure 5b].

#### Case 7

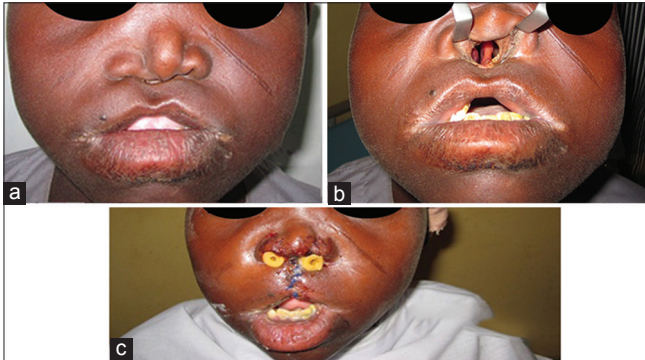
A malnourished 7-month-old male child presented with median cleft of upper lip (Tessier no 0) and dysmorphic nose. The premaxilla, columella, and nasal septum were completely absent. There was a Squit of the left eye, hypotelorism, and slight frontal bossing [Figure 6]. Midfacial hypoplasia was also noticed. No other abnormality



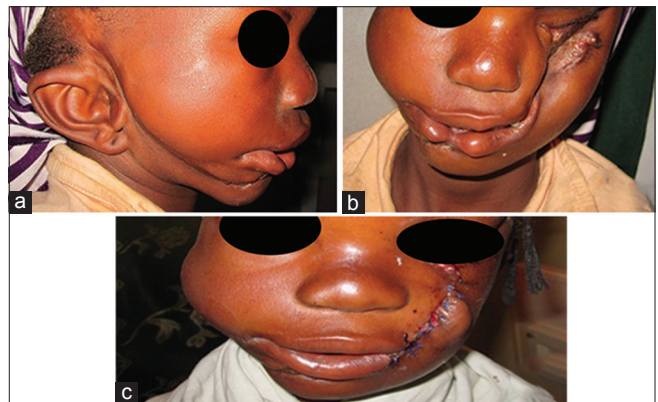
**Figure 1:** (a) Patient with median cleft of upper lip and nose with true orbital hypertelorism. (b) Immediate postoperative view of repaired median cleft lip



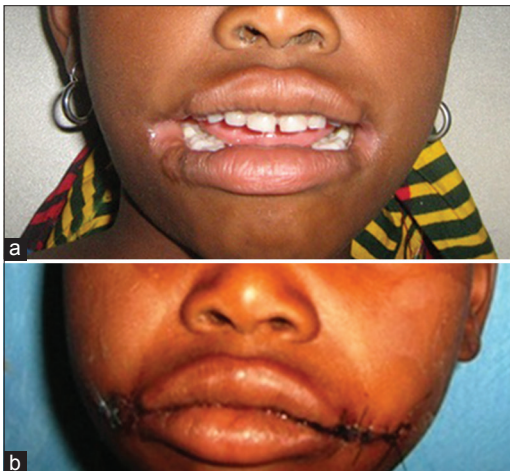**Figure 2:** (a) Patient with an incomplete median cleft of nose and lip and with lip incompetence. (b) The same patient with absence of cartilaginous nasal septum and columella. (c) Immediate postoperative view of repaired lip with improved lip competence



**Figure 3:** (a) Patient with incomplete median cleft lip, mild hypertelorism, absence columella, and cartilaginous part of nasal septum. (b) Same patient showing absence of cartilaginous part of nasal septum and columella. (c) Repaired upper lip and columella supported with a nasal stent



**Figure 4:** (a) Right dysmorphic ear, amniotic band, commissural cleft, and lower lip cleft. (b) Right dysmorphic ear with Left dysmorphic ear, amniotic band, commissural cleft, and lower lip cleft. (c) Postoperative photograph showing repaired oblique facial cleft, lower lip cleft, and right-sided commissural cleft

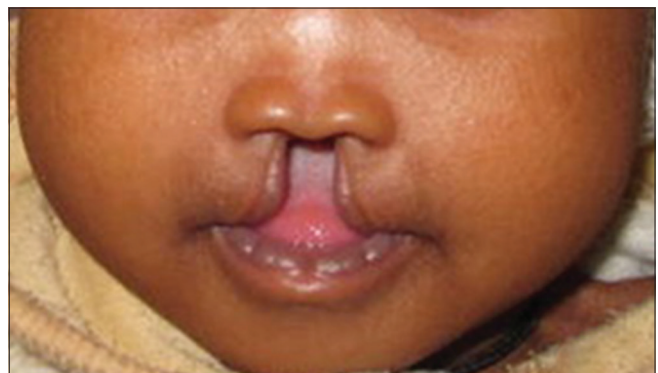

**Figure 5:** (a) Bilateral commissural cleft with accompanied macrostomia. (b) Postoperative view of repaired bilateral commissural cleft

was detected. A diagnosis of premaxillary agenesis type holoprosencephaly (HPE) was made; however, the patient was lost to follow-up. Therefore, no surgical repair could be done.

## DISCUSSION

Rare craniofacial clefts arise infrequently and may occur anywhere on the face. A total of 327 orofacial clefts



**Figure 6:** A 4-month-old child with premaxillary agenesis type holoprosencephaly

were seen in our center from May 2009 to May 2014, seven of these presented with atypical facial clefts. Our observation further highlights the rarity of this condition which is also in agreement with other similar studies



carried out by Kawamoto<sup>4</sup> and Iyun *et al.*<sup>6</sup> in Western Nigeria. Datubo-Brown<sup>7</sup> from Southern Nigeria made an observation of higher number of rare facial clefts among the population they studied and concluded that these atypical facial clefts had a higher proportion among all the orofacial clefts seen. However, this is contrary to our own observation in this study which clearly showed a very low proportion of rare facial clefts among all orofacial clefts. Therefore, the speculation by this author (Datubo-Brown) that atypical facial clefts may make up a higher proportion of all orofacial clefts in this Black populace (Nigeria) may not be absolutely true. However, the fact still remains the same that etiologies may be heterogeneous and prevalence may vary from one racial subgroup to others. Can we assumedly infer that the smaller series of orofacial clefts seen by the author (Datubo-Brown) influenced his result?

Median cleft (Tessier no 0) was most common in our series, followed by lateral cleft (Tessier no 7). Sieg *et al.*<sup>8</sup> in their study reported that lateral clefts to be the most common of the atypical facial clefts. They noted seven out of 14 cases of atypical facial cleft had lateral clefts (Tessier no 7), five oblique facial cleft (Tessier no 5), and three midline cleft (Tessier no 0). Iyun *et al.*<sup>6</sup> in their studies also observed lateral clefts as the most frequently occurring craniofacial cleft; however, in our series, midline cleft was found to be the most common, followed by lateral cleft. This observation shows that the pattern of presentation of rare craniofacial clefts may be heterogeneous in different study centers.

The first case in this present study was an adult that had characteristic features of frontonasal dysplasia (FND) which are bifid nose, broad nasal root, true orbital hypertelorism, and median cleft of upper lip. FND is a rare form of facial dysraphism that affects the midface. Clinically, it could be defined as the presence of two or more of the following clinical features: true orbital hypertelorism, broad nasal root, median cleft nose with or without median cleft of upper lip, occultum bifidum.<sup>9,10</sup> This patient [Figure 1] presented with more than two of aforementioned identifying features of FND, which thereby grouped him into it. Surprisingly, the demoniacal adult look caused by these facial anomalies gave him much attention in his domicile community because he was thought to possess a supernatural power. This eventually paved way for him to be selected as a youth leader of a leading political party in this Black continent (Nigeria). This shows a high level of ignorance, superstition, and poverty in this part of the country. The need for western education and public enlightenment campaign in this community cannot be overemphasized. To the best of our knowledge, this is the first adult FND to be reported in our country. Apart from this patient, two other ones had both lip and nasal defects (Cases 2 and 3). Their lip defects were successfully repaired by inverted V-shaped technique;

however, the nasal defects were yet to be corrected because of unavailability of adequate facilities to carry out such a highly skilled surgical repair. The need for advanced imaging technique is highly recognized, especially for the first patient that had an additional orbital hypertelorism, but such facilities were not yet available in a resource challenged setting like ours. An attempt was however made to improve the nasal contour of third patient by constructing the columella with internal nasal dorsal skin flap<sup>11</sup> and conchal cartilage which was harvested from left ear lobe. Rubber stents were inserted into the nostrils for more nasal support, but the patient was lost to follow-up which is a common practice among patients in this part of the country.

Apart from these patients, there were two others (Cases 3 and 4) that had both lip and nasal defects. Their lip defects were also successfully repaired by inverted V-shaped technique; however, their complex nasal anomalies were yet to be corrected because of inexperience of the cleft surgeons for such nasal reconstructive surgery. Therefore, the need for establishment of reconstructive craniofacial centers in the country with intensive training cannot be overemphasized. The findings of oblique facial cleft (Tessier no 5), right-sided commissural cleft (Tessier no 7), lower lip cleft (Tessier no 30) associated with irregularly distributed amniotic bands (ABs) on the facial region in Case 4 confirm a diagnosis of orofacial cleft associated with AB. It has been suggested that AB could be one of the etiological factors in the occurrence of atypical facial cleft.<sup>12</sup> The presence of a fibrous band at the base of the commissural cleft and the apex of V-shaped lower lip cleft is evidence that the slash effect of AB probably may have caused facial deformities in this patient. This particular case is a unique one because of the combination of three Tessier clefts presenting in a single patient (Tessier no 5, 7, and 30). The oblique, commissural, and lower lip clefts were repaired by direct apposition of adjoining soft tissues in layer, but the accompany orbital defects are yet to be corrected because a good advanced imaging technique is needed for this complex orbital surgery. This could not be provided in this rural-based hospital.

Cases 5 and 6 are bilateral commissural clefts with accompanied macrostomia. Cleft of the oral commissure is an uncommon malformation that results from incomplete mesenchymal merging of the mandibular and maxillary prominences of the first pharyngeal arch.<sup>13</sup> Z or W-plasty are techniques recommended by most authors<sup>14</sup> for the closure of commissural clefts, but it has been noticed that these geometric techniques may cause additional cutaneous scarring; therefore, the results have not always been cosmetically satisfactory.<sup>14</sup> Linear suturing technique<sup>15</sup> was then the preferred choice in repairing the commissural cleft in these presenting reports because of its simplicity. Furthermore, in repair of transverse facial cleft,

closure of the orbicularis oris muscular ring is the critical step in the procedure. Macrostomia was corrected and oral continence provided after surgical repair in these patients.

The facial anomalies such as premaxillary agenesis, median cleft lip, and ocular hypotelorism were observed in a 4-month-old patient (Case 7) suggested an impression of premaxillary agenesis facial type HPE even though CT scan of the brain was not done. HPE is a complex human brain malformation resulting from incomplete cleavage of the prosencephalon into right and hemispheres, occurring between 18<sup>th</sup> and 28<sup>th</sup> day of gestation.<sup>16</sup> DeMyer *et al.*<sup>17</sup> reported that premaxillary agenesis facial type is pathognomonic for HPE. Children with HPE often suffer from developmental delay, epilepsy, and feeding difficulties. The child had feeding problems which resulted in malnourishment and poor developmental growth. No surgical intervention was carried out on the patient because of lack of developmental potential and lost to follow-up.

## CONCLUSION

Atypical facial clefts often present with disfiguring facial deformities that may require a multidisciplinary approach for correction in experienced, skillful hands. The expertise needed for these complex reconstructive surgeries may not be readily available in some developing countries.

## Declaration of patient consent

The authors certify that they have obtained all appropriate patient consent forms. In the form the patient(s) has/have given his/her/their consent for his/her/their images and other clinical information to be reported in the journal. The patients understand that their names and initials will not be published and due efforts will be made to conceal their identity, but anonymity cannot be guaranteed.

## Financial support and sponsorship

Nil.

## Conflicts of interest

There are no conflicts of interest.

## REFERENCES

1. Eppley BL, van Aalst JA, Robey A, Havlik RJ, Sadove AM. The spectrum of orofacial clefting. *Plast Reconstr Surg* 2005;115:101e-14e.
2. Moore MH. Rare craniofacial clefts. *J Craniofac Surg* 1996;7:408-11.
3. Niemeijer MF, van der Meulen J. The genetics of craniofacial malformations. In: Stricker M, van der Meulen J, Rapale B, Mazzola R, editors. *Craniofacial Malformations*. London: Churchill Livingstone; 1990.
4. Kawamoto HK Jr. The kaleidoscopic world of rare craniofacial clefts: Order out of chaos (Tessier classification). *Clin Plast Surg* 1976;3:529-72.
5. Tessier P. Anatomical classification facial, cranio-facial and latero-facial clefts. *J Maxillofac Surg* 1976;4:69-92.
6. Iyem AO, Olusanya AA, Ademola SA, Akinmoladun VI, Olawoye OA. Rare craniofacial clefts in Ibadan. *J Niger Plast Surg* 2012;2:61-5.
7. Datubo-Brown DD. Craniofacial clefts in a black African population. *Cleft Palate J* 1989;26:339-43.
8. Sieg P, Hakim SG, Jacobsen HC, Saka B, Hermes D. Rare facial clefts: Treatment during charity missions in developing countries. *Plast Reconstr Surg* 2004;114:640-7.
9. DeMyer W. The median cleft face syndrome. Differential diagnosis of cranium bifidum occultum, hypertelorism, and median cleft nose, lip, and palate. *Neurology* 1967;17:961-71.
10. Sedano HO, Cohen MM Jr., Jirasek J, Gorlin RJ. Frontonasal dysplasia. *J Pediatr* 1970;76:906-13.
11. Bütow KW. Construction of the congenitally missing columella in midline clefts. *J Craniomaxillofac Surg* 2007;35:287-92.
12. Mayou BJ, Fenton OM. Oblique facial clefts caused by amniotic bands. *Plast Reconstr Surg* 1981;68:675-81.
13. Habal MB, Scheuerle J. Lateral facial clefts: Closure with W-plasty and implications of speech and language development. *Ann Plast Surg* 1983;11:182-7.
14. Rogers GF, Mulliken JB. Repair of transverse facial cleft in hemifacial microsomia: Long-term anthropometric evaluation of commissural symmetry. *Plast Reconstr Surg* 2007;120:728-37.
15. Aketa J, Nodai T, Kuga Y, Yamada N, Hirakawa M. A method for the repair of transverse facial clefts. *Cleft Palate J* 1980;17:245-8.
16. Shawky RM, Sadik DI. Holoprosencephaly; a report of 2 cases with different presentations. *Egypt J Med Hum Genet* 2008;2:249-56.
17. DeMyer W, Zeman W, Palmer CG. The face predicts the brain: Diagnostic significance of median facial anomalies for holoprosencephaly (arhinencephaly). *Pediatrics* 1964;34:256-63.