

Title: Brachial Plexus Neuropathies During the COVID-19 Pandemic: A Retrospective Case Series of 15 Patients in Critical Care

RUNNING HEAD: Brachial Plexus Neuropathies During COVID-19

ARTICLE TYPE: Original Research

TOC CATEGORY: COVID-19

Authors: Joel O'Sullivan, Caroline Miller, Jack Jeffrey, Dominic Power

C Miller, Physiotherapy Department, Queen Elizabeth Hospital, Birmingham, United Kingdom. School of Health Sciences, University of East Anglia, United Kingdom

J O'Sullivan, Physiotherapy Department, Therapy Services, Queen Elizabeth Hospital, North Suite, Level 1, Birmingham, UK B15 2GW. Address all correspondence to Mr O'Sullivan at: Joel.O'Sullivan@uhb.nhs.uk.

J Jeffrey, Physiotherapy Department, Queen Elizabeth Hospital.

DM Power, Birmingham Hand Centre, University Hospitals Birmingham, NHS Foundation Trust, Birmingham.

Keywords: Peripheral Nervous System Diseases, Anatomy: Upper Extremity: Shoulder, Anatomy: Upper Extremity: Arm, Anatomy: Upper Extremity: Hand

© The Author(s) 2020. Published by Oxford University Press on behalf of the American Physical Therapy Association. All rights reserved. For permissions, please email: journals.permissions@oup.com

Accepted Date: September 27, 2020

Submitted Date: July 10, 2020

Abstract

Objective. The utilization of the prone position to treat patients with COVID-19 pneumonia who are critically ill and mechanically ventilated is well documented. This case series reports the location, severity, and prevalence of focal peripheral nerve injuries involving the upper limb identified in an acute COVID-19 rehabilitation setting. The purpose of this study was to report observations and to explore the challenges in assessing these patients.

Methods. Participants were patients with suspected peripheral nerve injuries following discharge from COVID-19 critical care who were referred to the peripheral nerve injury multidisciplinary team. The patients studied had suspected peripheral nerve injuries following discharge from COVID-19 critical care and were referred to the peripheral nerve injury multidisciplinary team. Data were collected retrospectively on what peripheral neuropathies were observed, with reference to relevant investigation findings and proning history.

Results. During the first wave of the COVID-19 pandemic in the United Kingdom, 256 patients were admitted to COVID-19 critical care of Queen Elizabeth Hospital, Birmingham, United Kingdom. From March to June 2020, a total of 114 patients required prone ventilation. In this subgroup, a total of 15 patients were identified with clinical findings of peripheral nerve injuries within the upper limb. In total, 30 anatomical nerve injuries were recorded. The most commonly affected nerve was the ulnar nerve (12/30) followed by the

cords of the brachial plexus (10/30). Neuropathic pain and muscle wasting were identified, signifying a high-grade nerve injury.

Conclusion. Peripheral nerve injuries may be associated with prone positioning on intensive care units, although other mechanisms, such as those of a neuroinflammatory nature, cannot be excluded.

Impact. Proning-related upper limb peripheral nerve injuries are not discussed widely in the literature and may be an area of further consideration when critical care units review their proning protocols. Physical therapists treating these patients play a key part in the management of this group of patients by optimizing the positioning of patients during proning, making early identification of peripheral nerve injuries, providing rehabilitation interventions, and referring to specialist services if necessary.

Lay summary. During the COVID-19 pandemic, patients who are very ill may be placed for long periods of time on their stomach to improve their chances of survival. The potential consequences of prolonged time in this position are weakness and pain in the arms due to potential nerve damage. There are some recommended treatments to take care of these problems.

On December 31, 2019, China announced a cluster of novel pneumonia-like illness. As of this writing, the severe acute respiratory syndrome coronavirus 2 (SARS-CoV-2) pandemic has infected approximately 33.3 million people globally and has been responsible for over one million deaths.¹ Coronavirus 2019 (COVID-19) invades the respiratory mucosa and infects other cells, inducing a cytokine storm systemically.² Some patients progress rapidly with acute respiratory distress syndrome (ARDS)³ and supportive care in intensive care is the mainstay of treatment, with many patients needing intensive care treatment for many weeks.

One complication of critical care is polyneuropathy and critical illness myopathy involving both motor and sensory axons.⁴ Critical illness polyneuropathy and myopathy usually present as flaccid and symmetric paralysis.^{5,6} In addition to the presence of systemic neuropathies, focal neuropathies following long intensive care stays can be present due to direct compression or traction of the plexus, peripheral nerves, or arterial structures.

Proning has been shown to reduce mortality in ARDS⁷ and, with up to 42% of patients with COVID-19 developing ARDS,³ proning has been widely adopted in the recent epidemic. For all of its benefits, the prone position can be associated with various complications, including pressure sores and accidental injuries.⁸ Upper limb nerve injuries related to brachial plexus neuropathy are also associated with the prone position.⁹ Injury severity can vary widely from neurapraxia (conduction block), in which full recovery would be expected in up to 3 months, to more severe axonal injuries (high grade) for which incomplete recovery would be expected and which may require surgical intervention. To mitigate against complications associated with proning, numerous guidelines have been developed.^{10,11}

In this case series we describe the demographics, baseline comorbidities, presenting clinical tests in a series of patients in an inpatient COVID-19 acute rehabilitation ward who had symptoms of a peripheral nerve injury.

[H1]Methods

This study was conducted at the Queen Elizabeth Hospital, Birmingham (QEHB) in the United Kingdom. The QEHB is one of the largest single site hospitals in the UK, with the largest co-located critical care unit in Europe.

A referral pathway was implemented to improve rehabilitation of patients with upper limb dysfunction after infection with COVID-19. Allied health professionals working on rehabilitation wards at QEHB were asked to refer all patients with upper limb weakness, pain, or loss of sensation to the multidisciplinary peripheral nerve injury team. Members of the team at QEHB then assessed patients while they were in hospital.

Retrospectively, data were collected from the hospital's electronic Prescribing Information Communication System. Data included demographics, baseline comorbidities, results of clinical tests and working diagnosis. In addition, critical care specific data were also collected, including length of stay on critical care and frequency of proning. The clinical assessment outcomes included Medical Research Council (MRC) motor assessments of key muscles of the upper limb, assessment of sensory loss, presence of neuropathic pain (reports of burning, stinging, paresthesia in peripheral nerve distribution), and results of any neurophysiological tests or imaging. The nerve injury severity was defined by the clinical and electrophysiological data as high grade (complete axonopathy with paralysis), intermediate grade (axonopathy incomplete with paresis), and low grade (predominant neurapraxia / conduction block). Inclusion in the post-COVID-19 neuropathy group required paralysis or paresis +/- sensation loss in a specific peripheral nerve distribution.

This retrospective study was registered and approved by the University Hospitals Birmingham (UHB) National Health Service (NHS) Foundation Trust Clinical Audit

Registration Management System (CARMS-16211). Research ethics committee (REC) review was not sought or required for this project, due to the data capture being collected as part of normal clinical pathways. This was confirmed via completion of an NHS health research authority research decision tool, confirming that this project would not be deemed research by the NHS. Therefore, patient consent for holding anonymized data was not required.

[H1]Results

Between March and June 2020, 256 patients were admitted to COVID-19 critical care at the QEHB, Birmingham, United Kingdom. Thirty upper limb peripheral nerve injuries were identified in 15 patients in 21 limbs. Demographics and clinical findings are presented in Table 1. The mean age was 54.5 years (range = 39-69 y), and 12 (80%) of the patients were male. Comorbidities included hypertension (80%), type 2 diabetes mellitus (46%), and obesity (53%). All patients referred to the peripheral nerve injury team required critical care admission and were ventilated (at least in part) in a prone position on average 7.3 times (range = 2-15), with an average length of critical care stay of 32.5 days (Tab. 2). Hospital guidelines for managing all patients in the prone position were followed and positioned as per the Faculty of Intensive Care Medicine (FCIM) guidelines.¹² This entails careful positioning of the arms in the 'swimmers position'. This involves raising one arm on the same side to which the head is facing while placing the other arm by the patient's side. The shoulder should be abducted to 80 degrees and the elbow flexed 90 degrees on the raised arm. The patients are nursed in a 30 degrees reverse Trendelenburg position, with 2 hourly head and arm position changes. The guidelines suggest maintaining the prone position for 16 hours

and then returning to supine for 8 hours, alternating the position until the therapy is no longer indicated.

The most commonly injured nerve was the ulnar nerve (12/30) followed by the cords of the brachial plexus (11/30) (Tab. 2). All patients reported neuropathic pain, and all patients presented with motor weakness. Nerve conduction and electromyography studies (EMG) were performed in 14 (93%) patients during their inpatient stay. The timing of these studies varied. Additional investigations—such as magnetic resonance imaging of the shoulder, neck, plexus, and head; plain shoulder radiograph; and computed tomography—were performed in 5 (33%) patients. Three patients in our case series had evidence of a glenohumeral joint dislocation, which may account for axillary nerve and medial cord injuries seen.

[H1]Discussion

This study reports the demographics, clinical features, and neurophysiology for 15 patients presenting with 30 upper limb nerve injuries following step-down from COVID-19 critical care. All patients had significant muscle weakness and neuropathic pain suggesting high-grade nerve injuries. Thirteen patients (87%) presented with multiple nerve injuries within their upper limbs (range = 1-4). The majority of patients (9/15) had injuries involving the ulnar nerve at the cubital tunnel, with 3 of these patients having bilateral ulnar nerve symptoms. The next most common site of peripheral nerve injury was at the level of the cords in the infraclavicular brachial plexus (10/30). All patients presenting with upper limb peripheral nerve injuries had been treated with intermittent proning while ventilated during the course of their critical care management.

The presentation of ulnar nerve symptoms following long periods of proning in intensive care is not surprising and has previously been shown to account for up to one third of nerve

injuries associated with anesthesia.¹³ Furthermore, the ulnar nerve has been shown to be more sensitive to ischemia, when compared with the radial or median nerves.¹⁴

This is particularly important when considering that SARS coronavirus 2 infection is also known to cause microcirculatory disturbances. Heterogeneity of arm positioning when proning is apparent in the literature, and the FCIM proning guidelines¹² suggest that the elbow should be maintained at 90 degrees. This is, however, a potential stretch position for the ulnar nerve at the elbow.¹⁵ The safe proning checklist¹⁰ advise elbow flexion of 70 degrees; however, the images accompanying the checklist show elbow flexion at 90 degrees. In recent months, guidelines have recommended arm elevation under 70 degrees with the elbow in slight flexion.¹¹

Additionally, 2 of the 15 patients appear to have suffered axonopathy in the musculocutaneous nerve, with near complete motor loss and sensory impairment in the lateral cutaneous nerve of the forearm or the C6 dermatomal distribution. Prone positioning with inadvertent compression of the proximal, medial aspect of the arm, could conceivably directly injure the musculocutaneous nerve, the deep brachial artery (which supplies the radial nerve), and the brachial artery supplying the median and ulnar nerves.

The next most frequent presentation was injury to the cords of the brachial plexus. It is widely recognized that the abducted and lateral rotated position of the shoulder causes traction on all the infraclavicular plexus. Furthermore, the use of muscle relaxants removes protective muscle tone around the shoulder and inherently puts the glenohumeral joint at risk of subluxation/dislocation in this position. Other authors have linked large, high chest rolls with posterior shoulder displacement and resultant brachial plexopathy.¹⁶

The majority of the nerve injuries were high grade. Neuropathic pain, which was present in all patients is often a poor prognostic indicator for recovery because it indicates post–

ganglionic axonal disruption.¹⁷ In addition, most patients demonstrated muscle wasting and loss of muscle power 3 or 4 weeks following step-down from critical care. Finally, many of the electromyography studies reported spontaneous fibrillations, positive sharp waves, and fasciculations, which is indicative of active denervation and again suggestive of a more severe nerve injury with axonal injury.¹⁸ Outcome from an axonopathy is mixed and depends on both the severity of injury to the axons and the distance between the injury site and the sensory and/or motor target, but axonopathy can lead to significant and life-changing disability.¹⁹ It is possible that some of the low-grade injuries were missed or diagnosed as critical care myopathy.

Identification of a peripheral nerve injury is complex in patients recovering from COVID-19 stepped down from critical care. Numerous other differential diagnoses need to be considered following a significant length of stay on critical care and also with this particular coronavirus. In early recovery, we found that identification of a peripheral nerve injury was masked because of the presence of severe post critical illness myopathy and neuropathy, the most common cause of neuromuscular weakness in the intensive care setting.⁵ During rehabilitation, however, general weakness, stiffness, and pain in the upper limbs improved, and the peripheral nerve dysfunction became obvious. Delirium also brought additional challenges in managing these patients,²⁰ making our early assessment of suspected peripheral nerve injuries difficult.

Finally, it is clear that patients with coronaviruses can have both central and peripheral nervous system dysfunctions²¹ and, specifically, peripheral motor neuropathies in isolation.²² An inflammatory or autoimmune etiology, therefore, needs to be considered. Clues to the inflammatory etiology of the neuropathy sometimes can be available through the assessment of the timing of the neuropathy from the onset of the virus.²³ The timing is difficult to

ascertain in this group of patients who, on average, were 30 to 40 days since onset of the virus and were mostly sedated during that period.

Although this retrospective study included a small number of patients, it is valuable to highlight the complexity when providing rehabilitation to patients with COVID-19 on step-down from critical care. We were unable to extract data on the frequency of arm cycling while prone. However, there was clear evidence from electronic noting that these particular patients were critically ill and often repositioning had significant effects on their ventilation and was therefore limited. Future studies on frequency of arm cycling, prone episode duration, and cumulative time in the prone position could provide increased insight into the prone position on peripheral nerve injuries. Although nerve conduction studies were frequently carried out, some were performed in critical care where there were examination limitations and where polyneuromyopathy masked a peripheral nerve injury.

[H2]Implications

These early observations have important implications on both patient positioning in critical care, assessment and management of acute nerve injuries, and planning and allocation of rehabilitation resources. In critical care, sustained elbow flexion positions should be avoided when possible. Pressure on the elbows should be considered in relation to degree of elbow flexion and also direct compression, highlighting the need for potential padding around the medial elbow. Shoulder abduction/elevation should be maintained to less than 80 degrees and kept in the scapular plane when possible by the careful use of a pillow under the chest (covering the width of the chest without unduly compressing the proximal-medial arm), therefore also reducing the possibility of posterior shoulder displacement. Arms should be cycled every 2 hours when safe and feasible to do so. Side flexion of the neck should not be excessive.

Physical therapists are in a unique position to support with positioning in critical care and to identify and highlight patients with potential brachial or peripheral nerve injuries. Suspicion should be raised if a patient reports signs of neuropathic pain or loss of sensation in a peripheral nerve distribution or demonstrates focal muscle wasting or loss of power. Timely identification of nerve injuries enables baseline assessments to be conducted to ensure appropriate monitoring. It will also highlight the need for adaptations or specific strengthening and sensory relearning or motor patterning programs to be commenced to maximize rehabilitation potential.

Patient education on passive range of movement is a key part of management in addition to education on protection strategies, including advice on treatment of dry skin, education on how to avoid pressure areas, and positioning to avoid further ischemia on a recovering nerve. Local nerve entrapments such as ulnar neuropathy can be symptomatically improved by careful limb positioning. As recovery progresses, high-repetition, low-resistance functional exercises will limit fatigue but facilitate neural pathways.

The consequences of upper limb peripheral nerve injuries are potentially life changing and devastating.¹⁹ The patients included in this study were of working age, which has significant economic consequences; and many will need ongoing health care resources. During this recent pandemic there was increased demand on rehabilitation services but specifically on upper limb rehabilitation. Provision and planning for rehabilitation during future potential waves need to consider the need for these specialist rehabilitation pathways and potential training needs. Our center has produced an assessment guidance document that will support non-specialists to screen for injury (Figure). Those injuries that are deemed intermediate or high grade should be referred to a nerve service without delay.

Author Contributions

Concept/idea/research design: C. Miller, J. O'Sullivan, J. Jeffrey, D.M. Power

Writing: C. Miller, J. O'Sullivan, J. Jeffrey,

Data collection: C. Miller, J. O'Sullivan, J. Jeffrey, D.M. Power

Data analysis: C. Miller, J. O'Sullivan, J. Jeffrey,

Project management: C. Miller, J. O'Sullivan, J. Jeffrey,

Providing participants: C. Miller

Providing institutional liaisons: C. Miller

Consultation (including review of manuscript before submitting): C. Miller, J. O'Sullivan

Acknowledgments

The authors acknowledge the brilliant teamwork and dedication of QEHB staff during this unprecedented pandemic.

Ethics Approval

Research ethics committee (REC) review was not sought or required for this project, due to the data capture being collected as part of normal clinical pathways. This was confirmed via completion of a National Health Service health research authority (HRA) research decision tool, confirming that this project would not be deemed research by the NHS. Patient consent for holding anonymized data, therefore, was not required.

Funding

No funding was reported for this study.

Disclosures

The authors completed the ICMJE Form for Disclosure of Potential Conflicts of Interest and reported no conflicts of interest.

References

- [1] John Hopkins University. COVID-19 Dashboard by the Center for systems science and engineering (CSSE) at John Hopkins University. 2020. Accessed September 29, 2020. <https://coronavirus.jhu.edu/map.html>
- [2] Sun P, Qie S, Liu Z, et al. Clinical characteristics of hospitalized patients with SARS-CoV-2 infection: A single arm meta-analysis. *J Med Virol* 2020; 92: 612–617.
- [3] Wu C, Chen X, Cai Y, et al. Risk Factors Associated with Acute Respiratory Distress Syndrome and Death in Patients with Coronavirus Disease 2019 Pneumonia in Wuhan, China. *JAMA Intern Med*. Epub ahead of print 2020. DOI: 10.1001/jamainternmed.2020.0994.
- [4] Lacomis D. Neuromuscular disorders in critically ill patients: Review and update. *Journal of Clinical Neuromuscular Disease* 2011; 12: 197–218.
- [5] Shepherd S, Batra A, Lerner DP. Review of Critical Illness Myopathy and Neuropathy. *The Neurohospitalist* 2017; 7: 41–48.
- [6] Schmidt, S.B., Rollnik, J.D. Critical illness polyneuropathy (CIP) in neurological early rehabilitation: clinical and neurophysiological features. *BMC Neurol* **16**, 256 (2016). <https://doi.org/10.1186/s12883-016-0775-0>
- [7] Munshi L, Del Sorbo L, Adhikari NKJ, et al. Prone position for acute respiratory distress syndrome: a systematic review and meta-analysis. *Annals of the American Thoracic Society* 2017; 14: S280–S288.
- [8] McCormick J, Blackwood B. Nursing the ARDS patient in the prone position: the experience of qualified ICU nurses. *Intensive Crit Care Nurs* 2001; 17: 331–340.

- [9] Kwee MM, Ho YH, Rozen WM. The prone position during surgery and its complications: a systematic review and evidence-based guidelines. *International Surgery* 2015; 100: 292–303.
- [10] Oliveira VM, Piekala DM, Deponti GN, et al. Safe prone checklist: construction and implementation of a tool for performing the prone maneuver. *Rev Bras Ter Intensiva* 2017; 29: 131–141.
- [11] Quick TJ, Brown H. A commentary on Prone Position Plexopathy during the COVID-19 pandemic. *The transient journal of trauma, orthopaedics and coronavirus*. Accessed May 21, 2020. <https://www.boa.ac.uk/policy-engagement/journal-of-trauma-orthopaedics/journal-of-trauma-orthopaedics-and-coronavirus/a-commentary-on-prone-position-plexopathy.html>
- [12] The Faculty of Intensive Care Medicine. Guidance For: Prone Positioning in Adult Critical Care. 2019. Accessed June 4, 2020. https://www.ficm.ac.uk/sites/default/files/prone_position_in_adult_critical_care_2019.pdf
- [13] Kroll DA, Caplan RA, Posner K, et al. Nerve injury associated with anesthesia. *Anesthesiology* 1990; 73: 202–207.
- [14] Chung I, Glow JA, Dimopoulos V, et al. Upper-limb somatosensory evoked potential monitoring in lumbosacral spine surgery: a prognostic marker for position-related ulnar nerve injury. *Spine J*. 2009;9:287-295. doi:10.1016/j.spinee.2008.05.004
- [15] Bozentka D. Cubital Tunnel Syndrome Pathophysiology : Clinical Orthopaedics and Related Research®. *Clin Orthop Relat Res* 1998; 351: 90–94.
- [16] Goettler, C.E., Pryor, J.P. & Reilly, P.M. Brachial plexopathy after prone positioning. *Crit Care* 6, 540 (2002). <https://doi.org/10.1186/cc1823>

- [17] Truini A, Garcia-Larrea L, Cruccu G. Reappraising neuropathic pain in humans - How symptoms help disclose mechanisms. *Nat Rev Neurol* 2013; 9: 572–582.
- [18] Quan D, Bird S. Nerve conduction studies and electromyography in the evaluation of peripheral nerve injuries. *The university of Pennsylvania orthopaedic journal* 1999; 12:45-51
- [19] Miller C, Peek AL, Power D, et al. Psychological consequences of traumatic upper limb peripheral nerve injury: a systematic review. *Hand Ther* 2017; 22: 35–45.
- [20] Kotfis K, Williams Roberson S, Wilson JE, et al. COVID-19: ICU delirium management during SARS-CoV-2 pandemic. *Critical Care*; 24. Epub ahead of print 28 April 2020. DOI: 10.1186/s13054-020-02882-x.
- [21] Mao L, Jin H, Wang M, et al. Neurologic Manifestations of Hospitalized Patients with Coronavirus Disease 2019 in Wuhan, China. *JAMA Neurol*. Epub ahead of print 2020. DOI: 10.1001/jamaneurol.2020.1127.
- [22] Abdelnour L, Abdalla M, Babiker S. COVID 19 infection presenting as motor peripheral neuropathy. *J Formos Med Assoc*. Epub ahead of print April 2020. DOI: 10.1016/j.jfma.2020.04.024.
- [23] Van Alfen N, Van Engelen B. The Clinical Spectrum of Neuralgic Amyotrophy in 246 Cases - PubMed. *Brain* 2006; Feb: 438–50.

Table 1. Patient Specific Findings and Investigations^a

Patient	Age (y), Sex, and Affected Limb(s)	Comorbidities (HTN/T2DM/Obesity/Asthma)	Neuropathic Pain (Y/N)	Main Objective Findings— Motor (MRC scale)/ sensory/observations	No. of Nerve Injuries	Working Diagnosis	EMG Results	Nerve Injury Grade
1	60 Male Left	HTN T2DM	Y	<u>Motor-</u> <i>Left-</i> Biceps 0/5, Brachialis 0/5 <u>Sensory-</u> <i>Left-</i> Thumb and index 0/10	1	Left lateral cord injury	Spontaneous activity in the left C5/6 and C7 innervated muscles. These findings are not etiology specific	High
2	41 Female Bilateral	HTN T2DM Obesity	Y	<u>Motor-</u> <i>Right-</i> FPL 0/5, FDP (2/3) 0/5 <i>Left-</i> Biceps 0/5, Deltoid 0/5 Supraspinatus / infraspinatus 0/5 <u>Sensory-</u> <i>Right-</i> Thumb and index 0/10 <i>Left-</i> C5/6 dermatome 7/10	2	Right high median nerve injury Left upper trunk injury	Significant active denervation on left UL especially proximal muscles? upper plexus injury. Very severe CTS right side. Also evidence of critical care myoneuro	High

							pathy	
3	60 Male Left	HTN T2DM Obesity	Y	<u>Motor-</u> <i>Left-</i> Brachioradialis- 2/5, ECRL, ECRB 2/5, EDC- 0/5, EPL- 0/5 <u>Sensory-</u> <i>Left-</i> SRN- 0/10	2	Left posterior cord injury- RN & right medial cord injury- UN	Fibrillations and PSWs in left brachioradialis and EDC. Severe ulnar nerve dysfunction on right elbow. Also evidence of critical care myoneuro pathy	Interme diate / High
4	61 Male Right	HTN T2DM	Y	<u>Motor-</u> <i>Right-</i> Biceps 0/5, Brachialis 0/5, FDS 0/5, FDP (2/3) 0/5, FPL 0/5, intrinsic 0/5 <u>Sensory-</u> <i>Right-</i> LCNF 0/10 <u>Obs</u> <i>dry skin in hand</i>	2	Right medial and lateral cord injury	Fibs and PSWs in biceps, FDI and APB. Reported that studies compatibl e with an axonal injury to the right BP (lateral and medial cord)	High
5	42 Male Left	Obesity	Y	<u>Motor-</u> <i>Left-</i> Deltoid 0/5, SS 4/5, IS 4/5 Ulnar	2	Left axillar y nerve injury , left	Fibs and PSWs in Deltoid and left 1 st dorsal	High

				intrinsic 0/5 <i>Obs -Tinel sign at cubital tunnel</i>		UN injury (cubital tunnel)	interosseous	
6	69 Male Bilateral	HTN	Y	<u>Motor-</u> <i>Bilateral-Ulnar intrinsic 2/5</i> <u>Sensory-</u> <i>Bilateral- C8 reduced</i>	2	Bilateral UN injuries (cubital tunnel)	Significant fibrillations and PSWs in ulnar innervated muscles left worse than right on a background of polyneuropathy	High
7	50 Male Bilateral	HTN Obesity	Y	<u>Motor-</u> <i>Bilateral-FDP 3/5, FCU 3/5, Ulnar intrinsics 0/5</i> <i>Left- biceps weakness</i> <u>Obs-</u> <i>Bilateral Tinel sign at cubital tunnel</i>	3	Left lateral cord injury- MCN Bilateral UN injuries (cubital tunnel)	The findings are consistent with large fibre sensorimotor neuropathy. These are not aetiology specific.	High
8	59 Female Right	HTN T2DM Obesity	Y	<u>Motor-</u> <i>Right-Medial Pectoral 3/5, FCU 3/5, FDP(4-5) 3/5, Ulnar intrinsics 1/5</i> <u>Sensory-</u> <i>Right- MCNF 0/10</i>	2	Right medial and lateral cord injury	Marked focal lesion at the elbow segment of the right ulnar nerve	Intermediate / High

				<u>Obs-</u> wasting thenar & hypothenar eminence				
9	55 Male Left	HTN Obesity	Y	<u>Motor-</u> <i>Left-</i> EPL 0/5, EDC 0/5, ECRB 4/5, FDP(4-5) 4/5, Ulnar intrinsics 3/5 <u>Sensory-</u> <i>Left-</i> ulnar distribution of hand reduced <u>Obs-</u> ECU wasting	2	Left UN axonopathy (cubital tunnel) & high radial nerve injury	Inconclusive (technical)	High
10	60 Male Bilateral	HTN Obesity	Y	<u>Motor-</u> <i>Right-</i> Ulnar intrinsic 4/5 <i>Left-</i> Deltoid 0/5, Biceps 4/5 <u>Sensory-</u> <i>Right-</i> UN 1/10 <i>Left-</i> Ax 0/10 <u>Obs-</u> wasting of biceps & brachialis	2	Right UN injury (cubital tunnel) and left axillary nerve axonopathy	Nil conducted	Intermediate and High
11	41 Male Bilateral	HTN T2DM	Y	<u>Motor-</u> <i>Right-</i> Biceps 0/5, Ulnar intrinsic 4-/5 <i>Left-</i> Ulnar intrinsic 0/5, FDP(4-5) 1/5, general weakness of triceps, ECRL <u>Sensory-</u>	4	Right MCN injury, right UN injury (cubital tunnel) & Left posterior cord	Inconclusive-widespread axonal polyneuropathy-critical illness polyneuropathy	High

				<i>Left- Ulnar hand- 0/10</i> <u>Obs-</u> ulnar clawing Left hand		injury- RN, Left high UN axonopathy (cubital tunnel)		
12	57 Male Bilateral	Asthma	Y	<u>Motor-</u> <i>Right-</i> Biceps 0/5 <i>Left-</i> Ulnar intrinsics 0/5 <u>Sensory-</u> <i>Right-</i> Axillary nerve (Military badge) 0/10 <i>Left-</i> UN 0/10	2	Right MCN injury with left severe axonopathy of UN (cubital tunnel)	Inconclusive (timing)	High
13	59 Male Left	Nil	Y	<u>Motor-</u> <i>Left-</i> Trapezius 0/5 <u>Sensory-</u> <i>Left-</i> reduced C6 dermatome / SRN <u>Obs-</u> wasting trapezius & winged scapula	2	Left SAN injury, and? C6 dysfunction	Inconclusive (timing)	High
14	39 Male Right	HTN T2DM Obesity	Y	<u>Motor-</u> <i>Right-</i> Deltoid 0/5, Triceps 0/5, ECRL 3/5, ECRB 3/5, EDC 0/5, Ulnar intrinsics 0/5	2	Right posterior cord- RN injury & UN injury (cubita	Nil conducted	High

				Sensory- unable to assess		1 tunnel)		
15	64 Male Right	HTN	Y	<u>Motor-</u> <i>Right-</i> ADM and lumbrical weakness <u>Obs-</u> severe neuropathic pain C8 dermatome	1	UN / C8 injury	EMG showed denervati on in the right 1st dorsal interosseo us and EIP. EMG showed denervati on in the right C8 innervate d muscles.	High

^aADM = abductor digiti minimi; APB = abductor pollicis brevis; Ax = axillary nerve; BP = brachial plexus; CTS = carpal tunnel syndrome; ECRL = extensor carpi radialis longus; ECRB = extensor carpi radialis brevis; EDC = extensor digitorum communis; EIP = extensor indicis proprius; EPL = extensor pollicis longus; FCU = flexor carpi ulnaris; FDI = first dorsal interosseous; FDP = flexor digitorum profundus; Fibs = fibulations; FPL = flexor pollicis longus; HTN = hypertension; IS = infraspinatus; LCNF = lateral cutaneous nerve of forearm; MCN = musculocutaneous nerve; MCNF = medial cutaneous nerve of forearm; MRC scale = medical research council; Obs = observations; PSWs = positive short waves; RN = radial nerve; SAN = spinal accessory nerve; SRN = superficial radial nerve; SS = supraspinatus; T2DM = type 2 diabetes mellitus; UN = ulnar nerve.

Table 2 – Patient Demographics, Critical Care Data and Frequency of Nerve Injuries for Included Patients (n = 15) ^a

Patient Characteristics	Mean (Range)
Age (y)	54.5 (39-69)
Sex (male: female)	12 male / 3 female
Comorbidities present (%)	HTN – 80% T2DM – 46% Obesity – 53%
Critical care length of stay (days)	32.5 (20-46)
Number of times prone	7.3 (2-15)
Frequency of nerve injuries by anatomical location (n=30)_	
Upper trunk	1
Lateral cord	4
Posterior cord	3
Medial cord	3
Axillary nerve	2
Median nerve	1
Ulnar nerve	12
Radial nerve	1
Musculocutaneous nerve	2
Spinal accessory nerve	1

^aHTN = hypertension; = T2DM = type 2 diabetes mellitus.

Figure caption

Triage screening tool for COVID-19 critical care associated plexopathy and peripheral nerve injury

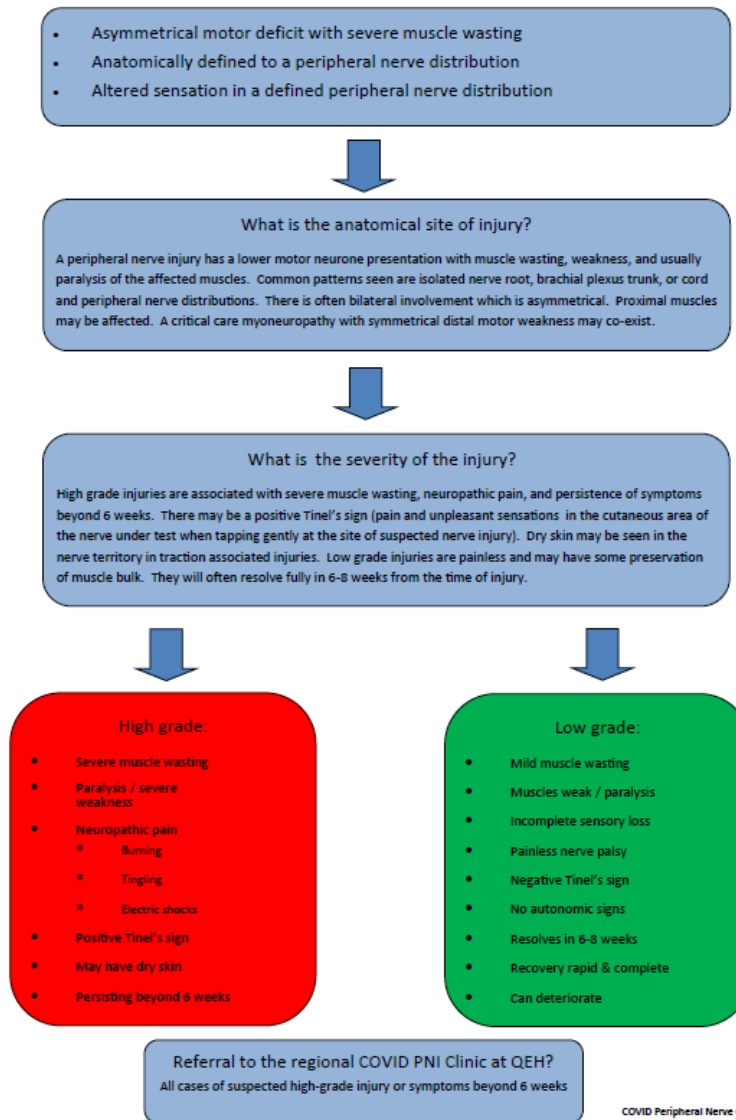


Figure. Screening tool for COVID19 critical care-associated plexopathy.