

Transfracture abduction osteotomy: A solution for nonunion of femoral neck fractures

Jairamchander Pingle

ABSTRACT

Background: Nonunion and avascular necrosis (AVN) of the femoral head remains one of the major complications following femoral neck fractures. Despite various surgical techniques and internal fixation devices, the incidence of nonunion and AVN has remained unsolved. Neglected nonunion of femoral neck fracture is common in the developing world. Treatment options include rigid internal fixation with or without bone grafting, muscle pedicle bone graft, valgus osteotomy of the proximal femur with or without bone graft, valgus osteotomy or hip arthroplasty. We conducted a retrospective analysis of cases of nonunion of femoral neck fracture treated by transfracture abduction osteotomy (TFAO).

Materials and Methods: Over a period of 35 years (1974-2008), 30 patients with nonunion of femoral neck fractures were treated with TFAO over a period of 35 years (1974-2008). All patients were less than 50 years of age. Absence of clinical and radiological signs of union after four months was considered as nonunion. Patients more than 50 years of age were excluded from the study. Union was assessed at 6 months radiologically. Limb length was measured at six months. The mean duration of femoral neck fracture was 19 months (range 4 months 10 years). Results were analyzed in terms of radiological union at six months. Average followup was five years and six months.

Results: Consistent union was noted at the followup after six months in 29 cases. One case was lost to followup after five and one-half months postoperatively. However, the fracture had united in this case at the last followup. Average shortening of the limb at six months was 1.9 cm. Average neck shaft angle was 127° (range 120-145°). Five cases went into AVN but were asymptomatic. Two cases required reoperation due to back out of Moore's pins. These were reopened and cancellous screws were inserted in the same tracks.

Conclusions: Consistent union of nonunion femoral neck fracture was noted at the followup after six months in 29 cases. The major drawback of the procedure is immobilization of the patient in the hip spica for eight weeks.

Key words: Femoral neck fracture, nonunion, transfracture abduction osteotomy

INTRODUCTION

Nonunion and avascular necrosis (AVN) have remained as the major complications following femoral neck fractures with a range of 10 to 20%.¹⁻³ Despite improvements in techniques of surgery and internal fixation devices, Neglected nonunion of femoral neck fracture is common in the developing world.^{1,2} Treatment options

include: Rigid internal fixation with or without bone grafting, muscle pedicle bone graft, valgus osteotomy of the proximal femur with or without bone graft, valgus osteotomy or hip arthroplasty.⁴ Pauwels believes that the fracture line (Pauwels' angle) has an important role in the union of fractures.⁵ The presence of shearing stress in fractures with vertical inclination increases the risk of nonunion. In these patients, change in the fracture line from a vertical to a horizontal orientation by an osteotomy usually results in healing.⁵⁻⁷ Valgus osteotomy is usually of the subtrochanteric or intertrochanteric type and is more efficient than displacement osteotomy in converting the shearing forces at the fracture site into compression forces, thereby improving chances of union.⁵

The traditional subtrochanteric or intertrochanteric osteotomies do not extend into the nonunion site of the fracture and hence, the fracture site cannot be freshened or bone grafted.⁷⁻⁹

We used transfracture abduction osteotomy (TFAO) as a solution for nonunions in the femoral neck fracture in children

Department of Orthopaedics, Apollo Health City, Jubilee Hills, Hyderabad, India

Address for Correspondence: Dr. Jairamchander Pingle,
8-2-293/82/A, Plot no. 1005, Road No 50, Jubilee hills, Hyderabad - 500 033, India.
E-mail: jairamchander1941@yahoo.co.uk

Access this article online

Quick Response Code:



Website:
www.ijoonline.com

DOI:
10.4103/0019-5413.125485

initially but later extended it as a treatment option even in adults (in subtrochanteric or intertrochanteric osteotomies), the apex of the osteotomy is below the neck of the femur and does not extend directly into the center of the nonunion site.⁷ In TFAO, the osteotomy is in the trochanteric region directly extending into the center of the fracture (nonunion) of the neck of femur. TFAO allows freshening of the nonunion site. Nonunion of the fracture of the neck of the femur comes in direct contact with the osteotomy. The osteotomized trochanteric bone is used as bone graft at the nonunion site. As the osteotomy is more proximal, the neck shaft angle is not disturbed and hence on closure of osteotomy, the hip is more anatomical. It also restores the valgus angle of the neck of the femur. We report a retrospective series of nonunion of the neck of femur treated by TFAO.

MATERIALS AND METHODS

30 consecutive patients with nonunion of femoral neck fracture were treated with TFAO over a period of 35 years (1974-2008). Age of the patients ranged from eight yrs to 45 yrs. There were 18 male patients and 12 female patients in this study. All patients more than 50 years of age and those who were unfit for the application of a hip spica for eight weeks were excluded.

Three patients came to us with a missed femoral neck fracture with treated and united ipsilateral fracture shaft femur. Six cases were neglected nonunions [Figures 1a-c, 2a-b], one case was nonunion secondary to osteomyelitis of the proximal femur [Figure 3a-e] and 20 cases were treated elsewhere with various modalities [Figure 4a-b, 5a-c, 6a-d] and subsequently went into nonunion.

Absence of clinical and radiological signs of union after four months was considered as nonunion.⁹ We operated on nonunions ranging from 4 months to 10 years duration.

Radiographs of both the hips were taken in anteroposterior and lateral views with the limbs in 10-15° of internal rotation. No special investigation other than X-rays was done to rule out AVN of head of femur. All the cases were operated after anesthesia clearance, under spinal/general anesthesia.

Operative procedure

The patient was placed on a fracture table. The fracture was reduced by traction and adduction [Figure 7a]. Through a lateral trochanteric approach, two parallel Moore's pins were passed through the trochanter into the superior half of the head of femur [Figure 7b]. Lateral closing wedge osteotomy based laterally was performed approximately 4 cm below directly opposite the nonunion site and parallel to the pins into the nonunion site [Figure 7c]. The proximal cut of osteotomy should be parallel to the proximal pins and the distal cut of the osteotomy should

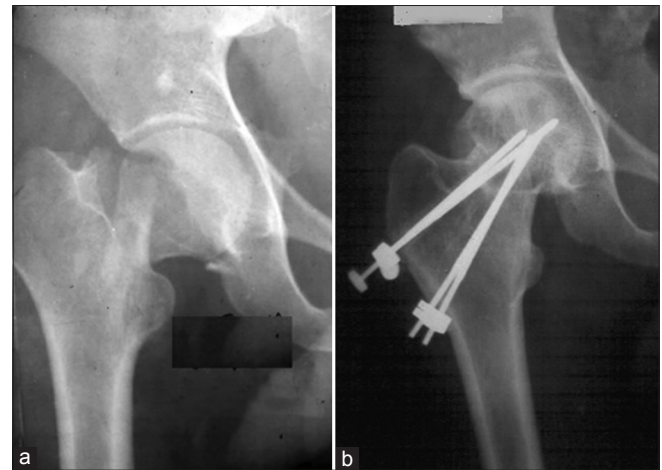

Figure 2: Radiograph of right hip joint of a 22 year old male showing (a) nonunion since one year; neck shaft angle 95°, (b) the status at five years followup showing; neck shaft angle 130° and union has been achieved

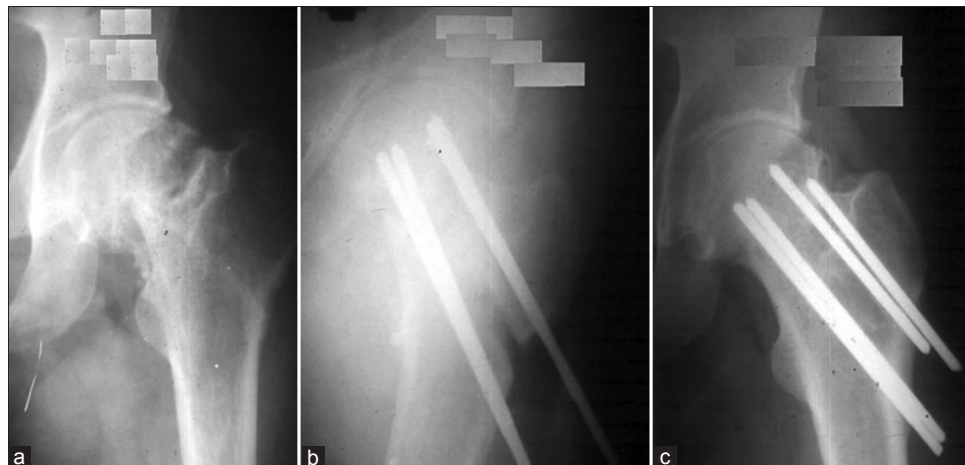

Figure 1: (a) Radiograph of left hip of 34 year old male patient with nonunion femoral neck fracture since four years, (b) treated with TFAO, (c) a postoperative followup X-ray at 12 months, excellent union achieved

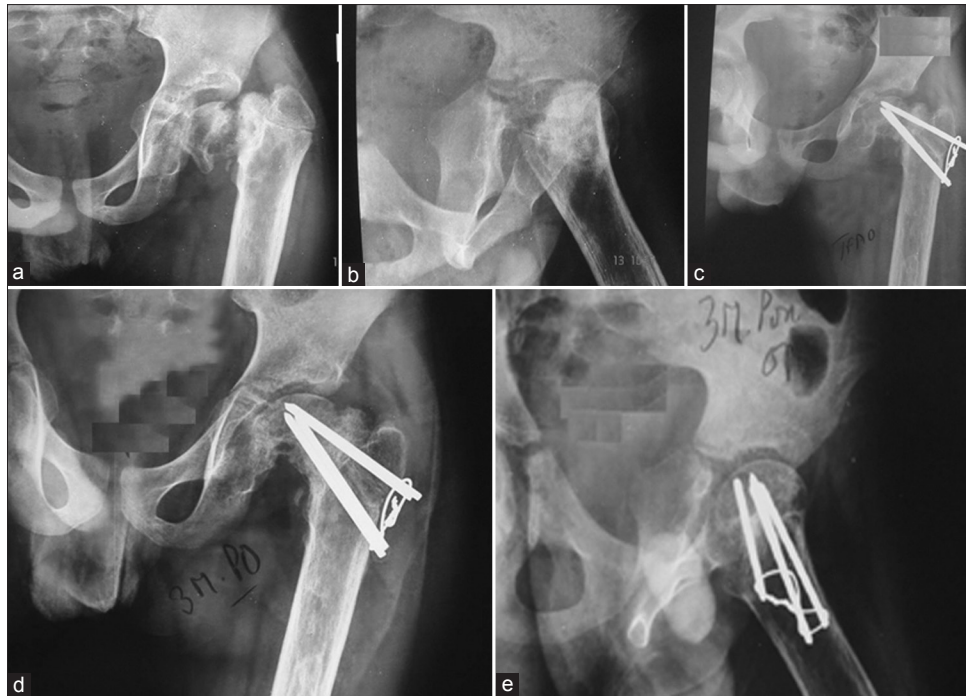


Figure 3: X-ray left hip joint anteroposterior and lateral views in an 11 year old male child showing (a,b) nonunion following sequel of chronic osteomyelitis, note the varus angle of neck of femur at 90°, (c) TFAO done (d) union achieved at three months postoperatively; neck shaft angle restored to 125° (e) lateral view at 3 months postoperatively showing union

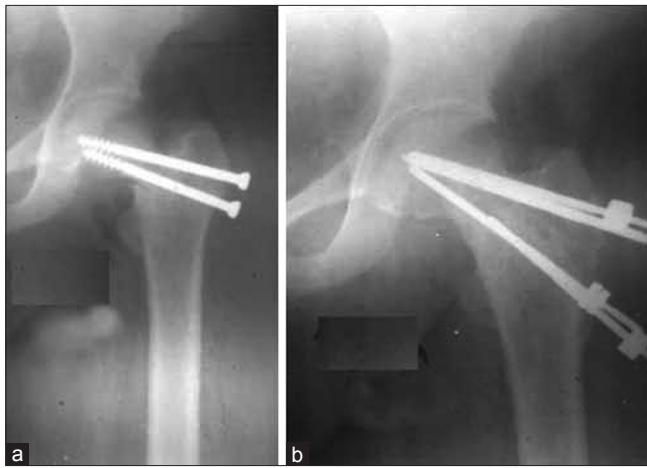


Figure 4: X-ray left hip joint anteroposterior view in a 30 year old lady showing (a) nonunion since six months, previously treated with cancellous screws; neck shaft angle is 105°, (b) a followup X-ray film at two years with good union and neck shaft angle restored to 136°

be angled to get the desired wedge laterally. Length of the wedge to be removed depends on the preoperative neck shaft (varus) angle. Generally in a long standing nonunion, it is difficult to calculate the neck shaft angle due to the resorption of the neck. Approximate length of the wedge is calculated under C-arm imaging after placing the patient on the fracture table and reducing the fracture with the hip in traction and adduction. Both proximal and distal osteotomies meet at the nonunion site. Through the osteotomy, the nonunion site is freshened and two Moore's

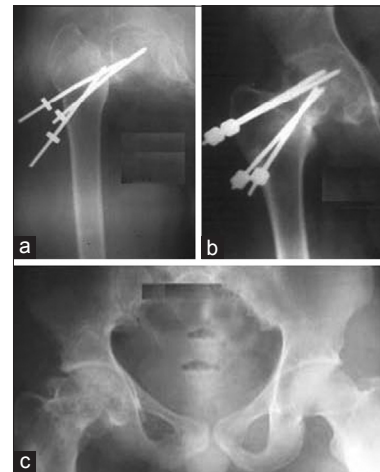


Figure 5: X-ray of right hip joint in a 16 year old male showing (a) nonunion of six months duration following failed Moore's pins *in situ*; neck shaft angle 85° in varus, (b) status at two years postoperatively, (c) status at 18 years postoperatively; there was 2" shortening with painless hip; neck shaft angle restored to 126°

pins were passed parallel and below the distal osteotomy into the femur (7d). The removed wedge of the cancellous bone was regrafted into the nonunion site. The osteotomy was closed by abducting the femur and thus the valgus angle was achieved (7e). The two distal parallel pins were then driven into the head of the femur and this keeps the osteotomy closed (7f). A hip spica was applied in 30° of abduction for eight weeks and after removal of the spica, partial weight bearing is allowed, gradually progressing to full weight bearing.

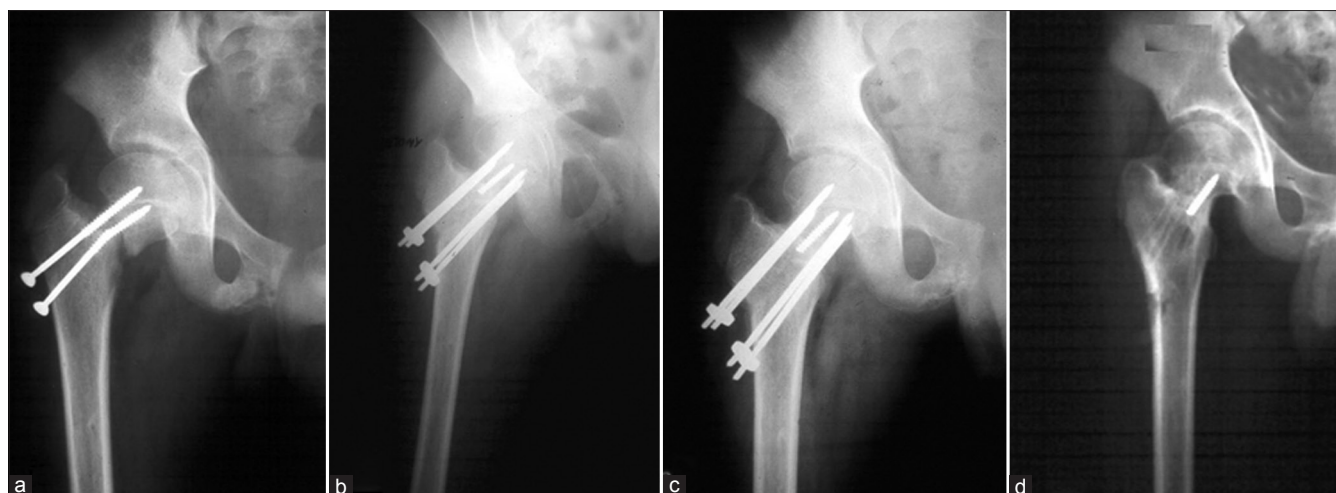

Figure 6: X-ray right hip joint in a 12 year old male child showing (a) nonunion since nine months; failed screws *in situ*; neck shaft angle 116°, (b) TFAO done, (c) seven months postoperatively, union achieved and neck shaft angle restored to 130°, (d) status at eight months after removal of implants

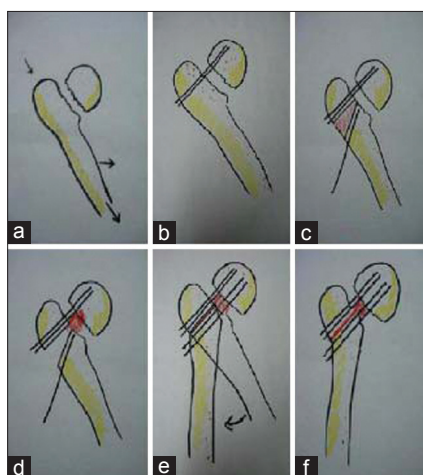


Figure 7: (a-f) Diagrammatic representation of the procedure

Serial check X-rays at two weeks, six weeks, 12 weeks and every four weeks were done till union is achieved.

RESULTS

Mean followup period was five years and six months (range 5.6 months - 33 years). The results were observed radiologically at the end of every month postoperatively for six months. Thereafter, radiographs were repeated every six months. At a followup after six months, measurements of limb lengths and neck shaft angle of both the affected and the normal lower limbs were taken. Consistent union of the nonunion of the neck of femur was noted at the followup after six months in 29 cases. One case was lost to followup after five and half months postoperatively [Table 1]. However, the fracture had united in this case at the last followup. The average shortening at six months was 1.9 cm (range 0 mm - 5 cm) [Table 2]. The neck shaft angle was measured at 6 months followup. The average neck shaft angle was 127° (range 120-145°).

Table 1: Duration of followup

Followup period	Number of cases
Less than six months	1
6 months to 1 year	5
1 year to 2 years	6
2 years to 5 years	7
5 years to 10 years	5
10 years to 20 years	4
More than 20 years	2

The average preoperative neck shaft angle was 105° (range 85-120°). Five cases had AVN of the femoral head but were asymptomatic. Two cases required reoperation (at a followup after six weeks in both cases) with cancellous screws due to back out of pins, which eventually united. The average period for union was four months (range 3-6 months).

There were five cases of AVN of the femoral head which were asymptomatic.

DISCUSSION

The advantage of TFAO over total hip replacement (THR) is that the femoral head of the patient is retained. There is significant cost-benefit ratio, with longevity of the hip and it is a good solution for young patients.

Benefits of TFAO over muscle pedicle graft are that there is minimal soft tissue dissection, requires less operating time, the anterior and posterior capsules of the hip are intact, hip stiffness is avoided and 100% union is achieved.

The success of the initial cases encouraged us to conduct a long term study on this procedure. In TFAO, the osteotomy extends directly into the center of the fracture site, whereas in subtrochanteric and intertrochanteric valgus osteotomies,

Table 2: Results of final followup

Results	Neck shaft angle	AVN	Shortening (cm)	Union (months)
1	126	N	1.5	3
2	122	N	2	4
3	145	N	0.0	3
4	120	N	2	4
5	136	N	1.5	3
6	130	N	1.4	5
7	121	N	5	6
8	130	N	3	4
9	127	Y	1.5	3
10	123	N	2	4
11	120	N	1.2	5
12	136	N	1.8	6
13	130	Y	2	4
14	129	N	1	3
15	121	N	1.5	4
16	124	N	2.5	3
17	131	N	1.7	6
18	124	Y	1	4
19	132	N	1.6	5
20	123	Y	2	6
21	125	N	2	4
22	131	N	1	3
23	122	N	1	5
24	130	N	1.4	4
25	123	Y	1.4	3
26	122	N	1.9	5
27	126	N	1.5	4
28	135	N	1	3
29	121	N	2	4
30	135	N	1	5
Mean	127		1.9	4

the osteotomy is essentially outside the neck of the femur. In TFAO, osteoinduction and osteoconduction are introduced directly into the nonunion site unlike the other osteotomies described for the treatment of nonunion fracture of the neck of femur.⁷⁻⁹ It also restores the valgus angle to the neck of femur. The goal of this reconstructive surgery is the restoration of normal anatomy which is accepted to be mechanically optimal for musculoskeletal function. The other advantage of this procedure is that in the future for any other reason, a THR can be done as this osteotomy does not alter the hip biomechanics. Though we have not done THR in any of the patients in this series, we believe that it can be done with ease.

Consistent union was achieved in this consecutive series of 30 cases of nonunion intracapsular fracture of the neck of the femur treated by TFAO.

The disadvantage of this procedure is that the patient has to be in hip spica for eight weeks, which requires proper counseling of the patient. Hip spica can be substituted with hip abduction brace. Careful preoperative assessment of the psychological and socioeconomic status of the patient is mandatory.

To conclude, the best end result after a femoral neck fracture is the healed femoral neck and head of the patient and this is achieved by a TFAO. Though this is a small series, the long term results of this procedure have been established and we believe that the results of this study justify the use of this conservative joint-preserving operation.

REFERENCES

1. Nagi ON, Dhillon MS, Goni VG. Open reduction, internal fixation and fibular autografting for neglected fracture of the femoral neck. *J Bone Joint Surg Br* 1998;80:798-804.
2. Roshan A, Ram S. The Neglected Femoral Neck Fracture in Young Adults: Review of a Challenging Problem. *Clin Med Res* 2008;6:33-9.
3. Gupta A. The management of ununited fractures of the femoral neck using internal fixation and muscle pedicle periosteal grafting. *J Bone Joint Surg Br* 2007;89:1482-7.
4. Canale ST, Campbell WC. *Campbell's Operative Orthopaedics*. 9th ed. St. Louis: Mosby; 1998. Chapter 52 delayed union or nonunion of fractures page No. 2611.
5. Pauwels F, der Schenkelhalsfraktur S. Late results of fractures of the neck of the femur. *Hefte Unfallbeikd*.1953;45:22.
6. Barnes B, Dunovan K. Functional outcomes after hip fracture. *Phys Ther* 1987;67:1675-9.
7. RK Marti, HM Schuller, EL Raaymakers. Intertrochanteric osteotomy for nonunion of the femoral neck. *J Bone Joint Surg Br* 1989;71:782-7.
8. Harrold AJ. Failure of union in fracture of the neck of the femur. *J Bone Joint Surg Br* 1960;42:226-35.
9. Harandi BA, Norouzi M. Treatment of the nonunion of the femoral neck by valgus osteotomy. *Arch Iranian Med* 2005;8:131-4.

How to cite this article: Pingle J. Transfracture abduction osteotomy: A solution for nonunion of femoral neck fractures. *Indian J Orthop* 2014;48:25-9.

Source of Support: Nil, **Conflict of Interest:** None.