

Horizontal Alveolar Ridge Augmentation with Xenogenic Block Grafts Compared with Autogenous Bone Block Grafts for Implant-retained Rehabilitation: a Systematic Review and Meta-Analysis

Jeppe Gronemann Christensen^{1,*}, Gustav Pors Grønlund^{1,*}, Signe Risom Georgi^{1,*}, Thomas Starch-Jensen², Niels Henrik Bruun³, Simon Storgård Jensen^{1,4}

¹Research Area Oral Surgery, Section for Oral Biology and Immunopathology, Department of Odontology, Faculty of Health and Medical Sciences, University of Copenhagen, Copenhagen, Denmark.

²Department of Oral and Maxillofacial Surgery, Aalborg University Hospital, Aalborg, Denmark.

³Unit of Clinical Biostatistics, Aalborg University Hospital, Aalborg, Denmark.

⁴Department of Oral and Maxillofacial Surgery, Copenhagen University Hospital, Copenhagen, Denmark.

*All authors contributed equally to the present study.

Corresponding Author:

Jeppe Gronemann Christensen

Section for Oral Biology and Immunopathology, Research Area: Oral Surgery

Department of Odontology

University of Copenhagen, Faculty of Health and Medical Sciences

Nørre Allé 20, DK-2200, Copenhagen

Denmark

Phone: +45 60 18 33 06

E-mail: jeppegronemann@gmail.com

ABSTRACT

Objectives: The objective of the present systematic review and meta-analysis was to test the 0-hypothesis of no difference in implant treatment outcome after horizontal alveolar ridge augmentation with xenogenic block compared with autogenous bone block.

Material and Methods: A literature search was conducted using PubMed, Embase and Cochrane Library databases in combination with a hand-search of relevant journals until 25th of January 2022. Comparative and non-comparative studies evaluating horizontal alveolar ridge augmentations with xenogenic blocks were included. Quality and risk of bias were evaluated by Cochrane Collaboration's revised tool and Newcastle-Ottawa scale.

Results: Meta-analysis revealed no statistically significant difference in implant survival rate after more than 6 months of functional implant loading ($P = 0.71$), no difference in alveolar ridge width ($P = 0.07$) or gain of alveolar ridge width at re-entry ($P = 0.13$). Non-comparative studies revealed moderate to high short-term implant survival rate and gain in alveolar ridge width, however, complications including dehiscences, graft exposure and graft failure were observed in several studies.

Conclusions: No significant difference could be identified in short-term implant treatment outcome following horizontal alveolar ridge augmentation using xenogenic block compared with autogenous bone block with the limited data available. A high incidence of healing complications and implant failures necessitates further investigation, as well as long-term results on implant survival rate.

Keywords: alveolar bone grafting; alveolar bone loss; alveolar ridge augmentation; bone substitutes; dental implants; review.

Accepted for publication: 29 June 2023

To cite this article:

Christensen JG, Grønlund GP, Georgi SR, Starch-Jensen T, Bruun NH, Jensen SS.

Horizontal Alveolar Ridge Augmentation with Xenogenic Block Grafts Compared with Autogenous Bone Block Grafts for Implant-retained Rehabilitation: a Systematic Review and Meta-Analysis

J Oral Maxillofac Res 2023;14(2):e1

URL: <http://www.ejomr.org/JOMR/archives/2023/2/e1/v14n2e1.pdf>

doi: [10.5037/jomr.2003.14201](https://doi.org/10.5037/jomr.2003.14201)

INTRODUCTION

Alveolar ridge deficiency following tooth loss or congenitally missing teeth can prevent rehabilitation with dental implants [1]. Horizontal alveolar ridge augmentation (HARA) may therefore be indicated to gain a sufficient alveolar ridge width to allow placement of implants of the desired dimensions in the correct three-dimensional position for the later prosthetic rehabilitation [2,3].

A variety of augmentation techniques and materials have been used to augment the horizontally deficient alveolar ridge [4]. These materials include autogenous bone from the same individual, allogenic bone from the same species but another individual, xenogeneic bone substitute materials of natural origin but from another species, and alloplastic materials of synthetic origin [5]. Autogenous bone blocks (ABB) in combination with a barrier membrane is considered the 'gold standard' for HARA procedures showing high survival rates of implants and suprastructures due to favourable osteogenic, osteoinductive and osteoconductive properties [5,6]. ABB can be harvested at intra- or extraoral donor sites. However, utilization of autogenous bone has the disadvantages of limited quantities, donor site morbidity, unpredictable resorption rates, and risk of injury to vital anatomic structures including permanent neurosensory disturbances [7,8]. Therefore, allogenic and xenogeneic bone substitutes have been suggested as alternatives for HARA [9,10].

Allogenic bone blocks (ALBB) solve the issue of harvest limitations and donor site morbidity and contains osteoinductive molecules. A recent systematic review documented high short-term implant survival rate after HARA using ALBB. However, an increased risk of biologic complications and late sequestrations at the recipient site was also reported [11]. These limitations underline the need for other alternatives to ABB.

Xenogeneic grafting materials are available as blocks and granules. Especially the granular form has been extensively evaluated in preclinical and clinical studies showing good biocompatibility, osteoconductive properties and minimal resorption [12-14]. Xenogeneic blocks (XB), primarily of equine or bovine origin, have been proposed as an alternative to xenogeneic granules to provide additional structural stability [15]. Utilization of XB may eliminate the limitations and complications associated with ABB harvesting and thus simplify the surgical procedure [16]. A recent systematic review evaluating clinical performance of XB compared with ABB in a variety

of bone defects, reported a similar gain in alveolar ridge width and block survival rate, but no data on implant survival rate after functional implant loading was presented [17].

The ultimate goal of HARA is to ensure predictability of the augmentation procedure and to be able to insert implants in a correct three-dimensional position and prosthetically load dental implants [18]. So far, no systematic reviews have evaluated implant survival rate following functional implant loading, when placed after HARA with XB.

Therefore, the primary objective of the present systematic review was to test the 0-hypothesis of no difference in implant treatment outcome after functional implant loading following horizontal alveolar ridge augmentation using xenogeneic blocks compared with autogenous bone blocks.

Secondarily, the possibility of placing implants following horizontal alveolar ridge augmentation, implant stability, peri-implant health, graft handling, and patient-reported outcome measures were recorded to further evaluate the applicability of xenogeneic blocks for clinical practice.

MATERIAL AND METHODS

Protocol and registration

This review was conducted in accordance with the Preferred Reporting Items for Systematic reviews and Meta-Analyses (PRISMA) statement for reporting systematic reviews [19].

Methods of the analysis and inclusion criteria were specified in advance, documented in a protocol, and registered in PROSPERO, an international prospective register of systematic reviews.

Registration number: CRD42022309532

The protocol can be accessed at:

https://www.crd.york.ac.uk/prospero/display_record.php?ID=CRD42022309532

Focus question

The focus question was developed according to the patient, intervention, comparison, outcome and study design (PICOS) framework as described in Table 1.

Types of outcome measures

Main outcome:

- Implant survival rate following HARA with a XB graft. Implant failure was defined as an implant that did not osseointegrate (early failure), mobility of previously clinically osseointegrated implant,

Table 1. PICOS guidelines

Patient and population (P)	Healthy adult patients (> 18 years) with a horizontal alveolar ridge deficiency following tooth loss or congenitally missing teeth in the maxilla and mandible not allowing placement of dental implants of the desired dimensions in the correct three-dimensional position for the later prosthetic rehabilitation.
Intervention (I)	Horizontal alveolar ridge augmentation with a xenogenic block.
Comparator or control group (C)	Horizontal alveolar ridge augmentation with an autogenous bone block graft.
Outcomes (O)	-Implant survival rate. -Complication rate prior to implant placement. -Possibility of placing an implant of sufficient dimensions and in the ideal three-dimensional position for the later placement of suprastructure. -Postoperative dimensional changes in width of the alveolar ridge. -Need for additional contour augmentation simultaneous with implant placement. -Complication rate after implant placement. -Alveolar ridge dimensions at implant placement. -Implant stability, peri-implant health, and graft handling. -Survival of suprastructure. -Patient-reported outcome measures.
Study design (S)	Randomized controlled trials, controlled trials, prospective case-series and retrospective studies assessing horizontal alveolar ridge augmentation with a xenogenic block graft compared with an autogenous bone block graft. Moreover, human studies solely assessing horizontal alveolar ridge augmentation with a xenogenic block graft will also be included as non-comparative studies.
Focused question	Are there any differences in implant survival rate following horizontal alveolar ridge augmentation with xenogenic block grafts compared with autogenous bone block grafts?

and removal of a non-mobile implant due to loss of grafting material, progressive peri-implant marginal bone loss or infection. Likewise, an osseointegrated implant upon which a functional suprastructure could not be placed due to malposition was considered a failure.

Additional outcomes:

- Complication rate prior to implant placement e.g., infections, dehiscences and sequestrations.
- Possibility of placing an implant of sufficient dimensions and in the ideal three-dimensional position for the later suprastructure.
- Postoperative dimensional changes in width of the alveolar ridge evaluated by radiographic or clinical measurements.
- Need for additional contour bone augmentation simultaneous with implant placement as evaluated radiographically and/or clinically. However, additional augmentation to allow implant placement was regarded as graft failure.
- Complication rate after implant placement e.g., infections, dehiscences, sequestrations.
- Implant stability evaluated by resonance frequency analysis, or percussion test.
- Health status of the peri-implant tissue as evaluated by clinical and radiographic measurements.
- Handling of graft material e.g., fracture of block during fixation.
- Survival of suprastructure.
- Patient-reported outcome measures.

Information sources

The search strategy included electronic databases, supplemented by a thorough hand-search of relevant journals. Electronic search in PubMed, Embase and Cochrane Library was performed until 25th of January 2022. Authors of ongoing studies included in the electronic search which fitted the inclusion criteria were contacted by email. Grey literature and other databases including Scopus, Google Scholar, or Research Gate were not included in the search strategy. The manual search also included the reference lists of all articles selected for full-text screening as well as previously published reviews relevant for the present systematic review.

Search

A combination of Medical Subject Headings (MeSH) and free text terms was used. Search strategy was performed in collaboration with a research librarian. A detailed description of the search strategy for all three databases is presented in Appendices 1 to 4.

Selection of studies

An overview of the selection process is presented in a PRISMA flowchart in Figure 1. Duplicates were removed and titles of identified reports were initially screened independently by two reviewers (S.R.G., J.G.C.). A third independent reviewer (G.P.G.)

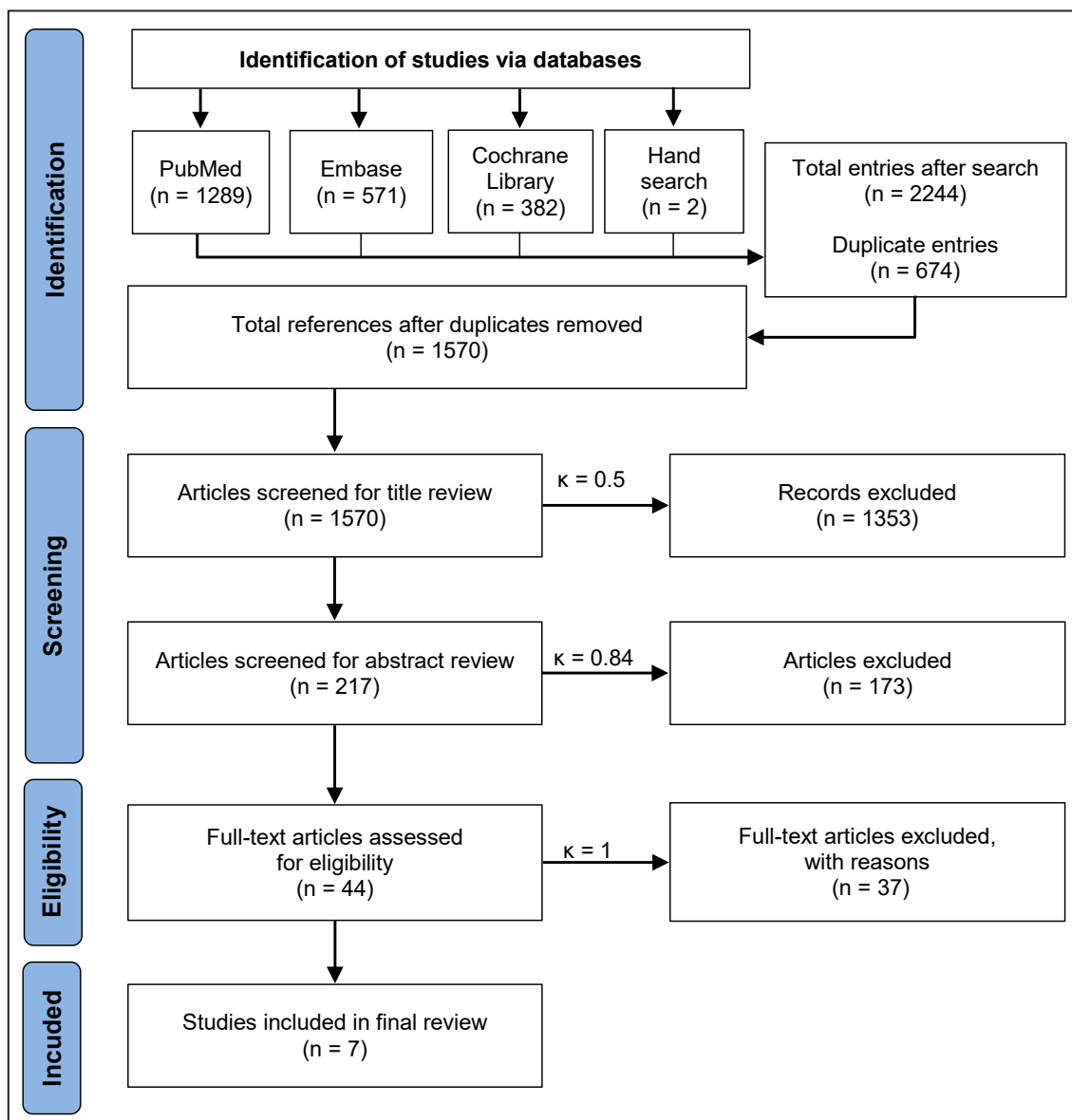


Figure 1. Flow diagram of studies selection according PRISMA guidelines.

solved disputes. Abstracts were assessed when titles indicated that the study was relevant. Abstracts were screened by two independent reviewers (J.G.C., G.P.G.) and disputes were solved by a third independent reviewer (S.R.G.). Full-text analysis was performed by two independent reviewers (S.R.G., G.P.G.) and there were no disputes. Reasons for exclusion after full text evaluation were recorded. Reviewers were calibrated before the screening process and inter-rater reliability Cohen’s kappa coefficient (κ) values were calculated for all screening steps [20].

Types of publications

Human studies published in English were included. Editorials, PhD theses, letters to the editor, case reports, abstracts, technical reports, conference

proceedings, cadaver studies, animal or *in vitro* studies and literature review papers were excluded.

Types of studies

Randomized controlled trials, controlled clinical trials and prospective case-series, assessing HARA with a XB graft compared with an ABB graft. Moreover, human non-comparative studies assessing HARA with XB graft were also included as non-comparative studies.

Types of participants

Healthy adult patients (> 18 years) with a horizontal alveolar ridge deficiency following tooth loss or congenitally missing teeth in the maxilla and mandible not allowing placement of dental

implants of the desired dimensions in the correct three-dimensional position for the later prosthetic rehabilitation.

Inclusion and exclusion criteria

Inclusion criteria

Studies assessing implant treatment outcome after HARA with XB were included by addressing the aforementioned outcome measures. Included studies were to have a reported minimum of six months follow-up period after functional implant loading. In addition, at least five patients should be included in the study and number of inserted implants and surgical procedures had to be clearly specified.

Exclusion criteria

Studies involving bone augmentation in medically compromised patients were excluded. Studies focusing on HARA solely for removable prosthodontics were excluded. Likewise, studies combining the grafting materials with growth factors, bone morphogenetic proteins, fibrin glue, platelet-rich plasma/fibrin, or other bioactive molecules were also excluded.

Data extraction

Data was extracted from each included study separately in accordance with the parameters listed above. In case of missing data on one or more parameters, the corresponding author was contacted by email.

Risk of bias

Assessment of quality and risk of bias was undertaken by three authors (J.G.C, G.P.G, and S.R.G) as part of the data extraction process. Cochrane Collaboration's revised tool for assessing the risk of bias (RoB 2), was applied for randomized controlled trials, as recommended in the The Cochrane Handbook for Systematic Reviews of Interventions [21]. Following five domains were evaluated for the randomized studies: bias arising from the randomization process, bias due to deviations from intended interventions, bias due to missing outcome data, bias in measurement of the outcome and bias in selection of the reported result. Publications were grouped into the following categories: low risk of bias, some concerns or high risk of bias [22].

The Newcastle-Ottawa scale was used to analyse bias for non-randomized studies to evaluate each included

study on selection of studies, comparability of cohorts and the ascertainment of either the exposure or outcome of interest. Stars were awarded with highest quality studies awarded up to nine stars. Following rating, the non-randomized studies were categorized as following: low-quality (0 to 3 stars), moderate quality (4 to 6 stars) and high quality (7 to 9 stars) [23].

Statistical analysis

Statistical software STATA version 17 (StataCorp LLC; Missouri, USA) was used for analysis. Random-effects meta-analyses were performed using the Sidik-Jonkman estimation method. The value of 0.5 was added to all cells of only those 2 x 2 tables that contain at least one zero cell. Forest plots and funnel plots were used to illustrate the results of the meta-analyses. Numerical values are presented as mean and standard deviation (M [SD]). $P < 0.05$ was considered statistically significant.

RESULTS

Study selection

A PRISMA flowchart illustrating the results of the systematic literature search is outlined in Figure 1. Electronic search resulted in 2242 entries. Two additional articles were identified through hand-searching. Of these, 674 duplicates were removed. Additional 1353 articles were excluded after screening of the titles. Six articles were excluded because abstract and full text could not be retrieved. A total of 217 abstracts were reviewed and full-text analysis included 44 articles. Seven studies were finally included [24-30]. Cohen's kappa coefficient (κ) values were calculated after each stage of screening. Title: $\kappa = 0.5$ - indicating moderate agreement; abstract: $\kappa = 0.84$ - indicating almost perfect agreement; full text review: $\kappa = 1.00$ - indicating perfect agreement [20].

Reasons for excluding 37 studies after full-text assessment were: studies not using a XB for augmentation, but solely particulate bone substitutes ($n = 15$) [31-45], ongoing studies ($n = 5$) [46-50], studies solely focusing on vertical alveolar ridge augmentation procedures or studies in which horizontal as well as vertical alveolar ridge augmentation were performed without the possibility of extracting data for HARA alone ($n = 4$) [51-54], studies including autogenous material in the XB group ($n = 2$) [55,56], study with insufficient follow-up time ($n = 1$) [57] studies evaluating

ridge augmentation at the time of, or after implant placement (n = 3) [58-60], studies reporting data from the same group of patients but with shorter follow-up (n = 2) [61,62], study on HARA as part of peri-implantitis treatment (n = 1) [63], study performing immediate implant placement (n = 1) [64], study not available in English (n = 1) [65], duplicate study as public title and scientific title did not match (n = 1) [66] and a study in which the graft type was not sufficiently specified (n = 1) [67].

Study characteristics

Detailed characteristics of the included studies are listed in Tables 2 and 3. Two comparative randomized controlled trials [24,25] and five non-comparative prospective case studies [26-30] were included. A total of 153 implants were placed in 123 patients. The studies included were published between 11 June 2009 and 14 July 2022.

Risk of bias within studies

Quality assessments of the included comparative studies are summarized in Table 4. Both included comparative studies in this systematic review showed high quality and low risk of bias regarding study design. However Romito et al. [24], reported as conflict of interest to have received research grants and lecture fees from the company which manufactured the XB used in the study.

The quality assessment of the included non-comparative studies is summarized in Table 5. All studies were rated as of moderate quality and were associated with a moderate risk of bias, as no control groups were used due to the nature of the study design. Four out of the five studies [26-28,30] reported to be fully or partially funded by the company manufacturing the XB used in the study.

Table 2. Randomized clinical trials on horizontal alveolar ridge augmentation with xenogenic bone block graft compared with autogenous bone block graft

Study	Year of publication	Study design	Number of patients	Recipient site	Graft type	Graft healing (weeks)	Number of implants	Implant healing (weeks)	Suprastructure
Romito et al. [24]	2022	RCT	32	Maxilla/mandible	ABB-MR (n = 32)	30	32	7	Single unit fixed dental prosthesis
			32		CXBB (n = 32)		32		
Lima et al. [25]	2018	SM-RCT	8	Maxilla	ABB-MR (n = 8)	26	8	17	Multiple unit fixed dental prosthesis
					CXBB (n = 8)		8		

RCT = randomized clinical trial; SM-RCT = split-mouth randomized clinical trial; CXBB = equine-derived collagenated xenogenic block; ABB-MR = autogenous bone block graft from mandibular ramus; n = number.

Table 3. Non-randomized clinical trials on horizontal alveolar ridge augmentation with xenogenic bone block graft

Study	Year of publication	Study design	Number of patients	Recipient site	Graft type	Graft healing (weeks)	Number of implants	Implant healing (weeks)	Suprastructure
Parvini et al. [26]	2021	PCS	16	Maxilla/mandible	CXBB (n = 16)	26	16	30	Single unit fixed dental prosthesis
Schwarz et al. [27]	2021	PCT	10	NR	CXBB (n = 10)	24	9	8 - 16	Single unit fixed dental prosthesis
Angermair et al. [28]	2020	PCT	5	Maxilla/mandible	CXBB (n = 10)	30	9	NR	NR
Di Stefano et al. [29]	2009	PCT	5	Mandible	CEEB (n = 5)	26	15	NR	Fixed dental prosthesis
Ortiz-Vigón et al. [30]	2018	PCT	15	Maxilla/mandible	CXBB (n = 28)	26	24	14 - 22	Single/multiple unit fixed dental prosthesis

PCS = prospective case series, PCT = prospective clinical trial, NR = not reported, CXBB = equine-derived collagenated xenogenic block, CEEB = collagen-preserving, enzyme-deantigenic, equine-derived bone blocks.

Table 4. Cochrane Collaboration’s revised tool for assessing risk of bias (RoB2)

	D1	D2	D3	D4	D5	Overall
Romito et al. [24]	⊕	⊕	⊕	⊕	⊕	⊕
Lima et al. [25]	⊕	⊕	⊕	⊕	⊕	⊕

D1 = bias arising from the randomization process; D2 = bias due to deviations from intended interventions; D3 = bias due to missing outcome data; D4 = bias in measurement of the outcome; D5 = bias in selection of the reported result.
 ⊕ = low risk of bias.

Results of individual studies

The results of the comparative studies assessing XB grafts compared with ABB grafts and of the non-comparative studies are presented below and outlined in Table 6 and 7, respectively. For each outcome measure, a summary is provided. Other parameters can be defined as: gain width (mm) - gain in alveolar ridge width at implant placement; additional augmentation (%) - need for additional augmentation procedure at the time of implant placement; possibility of implant placement (%) - possibility of placing an implant of sufficient dimensions and in the ideal three-dimensional position. Data obtained through personal communication with the corresponding authors are indicated in the tables.

Implant survival rate

Comparative studies

Survival of implants following HARA with either ABB or XB varied between 81 and 100% after a minimum of 6 months of functional implant loading [24,25]. A higher survival rate for the implants placed in ABB (91%) compared with XB (81%) has been reported in one study without statistical significance (P = 0.26) [24]. Another study found no difference in implant survival rate between ABB and XB (100%) [25].

Non-comparative studies

Survival of implants placed in alveolar ridges augmented with XB varied between 66 and 100% after 7 to 40 months of functional implant loading. Three studies reported a survival rate of 100% [26,27,29] and the remaining two studies found a survival rate of 66% [28] and 71% [30], respectively.

Analysis of failed implants in XB

Across the studies included in the present systematic

Table 5. Newcastle-Ottawa scale for assessing quality of non-randomized studies

	Selection	Comparability	Outcome	Score
Parvini et al. [26]	★★★★	☆☆	★★★	6/9
Schwarz et al. [27]	★★★★	☆☆	★★★	6/9
Angermair et al. [28]	★★★★	☆☆	★★★	6/9
Di Stefano et al. [29]	★★★★	☆☆	★★★	6/9
Ortiz-Vigón et al. [30]	★★★★	☆☆	★★★	6/9

0 to 3 stars = low-quality; 4 to 6 stars = moderate quality; 7 to 9 stars = high quality.

review [24-30], a total of 16 out of 113 (10.5%) implants failed during healing period, at re-entry surgery or after functional loading of the implants. The results show that 14 out of 16 (87.5%) of failed implants were placed in alveolar ridges with a baseline width < 4 mm.

Rate of complications prior to implant placement

Comparative studies

Rate of complications prior to implant placement was 0% for the ABB and XB group in one study [25]. In the other study 18.8% (n = 6) in both groups experienced soft tissue dehiscence during the healing phase following HARA. Most of the dehiscences were reported to be clinically insignificant small wound dehiscence without signs of graft exposure, infection, or inflammation. One dehiscence (3.1%) was associated with graft exposure (XB group) in which the graft failed to integrate, and no implant could be placed [24].

Non-comparative studies

Rate of complications prior to implant placement varied between 0 and 70% across the non-comparative studies. Soft tissue dehiscences were reported in two studies with incidences varying between 6.3 and 70% [26,27]. Graft exposure was reported in two studies with incidences of 33% [30] and 40% [27]. In both studies, repeated re-contouring of the grafts were performed to allow soft tissue healing. One adverse event in terms of an allergic reaction was reported in one patient (6.7%) resulting in exclusion of the patient from the study [30]. One XB block (3.6%) showed insufficient stability at re-entry and was removed [28].

Table 6. Outcomes: horizontal alveolar ridge augmentation with xenogenic bone block graft compared with autogenous bone block graft

Study	Number of patients	Graft type	Number of implants	Baseline width (mm)	Complications prior to implant placement (%)	Gain width (mm)	Additional augmentation (%)	Possibility of implant placement (%)	Complications after implant placement (%)	Survival of implants 6 months after loading (%)
				Mean (SD)		Mean (SD)				
Romito et al. [24]	32	ABB-MR (n ≥ 32)	32	Clinically: 2.95 (0.76)	18.8	Clinically: 3.51 (1.23)	10	100	21.9	91 ^a
	32	CXBB (n ≥ 32)	32	Clinically: 2.65 (0.69)	18.8	Clinically: 3.69 (1.55)	13.3	96.7	12.5	81 ^a
Lima et al. [25]	8	ABB-MR (n = 8)	8	Clinically: 3.4 (1.7)	0	Clinically: 4 (1.6)	0	100	0	100 ^a
				Radiographically: 3.7 (1.6)		Radiographically: 4.1 (1.8)				
	8	CXBB (n = 8)	8	Clinically: 3.3 (1.6)	0	Clinically: 5.6 (1.5)	0	100	0	100 ^a
				Radiographically: 3.6 (1.4)		Radiographically: 5.7 (1.6)				

^ainformation provided by the author after personal contact.

ABB-MR = autogenous bone block graft from mandibular ramus; CXBB = equine-derived collagenated xenogenic block.

Table 7. Outcomes: horizontal alveolar ridge augmentation with xenogenic bone block graft

Study	Number of patients	Graft type	Number of implants	Baseline width (mm)	Complications prior to implant placement (%)	Gain width (mm)	Additional augmentation (%)	Possibility of implant placement (%)	Complications after implant placement (%)	Survival of implants 6 months after loading (%)
				Mean (SD)		Mean (SD)				
Parvini et al. [26]	16	CXBB (n = 16)	16	Clinically: 3.68 (0.81)	6.3	Clinically: 5.09 (1.07)	12.5	100	0	100
Schwarz et al. [27]	10	CXBB (n = 10)	9	Clinically: 4.18 (0.92)	70	Clinically: 3 (2.2)	0	80	NS	100
Angermair et al. [28]	5	CXBB (n = 10)	9	Clinically: 3.5 (0.7)	10	Clinically: 3.6 (1.2)	0	90	66.7	66
Di Stefano et al. [29]	5	CEEB (n = 5)	15	Radiographically: 3.86 (0.13)	0	Radiographically: 3.28 (0.15)	0	100	0	100
Ortiz-Vigón et al. [30]	15	CXBB (n = 28)	24	Radiographically: 2.78 (0.55)	40	Radiographically: 4.12 (1.32)	15.4	86.7	0 ^a	71 ^a

^ainformation provided by the author after personal contact.

CXBB = equine-derived collagenated xenogenic block; CEEB = collagen-preserving, enzyme-deantigenic; equine-derived bone blocks; NS = not specified.

Possibility of placing implants in ideal three-dimensional position

Comparative studies

One of 32 patients (3.1%) in the XB group did not receive an implant due to graft integration failure, otherwise all implants could be placed as intended [24]. The need for additional contour augmentation at the time of implant placement was reported in both studies [24,25]. In one study, no need for additional augmentation was reported [25]. In the other study, 10% in the autogenous group and 13.3% in the XB group needed additional contour augmentation at the time of implant placement ($P = 1.00$) [24].

Non-comparative studies

The possibility of placing an implant at the augmented sites ranged from 80 to 100%. In two studies, additional contour augmentation at the time of implant placement was indicated in 12.5% [26] and 15.4% [30] of the patients, respectively. Three studies reported no need for additional contour augmentation at the time of implant placement [27-29]. However, in one of these studies [27], insufficient gain in alveolar ridged width excluded implant placement in 20% of the patients and were therefore regarded as graft failures.

Rate of complications after implant placement

Comparative studies

Complications after implant placement were reported to occur in 21.9% of the patients receiving ABB and 12.5% in the patients receiving XB [24]. Most of these were reported to be clinically insignificant small wound dehiscences without signs of graft exposure or infection.

Non-comparative studies

Rate of complications following implant placement varied between 0 and 66.7%. Small soft tissue dehiscence was reported with incidences of at least 20% of patients in one study, however the authors failed to specify if the complications were after implant placement or in relation to patients receiving additional augmentation [27]. In another study, soft tissue dehiscence was reported in 66.7% of grafted sites, most of which (83.3%) led to removal of the graft alone or along with the inserted implants due to graft exposure or sequestration of the blocks [28].

Implant stability, peri-implant health, graft handling and survival of suprastructure

Comparative studies

Peak torque at implant placement was significantly higher ($P = 0.004$) when the implants were placed in ABB grafts (32 ± 22 Ncm) compared with XB (18 ± 9 Ncm) [25].

Non-comparative studies

The peri-implant health, including plaque index, bleeding on probing, probing depth and mucosal recession were evaluated in two studies [26,27]. However, no clinically significant changes were reported between visits during the observation period of up to 724 days after implant placement. The placement of implants was associated with insufficient rotational stability in four patients (25%), necessitating a submerged healing procedure in one study [26]. Screw fixation of the XB graft resulted in fracture of 70% of the blocks in one study in which case the blocks were replaced [28]. Another study reported no fixation issues with handling of the graft material [29].

No data was reported in either of the studies regarding the survival of suprastructure.

Patient-reported outcome measures

Comparative studies

Post-operative pain (measured with VAS) and postoperative consumption of analgesic medication at different intervals were significantly lower ($P = 0.0226$) for the XB group compared with the ABB group as reported in one study [24]. In the same study, OHIP-14 scores conducted at the day of surgery and the 28th postoperative day failed to demonstrate any significant differences between the XB and ABB groups.

Non-comparative studies

No specified patient-reported outcome measures (PROMs) were reported in any of the non-comparative studies, however two studies mentioned that no patients reported postoperative pain [28,29]. Seven patients (70%) reported at least one adverse event, none of which was classified as being related to the xenogenic graft material, but one as possibly being related to the augmentation procedure in another study [27].

Meta-analysis

The results of the meta-analysis are illustrated in forest and funnel plots (Figures 2 - 7) [24,25]. Reported numerical values are presented as weighted mean values.

Implant survival

Implant survival rates after HARA with XB and ABB after a minimum of 6 months of functional implant loading were 85 and 92.5% respectively (P = 0.71) (Figures 2 and 3).

Gain in alveolar ridge from baseline to re-entry

HARA using XB, and ABB resulted in a mean increase in alveolar ridge width of 4.36 (SD 1.53) mm and 3.69 (SD 1.43) mm, respectively (P = 0.13) (Figures 4 and 5).

Alveolar ridge width at implant placement

At re-entry for implant placement, the mean alveolar ridge width after HARA with XB and ABB was 7.36 (SD 1.48) mm and 6.84 (SD 1.49) mm, respectively (P = 0.07) (Figures 6 and 7).

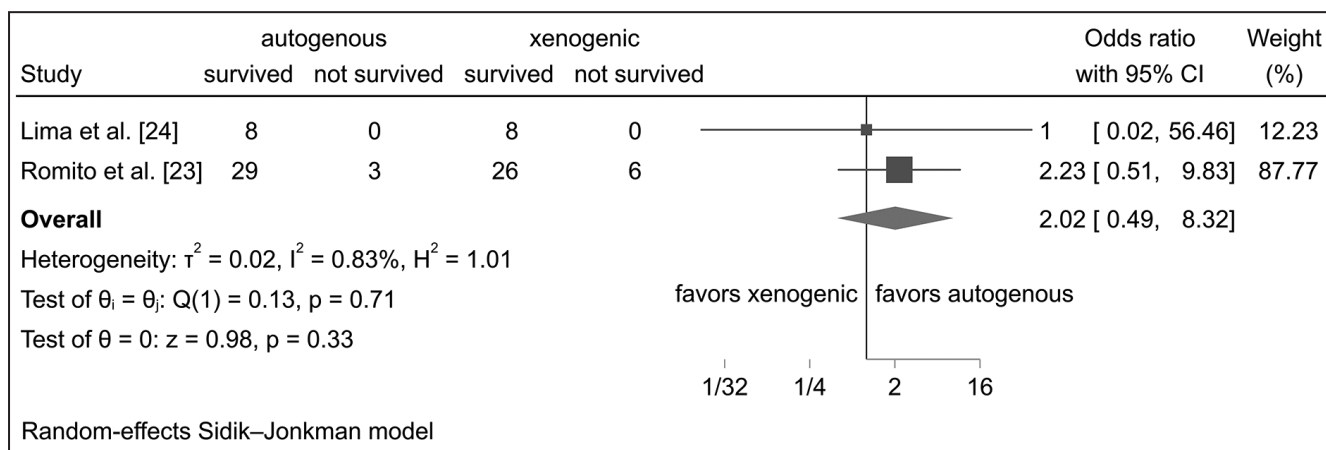


Figure 2. Forest plot implant survival. CI = confidence interval.

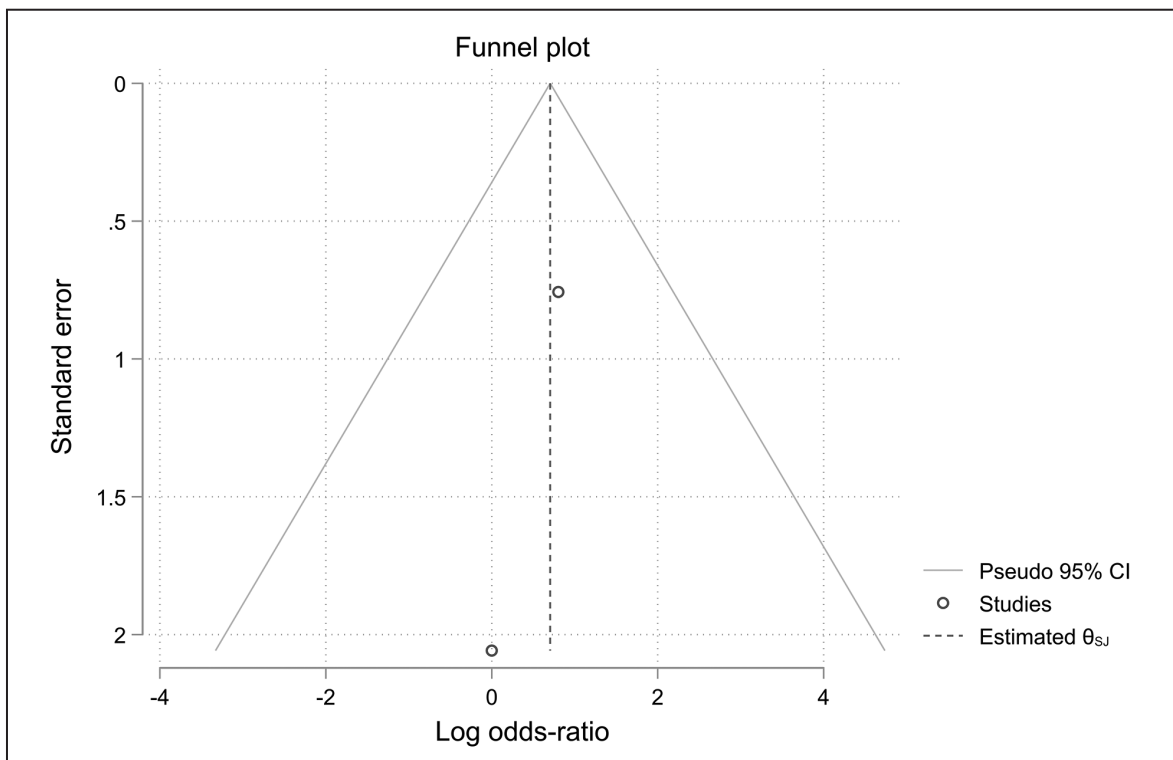


Figure 3. Funnel plot implant survival. CI = confidence interval.

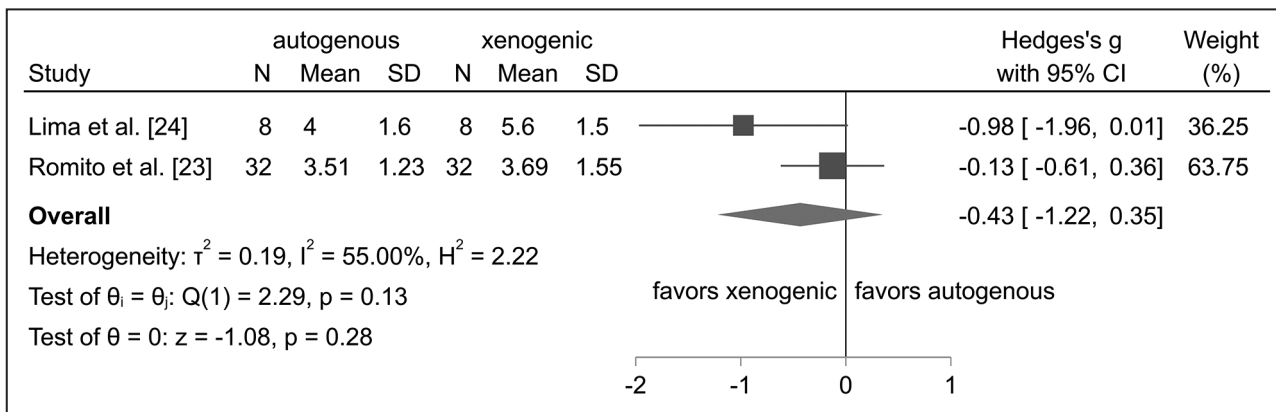


Figure 4. Forest plot gain in alveolar ridge width at re-entry. N = number; SD = standard deviation; CI = confidence interval.

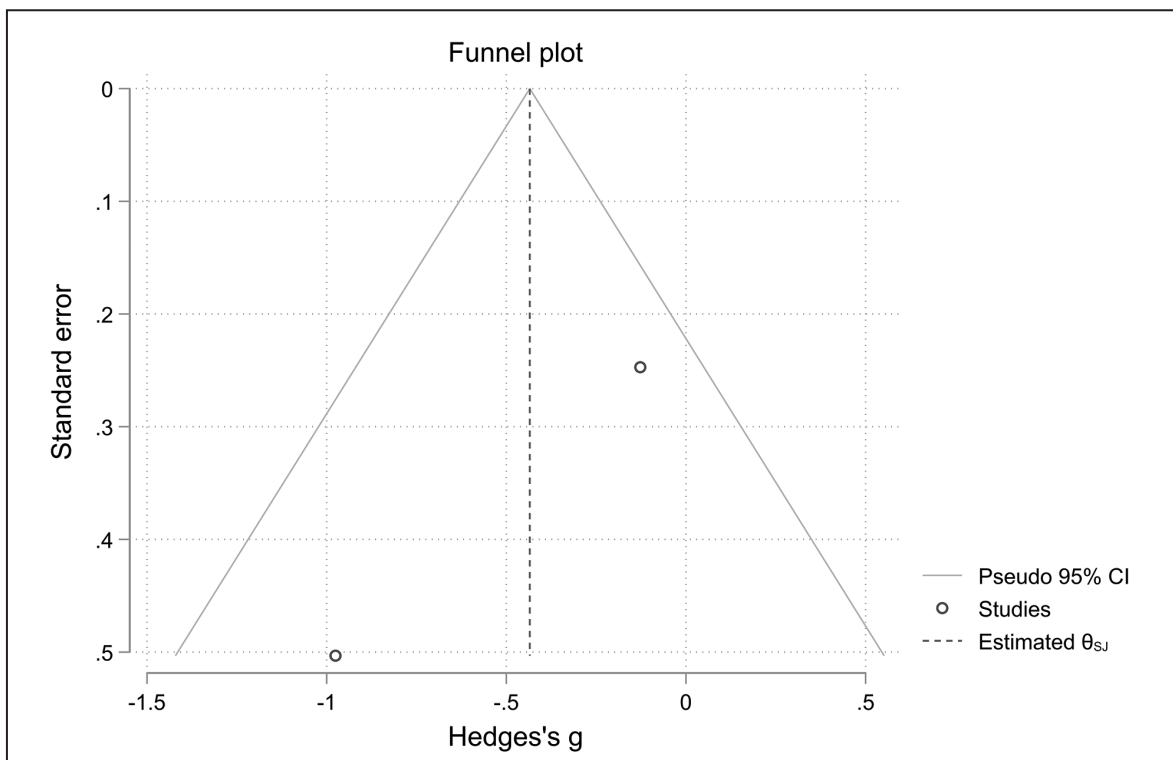


Figure 5. Funnel plot gain in alveolar ridge width at re-entry. CI = confidence interval.

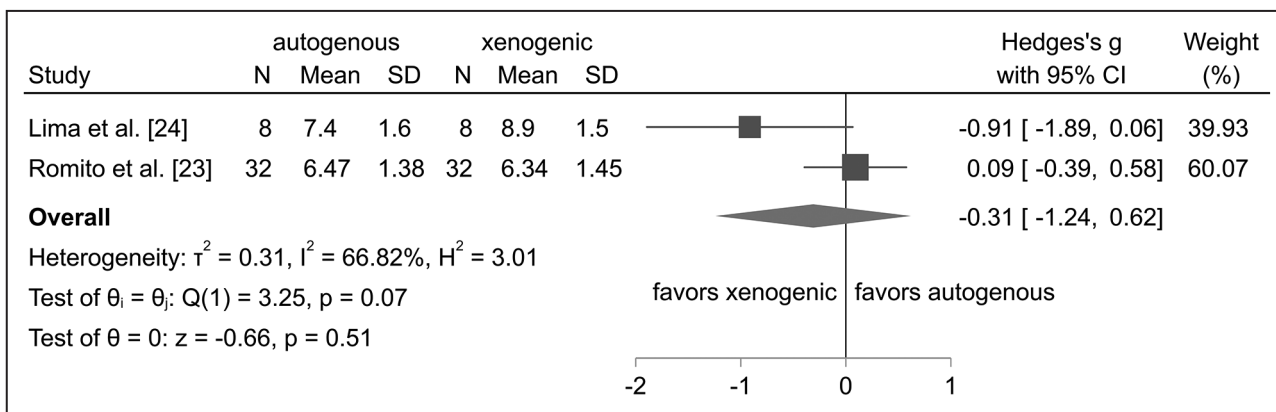


Figure 6. Forest plot alveolar ridge width at implant placement. N = number; SD = standard deviation; CI = confidence interval.

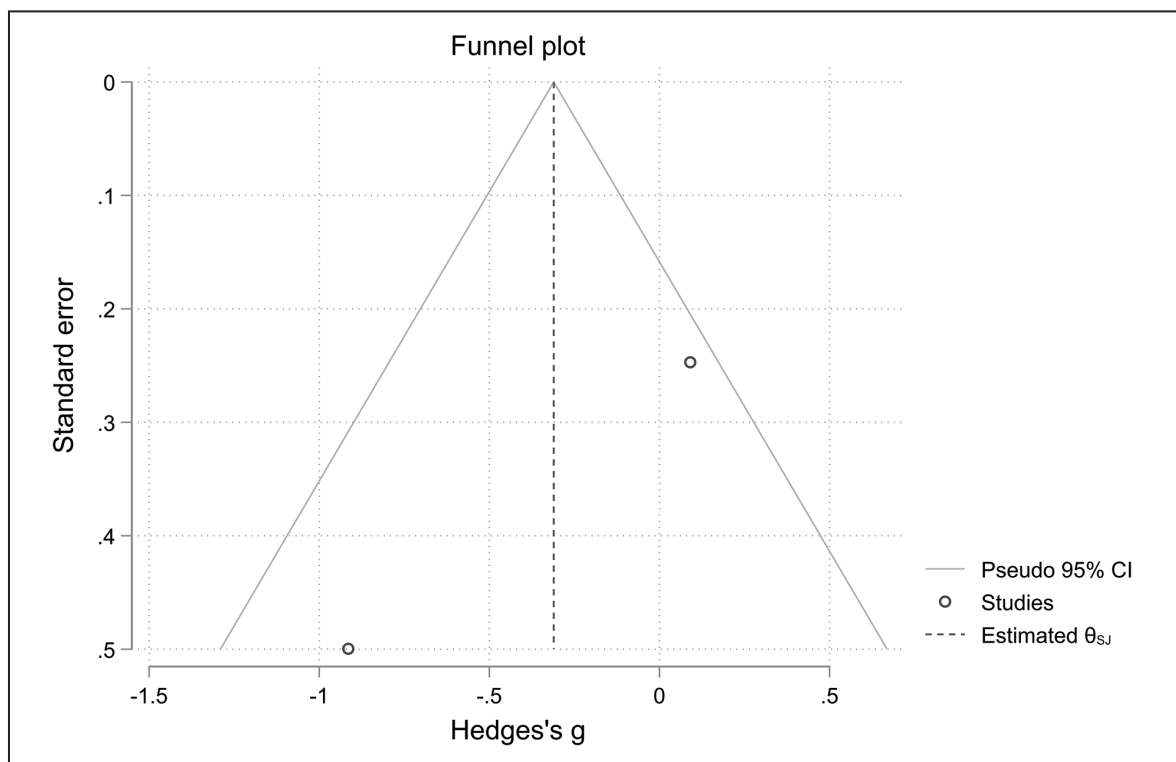


Figure 7. Funnel plot alveolar ridge width at implant placement. CI = confidence interval.

Synthesis of results

Two comparative studies with high quality and low risk of bias and five non-comparative studies with moderate quality and moderate risk of bias could be included in the present systematic review. A total of 153 implants were placed in 123 patients. The main results of the individual studies can be found in Table 4 - 7. The survival of implants placed in XB varied between 66 and 100% across all studies compared with 91 to 100% for implants placed in ABB. The overall rate of complications, either prior to or after implant placement ranged from 0 to 66.7% in the XB group and from 0 to 21.9% in the ABB group. In the XB group the possibility of placing an implant at re-entry varied between 80% and 100%, whereas it was 100% in the ABB group. Data on implant stability, peri-implant health, and graft handling were only sporadically reported. Likewise, only one comparative study [24] presented PROMs revealing that postoperative consumption of analgesic medication was significantly lower for the XB group compared with the ABB group. The meta-analysis found no statistically significant difference in either gain in alveolar ridge width ($P = 0.13$), alveolar ridge width at implant placement ($P = 0.07$) or survival of implants after a minimum of 6 months follow-up after functional implant loading ($P = 0.71$).

DISCUSSION

The 0-hypothesis of no difference in implant treatment outcome after functional implant loading following HARA using XB compared with ABB could not be rejected, due to no statistically significant differences in alveolar ridge width gain, alveolar ridge width at the time of implant placement, or implant survival rate after short-term functional implant loading.

Handling of XB from bovine origin has previously been reported to be problematic as there have been reports of fracture during screw fixation [68]. Collagenated XB from equine origin, however, are less brittle allowing screw fixating with reduced risk of fracture [68,69]. All the included studies of the present systematic review used collagenated equine XB, and only one study reported issues in handling of the grafts [28]. In addition, the possibility of customizing the XB blocks to fit the actual bone defect based on pre-operative cone beam computed tomography scans, holds the potential of simplifying and shortening the surgical procedures as compared with ABBs, which necessitates a separate harvesting procedure as well as local adaptation of the blocks. Only one study evaluated duration of surgery and found statistically significant ($P < 0.0001$) shorter surgical time when using XB compared with ABB [24].

The rate of healing complications after HARA varied greatly between the included studies. However, graft exposure rates of 33 to 40% seems high compared with exposure rates reported after HARA with ABB or particulate bone grafting materials [5], but comparable to what has been observed with ALBB [11]. Other complications included primarily dehiscences, which varied between 0 and 70% for XB and 0 and 18.8% for ABB within the included studies. This indicates an increased risk of soft tissue dehiscence using XB, but may also be due to the increased total number of sites receiving XB.

The gain in ridge width at re-entry was not statistically significant different between XB and ABB ($P = 0.13$). In agreement, preclinical animal studies have shown similar gain in alveolar ridge width with XB and ABB [15,70]. A histomorphometric study in dogs found a mean resorption of 25.2% in the XB when covered with a collagen membrane compared with a mean resorption of 53.9% in the ABB, however not statistically significant [71]. Even though no statically significant difference was found in the present meta-analysis, the numerical values of alveolar ridge width at implant placement of ABB showed a higher degree of width reduction compared with XB, supporting the assumption that XB may be more volume stable than ABB. In agreement, histomorphometric data 20 years after maxillary sinus floor augmentation using deproteinized bovine bone mineral in granular form shows incorporation of the xenogenic material in mature lamellar bone and minimal signs of resorption [72]. It may be speculated that XB successfully incorporated in mature bone may have a similar high resistance to resorption and potentially result in more predictable gain in ridge width after HARA compared with ABB.

However, several of the included studies using XB, showed failure of block integration after functional implant loading followed by implant failure [28,30]. This indicates that the high resorption resistance of xenogenic material is only beneficial if the XB stays incorporated in the native bone during functional implant loading. Histomorphometric analysis of areas grafted with XB show signs of new bone formation, however only in close conjunction to the alveolar ridge with diminishing amounts lateral to the native bone [29,61]. For these reasons it has been suggested that the XB require longer healing time to establish new bone formation before implant placement and reduce the risk of dehiscence [17]. These findings support the idea that long-term follow-up after loading of implants are needed to verify the predictability of XB. The histomorphometric study [71] in dogs found

a varying amount connective tissue encapsulation in the XB. No connective tissue encapsulation was observed around the ABB. Ortiz-Vigón et al. [61] retrieved trephine biopsies from the augmented areas at the time of implant placement. Biopsies from sites with later implant failure contained a significantly lower amount of vital bone ($P = 0.01$) and higher amount of connective tissue ($P = 0.02$) than sites with surviving implants. Another study by Ortiz-Vigón et al. [30], based on the same patient cohort documented that the ratio between ingrowth of fibrous tissue and bone in the XB was directly correlated to the frequency of soft tissue dehiscence during the healing period.

The implant torque at insertion was significantly higher in ABB than XB [25]. Considering the abovementioned observations of a lower amount of new mineralized bone formation and more fibrous tissue in XB when compared with ABB, it is not surprising that the primary stability is decreased.

The types of complications observed after implant placement in this review varied from minor clinical soft tissue dehiscences to loss of graft and implants. As the follow-up period where only up to a maximum of 40 months, these results cannot be used to evaluate the long-term implant treatment outcome.

Mid- and long-term follow-up studies with 5- and 10-years follow-up periods on implant survival rate in ridges augmented with ABB reported survival rates of 100% and 98%, respectively [73,74]. Similar long-term results are not available for survival rates of implants placed in XB. Survival of suprastructure along with its osseointegrated implant are generally considered as the primary criteria for assessment of long-term implant treatment outcome. Two studies [24,25] reported similar results regarding implant survival rate for XB and ABB. The corresponding authors verified implant survival rate after a minimum of 6 months after functional implant loading. Although the meta-analysis revealed no statistically significant difference ($P = 0.71$), one study observed twice as many implant failures in the XB as in the ABB group [24]. One study suggested that their low implant survival rate of 66% after a minimum of 6 months after functional loading, could be explained by the extended defects sizes in their study [28]. Similarly, a study observed better results in contained-type single-tooth defects than when multiple teeth were missing [27].

Three studies in this review state an inclusion criterion of less than 4 mm baseline width of the alveolar ridge [24,29,30]. The result of this present review found that 14 out of 16 (87.5%) of failed

implants were placed in alveolar ridges with a baseline width < 4 mm. One study reported 29% implant failure, however 17% of the total implant failures occurred in the same patients receiving multiple implants and presenting a very narrow baseline ridge (2.75 mm) [30]. This may indicate that structural support and stability is more dependent on osseointegration of the implant in the native bone and less dependent on the integration in the XB. Therefore, baseline ridge width could be a critical factor for implant survival rate when using XB for HARA.

Elimination of donor site morbidity is one of the main issues in the search for alternatives to ABB. An increased intake of painkillers was documented in the ABB group compared with the XB group in one of the studies [24]. This may be speculated to be due to the need for a second surgical site for harvesting and/or a longer duration of surgery because of the harvesting and graft adaptation procedure [24]. However, PROMs obtained from OHIP-14 questionnaires disclosed no significant difference between the XB and ABB groups, after one month [24]. This raises the question if the short-term increase in pain medications is worth accepting, considering the higher risks of complications associated with augmentation with XB. This data is only reported in a single study and supplies the need for similar studies to be able to confirm if the donor site morbidity is worth accepting, considering the complications related to alternative treatments.

A recent randomized clinical trial comparing the use of XB infused with BMP-2 to ABB, showed a high implant survival rate (100%) after three years of functional implant loading as well as stable soft tissues around the implants in both groups [75]. This study indicates good mid-term survival rates after loading in sites augmented with XB. Similar study designs with long-term follow-up should be performed without the use of BMP-2 to further enhance the evidence and determine the predictability of using XB for HARA.

Limitations

The main limitation of the present review and meta-analysis are that the results are based on few studies including a limited number of patients and implants. A great variance in evaluations methods, unclear reports of outcome measurements, dissimilar follow-up

periods following implant loading and a range of methodological confounding factors were observed. Furthermore, most studies primarily focused on survival of grafts and gain in alveolar ridge width after augmentation, with no clear definition of implant success apart from the persistence of implants at different intervals after surgery. Therefore, the conclusions should be interpreted with caution.

CONCLUSIONS

The present systematic review and meta-analysis could not identify any difference in short-term implant treatment outcome after functional implant loading following horizontal alveolar ridge augmentation using xenogeneic blocks compared with autogenous bone blocks. The meta-analysis failed to demonstrate statistically significant differences in alveolar ridge width gain, alveolar ridge width at the time of implant placement, or implant survival rate after a minimum of 6 months functional implant loading. However, these findings should be interpreted with caution as they are based on few studies and limited data. Non-comparative studies showed a moderate to high implant survival rate and gain in alveolar ridge width. However, a high rate of complications including dehiscences, exposure of xenogeneic blocks and graft failure were observed at widely difference incidences. Due to limited data, further long-term randomized controlled trials assessing the survival of implants after horizontal alveolar ridge augmentation with xenogeneic blocks compared with autogenous bone blocks are needed before definite conclusions can be drawn regarding the recommendation of xenogeneic blocks as a predictable alternative for horizontal alveolar ridge augmentation.

ACKNOWLEDGMENTS AND DISCLOSURE STATEMENTS

The authors declare to have no financial or other conflicts of interest related to this publication.

We would like to give a special thanks to Ms. Susie Rimborg (information specialist at Copenhagen University Library, Denmark) for her assistance with the literature search strategy.

REFERENCES

1. Tan WL, Wong TL, Wong MC, Lang NP. A systematic review of post-extraction alveolar hard and soft tissue dimensional changes in humans. *Clin Oral Implants Res.* 2012 Feb;23 Suppl 5:1-21. [Medline: [22211303](#)] [doi: [10.1111/j.1600-0501.2011.02375.x](#)]
2. Barone A, Ricci M, Tonelli P, Santini S, Covani U. Tissue changes of extraction sockets in humans: a comparison of spontaneous healing vs. ridge preservation with secondary soft tissue healing. *Clin Oral Implants Res.* 2013 Nov;24(11):1231-7. [Medline: [22784417](#)] [doi: [10.1111/j.1600-0501.2012.02535.x](#)]
3. Sanz M, Vignoletti F. Key aspects on the use of bone substitutes for bone regeneration of edentulous ridges. *Dent Mater.* 2015 Jun;31(6):640-7. [Medline: [25882277](#)] [doi: [10.1016/j.dental.2015.03.005](#)]
4. Elnayef B, Porta C, Suárez-López Del Amo F, Mordini L, Gargallo-Albiol J, Hernández-Alfaro F. The Fate of Lateral Ridge Augmentation: A Systematic Review and Meta-Analysis. *Int J Oral Maxillofac Implants.* 2018 May/Jun;33(3):622-635. [Medline: [29763500](#)] [doi: [10.11607/jomi.6290](#)]
5. Jensen SS, Terheyden H. Bone augmentation procedures in localized defects in the alveolar ridge: clinical results with different bone grafts and bone-substitute materials. *Int J Oral Maxillofac Implants.* 2009;24 Suppl:218-36. [Medline: [19885447](#)]
6. Hjørtting-Hansen E. Bone grafting to the jaws with special reference to reconstructive preprosthetic surgery. A historical review. *Mund Kiefer Gesichtschir.* 2002 Jan;6(1):6-14. [Medline: [11974547](#)] [doi: [10.1007/s10006-001-0343-6](#)]
7. Cordaro L, Torsello F, Miuccio MT, di Torresanto VM, Eliopoulos D. Mandibular bone harvesting for alveolar reconstruction and implant placement: subjective and objective cross-sectional evaluation of donor and recipient site up to 4 years. *Clin Oral Implants Res.* 2011 Nov;22(11):1320-6. [Medline: [21443607](#)] [doi: [10.1111/j.1600-0501.2010.02115.x](#)]
8. Nkenke E, Neukam FW. Autogenous bone harvesting and grafting in advanced jaw resorption: morbidity, resorption and implant survival. *Eur J Oral Implantol.* 2014 Summer;7 Suppl 2:S203-17. [Medline: [24977256](#)]
9. Fontana F, Rocchietta I, Dellavia C, Nevins M, Simion M. Biocompatibility and manageability of a new fixable bone graft for the treatment of localized bone defects: preliminary study in a dog model. *Int J Periodontics Restorative Dent.* 2008 Dec;28(6):601-7. [Medline: [19146056](#)]
10. Lyford RH, Mills MP, Knapp CI, Scheyer ET, Mellonig JT. Clinical evaluation of freeze-dried block allografts for alveolar ridge augmentation: a case series. *Int J Periodontics Restorative Dent.* 2003 Oct;23(5):417-25. [Medline: [14620116](#)]
11. Starch-Jensen T, Deluiz D, Tinoco EMB. Horizontal Alveolar Ridge Augmentation with Allogeneic Bone Block Graft Compared with Autogenous Bone Block Graft: a Systematic Review. *J Oral Maxillofac Res.* 2020 Mar 31;11(1):e1. [Medline: [32377325](#)] [PMC free article: [7191383](#)] [doi: [10.5037/jomr.2020.11101](#)]
12. Taylor JC, Cuff SE, Leger JP, Morra A, Anderson GI. In vitro osteoclast resorption of bone substitute biomaterials used for implant site augmentation: a pilot study. *Int J Oral Maxillofac Implants.* 2002 May-Jun;17(3):321-30. [Medline: [12074446](#)]
13. Jensen SS, Aaboe M, Pinholt EM, Hjørtting-Hansen E, Melsen F, Ruyter IE. Tissue reaction and material characteristics of four bone substitutes. *Int J Oral Maxillofac Implants.* 1996 Jan-Feb;11(1):55-66. [Medline: [8820123](#)]
14. Thorwarth M, Wehrhan F, Srour S, Schultze-Mosgau S, Felszeghy E, Bader RD, Schlegel KA. Evaluation of substitutes for bone: comparison of microradiographic and histological assessments. *Br J Oral Maxillofac Surg.* 2007 Jan;45(1):41-7. [Medline: [16713040](#)] [doi: [10.1016/j.bjoms.2006.03.013](#)]
15. Araújo MG, Sonohara M, Hayacibara R, Cardaropoli G, Lindhe J. Lateral ridge augmentation by the use of grafts comprised of autologous bone or a biomaterial. An experiment in the dog. *J Clin Periodontol.* 2002 Dec;29(12):1122-31. [Medline: [12492915](#)] [doi: [10.1034/j.1600-051X.2002.291213.x](#)]
16. Hämmerle CH, Jung RE, Yaman D, Lang NP. Ridge augmentation by applying bioresorbable membranes and deproteinized bovine bone mineral: a report of twelve consecutive cases. *Clin Oral Implants Res.* 2008 Jan;19(1):19-25. [Medline: [17956571](#)] [doi: [10.1111/j.1600-0501.2007.01407.x](#)]
17. Sánchez-Labrador L, Molinero-Mourelle P, Pérez-González F, Saez-Alcaide LM, Brinkmann JC, Martínez JL, Martínez-González JM. Clinical performance of alveolar ridge augmentation with xenogeneic bone block grafts versus autogenous bone block grafts. A systematic review. *J Stomatol Oral Maxillofac Surg.* 2021 Jun;122(3):293-302. [Medline: [33161168](#)] [doi: [10.1016/j.jormas.2020.10.009](#)]
18. Buser D, Martin W, Belser UC. Optimizing esthetics for implant restorations in the anterior maxilla: anatomic and surgical considerations. *Int J Oral Maxillofac Implants.* 2004;19 Suppl:43-61. [Medline: [15635945](#)]
19. Welch V, Petticrew M, Tugwell P, Moher D, O'Neill J, Waters E, White H; PRISMA-Equity Bellagio group. PRISMA-Equity 2012 extension: reporting guidelines for systematic reviews with a focus on health equity. *PLoS Med.* 2012;9(10):e1001333. [Medline: [23222917](#)] [PMC free article: [3484052](#)] [doi: [10.1371/journal.pmed.1001333](#)]
20. Landis JR, Koch GG. The measurement of observer agreement for categorical data. *Biometrics.* 1977 Mar;33(1):159-74. [Medline: [843571](#)] [doi: [10.2307/2529310](#)]
21. Higgins JPT, Altman DG, Sterne JAC. Chapter 8: assessing risk of bias in included studies. In: Higgins JPT, Green S, editors. *Cochrane handbook for systematic reviews of interventions version 5.1.0 (updated March 2011).* The Cochrane Collaboration. 2011. [URL: <http://handbook.cochrane.org/>]

22. Sterne JAC, Savović J, Page MJ, Elbers RG, Blencowe NS, Boutron I, Cates CJ, Cheng HY, Corbett MS, Eldridge SM, Emberson JR, Hernán MA, Hopewell S, Hróbjartsson A, Junqueira DR, Jüni P, Kirkham JJ, Lasserson T, Li T, McAleenan A, Reeves BC, Shepperd S, Shrier I, Stewart LA, Tilling K, White IR, Whiting PF, Higgins JPT. RoB 2: a revised tool for assessing risk of bias in randomised trials. *BMJ*. 2019 Aug 28;366:14898. [Medline: [31462531](#)] [doi: [10.1136/bmj.14898](#)]
23. Wells G, Shea B, O'Connell D, Peterson J, Welch V, Losos M, Tugwell P. The Newcastle-Ottawa Scale (NOS) for assessing the quality if nonrandomized studies in meta-analyses. Ottawa Hospital Research Institute. 2000. Canada. [URL: http://www.ohri.ca/programs/clinical_epidemiology/oxford.asp]
24. Romito GA, Villar CC, Sapata VM, Soares HH, Fonseca MA, Conde M, Hammerle CHF, Schwarz F. Autogenous bone block versus collagenated xenogeneic bone block in the reconstruction of the atrophic alveolar ridge: A non-inferiority randomized clinical trial. *J Clin Periodontol*. 2022 Nov;49(11):1158-1168. [Medline: [35833539](#)] [doi: [10.1111/jcpe.13701](#)]
25. Lima RG, Lima TG, Francischone CE, Turssi C, Souza Picorelli Assis NM, Sotto-Maior BS. Bone Volume Dynamics and Implant Placement Torque in Horizontal Bone Defects Reconstructed with Autologous or Xenogeneic Block Bone: A Randomized, Controlled, Split-Mouth, Prospective Clinical Trial. *Int J Oral Maxillofac Implants*. 2018 Jul/Aug;33(4):888-894. [Medline: [30025006](#)] [doi: [10.11607/jomi.6288](#)]
26. Parvini P, Mihatovic I, Sahin D, Becker J, Schwarz F. Lateral alveolar ridge augmentation using an equine-derived collagen-containing bone block: A prospective case series. *Clin Oral Implants Res*. 2022 Feb;33(2):142-149. [Medline: [34679206](#)] [doi: [10.1111/clr.13873](#)]
27. Schwarz F, Sahin D, Civale-Schweighöfer S, Becker J. Long-term outcomes following lateral alveolar ridge augmentation using a collagenated xenogeneic bone block: a monocenter, prospective single-arm clinical study. *Int J Implant Dent*. 2021 Feb 22;7(1):9. [Medline: [33615414](#)] [PMC free article: [7897587](#)] [doi: [10.1186/s40729-021-00293-3](#)]
28. Angermair J, Bosshardt DD, Nelson K, Flüge TV, Stricker A, Fretwurst T. Horizontal bone grafting using equine-derived cancellous bone blocks is associated with severe complications: A prospective clinical and histological pilot study. *Clin Oral Implants Res*. 2020 Nov;31(11):1149-1158. [Medline: [32881075](#)] [doi: [10.1111/clr.13661](#)]
29. Di Stefano DA, Artese L, Iezzi G, Piattelli A, Pagnutti S, Piccirilli M, Perrotti V. Alveolar ridge regeneration with equine spongy bone: a clinical, histological, and immunohistochemical case series. *Clin Implant Dent Relat Res*. 2009 Jun;11(2):90-100. [Medline: [18783426](#)] [doi: [10.1111/j.1708-8208.2008.00104.x](#)]
30. Ortiz-Vigón A, Suarez I, Martínez-Villa S, Sanz-Martín I, Bollain J, Sanz M. Safety and performance of a novel collagenated xenogeneic bone block for lateral alveolar crest augmentation for staged implant placement. *Clin Oral Implants Res*. 2018 Jan;29(1):36-45. [Medline: [28710793](#)] [doi: [10.1111/clr.13036](#)]
31. Bone Quality and Quantity Following Guided Bone Regeneration Prior to Dental Implant Placement. Hadassah Medical Organization, Israel. 2013 Mar 21. ClinicalTrials.gov registration number: NCT01603693. [URL: <https://clinicaltrials.gov/show/NCT01603693>]
32. Mehlisch DR, Taylor TD, Leibold DG, Hiatt R, Waite DE, Waite PD, Laskin DM, Smith ST. Collagen/hydroxylapatite implant for augmenting deficient alveolar ridges: twelve-month clinical data. *J Oral Maxillofac Surg*. 1988 Oct;46(10):839-43. [Medline: [2845038](#)] [doi: [10.1016/0278-2391\(88\)90046-8](#)]
33. Pagliani L, Andersson P, Lanza M, Nappo A, Verrocchi D, Volpe S, Sennerby L. A collagenated porcine bone substitute for augmentation at Neoss implant sites: a prospective 1-year multicenter case series study with histology. *Clin Implant Dent Relat Res*. 2012 Oct;14(5):746-58. [Medline: [20977615](#)] [doi: [10.1111/j.1708-8208.2010.00314.x](#)]
34. Merli M, Moscatelli M, Mariotti G, Pagliaro U, Raffaelli E, Nieri M. Comparing membranes and bone substitutes in a one-stage procedure for horizontal bone augmentation. A double-blind randomised controlled trial. *Eur J Oral Implantol*. 2015 Autumn;8(3):271-81. [Medline: [26355171](#)]
35. Merli M, Moscatelli M, Mariotti G, Pagliaro U, Raffaelli E, Nieri M. Comparing membranes and bone substitutes in a one-stage procedure for horizontal bone augmentation. Three-year post-loading results of a double-blind randomised controlled trial. *Eur J Oral Implantol*. 2018;11(4):441-452. [Medline: [30515484](#)]
36. Block MS. Does the Use of High-Temperature-Processed Xenografts for Ridge Augmentation Result in Ridge Width Stability Over Time? *J Oral Maxillofac Surg*. 2020 Oct;78(10):1717-1725. [Medline: [32649891](#)] [doi: [10.1016/j.joms.2020.06.004](#)]
37. Mayfield LJ, Skoglund A, Hising P, Lang NP, Attström R. Evaluation following functional loading of titanium fixtures placed in ridges augmented by deproteinized bone mineral. A human case study. *Clin Oral Implants Res*. 2001 Oct;12(5):508-14. [Medline: [11564112](#)] [doi: [10.1034/j.1600-0501.2001.120512.x](#)]
38. Kim HS, Park JC, Yun PY, Kim YK. Evaluation of bone healing using rhBMP-2 soaked hydroxyapatite in ridge augmentation: a prospective observational study. *Maxillofac Plast Reconstr Surg*. 2017 Dec 25;39(1):40. [Medline: [29302589](#)] [PMC free article: [5742315](#)] [doi: [10.1186/s40902-017-0138-9](#)]
39. Nam JW, Khureltogtokh S, Choi HM, Lee AR, Park YB, Kim HJ. Randomised controlled clinical trial of augmentation of the alveolar ridge using recombinant human bone morphogenetic protein 2 with hydroxyapatite and bovine-derived xenografts: comparison of changes in volume. *Br J Oral Maxillofac Surg*. 2017 Oct;55(8):822-829. [Medline: [28864147](#)] [doi: [10.1016/j.bjoms.2017.07.017](#)]

40. Mordenfeld A, Johansson CB, Albrektsson T, Hallman M. A randomized and controlled clinical trial of two different compositions of deproteinized bovine bone and autogenous bone used for lateral ridge augmentation. *Clin Oral Implants Res.* 2014 Mar;25(3):310-320. [Medline: [23551390](#)] [doi: [10.1111/clr.12143](#)]
41. Jung RE, Windisch SI, Eggenschwiler AM, Thoma DS, Weber FE, Hämmerle CH. A randomized-controlled clinical trial evaluating clinical and radiological outcomes after 3 and 5 years of dental implants placed in bone regenerated by means of GBR techniques with or without the addition of BMP-2. *Clin Oral Implants Res.* 2009 Jul;20(7):660-6. [Medline: [19489935](#)] [doi: [10.1111/j.1600-0501.2008.01648.x](#)]
42. Hising P, Bolin A, Branting C. Reconstruction of severely resorbed alveolar ridge crests with dental implants using a bovine bone mineral for augmentation. *Int J Oral Maxillofac Implants.* 2001 Jan-Feb;16(1):90-7. [Medline: [11280367](#)]
43. Lorenzetti M, Vono M, Lorenzetti V. A Retrospective Tomographic and Histologic Analysis of Horizontal Bone Augmentation in Maxillary Atrophic Ridges Using Resorbable Membrane with Anorganic Bovine Bone-Derived Mineral and Plasma Rich in Growth Factors. *Int J Periodontics Restorative Dent.* 2019 May/June;39(3):399-406. [Medline: [29451927](#)] [doi: [10.11607/prd.3082](#)]
44. Meijndert CM, Raghoobar GM, Meijndert L, Stellingsma K, Vissink A, Meijer HJ. Single implants in the aesthetic region preceded by local ridge augmentation; a 10-year randomized controlled trial. *Clin Oral Implants Res.* 2017 Apr;28(4):388-395. [Medline: [26919705](#)] [doi: [10.1111/clr.12811](#)]
45. Velázquez ÓI, Tresguerres FGF, Berrocal IL, Tresguerres IF, López-Pintor RM, Carballido J, López-Quiles J, Torres J. Split bone block technique: 4-month results of a randomised clinical trial comparing clinical and radiographic outcomes between autogenous and xenogeneic cortical plates. *Int J Oral Implantol (Berl).* 2021 Mar 16;14(1):41-52. Erratum in: *Int J Oral Implantol (Berl).* 2021 May 12;14(2):226. [Medline: [34006070](#)]
46. Clinical research on bone augmentation around dental implant with Bio-Oss and B-TCP; Prospective research. Tohoku University Hospital, Japan. 2015. [URL: <https://trialsearch.who.int/Trial2.aspx?TrialID=JPRN-UMIN000016537>]
47. Clinical research on bone augmentation around dental implant with unresorbable bone substitute (Bio-Oss). Okayama University Graduate School Medicine, Japan. 2012 Jul 9. [URL: <https://trialsearch.who.int/Trial2.aspx?TrialID=JPRN-UMIN000008362>]
48. Horizontal Augmentation With Deproteinized Bovine Bone Mineral Alone or in Combination With Particulate Autogenous Bone. NU-Hospital Organisation, Sweden; 2016 Jun 1. ClinicalTrials.gov registration number: NCT04755166. [URL: <https://clinicaltrials.gov/show/NCT04755166>]
49. Long-term clinical outcome after reconstruction of atrophied alveolar ridge using collagenated xenogeneic bone block (CXBB) or autogenous bone block (ABB). Follow-up of randomized controlled clinical investigation 10828-021. Geistlich Pharma AG, Switzerland. 2019 May 29. German Clinical Trials Register registration number: DRKS00017137. [URL: <https://trialsearch.who.int/Trial2.aspx?TrialID=DRKS00017137>]
50. Randomized controlled clinical trial of comparison between block-type collagenated bone substitute versus particle type bone substitute in guided bone regeneration on horizontal ridge defect around dental implants. Yonsei University, Republic of Korea. 2020 Aug 8. KCT registration number: KCT0005348. [URL: <https://trialsearch.who.int/Trial2.aspx?TrialID=KCT0005348>]
51. Pistilli R, Felice P, Piatelli M, Nisii A, Barausse C, Esposito M. Blocks of autogenous bone versus xenografts for the rehabilitation of atrophic jaws with dental implants: preliminary data from a pilot randomised controlled trial. *Eur J Oral Implantol.* 2014 Summer;7(2):153-71. [Medline: [24977250](#)]
52. Felice P, Barausse C, Barone A, Zucchelli G, Piatelli M, Pistilli R, Ippolito DR, Simion M. Interpositional Augmentation Technique in the Treatment of Posterior Mandibular Atrophies: A Retrospective Study Comparing 129 Autogenous and Heterologous Bone Blocks with 2 to 7 Years Follow-Up. *Int J Periodontics Restorative Dent.* 2017 Jul/Aug;37(4):469-480. [Medline: [28609491](#)] [doi: [10.11607/prd.2999](#)]
53. Li J, Xuan F, Choi BH, Jeong SM. Minimally invasive ridge augmentation using xenogenous bone blocks in an atrophied posterior mandible: a clinical and histological study. *Implant Dent.* 2013 Apr;22(2):112-6. [Medline: [23344366](#)] [doi: [10.1097/ID.0b013e3182805bec](#)]
54. Rossi R, Rancitelli D, Poli PP, Rasia Dal Polo M, Nannmark U, Maiorana C. The use of a collagenated porcine cortical lamina in the reconstruction of alveolar ridge defects. A clinical and histological study. *Minerva Stomatol.* 2016 Oct;65(5):257-68. [Medline: [27580650](#)]
55. Comparative Study Between Porcine and Autologous Cortical Plates. Universidad Complutense de Madrid, Spain. 2019 Sep 13. ClinicalTrials.gov registration number: NCT04205591. [URL: <https://clinicaltrials.gov/show/NCT04205591>]
56. Qiu L, Yu H. Onlay grafting with bovine bone mineral block for horizontal reconstruction of severely atrophic alveolar ridges in anterior maxillae: A 6-year prospective study. *J Craniomaxillofac Surg.* 2018 Aug;46(8):1199-1204. [Medline: [29909943](#)] [doi: [10.1016/j.jcms.2018.04.004](#)]
57. d'Oliveira EM, Shibli JA. Grafting heterologous bone blocks in the atrophic anterior maxilla as an alternative option to autogenous bone. Preliminary short-time results from a split-mouth prospective study. *IJDM.* 2016;1(1):3-8. [URL: <http://www.dentalmedjournal.it/grafting-heterologous-bone-blocks-atrophic-anterior-maxilla-alternative-option-autogenous-bone-preliminary-short-time-results-split-mouth-prospective-study/>]

58. Guided Bone Regeneration Using Bovine-derived Xenograft in Combination With or Without Injectable Platelet-rich Fibrin. Ege Dentistry School, Turkey. 2020 Nov 23. ClinicalTrials.gov registration number: NCT04709523. [URL: <https://clinicaltrials.gov/show/NCT04709523>]
59. Koutouzis T, Fetner M, Fetner A, Lundgren T. Retrospective evaluation of crestal bone changes around implants with reduced abutment diameter placed non-submerged and at subcrestal positions: the effect of bone grafting at implant placement. *J Periodontol*. 2011 Feb;82(2):234-42. [Medline: [20731584](#)] [doi: [10.1902/jop.2010.100340](https://doi.org/10.1902/jop.2010.100340)]
60. Jung EH, Jeong SN, Lee JH. Augmentation stability and early wound healing outcomes of guided bone regeneration in peri-implant dehiscence defects with L- and I-shaped soft block bone substitutes: A clinical and radiographic study. *Clin Oral Implants Res*. 2021 Nov;32(11):1308-1317. [Medline: [34423887](#)] [doi: [10.1111/clr.13830](https://doi.org/10.1111/clr.13830)]
61. Ortiz-Vigón A, Martínez-Villa S, Suarez I, Vignoletti F, Sanz M. Histomorphometric and immunohistochemical evaluation of collagen containing xenogeneic bone blocks used for lateral bone augmentation in staged implant placement. *Int J Implant Dent*. 2017 Dec;3(1):24. [Medline: [28634845](#)] [PMC free article: [5478548](#)] [doi: [10.1186/s40729-017-0087-1](https://doi.org/10.1186/s40729-017-0087-1)]
62. Schwarz F, Mihatovic I, Ghanaati S, Becker J. Performance and safety of collagenated xenogeneic bone block for lateral alveolar ridge augmentation and staged implant placement. A monocenter, prospective single-arm clinical study. *Clin Oral Implants Res*. 2017 Aug;28(8):954-960. [Medline: [27659183](#)] [doi: [10.1111/clr.12902](https://doi.org/10.1111/clr.12902)]
63. Benic GI, Eisner BM, Jung RE, Basler T, Schneider D, Hämmerle CHF. Hard tissue changes after guided bone regeneration of peri-implant defects comparing block versus particulate bone substitutes: 6-month results of a randomized controlled clinical trial. *Clin Oral Implants Res*. 2019 Oct;30(10):1016-1026. [Medline: [31332835](#)] [doi: [10.1111/clr.13515](https://doi.org/10.1111/clr.13515)]
64. Dahlin C, Simion M, Hatano N. Long-term follow-up on soft and hard tissue levels following guided bone regeneration treatment in combination with a xenogeneic filling material: a 5-year prospective clinical study. *Clin Implant Dent Relat Res*. 2010 Dec;12(4):263-70. [Medline: [19438941](#)] [doi: [10.1111/j.1708-8208.2009.00163.x](https://doi.org/10.1111/j.1708-8208.2009.00163.x)]
65. Schlegel KA, Karascholi T, Fenner M, Nkenke E. Klinische und radiologische Ergebnisse nach Augmentationen - eine prospektive Evaluation [Clinical and radiological results after augmentation procedures - a prospective study]. *Mund Kiefer Gesichtschir*. 2007 Sep;11(4):209-19. German. [Medline: [17641920](#)] [doi: [10.1007/s10006-007-0065-5](https://doi.org/10.1007/s10006-007-0065-5)]
66. Randomized controlled clinical trial to evaluate the concept of treatment for atrophied alveolar ridge reconstruction using Collaged Xenogenic Bone Block (CXBB) versus Autogenous Bone Block (ABB) treatment. Faculdade de Odontologia da Universidade de São Paulo, Brazil. 2021 Sep 16. [URL: <https://trialsearch.who.int/Trial2.aspx?TrialID=RBR-3vn9c5q>]
67. Dastaran M, Bailey D, Austin S, Chandu A, Judge R. Complications of augmentation procedures for dental implants in private practice, Victoria, Australia. *Aust Dent J*. 2019 Sep;64(3):223-228. [Medline: [30883798](#)] [doi: [10.1111/adj.12686](https://doi.org/10.1111/adj.12686)]
68. Benic GI, Thoma DS, Muñoz F, Sanz Martin I, Jung RE, Hämmerle CH. Guided bone regeneration of peri-implant defects with particulated and block xenogenic bone substitutes. *Clin Oral Implants Res*. 2016 May;27(5):567-76. [Medline: [26073212](#)] [doi: [10.1111/clr.12625](https://doi.org/10.1111/clr.12625)]
69. Schwarz F, Ferrari D, Balic E, Buser D, Becker J, Sager M. Lateral ridge augmentation using equine- and bovine-derived cancellous bone blocks: a feasibility study in dogs. *Clin Oral Implants Res*. 2010 Sep;21(9):904-12. [Medline: [20491835](#)] [doi: [10.1111/j.1600-0501.2010.01951.x](https://doi.org/10.1111/j.1600-0501.2010.01951.x)]
70. Schwarz F, Rothamel D, Herten M, Ferrari D, Sager M, Becker J. Lateral ridge augmentation using particulated or block bone substitutes biocoated with rhGDF-5 and rhBMP-2: an immunohistochemical study in dogs. *Clin Oral Implants Res*. 2008 Jul;19(7):642-52. [Medline: [18492078](#)] [doi: [10.1111/j.1600-0501.2008.01537.x](https://doi.org/10.1111/j.1600-0501.2008.01537.x)]
71. Rothamel D, Schwarz F, Herten M, Ferrari D, Mischkowski RA, Sager M, Becker J. Vertical ridge augmentation using xenogenous bone blocks: a histomorphometric study in dogs. *Int J Oral Maxillofac Implants*. 2009 Mar-Apr;24(2):243-50. [Medline: [19492639](#)]
72. Valentini P, Bosshardt DD. 20-Year Follow-up in Maxillary Sinus Floor Elevation Using Bovine-Derived Bone Mineral: A Case Report with Histologic and Histomorphometric Evaluation. *Int J Oral Maxillofac Implants*. 2018 Nov/Dec;33(6):1345-1350. [Medline: [30427966](#)] [doi: [10.11607/jomi.6884](https://doi.org/10.11607/jomi.6884)]
73. Buser D, Ingimarsson S, Dula K, Lussi A, Hirt HP, Belser UC. Long-term stability of osseointegrated implants in augmented bone: a 5-year prospective study in partially edentulous patients. *Int J Periodontics Restorative Dent*. 2002 Apr;22(2):109-17. [Medline: [12019706](#)]
74. Chappuis V, Cavusoglu Y, Buser D, von Arx T. Lateral Ridge Augmentation Using Autogenous Block Grafts and Guided Bone Regeneration: A 10-Year Prospective Case Series Study. *Clin Implant Dent Relat Res*. 2017 Feb;19(1):85-96. [Medline: [27476677](#)] [doi: [10.1111/cid.12438](https://doi.org/10.1111/cid.12438)]
75. Bienz SP, Payer M, Hjerpe J, Hüsler J, Jakse N, Schmidlin PR, Hämmerle CHF, Jung RE, Thoma DS. Primary bone augmentation leads to equally stable marginal tissue conditions comparing the use of xenograft blocks infused with BMP-2 and autogenous bone blocks: A 3D analysis after 3 years. *Clin Oral Implants Res*. 2021 Dec;32(12):1433-1443. [Medline: [34543475](#)] [PMC free article: [9293361](#)] [doi: [10.1111/clr.13843](https://doi.org/10.1111/clr.13843)]

To cite this article:

Christensen JG, Grønlund GP, Georgi SR, Starch-Jensen T, Bruun NH, Jensen SS.

Horizontal Alveolar Ridge Augmentation with Xenogenic Block Grafts Compared with Autogenous Bone Block Grafts for Implant-retained Rehabilitation: a Systematic Review and Meta-Analysis

J Oral Maxillofac Res 2023;14(2):e1

URL: <http://www.ejomr.org/JOMR/archives/2023/2/e1/v14n2e1.pdf>

doi: [10.5037/jomr.2003.14201](https://doi.org/10.5037/jomr.2003.14201)

Copyright © Christensen JG, Grønlund GP, Georgi SR, Starch-Jensen T, Bruun NH, Jensen SS. Published in the JOURNAL OF ORAL & MAXILLOFACIAL RESEARCH (<http://www.ejomr.org>), 30 June 2023.

This is an open-access article, first published in the JOURNAL OF ORAL & MAXILLOFACIAL RESEARCH, distributed under the terms of the [Creative Commons Attribution-Noncommercial-No Derivative Works 3.0 Unported License](https://creativecommons.org/licenses/by-nc-nd/3.0/), which permits unrestricted non-commercial use, distribution, and reproduction in any medium, provided the original work and is properly cited. The copyright, license information and link to the original publication on (<http://www.ejomr.org>) must be included.

Appendix 1. Search history

Database	Interface	Result	Date
PubMed	PubMed.gov	1289	25 January 2022
Cochrane Library	Wiley	382	25 January 2022
Embase	Embase.com	571	25 January 2022
Total		2242	-
After duplicate-removal		1568	-

Appendix 2. PubMed search until 25th of January, 2022

Search	Query	Items found
#6	(((bone substitutes[MeSH Terms]) OR (transplantation, heterologous[MeSH Terms]) OR (heterografts[MeSH Terms]) OR (((Xenograft*[Text Word]) OR (Xenogenic*[Text Word]) OR (Xenogenic*[Text Word]) OR (Heterogenic*[Text Word]) OR (heterograft*[Text Word]) OR (Heterogenic*[Text Word])) OR (((((((DBBM[Text Word]) OR (Deproteinized Bovine Bone mineral[Text Word])) OR (Deproteinized Bovine Bone matrix[Text Word]) OR (Bovine bone[Text Word]) OR (Equine bone[Text Word]) OR (deproteinized equine bone mineral[Text Word]) OR (Bone substitut*[Text Word]) OR (equine[Text Word]) OR (Bovine[Text Word])) AND (((alveolar augment*[Text Word]) OR (alveolar ridge augment*[Text Word]) OR (Ridge augment*[Text Word]) OR ((lateral ridge augment*[Text Word]) OR (horizontal ridge augment*[Text Word])) OR (alveolar ridge augmentation[MeSH Terms]))	1,289
#5	(((bone substitutes[MeSH Terms]) OR (transplantation, heterologous[MeSH Terms]) OR (heterografts[MeSH Terms]) OR (((Xenograft*[Text Word]) OR (Xenogenic*[Text Word]) OR (Xenogenic*[Text Word]) OR (Heterogenic*[Text Word]) OR (heterograft*[Text Word]) OR (Heterogenic*[Text Word])) OR (((((((DBBM[Text Word]) OR (Deproteinized Bovine Bone mineral[Text Word])) OR (Deproteinized Bovine Bone matrix[Text Word]) OR (Bovine bone[Text Word]) OR (Equine bone[Text Word]) OR (deproteinized equine bone mineral[Text Word]) OR (Bone substitut*[Text Word]) OR (equine[Text Word]) OR (Bovine[Text Word]))	402,627
#4	(((DBBM[Text Word]) OR (Deproteinized Bovine Bone mineral[Text Word])) OR (Deproteinized Bovine Bone matrix[Text Word]) OR (Bovine bone[Text Word]) OR (Equine bone[Text Word]) OR (deproteinized equine bone mineral[Text Word]) OR (Bone substitut*[Text Word]) OR (equine[Text Word]) OR (Bovine[Text Word])	274,952
#3	(((Xenograft*[Text Word]) OR (Xenogenic*[Text Word]) OR (Xenogenic*[Text Word]) OR (Heterogenic*[Text Word]) OR (heterograft*[Text Word]) OR (Heterogenic*[Text Word])	112,258
#2	(bone substitutes[MeSH Terms]) OR (transplantation, heterologous[MeSH Terms]) OR (heterografts[MeSH Terms])	52,367
#1	(((alveolar augment*[Text Word]) OR (alveolar ridge augment*[Text Word]) OR (Ridge augment*[Text Word]) OR ((lateral ridge augment*[Text Word]) OR (horizontal ridge augment*[Text Word])) OR (alveolar ridge augmentation[MeSH Terms])	4,934

Appendix 3. Embase search until 25th of January, 2022

No.	Searches	Results
#1	exp bone prosthesis/	10246
#2	exp xenograft/	44354
#3	1 or 2	54372
#4	(Xenograft* or Xenogenic* or Xenogenic* or heterograft* or Heterogenic*).mp [mp= title, abstract, heading word, drug trade name, original title, device manufacturer, drug manufacturer, device trade name, keyword heading word, floating subheading word, candidate term word]	148115
#5	(DBBM or Deproteinized Bovine Bone mineral or Deproteinized Bovine Bone matrix or Bovine bone or Equine bone or deproteinized equine bone mineral or Bone substitut or equine or Bovine).mp [mp= title, abstract, heading word, drug trade name, original title, device manufacturer, drug manufacturer, device trade name, keyword heading word, floating subheading word, candidate term word]	293899
#6	3 or 4 or 5	448442
#7	(alveolar augment* or alveolar ridge augment* or Ridge augment* or lateral ridge augment* or horizontal ridge augmen*).mp [mp= title, abstract, heading word, drug trade name, original title, device manufacturer, drug manufacturer, device trade name, keyword heading word, floating subheading word, candidate term word]	2120
#8	exp alveolar ridge augmentation/	978
#9	7 or 8	2120
#10	6 or 9	571

Appendix 4. Cochrane Library search until 25th of January, 2022

ID	Search	Hits
#1	MeSH descriptor: [Alveolar Ridge Augmentation] explode all trees	393
#2	Lateral ridge augment* OR Horizontal ridge augment* OR Alveolar augment* OR alveolar ridge augment* OR ridge augment*	1016
#3	#1 OR #2	1016
#4	MeSH descriptor: [Bone Substitutes] explode all trees	564
#5	MeSH descriptor: [Transplantation, Heterologous] explode all trees	82
#6	MeSH descriptor: [Heterografts] explode all trees	74
#7	#4 OR #5 OR #6	683
#8	Xenograft* OR Xenogenic* OR Xenogenic* OR Heterogenic* OR heterograft* OR Heterogeneic*	1156
#9	DBBM OR Deproteinized Bovine Bone mineral OR Deproteinized Bovine Bone matrix OR Bovine bone OR Equine bone OR deproteinized equine bone mineral OR Bone substitut* OR equine OR Bovine	6125
#10	#7 OR #8 OR #9	7037
#11	#3 AND #10	382