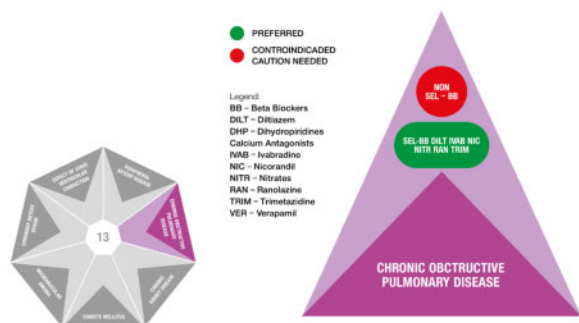


Angina due to obstructive coronary artery disease in a patient with chronic obstructive pulmonary disease

Luis Henrique Wolff Gowdak

Heart Institute (InCor), Laboratory of Genetics and Molecular Cardiology, Av Dr Eneas de Carvalho Aguiar, 44 Sao Paulo, SP 05403-000 Brazil



A 70-year-old Caucasian male was referred to our Outpatient Clinic Center with a history of non-limiting, post-percutaneous coronary intervention (PCI) angina (Canadian Cardiovascular Society Class II). The patient had undergone PCI with a drug-eluting stent implantation to the left obtuse marginal branch of the left circumflex artery 9 months before because of stable angina. Despite the successful PCI, 2 months ago, he noticed a recurrence of angina during more vigorous effort, such as climbing stairs or walking briskly. His past medical history included treatment for asthma during childhood until adolescence, when he became symptom-free. He began smoking at the age of 22 years. He had a long history of hypercholesterolaemia. A couple of years later, occasional respiratory symptoms (shortness of breath and wheezing) developed again, particularly during the winter and he started using budesonide/formoterol 400 µg/12 µg (inhalation) twice daily. He works as a desk clerk and exercises only during the week-ends (30-min walks) and finally, quit smoking at the age of 65 years.

On examination, he had a body mass index of 24.5 kg/m², his heart rate was 84 b.p.m., and his blood pressure was

122/80 mmHg. His physical examination was unremarkable except for a decreased left posterior tibial pulse. His laboratory exams showed a blood glucose level of 92 mg/dL, HbA_{1c} 5.5%, total cholesterol 152 mg/dL, low-density lipoprotein (LDL) 98 mg/dL, high-density lipoprotein 30 mg/dL, triglycerides 110 mg/dL, and a creatinine level of 1.1 mg/dL (glomerular filtration rate 70 mL/min/1.73 m² calculated by the Modification of Diet in Renal Disease Study equation). A resting ECG and transthoracic echocardiogram were normal. An arterial blood gas test while breathing air showed an O₂ saturation of 94%, a partial pressure of O₂ of 64 mmHg, and a partial pressure of CO₂ of 35 mmHg. A pulmonary function test confirmed a moderate obstructive ventilatory disorder with reduced forced vital capacity (baseline 55%, post-bronchodilator 64% of the predicted values).

He was on aspirin 100 mg once daily, clopidogrel 75 mg once daily, rosuvastatin 10 mg once daily, and budesonide/formoterol 400 µg/12 µg (inhalation) twice daily.

The diagnosis of post-PCI angina in a patient with chronic obstructive pulmonary disease (COPD) was made.

Based on the clinical diagnosis, how would you further investigate this patient?

How frequent is it in your practice to have a post-PCI patient complaining of angina? Would you consider a functional, non-invasive assessment of his ischaemic burden? Would you order a non-invasive assessment of the coronary arteries by computed tomography angiography? Or would you rather proceed immediately with an invasive angiography?

Different studies have shown that the rate of persistence or recurrence of angina after successful PCI is not rare, occurring between 20% and 40% of patients.¹ In this patient, with non-limiting symptoms, preserved left ventricular function, and not on optimal medical therapy, the Heart Team decided for a functional non-invasive assessment of myocardial ischaemia. In choosing not only the imaging

*Corresponding author. Tel: +55 11 2661 5929, Fax: +55 11 2661 5022, Email: luis.gowdak@incor.usp.br

modality, but also the pharmacological view of treated COPD, we performed a stress echocardiogram using the dobutamine-atropine protocol as the use of dipyridamole could provoke bronchospasm in patients with COPD.

While waiting for the stress echo to be performed, the patient needs to be treated. How would you optimize his medical treatment for both symptom control and secondary prevention?

Rosuvastatin was increased to 20 mg daily in an attempt to achieve an LDL level <50 mg/dL. Regarding the best anti-anginal agent, there was an intense debate about whether a beta-blocker should be started for symptom control in a patient with elevated heart rate, but on treatment for COPD, and no hypertension. The use of a β_1 -selective agent, like bisoprolol or metoprolol, was considered, but, since prognosis would not be affected by these agents in a patient with angina, without a previous myocardial infarction or left ventricular dysfunction, the panel opted for a different heart rate-lowering strategy, favouring a non-blood pressure-lowering strategy; therefore, ivabradine 5 mg twice daily was chosen.

At his next appointment 1 month later, the patient returned with the results of the stress echocardiogram, which was positive for stress-induced myocardial ischaemia in the apical inferior/lateral segments with preserved left ventricular function. With the increment of the therapy, the symptoms improved greatly and angina occurred only with more strenuous exercise. In fact, he increased the frequency of his walks from 2 to 5 times per week. His heart rate was reduced to 72 b.p.m. and his blood pressure remained stable at 120/72 mmHg.

What would you do now? Would you increase the dose of ivabradine? Would you consider an invasive coronary angiography? Do both?

All members of the Heart Team agreed on increasing the dose of ivabradine to 7.5 mg twice daily since the patient was still having residual angina and the drug was very well tolerated. However, the Heart Team felt that an invasive coronary angiography would be indicated in face of inducible myocardial ischaemia. Therefore, an invasive coronary angiography was performed as shown in *Figure 1*, which confirmed a patent stent in the obtuse marginal branch of the left circumflex artery and no other lesions in the coronary tree.

The patient was kept on medical treatment with further improvement in his exercise tolerance and no associated respiratory symptoms. This single case confirms a study by Mahmoud *et al.*² showing that, in patients with COPD and elevated heart rate, ivabradine significantly improves the 6-min-walk distance from 192.6 ± 108.8 m at baseline to 285.1 ± 88.9 m at the end of the study. The prognostic impact provided by ivabradine in patients with left

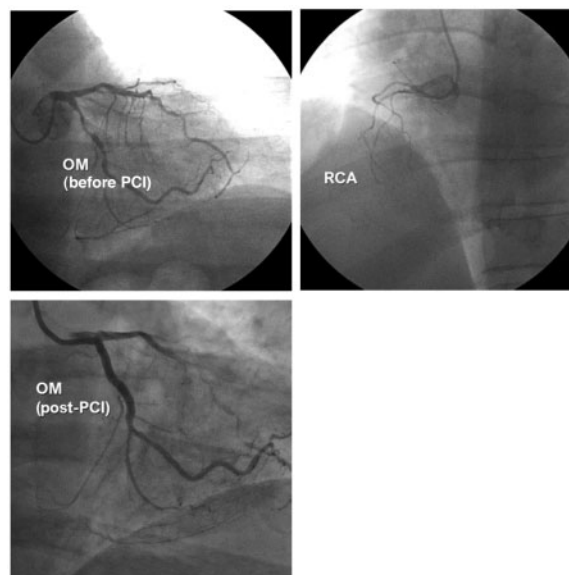


Figure 1 Coronary angiography performed 11 months after a percutaneous coronary intervention to the obtuse marginal branch of the left circumflex artery showing a patent stent. Chronic total occlusion of a non-dominant right coronary artery.

ventricular dysfunction was also demonstrated in patients with COPD who were enrolled in the SHIFT trial (Systolic Heart failure treatment with the I_f inhibitor ivabradine Trial).³ Thus, ivabradine can be safely used not only for symptom control in patients with COPD and stable coronary artery disease like the one discussed here but also to improve prognosis in patients with COPD and left ventricular dysfunction, in whom the concomitance of COPD may be a barrier for beta-blocker therapy.

Funding

The authors didn't receive any financial support in terms of honorarium by Servier for the articles.

Conflict of interest: L.H.W.G. has received honoraria from Servier for lecturing and consulting.

References

1. Crea F, Bairey Merz CN, Beltrame JF, Berry C, Camici PG, Kaski JC, Ong P, Pepine CJ, Sechtem U, Shimokawa H. Mechanisms and diagnostic evaluation of persistent or recurrent angina following percutaneous coronary revascularization. *Eur Heart J* 2019;40:2455-2462.
2. Mahmoud K, Kassem HH, Baligh E, ElGameel U, Akl Y, Kandil H. The effect of ivabradine on functional capacity in patients with chronic obstructive pulmonary disease. *Clin Med (Lond)* 2016;16:419-422.
3. Tavazzi L, Swedberg K, Komajda M, Böhm M, Borer JS, Lainscak M, Robertson M, Ford I, SHIFT Investigators. Clinical profiles and outcomes in patients with chronic heart failure and chronic obstructive pulmonary disease: an efficacy and safety analysis of SHIFT study. *Int J Cardiol* 2013;170:182-188.