

# Transpedicular curettage and drainage versus combined anterior and posterior surgery in infectious spondylodiscitis

Byung Ho Lee<sup>1</sup>, Jin-Oh Park<sup>2</sup>, Hak-Sun Kim<sup>2</sup>, Hwan-Mo Lee<sup>2</sup>, Byung-Woo Cho<sup>2</sup>, Seong-Hwan Moon<sup>2</sup>

## ABSTRACT

**Background:** Hematogeneous infectious spondylodiscitis usually occurs in older immunocompromised patients with other comorbidities. They are usually unable to undergo reconstructive anterior and posterior surgeries. Therefore, an alternative, less aggressive surgical method of transpedicular curettage and drainage was suggested. This study was designed to compare the surgical outcomes for the treatment of hematogeneous infectious spondylodiscitis between transpedicular curettage and drainage technique and conventional combined anterior and posterior surgery.

**Materials and Methods:** Between January 2002 and July 2011, 26 patients underwent surgical treatment for hematogeneous infectious spondylodiscitis. The patients were classified into two groups depending on surgical modality: a transpedicular curettage and drainage (TCD) group and a combined anterior and posterior surgery (CAPS) group.

**Results:** The TCD group consisted of 10 patients (mean age 68.0 years), and the CAPS group consisted of 16 patients (mean age 58.4 years). The mean postoperative followup periods were 36.9 (months) in the TCD group and 69.9 (months) in the CAPS group. The operation time was 180.6 ± 33.6 minutes in the TCD group and 332.7 ± 74.5 minutes in the CAPS group ( $P < 0.05$ ). Postoperative independent ambulation began at postoperative 4.9 ± 2.4 days in the TCD group but at postoperative 15.1 ± 15.3 days in the CAPS group ( $P < 0.05$ ). The postoperative hospital stays were 19.9 ± 7.8 days in the TCD group and 35.4 ± 33.3 days in the CAPS group ( $P < 0.05$ ). The level of C-reactive proteins decreased significantly in both groups after surgery ( $P < 0.05$ ).

**Conclusion:** Transpedicular curettage and drainage technique proved to be a useful technique for treating hematogeneous infectious spondylodiscitis in patients who were in poor health with multiple comorbidities unable to undergo the conventional combined anterior and posterior surgery in a single day in terms of earlier ambulation, shorter hospitalization and similar clinical success rate.

**Key words:** Curettage, drainage, infectious, spondylodiscitis, transpedicular

## INTRODUCTION

A hematogeneous spinal infection is a relatively rare condition in patients with immunocompromised condition including older age and multiple comorbidities.<sup>1-3</sup> In general, the principle for treating infectious spondylodiscitis includes identifying infectious

strains and using appropriate antibiotics with weight load support to prevent subsequent collapses of the infected vertebrae.<sup>1,4-7</sup> However, in patients whose infections do not respond to medical treatment, additional surgical procedures removing infectious foci, necrotic debris, and reconstructing the spinal column are required to prevent aggravation of deformity and development of neurological symptoms.<sup>3,8,9</sup> Well established surgical treatment consists of a corpectomy that involves anterior strut bone graft with or without posterior instrumentation.<sup>10-13</sup> In some patients, the classic surgical treatments are not applicable due to the patients' age, general condition and co-morbidities.<sup>1,14-16</sup> To meet the need of an alternative and less aggressive surgical method, we developed and have been using a transpedicular curettage and drainage (TCD) as the new surgical technique for treating hematogeneous infectious spondylodiscitis.<sup>17</sup>

Hence, in the present study, clinical results and serological markers were compared between TCD and CAPS retrospectively.

<sup>1</sup>Department of Orthopaedic Surgery, International St.Mary's Hospital, Incheon,  
<sup>2</sup>Department of Orthopaedic Surgery, Yonsei University College of Medicine, Seoul, Korea

**Address for correspondence:** Dr. Seong-Hwan Moon,  
 Department of Orthopaedic Surgery, Yonsei University College of Medicine, 50  
 Yonsei-ro, Seodaemun-gu, Seoul - 120752, Korea.  
 E-mail: shmoon@yuhs.ac

Access this article online	
Quick Response Code:	Website: www.ijoonline.com
	DOI: 10.4103/0019-5413.125508

## MATERIALS AND METHODS

33 patients underwent surgical treatment for infectious spondylodiscitis between January 2002 and July 2011 after failure of conservative treatment. The data of the present study was gathered based on the International Statistical Classification of Diseases and Related Health Problems (ICD-10), 10<sup>th</sup> Revision, 2007, World Health Organization, from medical records of cases of infective spondylodiscitis, coded as M46.3, using our institute's electronic medical record search program. The electronic medical records (EMR) and imaging studies were thoroughly and retrospectively reviewed and analyzed. Failure of conservative treatment was considered when the erythrocyte sedimentation rate (ESR), C-reactive protein (CRP) and pain severity did not decrease for more than 2 weeks despite intravenous antibiotic administration of first-generation cephalosporin. Indications of surgical procedure basically met the classical surgical indications including (1) intolerable back and/or radiating pain caused by infective spondylodiscitis (2) progressive neurologic deficit because of epidural abscess formation. Among these patients, six patients were excluded due to iatrogenic cause of infectious spondylodiscitis after discectomy or discogram at another hospital, which have shown different pathogenesis and acute exacerbation of related symptom from direct inoculation of pathogen compared with those of hematogeneous infectious spondylodiscitis. Another patient was excluded due to young age (15 year old).

The patients who were unfit for conventional classical anterior and posterior combined surgery based on preoperative American Society of Anesthesiologists Physical Status Classification were taken up for TCD procedures.<sup>18</sup> Among these enrolled patients, who could be followed up longer than 1 year were classified into two groups depending on the treatment they received: 10 patients in the TCD group and 16 patients in the CAPS group [Table 1]. There were seven males and three females in the TCD group. The mean age was 68.0 years (range 48-78 years). There were 10 males and 6 females in CAPS group with mean age 58.4 years (range 32-80 years). Anterior surgery consisted of abscess drainage, discectomy and anterior interbody fusion using tricorticaliliac bone graft. Posterior fixation using pedicle screw fixation system was added as posterior surgery. The mean intervals between anterior surgery and posterior fixation were 9.4 days (range 3-14 days).

The distribution of ASA-PS classification scale was 2 cases of class III and 8 cases of class IV in the TCD group, 10 cases of class III and 6 cases of class IV in the CAPS group. The distribution was not statistically significant (nonparametric Chi-square test).

The mean postoperative followup periods were 36.9 months (range 16-69 months) in the TCD group and 69.9 months (range 17-109 months) in the CAPS group. In the CAPS group, 8 of 16 patients showed Kellgren/Lawrence grade III,<sup>19</sup> but no symptoms related to knee conditions were presented. Also, in the TCD group, four patients showed K/L grade III, but again no symptoms were presented.

Serological tests including white blood cell counts, ESR, CRP and blood chemistry profiles were performed in all patients. Radiographic studies including plain X-rays of the involved spine area, computed tomography (CT), whole body bone scan (WBBS) and magnetic resonance image (MRI) were performed. In most patients, empirical antibiotics of first-generation cephalosporin (e.g. cefazolin 1 g mixed with normal saline 10 cc at every 12 hours) were started with initial diagnosis of pyogenic spondylodiscitis. The disease was considered cured when serologic inflammatory markers (ESR, CRP and WBC counts) were within the normal limit, without any correlating clinical symptoms, after cessation of oral antibiotics.

All experimental protocols were approved by the Institutional Review Board of each participating institution (IRB No. 1-2011-0068).

All statistical analyses including Friedman test and Mann-Whitney U test and other basic statistical tests were performed by using the SPSS 12.0.1 statistics package (SPSS, Inc., Chicago, IL).

### Operative procedure for transpedicular curettage and drainage<sup>17</sup>

First, the pedicle screws were inserted to the adjacent healthy

**Table 1: Comparison of demographic data of patients**

	TCD	CAPS	P value
Case no (M:F)	10 (7:3)	16 (10:6)	N.S
Age (years)	68 (48~78)	58.4 (32~80)	N.S
ASA-PS classification scale <sup>18</sup> (III:IV)	(2: 8)	(10: 6)	N.S
Followup duration (months)	36.9 (16~69)	69.9 (17~109)	0.012
Operation time (minutes)	180.6±33.6	332.7±74.5	0.000
Intraoperative bleeding (cc)	917.0±565.7	704.4±382.9	N.S
Postoperative total ICU stay (days)	2.1±1.1	4.3±2.1	0.010
Postoperative independent ambulation start (days)	4.9±2.4	15.1±15.3	0.000
Postoperative hospital stay (days)	19.9±7.8	35.4±33.3	0.032
Hemovac suction drain removal (days)	9.8±3.3	4.8±2.4	0.001

Mann-Whitney U test, and  $P < 0.05$  means statistical significance. TCD=Transpedicular curettage and drainage, ICU=Intensive care unit, CAPS=Combined anterior and posterior surgery, ASA-PS classification scale=American society of anesthesiologists physical status classification scale. N.S=Not statistically significant

vertebrae of infected vertebrae in the usual manner. After inserting the pedicle screws, mostly 1 proximal and 1 distal level of vertebrae, drainage pedicle holes were made through pedicles of infected vertebrae adjacent to infected disc level (s) in order to prevent possible seeding of infectious emboli to the healthy vertebra as the same surgical instruments and utensils are used for both the pedicle screws and the drainage holes. The amount of bone removal through pedicle holes was minimized to secure the irrigation fluid drainage in order to prevent an iatrogenic fracture. At least 15,000 cc of sterilized normal saline was used for continuous irrigation through the pedicular pathways until the drained fluid looked clear. Depending on the presence of epidural abscess causing neurological deficits and co-existing spinal stenosis, additional decompression procedures including laminectomy, flavectomy and/or pediclectomy were applied. Then two rods, which were slightly bent laterally to facilitate pedicular drainage, were assembled with the pedicle screws. Hemovac drains were not removed until the amount of postoperative drainage was less than 30 cc to encourage drainage of the remaining unhealthy discharge from the infected vertebrae.

## RESULTS

Clinical presentations were analogous in both groups. In the CAPS group, six patients had chronic onset (longer than 3 months) and 10 patients had acute onset of clinical symptoms including lower back pain. Only one patient had neurological motor deficit preoperatively in this group. In the TCD group, seven patients had a chronic insidious onset of lower back pain. Three patients had acute exacerbation of lower back pain and development of neurological deficits. Seven patients experienced pyretic events in the TCD group before admission to the hospital. In the CAPS group, 10 patients complained of fever before admission.

The blood loss was  $917.0 \pm 565.7$  cc (range 170-1000 cc) in the TCD group and  $704 \pm 382.9$  cc (range 200-1150 cc) in the CAPS group. Postoperative independent ambulation started at  $4.9 \pm 2.4$  days in the TCD group and  $15.1 \pm 15.3$  days in the CAPS group, respectively ( $P = 0.000$ , Mann-Whitney U test). Postoperative hospital stays were  $19.9 \pm 7.8$  days in the TCD group and  $35.4 \pm 33.3$  days in the CAPS group ( $P = 0.032$ , Mann-Whitney U test).

Levels of surgery in the CAPS group were T8-10 ( $n = 1$ ), T10-11 ( $n = 1$ ), T12-L1 ( $n = 1$ ), L2-3 ( $n = 3$ ), L2-3-4 ( $n = 1$ ), L3-4-5 ( $n = 1$ ), and L 4-5 ( $n = 8$ ). The levels of surgery in the TCD group were T12-L1 ( $n = 2$ ), L1-2-3 ( $n = 1$ ), L3-4 ( $n = 4$ ), L3-4-5 ( $n = 1$ ), and L4-5 ( $n = 2$ ).

Preoperative parenteral antibiotics such as first and third generation cephalosporin, vancomycin and aminoglycoside

depending on the pathogen and co-existing other infection were used for an average 30 days (range 0-106 days) in the TCD group and 14.5 days (range 0-41 days) in the CAPS group. Postoperative parenteral antibiotics were used for 21.3 days (range 2-33 days) in the TCD group and 31.2 days (range 2-128 days) in the CAPS group. Oral antibiotics of third-generation cephalosporin were administered for of 40.6 days (range 14-105 days) in the TCD group and 19.3 days (range 0-69 days) in the CAPS group after discharge ( $P = 0.038$ , Mann-Whitney U test). Serological outcomes improved in both groups and there were no significant differences of inflammatory markers between groups [Figures 1-3 and Table 2].

Only two patients in the TCD group had a positive result of vertebral wound culture with methicillin-resistant coagulase negative streptococcus and methicillin-sensitive *Staphylococcus aureus*. The others showed all negative vertebral wound culture, but two patients presented with positive blood culture results with methicillin-resistant *S.aureus*.

In the CAPS group, two patients had positive tuberculosis PCR, two patients with methicillin-sensitive *S. aureus*, and three patients with methicillin-resistant coagulase negative streptococcus. After confirmative diagnosis of TB, 9 months of antituberculosis medication regimen of 2 HERZ/7HR was prescribed and taken by patients as suggested by World Health Organization. All patients demonstrated negative result with the culture for fungus.

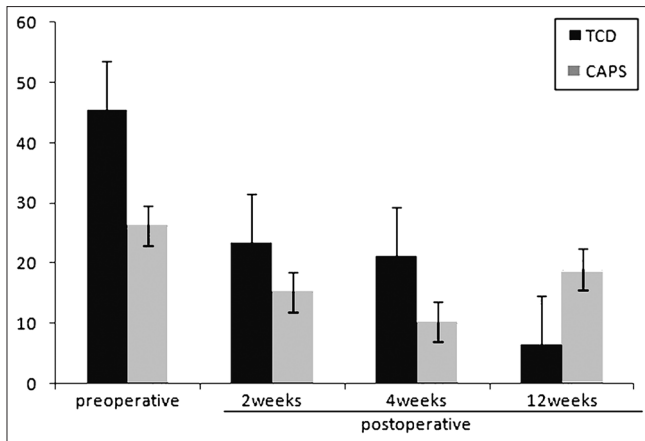
## Complication

Two patients in the TCD group had postoperative morbidities such as postoperative delirium and postoperative arrhythmia. In one patient, pedicle screws had pulled-out at the distal segment due to poor osteoporotic bone

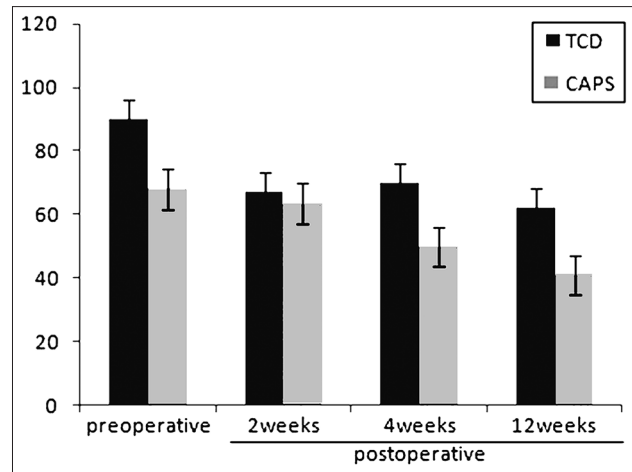
**Table 2: Serological inflammatory marker changes after surgery**

	Preoperative	Postoperative			P value
		2 weeks	4 weeks	12 weeks	
CRP (0-8 mg/l)					
TCD	45.6±51.4	23.4±33.3	21.2±30.9	6.5±5.3	<0.05
CAPS	26.3±44.6	15.2±26.6	10.3±19.8	19.0±48.7	<0.05
ESR (0-35 mm/h)					
TCD	100.7±26.1	66.7±15.7	78.5±33.7	62.7±23.0	N.S
CAPS	68.1±34.0	63.6±34.6	50.1±30.4	41.3±36.9	<0.05
WBC (4.0-10.8* 10 <sup>3</sup> /μl)					
TCD	9.7±4.9	7.5±1.7	9.3±0.4	8.3±1.3	N.S
CAPS	8.44±2.6	7.5±2.1	6.6±1.7	7.8±3.4	N.S

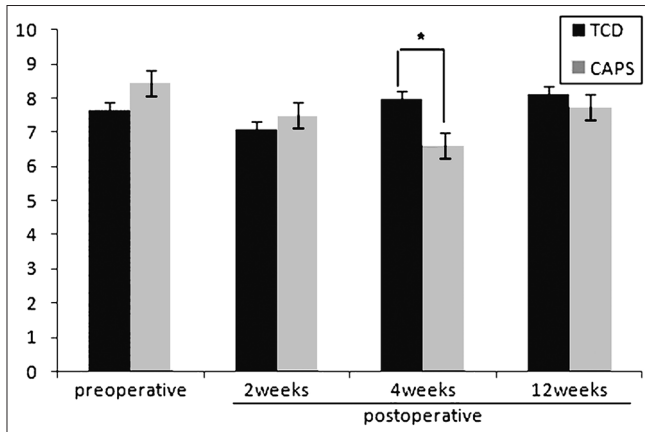
Statistical analysis by Friedman test, and  $P < 0.05$  is considered to be statistically significant. TCD = Transpedicular curettage and drainage, CAPS = Combined anterior and posterior surgery



**Figure 1:** A bar diagram showing C-reactive protein levels decreased significantly after surgery in both groups ( $P=0.013$  in the TCD group,  $P=0.029$  in the CAPS group, Friedman test) However, there was no significant difference between the groups ( $P$  value range 0.103-0.283 at each measure, Mann-Whitney U test) (normal range, 0-8 mg/L). TCD: Transpedicular curettage and drainage, CAPS: Combined anterior and posterior surgery



**Figure 2:** A bar diagram showing erythrocyte sedimentation rates decreased significantly only in the CAPS group. ( $P=0.048$  in the CAPS group,  $P=0.078$  in TCD group, Friedman test) There was no significant difference between the two groups ( $P$  value range 0.100-0.540, Mann-Whitney U test) (normal range, 0-35 mm/h). TCD: Transpedicular curettage and drainage, CAPS: Combined Anterior and Posterior Surgery



**Figure 3:** A bar diagram showing white blood cell counts did not decrease significantly in both groups. There was significant difference between the two groups at postoperative 4 weeks ( $P=0.035$ , Mann-Whitney U test), but no clinical significance was found (normal range, 4.0-10.8\*10<sup>3</sup>/μl) TCD: Transpedicular curettage and drainage, CAPS: Combined anterior and posterior surgery

quality during outpatient clinic followup in the TCD group. However, no additional surgical procedure was required. All patients in the TCD group showed spontaneously healed fusion during followup [Figure 4], except for this one patient. Local flat back and/or losses of lordosis were confirmed as a result of spontaneous fusion among them, but patients did not complain of this postural change.

One patient in the CAPS group had neurological deficit of neurogenic bladder after surgery. Three patients had operation wound-related complication including wound dehiscence and discharge. One patient exhibited loosening of pedicular screws with progression of the local kyphotic change because of a downward rotatory migration of the grafted tricortical iliac bone block due to poor osteoporotic

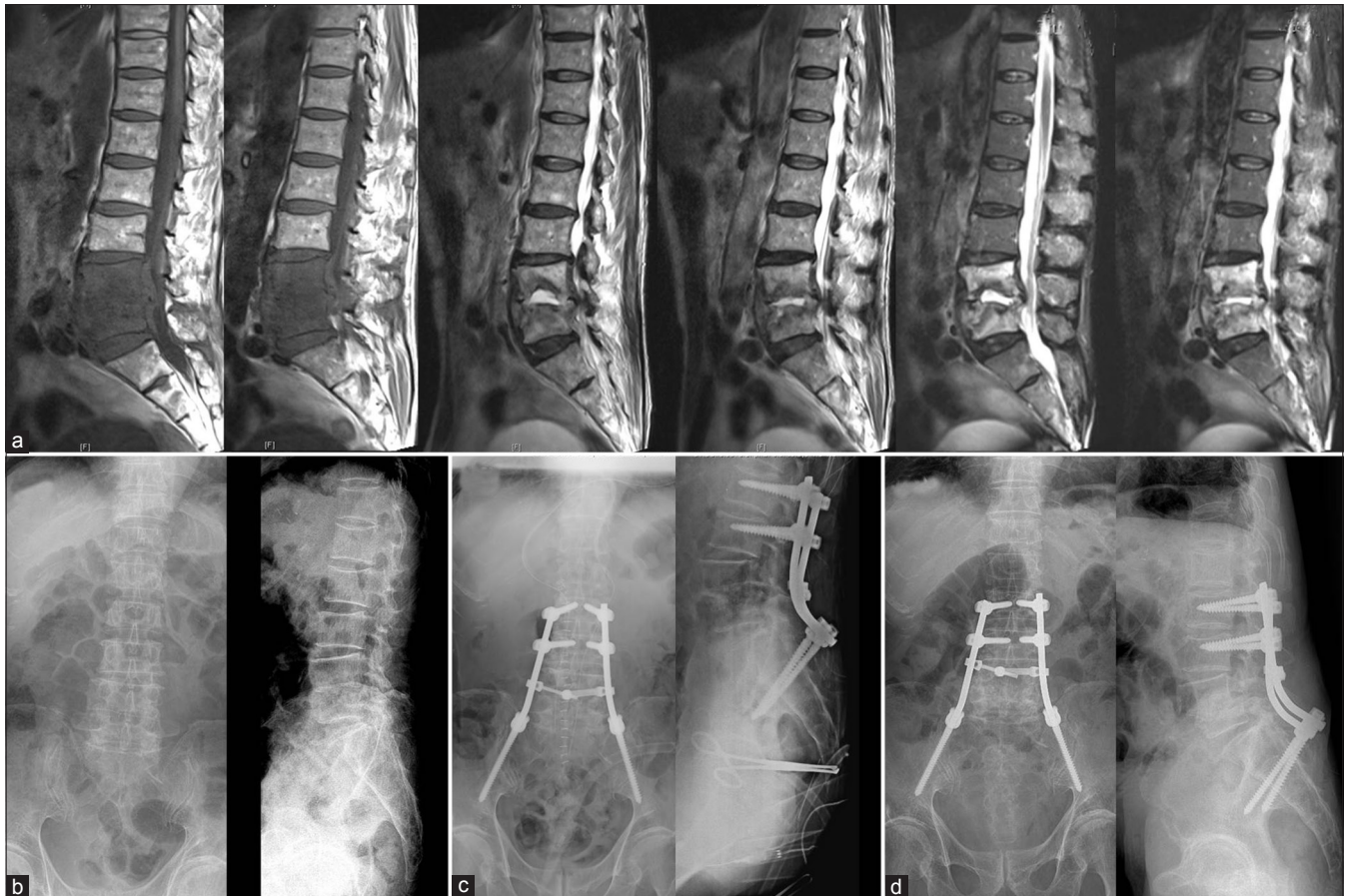bone quality. Conclusively, this patient underwent additional posterior surgery to extend one cephalad instrumented level and one caudal instrumented level of pedicle screws to secure mechanical stability.

In the TCD group, one patient was readmitted for administration of intravenous antibiotics after hospital discharge because of a recurrent fever. After additional 2 weeks of parenteral antibiotics therapy, the patient was able to leave the hospital without any other pyretic events. No patients in the CAPS group were readmitted due to pyretic event.

## DISCUSSION

In the CAPS group, patients experienced longer operation time and longer postoperative hospital stays compared to the TCD group. Among the patients in the CAPS group, 11 of 16 patients had multiple comorbidities such as diabetes mellitus, hypertension, chronic renal failure, liver cirrhosis. These comorbidities could be the reason why CAPS necessitates a longer operative period and a longer postoperative recovery than expected.

Among parameters of the statistical significance between the two groups [Table 1], an emphasis on the postoperative independent ambulation time required. The gap between the two groups to start independent ambulation was more than 2 weeks even with older age and more comorbidities in the TCD group. Therefore, the patients who belonged to the CAPS group stayed in bed longer due to longer stays in the intensive care unit [Table 1] and the interval between anterior and posterior surgeries compared with those who



**Figure 4:** Image study of a 78-year old male patient including (a) preoperative MRI, (b) pre and (c) immediate postoperative X-ray, and (d) postoperative X-ray at 1 year followup showing preoperative destruction of vertebral body had spontaneously fused without the need for anterior strut bone graft after the TCD procedure on X-rays at 1 year postoperative followup

underwent a single TCD procedure. The CAPS patients' poor conditions, which did not allow them to undergo CAPS in a single day, also delayed recovery from the repetitive surgical stresses hampered the start of independent ambulation. As a result, most of patients in the CAPS group were recommended to start with stepwise physical therapy such as a tilt table and a parallel bar walking to encourage independent walking. Although the patients in the TCD group had similar co-existing morbidities with those in the CAPS group, they recovered more quickly from the single surgery.

It is well known that a longer bed rest causes higher complication and mortality rates in critically ill patients, causing disuse muscle atrophy, joint contractures, thromboembolic disease, atelectasis, and insulin resistance.<sup>17,20-26</sup> Disuse atrophy could hamper the early restoration of walking ability and earlier discharge of patients from hospital after surgery. The subsequent longer hospital stays are accompanied with the loss of quality of life and psychological weakness.<sup>28-30</sup> Hence, earlier ambulation and shorter hospitalization in TCD compared to CAPS provided a profound clinical benefit.

The total period of antibiotics administration was slightly longer in the TCD group compared with the CAPS group that it is our practice to administer antibiotics until three consecutive normal levels of serologic inflammatory markers different from other study.<sup>19</sup> This could be from the unique characteristic of TCD procedure. TCD procedure approaches the affected area only from the posterior position, allowing peri-vertebral abscesses a higher chance to remain in the area, which means the infection foci are unable to be evacuated completely. This concept has important limitation in way that the purpose of surgery is to remove the infective and necrotic material but this surgery could not remove the infective material in disc space and paravertebral area completely. These could weaken the surgical effect of this TCD procedure. However, vertebral osteomyelitis could be diminished to soft tissue infection by TCD, which is a better suitable condition for complete cure with continuous usage of antibiotics. Aggressiveness of the surgical techniques might be weighed against the benefits, spinal surgeons can decide most optimal surgical techniques in treating patients with these hematogeneous infectious spondylodiscitis by leveraging risk and benefit, especially in fragile patients who could not bear CAPS in a single day.

The amounts of blood loss in the TCD group were not less than those of the CAPS group in spite of short duration of operation time. This is due to bleeding through the punched pedicle holes on the infected vertebrae. Direct bone bleeding could not be controlled during the TCD procedure; therefore, cardiovascular stresses should be kept in mind and managed properly under good cooperation with an anesthesiologist. However, postoperative drainage through punched pedicle seems to render additional beneficial effect on clearing up vertebral osteomyelitis.

Limitations of study are that sample size is small ( $n = 26$ ). We included only the hematogeneous infectious spondylodiscitis in the present study. Regardless of the limited number of patients due to exclusion of iatrogenic spondylodiscitis, the surgical outcomes in the group of critically ill patients could be demonstrated successfully. Another limitation is the lack of a health-related quality of life (HRQOL) and disease-specific outcome measurement such as Euro-Qol-5D (EQ-5D) and the Oswestry index score due to the retrospective design.

In conclusion, TCD, which is a less aggressive and simpler surgical approach, rendered comparable clinical recovery for treating hematogeneous infectious spondylodiscitis in patients who were in poor health with multiple comorbidities and were unable to undergo the conventional combined anterior and posterior surgery.

## REFERENCES

- Müller EJ, Russe OJ, Muhr G. Osteomyelitis of the spine. *Orthopade* 2004;33:305-15.
- Okada Y, Miyamoto H, Uno K, Sumi M. Clinical and radiological outcome of surgery for pyogenic and tuberculous spondylitis: Comparisons of surgical techniques and disease types. *J Neurosurg Spine* 2009;11:620-7.
- Dimar JR, Carreon LY, Glassman SD, Campbell MJ, Hartman MJ, Johnson JR. Treatment of pyogenic vertebral osteomyelitis with anterior debridement and fusion followed by delayed posterior spinal fusion. *Spine (Phila Pa 1976)* 2004;29:326-32.
- McGuire RA, Eismont FJ. The fate of autogenous bone graft in surgically treated pyogenic vertebral osteomyelitis. *J Spinal Disord* 1994;7:206-15.
- Calderone RR, Larsen JM. Overview and classification of spinal infections. *Orthop Clin North Am* 1996;27:1-8.
- Ghanayem AJ, Zdeblick TA. Cervical spine infections. *Orthop Clin North Am* 1996;27:53-67.
- Graziano GP, Sidhu KS. Salvage reconstruction in acute and late sequelae from pyogenic thoracolumbar infection. *J Spinal Disord* 1993;6:199-207.
- Abramovitz JN, Batson RA, Yablon JS. Vertebral osteomyelitis. The surgical management of neurologic complications. *Spine (Phila Pa 1976)* 1986;11:418-20.
- Fukuta S, Miyamoto K, Masuda T, Hosoe H, Kodama H, Nishimoto H, et al. Two-stage (posterior and anterior) surgical treatment using posterior spinal instrumentation for pyogenic and tuberculous spondylitis. *Spine (Phila Pa 1976)* 2003;28:E302-8.
- Carragee EJ. Instrumentation of the infected and unstable spine: A review of 17 cases from the thoracic and lumbar spine with pyogenic infections. *J Spinal Disord* 1997;10:317-24.
- Chen WJ, Wu CC, Jung CH, Chen LH, Niu CC, Lai PL. Combined anterior and posterior surgeries in the treatment of spinal tuberculous spondylitis. *Clin Orthop Relat Res* 2002;398:50-9.
- Dietze DD Jr, Fessler RG, Jacob RP. Primary reconstruction for spinal infections. *J Neurosurg* 1997;86:981-9.
- Fayazi AH, Ludwig SC, Dabbah M, Bryan Butler R, Gelb DE. Preliminary results of staged anterior debridement and reconstruction using titanium mesh cages in the treatment of thoracolumbar vertebral osteomyelitis. *Spine J* 2004;4:388-95.
- Lee MC, Wang MY, Fessler RG, Liauw J, Kim DH. Instrumentation in patients with spinal infection. *Neurosurg Focus* 2004;17:E7.
- Rath SA, Neff U, Schneider O, Richter HP. Neurosurgical management of thoracic and lumbar vertebral osteomyelitis and discitis in adults: A review of 43 consecutive surgically treated patients. *Neurosurgery* 1996;38:926-33.
- Perronne C, Saba J, Behloul Z, Salmon-Céron D, Lepoutre C, Vildé JL, et al. Pyogenic and tuberculous spondylodiskitis (vertebral osteomyelitis) in 80 adult patients. *Clin Infect Dis* 1994;19:746-50.
- Lee BH, Lee HM, Kim TH, Kim HS, Moon ES, Park JO, et al. Transpedicular curettage and drainage of infective lumbar spondylodiscitis: Technique and clinical results. *Clin Orthop Surg* 2012;4:200-8.
- Aronson WL, McAuliffe MS, Miller K. Variability in the American Society of Anesthesiologists Physical Status Classification Scale. *AANA J* 2003;71:265-74.
- Zarghooni K, Rölinghoff M, Sobottke R, et al. Treatment of spondylodiscitis. *Int Orthop*. 2012;36:405-11.
- Chester JG, Rudolph JL. Vital signs in older patients: Age-related changes. *J Am Med Dir Assoc* 2011;12:337-43.
- Lu DC, Lau D, Lee JG, Chou D. The transpedicular approach compared with the anterior approach: An analysis of 80 thoracolumbar corpectomies. *J Neurosurg Spine* 2010;12:583-91.
- Lee TC, Lu K, Yang LC, Huang HY, Liang CL. Transpedicular instrumentation as an adjunct in the treatment of thoracolumbar and lumbar spine tuberculosis with early stage bone destruction. *J Neurosurg* 1999;91(Suppl 2):163-9.
- Kim NH, Lee JW. Anterior interbody fusion versus posterolateral fusion with transpedicular fixation for isthmic spondylolisthesis in adults. A comparison of clinical results. *Spine (Phila Pa 1976)* 1999;24:812-6.
- Lee TC. Transpedicular reduction and stabilization for postlaminectomy lumbar instability. *Acta Neurochir (Wien)* 1996;138:139-44.
- Chen IH, Hou CH, Huang CI, Lee LS. Measurement of Chinese lumbar pedicles: With special reference to transpedicular screw fixation. *Zhonghua Yi Xue Za Zhi (Taipei)* 1994;53:351-6.
- Hespeel P, Op't Eijnde B, Van Leemputte M, Ursø B, Greenhaff PL, Labarque V, et al. Oral creatine supplementation facilitates the rehabilitation of disuse atrophy and alters the expression of muscle myogenic factors in humans. *J Physiol* 2001;536:625-33.
- Veldhuizen JW, Verstappen FT, Vroemen JP, Kuipers H, Greep JM. Functional and morphological adaptations following four weeks of knee immobilization. *Int J Sports Med* 1993;14:283-7.
- Desai SV, Law TJ, Needham DM. Long term complications of critical care. *Crit Care Med* 2011;39:371-9.
- Bilotta C, Bowling A, Nicolini P, Casè A, Pina G, Rossi SV, et al. Older Peoples Quality of Life (OPQOL) scores and adverse health outcomes at a one-year followup. A prospective cohort

study on older outpatients living in the community in Italy. *Health Qual Life Outcomes* 2011;9:72.

30. Jeitziner MM, Hantikainen V, Conca A, Hamers JP. Long term consequences of an intensive care unit stay in older critically ill patients: Design of a longitudinal study. *BMC Geriatr* 2011;11:52.

**How to cite this article:** Lee BH, Park J, Kim H, Lee H, Cho B, Moon S. Transpedicular curettage and drainage versus combined anterior and posterior surgery in infectious spondylodiscitis. *Indian J Orthop* 2014;48:74-80.

**Source of Support:** Nil, **Conflict of Interest:** None.