

Brain Abscess due to *Staphylococcus lugdunensis* in the Absence of Endocarditis or Bacteremia

Andreia Matas Andreia Veiga João Paulo Gabriel

Centro Hospitalar Trás-os-Montes-e-Alto-Douro, [Vila Real](#), Portugal

Key Words

Staphylococcus lugdunensis · Brain abscess · Coagulase-negative staphylococcus

Abstract

Staphylococcus lugdunensis has been recognized to be a microorganism potentially more virulent than other coagulase-negative staphylococci. We report the case of a patient who presented with a single, large, right, frontoparietal abscess that evolved despite conventional antibiotic treatment. Bacteremia and endocarditis were excluded. After surgical treatment, *S. lugdunensis* sensible to trimethoprim-sulfamethoxazole was isolated, and the patient responded favorably to treatment. Although the ability of *S. lugdunensis* to produce brain abscesses has been recognized, we report a case of a brain abscess in the absence of bacteremia or endocarditis.

© 2015 S. Karger AG, Basel

Introduction

Staphylococcus lugdunensis, one of the coagulase-negative staphylococci, was first described by Freney et al. [1] in 1988. While originally thought to be a skin commensal rarely responsible for opportunistic infection, it was rapidly established as a significant human pathogen and is now recognized to be a microorganism potentially more virulent than other coagulase-negative staphylococci [2].

S. lugdunensis infections are clinically indistinguishable from infections caused by *S. aureus*, and the ability of this pathogen to cause abscesses is known [3]. The most frequent infection reported in the literature is acute endocarditis, but osteomyelitis, peritonitis, intravascular catheter infections, prosthetic joint infections, and urinary tract infections have also been reported [4]. Cerebral ischemia can also be a potential serious complication of infections that affect the central nervous system [5].

As *S. lugdunensis* is part of the normal human skin flora and commonly colonizes the perineal region, a perineal source of infection has been suspected, although this hypothesis is still controversial. There is evidence that *S. lugdunensis* might be a commensal in areas with apocrine sweat glands (axilla, anogenital region, auditory canals, eyelids, and mammary areolae) [4, 6]. Here, we report the case of a patient who presented with a brain abscess in the absence of bacteremia or endocarditis.

Case Report

A 59-year-old man with an unremarkable medical history presented with an acute state of confusion, fever and two episodes of generalized tonic-clonic seizures on that day. On admission, the patient was febrile (tympanic temperature of 38.1°C), his blood pressure was 137/79 mm Hg with a pulse rate of 103 beats/min, his respiratory rate was 16/min, and his oxygen saturation was 98% at room air. There were no murmurs or other abnormalities on cardiac auscultation, and examination of the respiratory system, the abdomen and anogenital region was normal. The neurological examination revealed psychomotor inhibition and left homonymous hemianopsia, without any motor abnormalities or other neurological deficits.

There were no abnormalities found on the laboratory studies (hemoglobin 15.23 g/dl, white blood cell count $8.70 \times 10^3/\mu\text{l}$, C-reactive protein 0.5 mg/dl, erythrocyte sedimentation rate 11 mm/h), including negative results on the immunological study, seronegative status for HIV and negative serological tumor markers.

A brain magnetic resonance imaging (MRI) scan revealed a single, large, right, frontoparietal lesion. Cerebrospinal fluid analysis showed no abnormalities, including negative results for DNA of HSV 1 and 2, *Mycobacterium tuberculosis*, toxoplasmosis, and JC virus. A repeated brain MRI scan showed a worsening of the lesion, and the hypothesis of brain abscess was strongly considered (fig. 1). Treatment with ceftriaxone (2 g i.v. every 12 h) combined with metronidazole (500 mg i.v. every 6 h) and dexamethasone (5 mg i.v. every 8 h) was started. Seizures were controlled with levetiracetam (500 mg p.o. every 12 h). There was no evidence of paroxysmal activity on the electroencephalogram, and contrast-enhanced computed tomography of the chest, abdomen and pelvis resulted negative. Blood and urine cultures were obtained before starting antibiotic therapy, also with negative results. Endocarditis was ruled out by a normal transesophageal echocardiogram.

After 4 weeks of antibiotic therapy, although the neurological exam was normal, the patient again became febrile and symptomatic, complaining of a severe headache that evolved for 4 days, throbbing in nature and precipitated by Valsalva maneuver. Another brain MRI was performed, with evidence of further worsening of the lesion (fig. 2).

Given the lack of evidence of a resolution of the lesion and the persistence of neurological symptoms, surgical drainage was performed with isolation of *S. lugdunensis*. The antibiogram of the isolated microorganism disclosed susceptibility to trimethoprim-sulfamethoxazole, methicillin, gentamicin, and erythromycin. Transesophageal echocardiogram and blood cultures were then repeated, again with negative results.

Treatment with trimethoprim-sulfamethoxazole (5 mg/kg p.o. every 6 h) was performed during 12 weeks with a good response. There was also a favorable imaging response, with brain MRI undertaken a month after starting this therapy revealing almost complete resolution of the brain abscess (fig. 3). After 6 months of follow-up, the patient remains asymptomatic, and his neurological exploration is unremarkable.

Discussion

We report the case of a cerebral abscess caused by *S. lugdunensis* in the absence of bacteremia or endocarditis. No perineal lesion was identified in this patient, and there was no evidence of any other route of infection.

It is possible that *S. lugdunensis* is currently being underdiagnosed, as it can be misidentified as *S. aureus* or *S. schleiferi* because colonies of these organisms have similar morphologies, and all give positive results in tests for clumping factor [5]. Also, as biochemical phenotypic systems designed for the identification of coagulase-negative staphylococci do not appear to be species specific and are hardly reliable in the discrimination of *S. lugdunensis* from other staphylococci, its precise identification requires fine molecular methods [2].

The present case of cerebral abscess was successfully managed using surgical treatment followed by 12 weeks of antibiotherapy. However, the optimal duration of antimicrobial therapy for brain abscesses, alone or related to endocarditis, is not yet known. Emerging evidence suggests that it should be determined individually, based on the size of the abscess, combination of surgical treatment, causative organism, and response to treatment [7]. Most authors agree on a long-term treatment, and it seems prudent to consider a period of 4–6 weeks for surgically treated abscesses, and 6–8 weeks for those treated solely with antibiotics or for multiple brain abscesses when the larger ones are treated surgically [3, 7, 8].

The *S. lugdunensis* isolated in this case was methicillin sensitive, but cases of resistance to methicillin have already been described in China, Brazil, and Europe [9]. It is hypothesized that small changes in environmental parameters can lead to alterations in cell morphology and in the membrane fatty acid composition of *S. lugdunensis*, ultimately contributing to the emergence of antibiotic resistance [10].

References

- 1 Freney J, Brun Y, Bes M, Meugnier H, Grimont F, et al: *Staphylococcus lugdunensis* sp. nov. and *Staphylococcus schleiferi* sp. nov., two species from human clinical specimens. *Int J Syst Bacteriol* 1988;38:168–172.
- 2 Ravaioli S, Selan L, Visai L, et al: *Staphylococcus lugdunensis*, an aggressive coagulase-negative pathogen not to be underestimated. *Int J Artif Organs* 2012;35:742–753.
- 3 Gianella S, Ulrich S, Huttner B, Speich R: Conservative management of a brain abscess in a patient with *Staphylococcus lugdunensis* endocarditis. *Eur J Clin Microbiol Infect Dis* 2006;25:476–478.
- 4 Böcher S, Tønning B, Skov RL, Prag J: *Staphylococcus lugdunensis*, a common cause of skin and soft tissue infections in the community. *J Clin Microbiol* 2009;47:946–950.
- 5 Arboix A, Bechich S, Oliveres M, García-Eroles L, Massons J, Targa C: Ischemic stroke of unusual cause: clinical features, etiology and outcome. *Eur J Neurol* 2001;8:133–139.
- 6 Kaabia N, Scauarda D, Lena G, Drancourt M: Molecular identification of *Staphylococcus lugdunensis* in a patient with meningitis. *J Clin Microbiol* 2002;40:1824–1825.
- 7 Alvis Miranda H, Castellar-Leones SM, Elzain MA, Moscote-Salazar LR: Brain abscess: current management. *J Neurosci Rural Pract* 2013;4(suppl 1):S67–S81.
- 8 Helweg-Larsen J, Astradsson A, Richhall H, Erdal J, Laursen A, Brennum J: Pyogenic brain abscess, a 15 year survey. *BMC Infect Dis* 2012;12:332.
- 9 Bhumbra S, Mahboubi M, Blackwood RA: *Staphylococcus lugdunensis*: novel organism causing cochlear implant infection. *Infect Dis Rep* 2014;6:5406.
- 10 Crompton MJ, Dunstan RH, Macdonald MM, Gottfries J, von Eiff C, Roberts TK: Small changes in environmental parameters lead to alterations in antibiotic resistance, cell morphology and membrane fatty acid composition in *Staphylococcus lugdunensis*. *PLoS One* 2014;9:e92296.

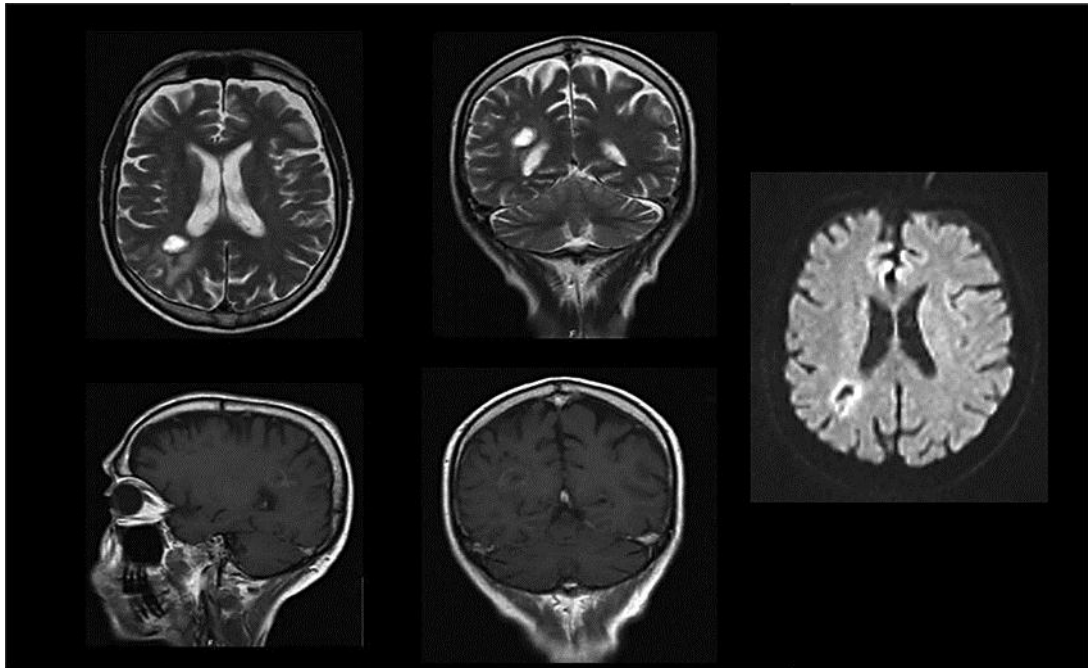


Fig. 1. MRI of the brain revealing a single, large, right, frontoparietal, ring-enhancing lesion with high signal intensity on T2-weighted images, low signal intensity on T1-weighted images and restricted diffusion on diffusion-weighted images.

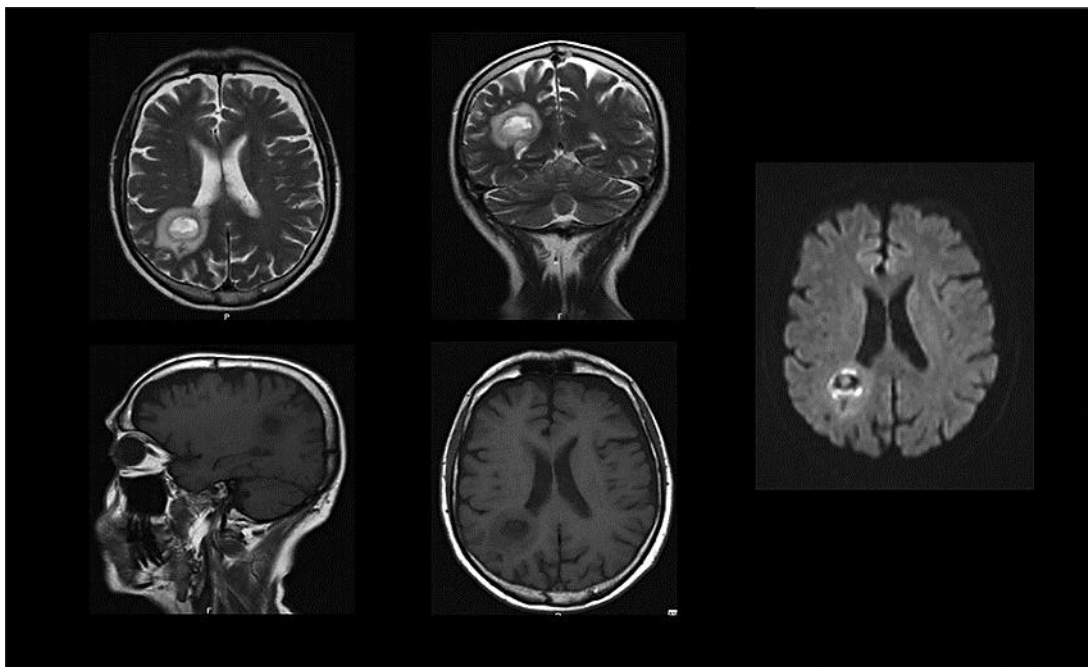


Fig. 2. MRI of the brain showing worsening of the right frontoparietal lesion after 4 weeks of treatment with ceftriaxone combined with metronidazole. On T2-weighted images, the central abscess is hyperintense, with a hypointense surrounding capsule and extensive surrounding edema.

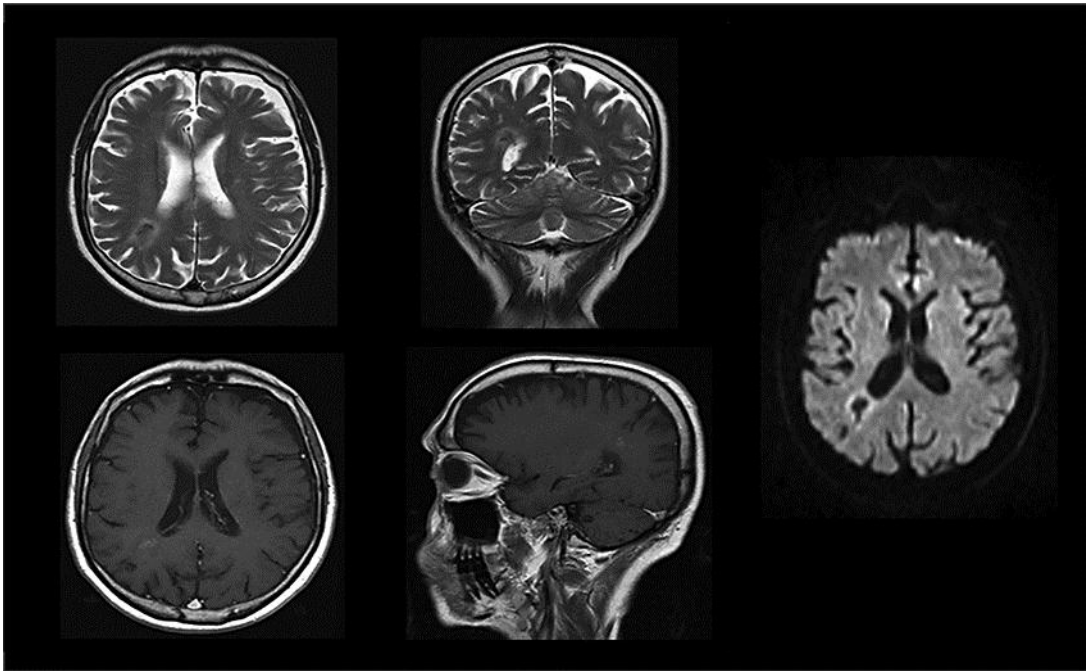


Fig. 3. MRI of the brain evidencing almost complete resolution of the cerebral abscess after 12 weeks of treatment with trimethoprim-sulfamethoxazole.