

## CASE REPORT

doi: 10.5455/medarch.2017.71.69-71

Med Arch. 2017 Feb; 71(1): 69-71

Received: DEC 15, 2016 | Accepted: JAN 20, 2017

© 2017 Marco Abbondanza, Gabriele Abbondanza, Valentina De Felice

This is an Open Access article distributed under the terms of the Creative Commons Attribution Non-Commercial License (<http://creativecommons.org/licenses/by-nc/4.0/>) which permits unrestricted non-commercial use, distribution, and reproduction in any medium, provided the original work is properly cited.

# Mini Asymmetric Radial Keratotomy and Corneal Cross-linking for the Treatment of a Bilateral Stage IV Keratoconus in a 14-year-old Child

Marco Abbondanza<sup>1</sup>, Gabriele Abbondanza<sup>2</sup>, Valentina De Felice<sup>1</sup>

<sup>1</sup>Abbondanza Eye Centers, Rome and Milan, Italy

<sup>2</sup>University of Sydney, Sydney (NSW), Australia

**Corresponding author:** Marco Abbondanza, MD, Abbondanza Eye Center, Via Luigi Bodio 72, 00191 Roma (RM), Italy. Tel: +39063207111. E-mail: [info@abbondanza.org](mailto:info@abbondanza.org)

## ABSTRACT

**Aim:** To present the case of a 14-year-old boy with bilateral stage IV keratoconus, treated with a combined MARK + CXL intervention, without the need for a corneal transplantation.

**Results:** The left eye displays considerable improvements, with a follow-up of 13.5 years: Kmax is decreased by 5.53 D, Kmed is decreased by 1.95 D and thinnest pachymetry is increased by 106 µm. The right eye shows equally remarkable parameters, with a follow-up of 9.5 years: Kmax is decreased by 8.16 D, Kmed is decreased by 0.38 D and thinnest pachymetry is increased by 52 µm. Keratoconus has been halted and the patient has a binocular best corrected visual acuity of -0.079 LogMAR (12/10). **Conclusion:** The MARK + CXL combined intervention, known as the "Rome Protocol", was successful in halting a bilateral stage IV keratoconus and improving visual acuity in a very young patient, with long-term follow-up. Conservative treatments should always be privileged when treating very young patients with developed stages of the pathology.

**Keywords:** keratoconus, cornea, mini asymmetric radial keratotomy, MARK, corneal collagen cross-linking, CXL.

## 1. INTRODUCTION

Keratoconus (KC) is a bilateral non-inflammatory corneal ectasia, generally manifested in the second decade of life, which results in progressive, bilateral and asymmetrical corneal distortion and thinning, altered refractive powers and reduced vision (1). Clearly identified in 1854 by John Nottingham, this degenerative disease requires an invasive intervention such as corneal transplantation in 15-20% of cases, although a number of conservative procedures has been developed. These are Corneal Collagen Cross-linking (CXL) (2), Intrastromal Corneal Ring Segments (ICRS) (3), Mini Asymmetric Radial Keratotomy (MARK) (4), Circular Keratotomy (CK and Fem-

toCK) (5) and Conductive Keratoplasty (CKP).

Corneal Cross-linking, the most recent among these, is widely regarded as the golden standard in the treatment of KC, due to the fact that it halts its progression and slightly reduces corneal curvature, if performed with epithelium removal. It is not intended, however, as a procedure to correct vision, a condition that has led to its combination with refractive procedures. Successful CXL-combined protocols have been reported with PRK, i-LASIK, ICRS, MARK (6), Phakic Intraocular Lenses (PIOL) and CKP (7). We report the case of a 14-year-old boy with a stage IV keratoconus in both eyes, which has been treated with a combined MARK + CXL intervention, known

as the “Rome Protocol”, with a maximum follow-up of over 13 years.

**2. CASE REPORT**

In 2003 a 14-year-old boy presented with a bilateral keratoconus in considerably advanced stage, diagnosed the previous year. The patient underwent a thorough clinical examination prior to the intervention, which included measurement of uncorrected (UCVA) and best corrected visual acuity (BCVA), corneal topography, axial biometry, pachymetry, endothelial cell count, keratometry and slit lamp examination. A written informed consent was required as a part of our pre-operative routine. The patient’s left eye, in worse conditions, had a Kmax of 61.53 dioptres (D), a Kmed of 46.25 D and thinnest pachymetry of 410 microns (µm), whereas the right eye showed a Kmax of 55.86 D, a Kmed of 44.38 D and thinnest pachymetry of 475 µm (Figure 1).

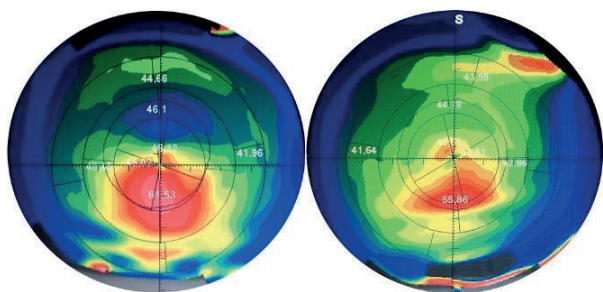


Figure 1. Axial map of the left and right eye before the combined intervention. Kmax was, respectively, 61.53 D and 55.86 D

**3. MARK SURGERY**

Given the rapid progression of the disease and the increasing visual impairment it produced, Mini Asymmetric Radial Keratotomy (MARK) was performed on the left eye in 2003 and on the right eye in 2007. MARK was first developed by the author (M.A.) in 1993 and consists of a small series of micro-incisions performed with a diamond knife and a double concentric corneal marker, known as the “Abbondanza marker”. MARK incisions are topography- and tomography-guided with the aim of flattening only the portion of cornea where keratoconus is manifest – thus avoiding excessive flattening and favoring a stable outcome – and are always performed to a maximum of 7.5-8 mm on the external end and a

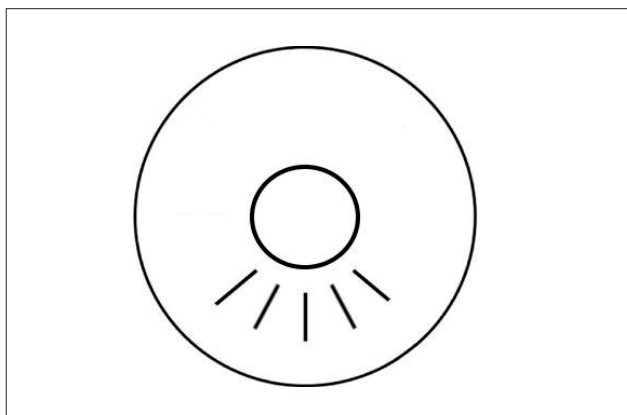


Figure 2. Diagram of MARK micro-incisions

minimum of 3.5-4 mm on the internal end, at 80 to 90% of corneal thickness (Figure 2). Topical anesthesia was applied prior to the treatment with benoxinate chloride 0.4% drops. Following the intervention, a bandage contact lens was placed and topical antibiotics and non-steroidal anti-inflammatory drops were prescribed. Postoperative conditions were regularly checked, showing the stabilization of both eyes.

**CXL treatment**

In order to further strengthen the patient’s corneal tissue, Corneal Cross-linking with epithelium removal (Dresden protocol) was performed on both eyes in 2013. Following topical anesthesia, the removal of corneal epithelium was performed using an ophthalmic scalpel (MicroFeather, Feather Safety Razor Co. Ltd., Osaka, Japan), while riboflavin eye drops (B2 vitamin) were applied on the corneal stroma 30 minutes before the procedure, 10 times at 3 minute intervals. Riboflavin was then applied 6 times at 5 minute intervals during UV-A irradiation. The UV-A source used was the UV-X illumination system, version 1000, from IROC AG, Switzerland, while total UV-A exposure time was 30 minutes. Following CXL, a bandage contact lens was placed and topical antibiotics and non-steroidal anti-inflammatory drops were prescribed.

**4. RESULTS**

13 years and a half after MARK surgery and 3 years and a half after CXL treatment, the patient’s left eye showed considerably improved topographic and tomographic parameters (Table 1): Kmax was 56 D, Kmed was 44.3 D and thinnest pachymetry measured 516 µm. The right eye, 9 years and a half after MARK and 3 years after CXL, also presented significantly improved values: Kmax of 47,7 D, Kmed of 44 D and thinnest pachymetry of 527 µm (Figure 3). During the latest examination, the

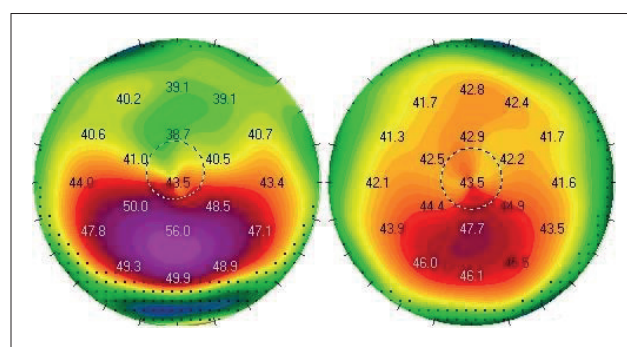


Figure 3. Axial map of the left and right eye after the combined intervention. Kmax was, respectively, 56 D and 47.7 D

	Kmax	Kmed	Thinnest pachymetry
Before MARK + CXL (OS)	61.53	46.25	410
(OD)	55.86	44.38	475
After MARK + CXL (OS)	56	44.3	516
(OD)	47.7	44	527
Difference (OS)	- 5.53	- 1.95	+ 106
(OD)	- 8.16	- 0.38	+ 52

Table 1. Pre- and post-MARK + CXL values, with 13.5 years of follow-up for the left eye and 9.5 years for the right eye

patient had a BCVA of 0.045 LogMAR (9/10) with both eyes and a binocular BCVA of -0.079 LogMAR (12/10).

## 5. DISCUSSION

Mini Asymmetric Radial Keratotomy has been used for more than two decades as a treatment for progressive keratoconus in early stages, showing positive and stable results from the short to the long term. Its micro-incisions (approximately 2 mm) and the limited angular span of the cornea they involve (only where KC is localized) are the main differences with the old RK, producing a considerably more stable result compared to that of the latter, a condition that is extremely significant when treating this corneal ectasia. Corneal Collagen Cross-linking, on the other hand, successfully halts the progression of KC, although with only a slight degree of corneal regularization, quantified in 1.2 D with epithelium removal (8).

The increased corneal strength and thickness resulting from CXL, along with the lack of any invasive procedure involved, have therefore led to a series of combined protocols, where CXL is paired with other refractive interventions and is thus named “Cross-linking Plus”. The experience with MARK surgery, conceived by the author, and that with CXL treatment, performed by our team since 2005, brought us to the development of the MARK + CXL combined procedure, the “Rome Protocol”.

It is a valid therapeutic option for patients affected by keratoconus that are contact lens intolerant and have inadequate vision with spectacles, due to high irregular astigmatism. This indication can be extended to selected patients that are especially prone to develop superficial and centrally located corneal scars secondary to extended contact lens use. Moreover, it is important to remind the this combined intervention does not preclude any other invasive procedure, as MARK micro-incisions don't extend beyond a corneal diameter of 8 mm peripherally, which means they are included in the diameter of corneal tissue to be substituted in case of corneal transplantation.

## 6. CONCLUSION

Today we witness a threefold set of improvements when treating keratoconus: the availability of more accurate instruments for the diagnosis of KC; a deeper knowledge of it by both doctors and patients and, lastly,

more therapeutic options, represented by conservative treatments such as those outlined in the introduction but also by less invasive corneal transplantations. It is worth reminding that keratoconus can be insidious, especially when developed in young patients, a group in which it generally progresses more rapidly. In our case, the MARK + CXL combined procedure was effective in halting the progression of KC and considerably improving visual acuity of a 14-year-old patient with bilateral stage IV keratoconus, whose conditions have been stable for a long period of observation. Conclusively, it is important to underline that conservative treatments should always be privileged when treating keratoconus, particularly when dealing with very young patients with developed stages of the pathology.

• Conflict of interest: none declared.

## REFERENCES

1. Rabinowitz YS. Keratoconus. *Survey of Ophthalmology*. 1998; 42(4): 297-319.
2. Wollensak G, Spoerl E, Seiler T. Riboflavin/ultraviolet-a-induced collagen crosslinking for the treatment of keratoconus. *American Journal of Ophthalmology*. 2003; 135(5): 620-7.
3. Colin J, Cochener B, Savary G, Malet F. Correcting keratoconus with intracorneal rings. *Journal of Cataract and Refractive Surgery*. 2000; 26(8): 1117-22.
4. Abbondanza M. Asymmetric radial keratotomy for the correction of keratoconus. *Journal of Refractive Surgery*. 1997; 13(3): 302-7.
5. Krumeich JH, Hirschschall N. Effect of Circular Keratotomy on Progression of Keratoconus. *International Journal of Keratoconus and Ectatic Corneal Diseases*. 2016; 5(2): 57-62.
6. Abbondanza M, Abdolrahimzadeh B, Guidobaldi M. Combined Corneal Collagen Cross-linking and Mini Asymmetric Radial Keratotomy for the Treatment of Keratoconus. *Acta Medica International*. 2016; 3(1): 63-8.
7. Kymionis GD, Kontadakis GA, Naoumidi TL, Kazakos DC, Giapitzakis I, Pallikaris I. Conductive Keratoplasty Followed by Collagen Cross-Linking With Riboflavin-UV-A in Patients With Keratoconus. *Cornea*. 2010; 29(2): 239-43.
8. Abbondanza M, Abdolrahimzadeh B, Zuppardo M. Refractive Changes Following CXL. *Cataract and Refractive Surgery Today Europe*. 2009; 4(7): 33-8.