

MINI-FOCUS ISSUE: ARRHYTHMIAS AND EP

BEGINNER

CASE REPORT: CLINICAL CASE

# Inadvertent Disabling of Implantable Cardiac Defibrillator Antitachycardia Therapies Following Breast Reconstructive Surgery



Paulina R. Skaff, MD, Bridget S. Phillips, PA-C, John H. Lobban, MD, Christopher M. Bianco, DO

## ABSTRACT

A 47-year-old woman with an implantable cardiac defibrillator and breast cancer underwent left breast mastectomy with simultaneous reconstruction using a breast tissue expander. She was found to have intermittent disabling of tachyarrhythmia detection and therapy functions of her implantable cardiac defibrillator that were triggered by the breast tissue expander magnetic port. (**Level of Difficulty: Beginner.**) (J Am Coll Cardiol Case Rep 2020;2:1753-6)

© 2020 The Authors. Published by Elsevier on behalf of the American College of Cardiology Foundation. This is an open access article under the CC BY-NC-ND license (<http://creativecommons.org/licenses/by-nc-nd/4.0/>).

A 47-year-old woman presented with complaints of a sporadic, high-pitched beeping sound and a vibration sensation coming from her chest for 1-day duration. Two days before her presentation she had undergone a left breast mastectomy with immediate reconstruction using a

Mentor Aurora breast tissue expander (Johnson and Johnson, New Brunswick, New Jersey) for grade 1 invasive lobular breast carcinoma. A magnet was used during the operation, and postoperative implantable cardiac defibrillator (ICD) interrogation demonstrated normal function. The operation was without immediate complication and she was discharged home the following day. Two days after discharge, the patient began to hear an intermittent high-pitched beeping sound. After turning off all of the electronics in the house, she soon realized that the sound and simultaneous vibration was originating from her chest. This was particularly notable whenever she leaned forward or raised her left arm. She denied any other signs or symptoms, and never experienced a syncopal episode or defibrillator shock. The patient presented to the emergency department where vitals were noted to be within normal limits and physical examination was unremarkable with the exception of a well-healing surgical wound.

## LEARNING OBJECTIVES

- To raise awareness of this potentially life-threatening interaction between magnetic components of breast tissue expanders (or other chest prostheses) and ICD function.
- To promote prompt recognition and rectification is necessary if this situation is encountered post-operatively.
- To understand that, if faced with this situation pre-operatively, clinicians should recommend use of alternative prostheses that do not have magnetic components.

From the West Virginia University, Department of Cardiovascular Medicine, Heart and Vascular Institute, Morgantown, West Virginia. The authors have reported that they have no relationships relevant to the contents of this paper to disclose.

The authors attest they are in compliance with human studies committees and animal welfare regulations of the authors' institutions and Food and Drug Administration guidelines, including patient consent where appropriate. For more information, visit the *JACC: Case Reports* [author instructions page](#).

Manuscript received March 31, 2020; revised manuscript received June 15, 2020, accepted July 1, 2020.

## ABBREVIATIONS AND ACRONYMS

ICD = implantable cardiac  
defibrillator

## PAST MEDICAL HISTORY

The patient had a history of spontaneous sustained monomorphic ventricular tachycardia with implantation of a single lead Medtronic implantable cardioverter-defibrillator (Model: Visia AF MRI VR DVT SB 1 D4) for secondary prevention approximately 1 year earlier and recently diagnosed grade 1, invasive lobular breast carcinoma with multifocal hormone positivity (estrogen receptor 95%, progesterone receptor 95%, human epidermal growth factor receptor 2/neu negative, Ki67 21%).

## DIFFERENTIAL DIAGNOSIS

The differential diagnosis of a high-pitched beeping sound and vibration over her ICD included cardiac device malfunction or deactivation from a number of potential mechanisms following left chest surgery.

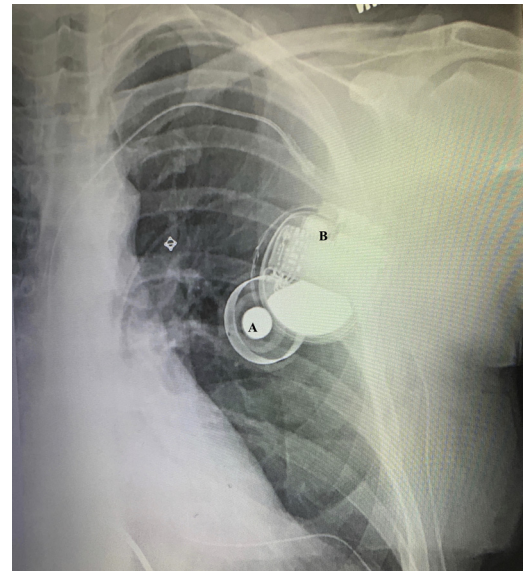
## INVESTIGATIONS

The patient presented to our facility where ICD interrogation showed normal function and stable pacing and sensing thresholds. However, after further inquiry it was discovered that the recently implanted breast expander had a magnetic port that intermittently disabled the tachyarrhythmia detection and therapy function of the ICD 23 times over the preceding 2 days. We deduced that when the patient leaned forward or raised her left arm, the magnetic port on the breast tissue expander came into close proximity to the defibrillator, leading to inhibition of tachyarrhythmia detection and therapies. The magnetic port and defibrillator relationship can be seen on the chest radiograph in [Figure 1](#) and the dynamic nature of the magnetic port and defibrillator with motion is depicted in the illustration in [Figure 2](#). We also suspect the magnetic port interaction became particularly prominent in the immediate days following surgery as her post-operative swelling subsided. Fortunately, she did not suffer from any malignant ventricular arrhythmias during these vulnerable periods of ICD deactivation.

## MANAGEMENT

The patient was admitted and underwent left breast tissue expander exchange involving the removal of the left breast magnetic port containing tissue expander and immediate implantation of a magnetic-free adjustable saline breast implant. Post-operative ICD interrogation showed appropriate device function and she was discharged home the same day.

**FIGURE 1** Chest Radiograph

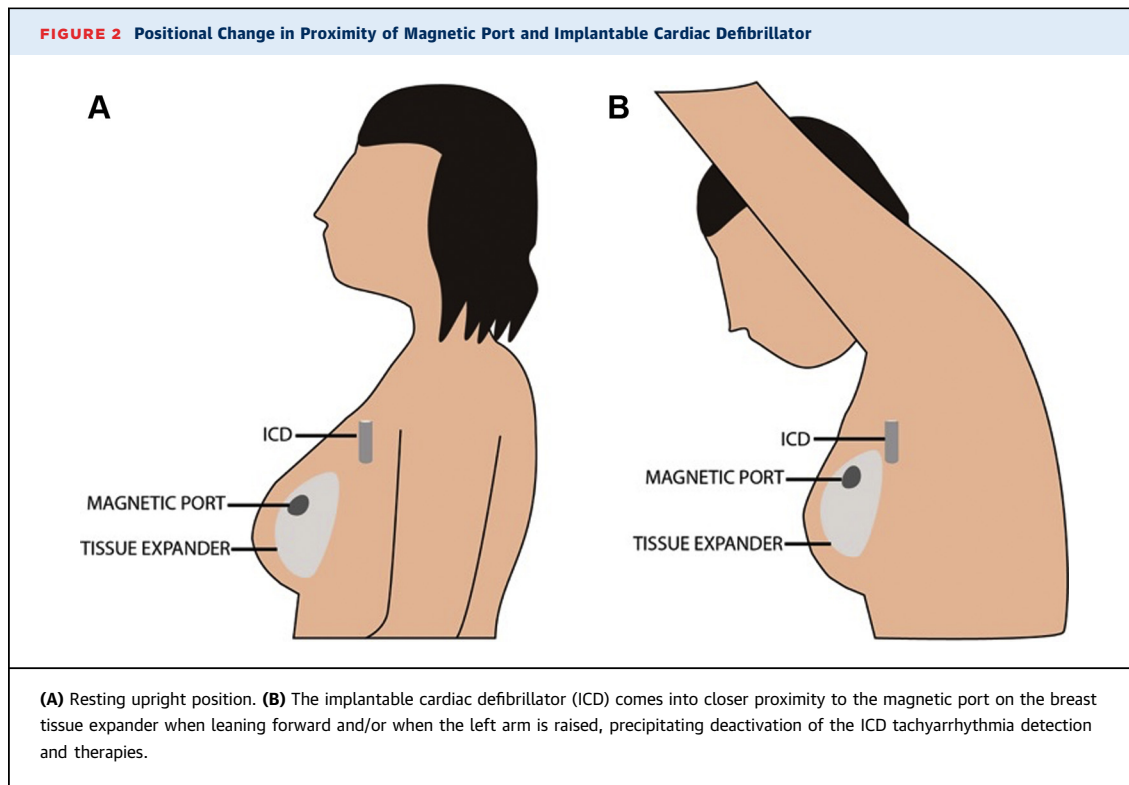


The magnetic port of the breast tissue expander (A) in close proximity to the implantable cardiac defibrillator can (B).

## DISCUSSION

Women in the United States have a 1 in 8 (or approximately 13%) lifetime risk of developing breast cancer (1). Advances in adjuvant chemo- and radiotherapy now allow for mastectomy with immediate breast reconstruction in many circumstances. Approximately 275,000 ICDs have been implanted in women in the United States over the past decade (2). The American Society of Plastic Surgeons reported that there were approximately 75,000 breast reconstructions in the United States using tissue expanders/implant in 2014 (3). Recent data suggest that heart disease, particularly heart failure, is an independent risk factor for developing cancer (4). Therefore, many women with an ICD will develop breast cancer and potentially undergo breast surgery. With the growth of cardio-oncology clinics throughout the country, this situation may be increasing faced by the cardiology community.

Reconstructive breast surgery frequently involves the use of breast tissue expanders that contain a magnetic injection port. The magnetic injection port facilitates targeted saline injections for implant expansion, thereby avoiding inadvertent needle puncture of the tissue expander itself. The minimum required field strength of a magnet to induce electromagnetic interference in a cardiac device is  $>10$



Gauss. In general, most magnets manufactured to deactivate ICDs have a field strength  $>90$  Gauss. Breast tissue expander magnetic ports generate a magnetic field ranging from 65 to 175 Gauss (5).

Implantable cardiac devices have various alert features in the form of audible signals and/or vibrations of varying length, tone, and patterns depending on the device manufacture and programming. These alerts are designed to signal if there is a change in the cardiac device, such as improper functioning. The functioning of implantable cardiac devices can be altered with a magnet. Depending on the device and its programming, this can change the mode of application or suspend detection of dysrhythmias, therefore disabling therapies that would otherwise be delivered.

The U.S. Food and Drug Administration (6) published a warning on March 8, 2016, regarding magnetic interference between breast tissue expanders with magnetic ports and cardiac implantable devices. However, it was stated that there was a very small population at risk due to the general infrequency of patients with cardiac devices who also undergo breast reconstruction. Few direct data exist in this situation, and epidemiologic data would suggest otherwise. A literature review revealed only 2 case reports detailing a similar presentation: Agarwal et al. (7)

reported a woman with history of ICD placement for hypertrophic cardiomyopathy who later underwent bilateral mastectomy with breast tissue expander implantation. Sher Khan et al. (8) detailed a woman with a history of breast cancer status post mastectomy with breast tissue expanders that later required ICD implantation for chemotherapy-induced cardiomyopathy. Both cases also reported that the women presented with complaints of hearing an abnormal sound and were found to have the magnet of their breast tissue expander interacting with their ICD, temporarily suspending all anti-tachycardia therapies.

#### FOLLOW-UP

The patient presented for follow-up without any further complaints of abnormal sounds originating from her device. The device has not experienced any unexpected disabling of tachyarrhythmia detection or therapy function.

#### CONCLUSIONS

This case highlights the rare and potentially life-threatening interaction between a chest prosthetic device involving a magnetic field with an ICD. Prosthetic material without magnet components should

be preferentially used in this select patient population.

**ACKNOWLEDGMENTS** The authors acknowledge and thank Ian Moore from the West Virginia Clinical and Translational Science Institute for the illustration in **Figure 2**.

---

**ADDRESS FOR CORRESPONDENCE:** Dr. Christopher Bianco, PO Box 8003, WVU Heart and Vascular Institute, 1 Medical Center Drive, Morgantown, West Virginia 26505. E-mail: [christopher.bianco@wvumedicine.org](mailto:christopher.bianco@wvumedicine.org).

---

## REFERENCES

1. Howlander N, Noone AM, Krapcho M, et al. Table 4.17 Cancer of the female breast (invasive) - Lifetime risk of being diagnosed with cancer given alive at current age. SEER Cancer Statistics Review, 1975-2016, National Cancer Institute. Bethesda, MD. Available at: [https://seer.cancer.gov/archive/csr/1975\\_2016/](https://seer.cancer.gov/archive/csr/1975_2016/). Accessed November 5, 2019.
2. Patel NJ, Edia S, Abhishek D, et al. Gender, racial, and health insurance differences in the trend of implantable cardioverter-defibrillator (ICD) utilization: a United States experience over the last decade. *Clin Cardiol* 2016;39:63-71.
3. ASPS National Clearinghouse of Plastic Surgery Procedural Statistics. 2014 Plastic Surgery Statistics Report. Available at: <https://www.plasticsurgery.org/documents/News/Statistics/2014/plastic-surgery-statistics-full-report-2014.pdf>. Accessed June 2, 2020.
4. Bertero E, Canepa M, Maack C, Ameri P. Linking heart failure to cancer background evidence and research perspectives. *Circulation* 2018;138:735-42.
5. Liang M, Narayanan K, Kanal E. Magnetic ports in tissue expanders: A caution for MRI. *Magn Reson Imaging* 1989;7:541-2.
6. US Food and Drug Administration. Warning about magnetic interference between breast tissue expanders with magnetic ports and implantable cardioverter-defibrillators (ICDs) or pacemakers: Letter to Health Care Providers. March 8, 2016. Available at: <https://www.fda.gov/medical-devices/letters-health-care-providers/warning-about-magnetic-interference-between-breast-tissue-expanders-magnetic-ports-and-implantable>. Accessed November 1, 2019.
7. Agarwal S, Verma N, Kim JYS, Knight BP, Chicos A. A curious case of breast tissue expander. *Arrhythmia Grand Rounds J* 2015;1:56-7.
8. Sher Khan MMK, Sher Khan MMH, Tolan A, Elmouchi D, Tavera CE. Breast tissue expanders and implantable cardioverter-defibrillator: an unusual interaction. *HeartRhythm Case Report* 2015; 1167-8.

---

**KEY WORDS** breast cancer, breast tissue expander, cardio-oncology, implantable cardiac defibrillator