

Fusiform superior cerebellar artery aneurysm treated with STA-SCA bypass and trapping

Fabricio C. Lamis, Manoel A. De Paiva Neto, Sergio Cavalheiro

Department of Neurosurgery, Federal University of São Paulo, São Paulo, Brazil

E-mail: Fabricio C. Lamis - fabriciolamis@hotmail.com; *Manoel A. de Paiva neto - mapnpaiva@ig.com.br; Sérgio Cavalheiro - iscava@uol.com.br

*Corresponding author

Received: 16 February 14 Accepted: 30 April 14 Published: 19 June 14

This article may be cited as:

Lamis FC, De Paiva Neto MA, Cavalheiro S. Fusiform superior cerebellar artery aneurysm treated with STA-SCA bypass and trapping. *Surg Neurol Int* 2014;5:139-42.

Available FREE in open access from: <http://www.surgicalneurologyint.com/text.asp?2014/5/5/139/134806>

Copyright: © 2014 Lamis FC. This is an open-access article distributed under the terms of the Creative Commons Attribution License, which permits unrestricted use, distribution, and reproduction in any medium, provided the original author and source are credited.

Abstract

Background: Fusiform aneurysms of cerebellar arteries are rare. Different surgical techniques to address these challenging lesions have been described, and their application depends on whether the goal is to maintain the flow in the parent vessel or to occlude it.

Case Description: The authors reported a case of a fusiform aneurysm located in the lateral pontomesencephalic segment of the superior cerebellar artery (SCA) in a 32-year-old man who presented with subarachnoid hemorrhage. The patient was subjected to aneurysm trapping followed by a bypass between the superficial temporal artery (STA) and SCA and had an uneventful recovery.

Conclusions: Although only a few cases of fusiform aneurysms in the supracerebellar artery have been reported in the literature, the treatment strategies adopted were diverse. In selected cases of patients in good neurological condition with ruptured fusiform aneurysms at the proximal segments of SCA and who have poor evidence of collateral supply, the possibility of a STA-SCA bypass with aneurysm trapping must be considered. A review of the current treatment modalities of this pathology is also presented.

Key Words: Bypass, dissecting aneurysm, fusiform aneurysms, superior cerebellar artery aneurysm

Access this article online

Website:

www.surgicalneurologyint.com

DOI:

10.4103/2152-7806.134806

Quick Response Code:



INTRODUCTION

Fusiform aneurysms of cerebellar arteries are rare. There are only 17 cases of fusiform superior cerebellar artery (SCA) aneurysms that have been reported in the literature [Table 1]. Some surgical techniques to address these challenging lesions have been described and mainly aim to occlude the parent vessel, either endovascularly or by trapping.^[3] Considerations of the importance of preserving the parent vessel are also debated in the literature.^[9] We report a case of a fusiform artery aneurysm located in the SCA between

the pontomesencephalic anterior and lateral segments in a 32-year-old male patient who underwent a bypass between the SCA and superficial temporal artery (STA), followed by aneurysm trapping. Controversies about the treatment of this lesion are discussed.

CASE REPORT

A 32-year-old man was admitted to the emergency room with a history of sudden headaches, vomiting, and drowsiness. His past medical history showed arterial hypertension. On neurological examination, he

Table 1: Cases of fusiform supracerebellar aneurysms

Author, year	Age (years)/sex	Arterial segment	Clinical symptoms	Treatment	Outcome
Hirose <i>et al.</i> , 1989	25/F	SCA/anteropontine	Hemorrhage	Proximal clipping	VI nerve palsy
Kalyan-Raman <i>et al.</i> , 1983	38/M	SCA/anteropontine	Headache + dizziness	Conservative	Death
Fukui <i>et al.</i> , 1998	33/F	SCA/anteropontine	Hemorrhage	NA	NA
Ikeda <i>et al.</i> , 1999	37/F	SCAA/anteropontine	Hemorrhage	Clip + wrapping	Good
Sato <i>et al.</i> , 1999	52/F	SCA/cortical	Hemorrhage	Trapping	GR
Mizutani <i>et al.</i> , 2001	34/F	SCA	Hemorrhage	Trapping + STA – SCA bypass	NA
Danet <i>et al.</i> , 2001	27/F	SCA/hemispheric	Ischemia	Embolized + occlusion	GR
Araki <i>et al.</i> , 2002	64/F	SCA/anteropontine	Hemorrhage	Coating	Vegetative
Gotoh <i>et al.</i> , 2003	37/M	SCA/anteropontine	Headache e, dizziness	Conservative	GR
	45/M	SCA/anteropontine	Hemorrhage	Embolized	GR
Atalay <i>et al.</i> , 2007	26/M	SCA/ateropontine	Hemorrhage	Trapping	GR
Nussbaum <i>et al.</i> , 2011	70/F	SCA/anteropontine	Incidental	Clip reconstruction	GR
	60/F	SCA/ateropontine	Incidental	Clip reconstruction	GR
Alurkar <i>et al.</i> , 2012	40/F	SCA/ateropontine	Headache, hemorrhage	Endovascular parent vessel occlusion	GR
	50/F	SCA/ateropontine	Headache/ataxia Hemorrhage	Endovascular parent vessel occlusion	GR
	64/M	SCA/hemispheric	Headache/vomit Hemorrhage	Endovascular parent vessel occlusion	GR
Briganti <i>et al.</i> , 2013	62/F	SCA/anteropontine	Headache/diplopia Hemorrhage	Stent	GR
Lamis <i>et al.</i> , 2014	30/M	SCA/ateropontine	Hemorrhage	STA – SCA bypass + trapping	GR

SCA: Superior cerebellar artery, F: Female, M: Male, STA: Superficial temporal artery, NA: Not available, GR: Good recovery

was confused without localized neurological deficits. A computerized tomography (CT) scan showed a dense subarachnoid hemorrhage (SAH) with blood in the fourth ventricle. He underwent a digital angiography, which revealed a 6 mm fusiform SCA aneurysm without other signs of vascular dissection [Figure 1].

Surgery

The patient underwent surgery on the 15th post-hemorrhage day. He was positioned in park bench. A lumbar catheter was inserted and the cerebrospinal fluid (CSF) was drained to induce brain relaxation. A right subtemporal approach was performed, starting with a straight incision over the parietal branch of the STA. This artery was then dissected 10 cm from subcutaneous tissue under microscopic assistance. The temporal muscle was incised and a basal temporal craniotomy was performed. At that time, the lumbar drain was opened and 20 ml of CSF was drained. After a gentle lifting of the temporal lobe, the perimesencephalic cisterns were visualized and opened widely. The cerebellar tent was then incised. A fusiform dilatation of the SCA was observed between the anterior and lateral mesencephalopontine segments. The perforator arteries to brainstem were visualized proximal and distal to the aneurysm. A segment of the artery distal to the aneurysm that did not have perforator arteries was identified as the location for the anastomosis. The STA was then prepared for a terminolateral anastomosis. Temporary clips were

positioned in the SCA segment and this artery was then opened and cleaned with heparin solution. Anastomosis was then performed in 40 min with 10-0 nylon single stitches. At the end of the procedure, the temporary clips were opened in a sequential manner. The patency of the anastomosis was confirmed by a micro-Doppler probe. Finally, aneurysm trapping was performed.

The patient had an unremarkable recovery and was discharged on postoperative day 7, with a prescription for 100 mg aspirin daily. The postoperative angiogram showed the patency of the bypass, with an excellent filling of the distal SCA segments from the bypass and total aneurysm exclusion [Figure 2].

DISCUSSION

Nonsaccular aneurysms are often referred to as fusiform, dissecting, or trunkal aneurysms.^[6] The heterogeneous terminologies used to describe these lesions have led to additional difficulties in their study. Some authors have described these lesions based on their morphologic aspects, such as fusiform, dolichoectatic, or serpentiform. Others have based their descriptions on etiology, such as dissecting or atherosclerotic aneurysms. According to some authors, the majority of these spontaneous, nonsaccular aneurysms originate from vessel dissection,^[11,18,19] but this is often difficult to prove in pathological studies. Other less-frequent causes include infection, arteriosclerosis, and trauma.

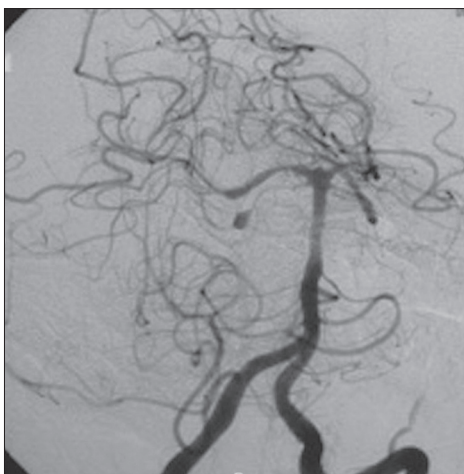


Figure 1: Vertebral angiography showing a fusiform aneurysm in pontomesencephalic segment of SCA

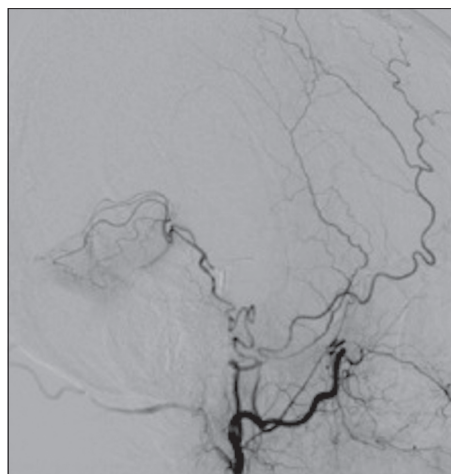


Figure 2: Carotid angiography disclosing adequate filling of distal cerebellar branches through STA anastomosis

Most cases of fusiform cerebellar artery aneurysms are located in the posterior inferior cerebellar artery (PICA), followed by the SCA and the anterior inferior cerebellar artery (AICA).

This is the 18th reported case of fusiform SCA aneurysm [Table 1].^[1,2,3,7,12-16,20-22] Among these cases, 35.3% were reported in men and the median age of the individuals was 44.1 years. In eight cases, the aneurysms were in the anterior pontomesencephalic segment, seven were in the lateral pontomesencephalic segment, two were in the cortical branches, and one was not specified. SAH was the most common clinical presentation. Additionally, ischemic cerebellar events were reported in three cases.

Treatment considerations

Clinical presentation is important for treatment decisions. Patients with ischemic events seem to have more benign clinical courses and, therefore, are usually treated with antiaggregation or anticoagulation therapies. Conversely, patients presenting with SAH have a greater chance of rebleeding and death. In these cases, a more aggressive treatment with the complete exclusion of the aneurysm from circulation is warranted.

Endovascular techniques with the use of stents must be considered in order to exclude the aneurysm and preserve the blood flow. However, immediate aneurysm occlusion does not occur in some cases and double antiplatelet regimen is mainly required in small vessels due the tendency of parent vessel thrombosis.^[24,25] Given the presence of SAH, ventricular shunts might be required. Kung *et al.* reported that a 32% rate of radiographically diagnosed hemorrhage and an 8% rate of symptomatic hemorrhage were associated with ventriculostomy placement in patients who underwent endovascular treatment.^[17]

Microsurgical treatments with clipping or wrapping of the aneurysm are other surgical alternatives. The maintenance

of patency of the parent vessel is an important issue related to these procedures as flow preservation demands more risky and complex techniques.

There are some reports in the literature of using parent artery occlusion (PAO) in cerebellar arteries, without incurring neurological deficits.^[3,8,10] The principle for using PAO to treat the aneurysm is based on the rich collateral blood flow between the cerebellar arteries that could prevent an ischemic event. Furthermore, there is a sense that cerebellar infarcts could be well tolerated by the majority of patients.

The safety of using PAO to treat lesions in the SCA remains unclear. Tohgi *et al.* reported that after SCA infarcts, 61% of cases resulted in independent outcomes, 26% of cases resulted in dependent outcomes, and 6% of cases resulted in death. Worse results were observed in infarcts of the SCA territories, compared to the PICA or AICA.^[23]

Some factors must be considered in the evaluation of the necessity of flow preservation in SCA, such as the proximity of the segment, diameter of the vessel, and collateral blood flow.

The more proximal the SCA segment from the basilar, the more unpredictable the clinical repercussions can be after PAO, which are determined by the presence of adequate collateral blood flow. More distal occlusions are more frequently associated with ischemic lesions because of the presence of fewer collateral vessels, but this ischemia does not tend to cause clinical manifestations.

The SCA diameter is also an important factor that must be noted in angiographic studies. Larger arteries with small adjacent ones, as well as the presence of a vessel spasm, can indicate poor collateral blood flow.

The evaluation of cerebellar collateral blood flow is sometimes very difficult. Using the balloon test to assess

occlusion in the small arteries of the posterior circulation has not been validated as useful and is not routinely performed, even in busy neurovascular centers.

Because the clinical outcome after the sacrifice of the proximal SCA cannot be anticipated in a considerable number of cases, it is intuitive to spare the artery flow. Techniques to preserve flow have significant morbidity. Ausman *et al.* first described STA–SCA anastomosis in 1979.^[5] In 1982, they reported a series of eight cases of STA-SCA bypasses for severe vertebrobasilar insufficiency. Their series had 87% patency in angiograms, four cases with transient morbidity with temporal swelling, one with subdural hematoma, and one death.^[4] Furthermore, STA-SCA bypass is time consuming and technically demanding.

Therefore, the risk of morbidity associated with the surgical procedure must be balanced against the ischemic risks and their consequences.

Fusiform SCA aneurysms are extremely rare, and the best treatment modality must be considered judiciously according to clinical presentation, location, collateral circulation, and the expertise of the neurosurgical team. We must consider the possibility of STA–SCA bypass with aneurysm trapping in selected cases of patients who are in good neurological condition with ruptured fusiform aneurysms in the proximal segments of SCA and poor evidence of collateral supply.

REFERENCES

- Alurkar A, Karanam LS, Nayak S, Oak S. Endovascular management of fusiform superior cerebellar artery aneurysms: A series of three cases with review of literature. *J Clin Imaging Sci* 2012;2:47.
- Araki T, Fujiwara H, Murata H, Sampei T, Taki W. Subarachnoid hemorrhage due to ruptured dissecting aneurysm of peripheral superior cerebellar artery. *No Shinkei Geka* 2002;30:1345-51.
- Atalay B, Altinors N, Yilmaz C, Caner H, Ozger O. Fusiform aneurysm of the superior cerebellar artery: Short review article. *Acta Neurochir (Wien)* 2007;149:291-4.
- Ausman JI, Diaz FG, de los Reyes RA, Pak H, Patel S, Mehta B, *et al.* Posterior circulation revascularization. Superficial temporal artery to superior cerebellar artery anastomosis. *J Neurosurg* 1982;56:766-76.
- Ausman JI, Lee MC, Chater N, Latchaw RE. Superficial temporal artery to superior cerebellar artery anastomosis for distal basilar artery stenosis. *Surg Neurol* 1979;12:277-82.
- Biondi A. Trunkal intracranial aneurysms: Dissecting and fusiform aneurysms. *Neuroimaging Clin N Am* 2006;16:453-65, viii.
- Briganti F, Marseglia M, Leone G, Briganti G, Piccolo D, Napoli M, *et al.* Endovascular treatment of a small aneurysm of the superior cerebellar artery with a flow-diverter device. A case report. *Neuroradiol J* 2013;26:327-31.
- Chaloupka JC, Putman CM, Awad IA. Endovascular therapeutic approach to peripheral aneurysms of the superior cerebellar artery. *AJNR Am J Neuroradiol* 1996;17:1338-42.
- Chang SW, Abila AA, Kakarla UK, Sauvageau E, Dashti SR, Nakaji P, *et al.* Treatment of distal posterior cerebral artery aneurysms: A critical appraisal of the occipital artery-to-posterior cerebral artery bypass. *Neurosurgery* 2010;67:16-25.
- Danet M, Raymond J, Roy D. Distal superior cerebellar artery aneurysm presenting with cerebellar infarction: Report of two cases. *AJNR Am J Neuroradiol* 2001;22:717-20.
- Day AL, Gaposchkin CG, Yu CJ, Rivet DJ, Dacey RG Jr. Spontaneous fusiform middle cerebral artery aneurysms: Characteristics and a proposed mechanism of formation. *J Neurosurg* 2003;99:228-40.
- Fukui S, Minamida Y, Kubota T, Kosukegawa O, Inaba K. A case of peripheral, fusiform type aneurysm originating from the superior cerebellar artery. *No Shinkei Geka* 1998;26:163-7.
- Gotoh H, Takahashi T, Shimizu H, Ezura M, Tominaga T. Dissection of the superior cerebellar artery: A report of two cases and review of the literature. *J Clin Neurosci* 2004;11:196-9.
- Hirose Y, Nakamura T, Takamiya Y, Kinoshita N, Hirai H. Fusiform superior cerebellar artery aneurysm presenting with contralateral abducens nerve paresis—case report. *Neurol Med Chir (Tokyo)* 1990;30:119-22.
- Ikeda K, Shoin K, Taguchi H, Yamano J, Kawahara R. Postpartum dissecting aneurysm of the superior cerebellar artery—case report. *Neurol Med Chir (Tokyo)* 1999;39:852-7.
- Kalyan-Raman UP, Kowalski RV, Lee RH, Fierer JA. Dissecting aneurysm of superior cerebellar artery its association with fibromuscular dysplasia. *Arch Neurol* 1983;40:120-2.
- Kung DK, Policeni BA, Capuano AW, Rossen JD, Jabbour PM, Torner JC, *et al.* Risk of ventriculostomy-related hemorrhage in patients with acutely ruptured aneurysms treated using stent-assisted coiling. *J Neurosurg* 2011;114:1021-7.
- Mizutani T, Kojima H. Clinicopathological features of non-atherosclerotic cerebral arterial trunk aneurysms. *Neuropathology* 2000;20:91-7.
- Mizutani T, Kojima H, Asamoto S. Healing process for cerebral dissecting aneurysms presenting with subarachnoid hemorrhage. *Neurosurgery* 2004;54:342-8.
- Nakahara K, Nakayama K, Takahashi Y, Otsuru K, Takagi S, Shigemori M. Two cases of distal superior cerebellar artery aneurysm. *No To Shinkei* 1994;46:1075-9.
- Nussbaum ES, Defillo A, Zelensky A, Stoller R, Nussbaum L. Dissecting peripheral superior cerebellar artery aneurysms: Report of two cases and review of the literature. *Surg Neurol Int* 2011;2:69.
- Sato M, Kodama N, Sasaki T, Watanabe Z. Aneurysms arising from the cortical segment of the superior cerebellar artery—two case reports. *Neurol Med Chir (Tokyo)* 1999;39:858-62.
- Tohgi H, Takahashi S, Chiba K, Hirata Y. Cerebellar infarction. Clinical and neuroimaging analysis in 293 patients. The Tohoku Cerebellar Infarction Study Group. *Stroke* 1993;24:1697-701.
- Turk AS, Niemann DB, Ahmed A, Aagaard-Kienitz B. Use of self-expanding stents in distal small cerebral vessels. *AJNR Am J Neuroradiol* 2007;28:533-6.
- Zenteno M, Santos-Franco J, Aburto-Murrieta Y, Modenesi-Freitas JM, Ramirez-Guzmán G, Gómez-Llata S, *et al.* Superior cerebellar artery aneurysms treated using the sole stenting approach. *J Neurosurg* 2007;107:860-4.